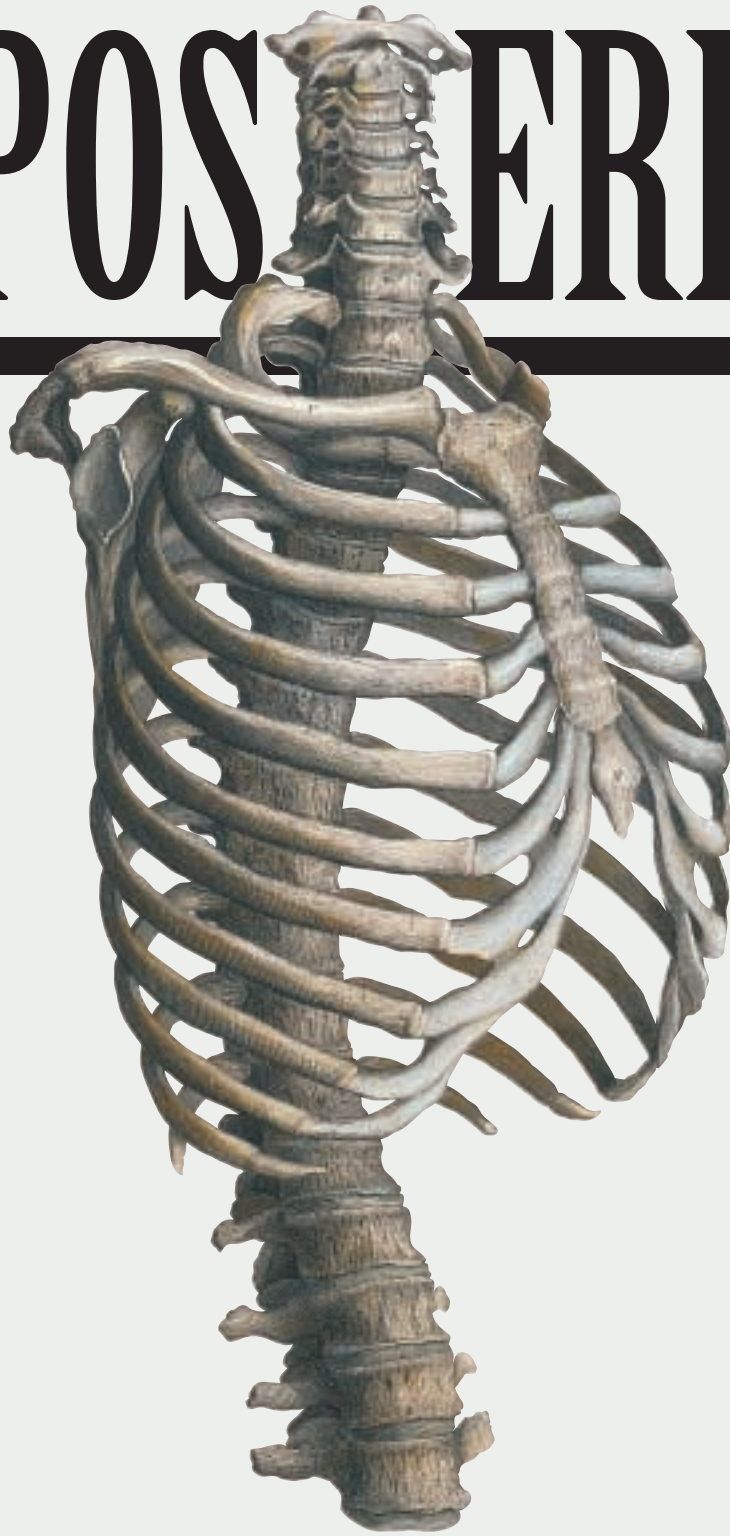

# POSTERIOR SP

---



*from ancient Egypt to the late 20th century*

# SPINAL SURGERY

Jeffrey Cortese, CST

**S**PINAL SURGERY HAS BEEN the domain of two specialties, neurosurgery and orthopaedics. Traditionally, neurosurgeons focus on problems inside the dura and bony abnormalities that result in compromise of the spinal cord or nerves, while orthopaedists are principally concerned with skeletal deformity. The role of each specialty in degenerative disc disease and spinal trauma has been less defined. The first article ever published on the herniated lumbar disc was coauthored by an orthopedist and a neurosurgeon. Consequently, both specialties have claimed the herniated disc and are actively involved in the evaluation and treatment of all forms of disc disease.

At one time, this situation was more clear-cut in spinal trauma. Neurosurgeons generally treated patients with neurological deficits, and orthopedists generally treated

patients without neurological deficits.

This article examines the history of all spinal fusion and will be presented in two parts. In this issue, the discussion begins with ancient approaches to spinal surgery and concludes with 20th Century posterior plating systems. In a subsequent issue of the *Journal*, a follow-up article will continue with several screw placement systems and discuss various modular and fixation systems.

## ancient Egypt

The Edwin Smith papyrus was the earliest known document addressing surgical procedures of the spine.<sup>37</sup> In 1930, Professor James Henry Breasted, a renowned Egyptologist, translated the document, writing careful, detailed commentaries on each case. Breasted believed that, although written circa 1700 BCE, the papyrus itself was a copy of an original manuscript written between 3000 BCE and 2500 BCE.<sup>37</sup> The ancient Egyptian surgeons classified injuries into three categories:

1. *An ailment which I will treat. (Favorable cases.)*
2. *An ailment with which I will contest. (Cases that might be cured.)*
3. *An ailment not to be treated. (Hopeless cases.)*

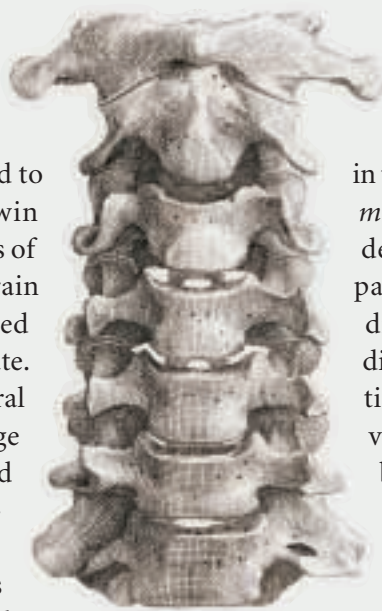
Spinal injuries were relegated to the hopeless category. The Edwin Smith papyrus describes six cases of injury to the spine including sprain in the spinal vertebrae, dislocated vertebrae, and crushed vertebrae. Its author recognized that vertebral injuries with spinal cord damage caused paralysis of the arms and legs, bowel and bladder incontinence, and loss of erection. The Egyptian surgeon treated patients with signs of spinal cord injury by application of meat and honey to the neck and through maintenance of the sitting position. The Breasted translation of case 32 from the Smith papyrus states: "Thou should bind it with meat the first day, thou shall lose his bandages and apply grease to his head as far as his neck, and thou shall bind it with ymrw (sic). Thou shouldst treat it afterward with honey every day and his relief of sitting until he recovers."<sup>37</sup>

## Ancient Greece

Hippocrates (460-377 BCE) discussed the nature of dislocation of the vertebrae and its relationship to paralysis of the limbs, but did not clearly appreciate the role of the spinal cord. He had

observed the results of traumatic spinal cord injury, but did not believe that anything could be done to correct spinal deformity in a living person. Oribasius of Pergamum (325-403 CE) illustrated a stretching-type traction frame for treating fractured spinal columns.

Aretaeus of Cappadocia (150 BCE) observed that in injuries involving the spinal cord, the resulting paralysis originated in some cases at the site of injury. Celsius (30 BCE) noted that death followed quickly when the spinal injury involved the cervical area. Galen (130-201 CE) proved experimentally that interruption of the spinal cord caused paralysis and loss of sensation below the level of injury.



## The Talmud and spinal surgery

Paraplegia, questionably of traumatic origin, was reported in the *Talmud*. An account in the *Talmud* reported by Joshua Leibowitz describes signs and symptoms of paraplegia as well as a differential diagnosis and verification of the diagnosis by postmortem examination. The case properly belongs in veterinary medical literature, because it deals with sheep. The reason for the discussion in the *Talmud* is that the case demanded a ritual decision, since consumption of meat of certain animals suffering from certain diseases, such as bony lesions, is not permitted according to Hebrew religious law. In addition to the case of the sheep, mention is also made of an animal sustaining similar injuries to the spine in a fall from a roof. In spite of the observations of these and other writers, progress was very slow toward an accurate and detailed knowledge of spinal cord function and treatment of injury.

Paul of Aegia (625-690), an outstanding seventh century figure, wrote about spinal injuries, "But if any of the processes of the vertebrae of the spine, as it is called, be broken off, it will readily be felt upon examination with the finger, the broken piece yielding and returning again to its

observed the results of traumatic spinal cord injury, but did not believe that anything could be done to correct spinal deformity in a living person. Oribasius of Pergamum (325-403 CE) illustrated a stretching-type traction frame for treating fractured spinal columns.

position, and therefore we must make an incision of the skin externally and extract it and having united the wounds with sutures, pursue the treatment for recent wounds.”

### High and late Middle Ages

Guido Lanfranc (1296) believed prognosis of dislocation of the spine was hopeless, but he was the first to report peripheral nerve structure. Guy de Chauliac (1300-1368) dismissed the matter by saying that one should not labor to cure paralysis from spinal injury. Called the father of modern surgery, de Chauliac’s great book on surgery was completed in 1363.<sup>37</sup>

Ambrose Pare advocated the cure of spinal dislocations by traction. Recognizing the seriousness of operating on spinal injuries he said, “You may make an incision so as to take forth the splinters of the broken vertebrate which driven in pressed the spinal marrow and the nerves thereof.” The diagnosis was made by palpation and evidence of crepitation.

### Elizabethan Age

Petrus L’Argelate (1531) described reduction of a cervical fracture dislocation by pressure applied to the point of angulation. Fabricius Hildanus (1646) noted treatment of fracture-dislocations of the cervical spine by grasping soft tissues of the neck with forceps and applying pressure. If this procedure of apparent reduction was unsuccessful, the surgeon was advised to explore the spinous processes and vertebral arch extricate fragments of bone.

### Age of Reason

In 1745, James advocated an operation intervention for fracture of the spine. Lorenz Heister, in 1768, advocated surgical removal of fragments in cases of fractured spines. Geraud described attempts to remove a musket ball from the body of the third lumbar vertebrae in a patient who

had paraplegia and bladder paralysis. He finally removed the missile on the fifth attempt, and the wound drained. The patient did recover some strength in his legs.

Gervase Markham described several other surgical procedures during this period including an operation by Louis during the war of 1762 in which a metallic fragment was removed from the lumbar spine and the patient made a complete, functional recovery.

### 19th century

F Chopart and Pierre Joseph Desault, writing in 1796, advocated removal of depressed fragments

of bone in spinal injury and suggested trephining the lamina. Henry

Cline, in 1814, resected fractured spines and lamina for a thoracic fracture-dislocation associated with signs of a complete transverse lesion of the spinal cord.

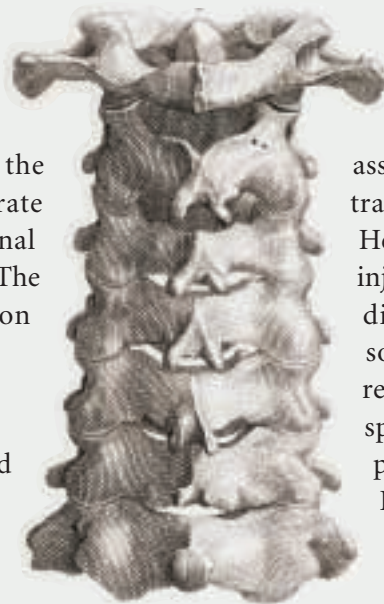
He operated within 24 hours of the injury, but was unable to reduce the dislocation and the patient died soon afterward. In 1827, Tyrell reported several operative cases of spinal dislocation with cord compression, but all patients died.

Rogers, in 1835, also reported discouraging results. In 1828, Alban Smith of Kentucky operated on a man who had fallen from a horse

and suffered immediate paralysis of the legs. Smith removed the spinous processes and depressed the lamina, inspected the dura, and closed the incision. The patient survived and partially improved.

### 20th century

At the turn of the century, Hadra in Galveston, Texas, used wires to stabilize a fracture dislocation of the cervical spine; and George W Albee and Russel Hibbs reported a successful fusion in 1911.<sup>1</sup> However, it was not until the 1950s and 1960s that the Harrington rod for spinal instrumentation became available. In the early 1950s, in Houston, Texas, Paul R Harrington assumed



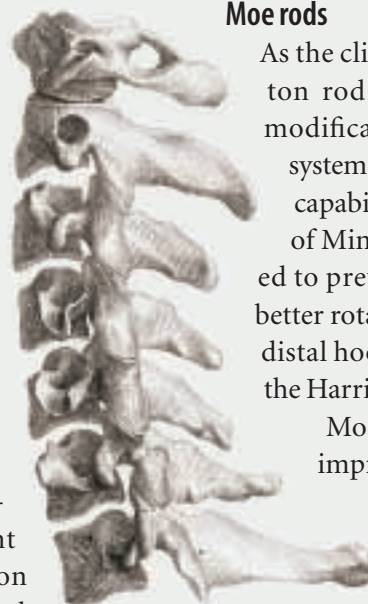
the care of children with progressive neuromuscular scoliosis secondary to polio. Poliomyelitis was epidemic at the time, and there were unacceptably high complication rates with stagnant casting and the major operative procedures of the day. Within this context, Harrington developed a spinal instrumentation system employing hooks and rods to effect spinal fusion as well as correction of the deformed spine. His initial operation required only 20 minutes and utilized facet screws through the vertebral bodies in the corrected position. Although the initial correction and results were satisfying, the results deteriorated postoperatively, leading to the abandonment of the facet-screw fixation concept.

The next step in the development of the modern Harrington rod was to use a threaded rod and hook system to effect correction. Employed in either compression or distraction mode the system was handmade on the night prior to surgery by the surgeon and an assistant. No bone grafting techniques or present-day fusion techniques were employed with these instrumentation systems. Applying knowledge gained from the failures of his earlier attempts, Harrington recognized two important concepts. First, dynamic correction without a good fusion could not work because of the high rate of hook disengagement and rod failure. These two complications produced a recurrence of deformity and failure of the rod. Second, instrumentation must be designed for greater durability, because there was an extremely high rate of instrumentation failure through breakage. Investigators concluded instrumentation would need to withstand seven million cycles of loading before fatigue failure.

Harrington arrived at this figure by doubling the estimated cycles for a one-year period, assuming 10,000 cycles per day. In the early stages of development, these changes were accomplished by doubling the hardness and

changing the fillet design of the ratchets in the rods.

When Harrington presented his modified design at the American Orthopedic Association Meeting in 1960, the widespread use of the current Harrington system began. The modern Harrington rod has gone through more than 47 changes since the original facet-screw system was developed in the early 1950s. Over the last 30 years, the Harrington rod system has been the standard for comparison of instrumentation systems used to effect spinal fusion in the treatment of scoliosis and the fractured spine, particularly at the thoracolumbar junction.



### Moe rods

As the clinical indications for Harrington rod instrumentation expanded, modifications of the basic Harrington system were made to improve stability, capability, and adaptability. John Moe of Minneapolis, Minnesota, attempted to prevent loss of lordosis and gain better rotational control by squaring the distal hook and distal end of the rod of the Harrington system.<sup>6</sup>

Moe believed a square hole would improve control of contouring and rotation better than Harrington's round tube in a round hole. He also employed this system for subcutaneous

distraction, which was particularly helpful in young scoliosis patients with significant residual growth potential.

Modifications in hook design were initiated to prevent hook dislodgment. Other changes included a tongue to lock the sublaminar hook, as well as using two upper hooks in the proximal lamina. By distributing the stress between two hooks, scientists believed it would reduce stress on the individual hook site by 50 percent. Bifid facet hooks are now available to gain purchase around the pedicle.

CL Edwards of Baltimore had modified the Harrington system by altering the hook to match the anatomy of the lamina. He subsequently

improved modularity by employing universal rods, pedicle screws, and rod sleeves to effect forces in several directions in addition to distraction.<sup>9</sup> These hook and rod modifications were attempts to improve fixation attained by the original Harrington devices.

Harrington instrumentation revolutionized the surgical care of patients with spinal deformity and traumatic injuries of the spine. Most instrumentation systems available today are based on concepts derived from the development of Harrington instrumentation. All new instrumentation should be measured against Harrington instrumentation with regard to the biomechanical principles and the clinical results of that particular system.

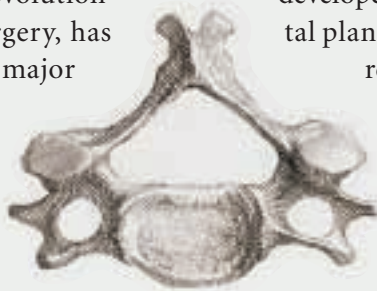
The use of posterior instrumentation led to some significant advances in the care and treatment of spinal fractures and deformity. The Harrington system, though a revolutionary development in spinal surgery, has many deficiencies. Some of the major problems include: rod breakage due to the notches; hook pull-out; lack of rotational control with loss of sagittal plane alignment; and over distraction of the injured spine. These shortcomings encouraged the development of newer spinal implant systems.

The square-ended Moe system partially addressed rotational control. However, to ensure sagittal plane correction, this system requires precise determination of the hook placement and rod contouring. Supplemental sublaminar wiring to control hook pullouts resulted in higher risks of neurologic injury during insertion and removal of these wires. The use of pedicular fixation, which allows shorter fusion levels and preservation of more motion segments, is technically demanding and can cause neurologic injuries.

### Jacobs rodding

In 1979, Rea R Jacobs, collaborating with F Schlaepfer, R Mathys, and Alf Nachemson, designed a system to address these problems. A

rod with hooks controlled by nuts and washers permitted positioning of the hook axially along the rod, thus eliminating the need for deep notches in the rod and their weakening effect. Extra head 316-L stainless steel 5 mm by 7 mm rods were used to achieve maximum strength and increased fatigue life. The upper and lower hooks were in the anatomical configuration necessary to conform to the lamina to which they are applied. A sliding cover is placed over the cranial aspect of the upper lamina to lock the upper hook in place, thus avoiding the use of high distraction loads on the spine necessary for upper hook attachment. Both hooks are rotationally locked into the rod by meshing radial grooves in six-degree increments into the hook and a washer keyed to the rod. Superior and inferior nuts crimped to the flat end of the rod lock the hooks into position. The system was developed to permit maintenance of sagittal plane correction to facilitate implant



removal and allow for the possibility of fusion of only the injured motion segment. Implant removal would then allow restoration of motion of the infused segments after successful fusion and healing of the fractures.<sup>11</sup> In canine models, there is evidence that unfused motion segments undergo degeneration.

The Jacobs locking hook spinal rod helps the stabilization and reduction of the thoracolumbar spine. It provides adequate correction and maintenance of correction with little risk of complications. Attention to detail, especially during upper hook placement, is mandatory.

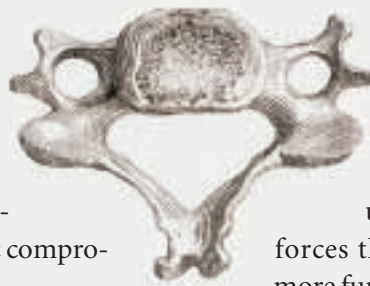
### Luque sublaminar technique

The use of sublaminar wiring to achieve multiple points of fixation for spinal stabilization was developed by Eduardo Luque, MD, more than 20 years ago. Luque created his sublaminar wiring technique after observing the use of sublaminar wiring for fusion of a fracture and dislocation of C3 on C4.<sup>22</sup> The advantages of sublaminar wiring were immediately apparent: firm fixa-

tion at multiple points along the instrumented area of the spine and distribution of the corrective forces being applied to the spine, thereby diminishing the risk of osseous failure.

A large number of his scoliotic patients had poliomyelitis with associated osteoporotic bone. In this patient population, Luque found the use of conventional Harrington instrumentation was associated with a high failure rate due to cutting out the hooks. In addition, the socioeconomic situation of many patients made postoperative bracing difficult or impossible.

For the next several years, with increased clinical and laboratory experience, Luque modified the technique numerous times and reached several conclusions.<sup>22,23</sup> He found that the use of double L rods with segmental sublaminar wiring combined with good surgical technique led to a very high rate of arthrodesis. This construct provided excellent correction in both the frontal and sagittal planes. The multiple points of firm fixation allowed significant correction of the curves to occur. Luque cautioned against very aggressive attempts at correction that could lead to neurologic compromise.



### The arrival of segmental fixation

The concept of segmental fixation of the spine dates back to 1902.<sup>19</sup> Fritz Lange developed a technique for tuberculosis spondylitis designed to prevent progressive kyphosis. The technique involved placing buried steel rods in the back, which were fixed to the spinous processes with wires. His reception at the American Orthopedic Association was skeptical. He was thanked for, "...bringing before the members a method of securing fixation of the spinal column without restraint of the respiratory organs of the body, but it is questionable whether this method would be much of use."

In 1963, J Resina described a technique for the use of metal rods fixed to the spinous processes.<sup>28</sup> He felt that it was most effective biomechanically for the corrective forces to work at

right angles to the long axis of the rod. More recently, other methods of segmental fixation have been developed.

### Cotrel-Dubousset system

Since its introduction to the Scoliosis Research Society in 1984, Cotrel-Dubousset (C-D) instrumentation for the correction and stabilization of spinal deformity has generated tremendous excitement and various applications. Both the Harrington and Luque systems were popular. Their biomechanics, however, were confined to the application of unidirectional forces that achieved adequate correction, but often inadequate fixation.

The addition of sublaminar wires, while safe in most experienced surgeon's hands, offers the potential for catastrophic complications. Indeed, many teachers of spinal surgery had great difficulty conveying the fundamentals of sublaminar wiring technique without exposing patients to increased risk. The C-D device, with its ingenious rod design, has allowed for the unique utilization of multiple forces that attack spinal deformity on a more fundamental basis.<sup>5,7,8,13,29</sup>

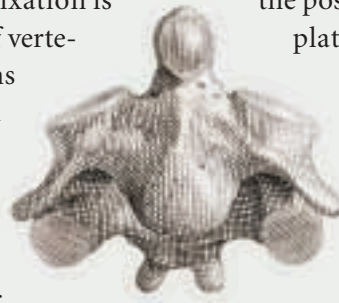
The C-D device introduced a significant increase in the number of available surgical options for the patient with spinal deformities. The use of apical distraction or compression, the ability to distract and compress along the same rods, the advantages of rod coupling through the use of device for transverse traction (DTT), and the newer generation devices that offer exciting potential for fixation to the sacrum and pelvis are major milestones in the operative treatment of spinal deformity. Currently, the use of the device is expanding into the field of degenerative spinal disorders and spinal trauma. With tens of thousands of cases now performed worldwide, the Cotrel-Dubousset device has proved to be a safe and effective method in the treatment of scoliosis.

## Texas Scottish Rite Hospital spinal system

A truly universal spinal instrumentation system should be applicable to any area of the spine and to any spinal pathology for which stabilizing or corrective instrumentation is indicated. Such a system has been developed over the past five years at the Texas Scottish Rite Hospital (TSRH).<sup>16</sup>

Originally designed as an adjunctive implant for Luque sublaminar segmental instrumentation (SSI), the original Crosslink device has become a part of a complete, versatile system for correction of adolescent spinal deformity. It utilizes and expands the principles of the C-D system, while simultaneously improving certain technical aspects of implantation and, perhaps more importantly, improving the ease of removing and revising instrumentation already implanted.<sup>2</sup>

Anterior and transpedicular fixation is now possible with the addition of vertebral screws. This greatly broadens the uses of the instrumentation pathologies other than adolescent deformity, including all types of adult degenerative, traumatic, or neoplastic instabilities. With the addition of smaller, pediatric-sized hooks, deformity in very young or skeletally dysplastic patients can be instrumented safely, addressing certain cervical spine instabilities. Because of its ability to extend existing instrumentation cephalad or caudad by the axial cross-linking plates, the TSHR system has evolved into a truly universal system for instrumenting the spine.



## Posterior plating systems

### Roy-Camille

Devised over 25 years ago by R Roy-Camille, the posterior approach of the spine is relatively simple, and was later followed by a pedicular-screw plating system in the thoracolumbar spine.<sup>30</sup> He applied posterior fixation with plates and screws to the cervical, thoracic, and lumbar spine. The evolution of the instrumen-

tion has now solved almost all difficulties and technical problems of stabilization of the spine, whatever the pathology.

For thoracolumbar levels, the plates are 1 cm wide to fit into the posterior thoracolumbar vertebral grooves. The interface between the holes is 13 mm. This distance has been selected because the mean distance between two vertebral pedicles is approximately 26 mm with only slight differences along the entire length of the spine. To prevent plate breakage, the plates have reinforced holes. This reinforcement around the holes diminishes stress concentration at the holes so that the relative strength of the plate is the same along its length. When bending a long plate, the contour will be smooth and very regular along the entire plate without any abrupt bends at the screw holes. They are pre-contoured to adapt to the normal sagittal curvature of the posterior aspect of the spine. The same plate can be adapted for use in the thoracic and lumbar level.

The clearance of the screws in the hole plates produces a strong, flexible fixation that prevents screw breakage. This technique may be used at the lumbar spine and at the thoracic spine. The diam-

eter of the screws changes as the size of pedicles changes from thoracic to lumbar region. Using this instrumentation, the surgeon can solve any problem of instability of the spine and reconstruct in a stable manner.

### Louis plates

Following the works of Roy-Camille, published in 1969, on posterior vertebral osteosynthesis by pedicle screw plate, René Louis adopted this method to stabilize certain vertebral lesions. After two years, Louis decided to implement his own method with different material while maintaining the use of pedicle screws.<sup>21</sup> Transarticular screws did not seem practical and could be dangerous for the contents of the foramen. In addition, the screw holes were too far apart to regularly allow for exact positioning of the pedicular screws. To avoid a systematic second operation



with ablation of the material, Louis chose short and solid osteosynthesis accompanied by fusion of the posterior joints covered by osteosynthesis. He also modified the method for screw insertion in order to decrease the surgeon's exposure to X-rays. Ultimately, Louis's theory of vertical stability with three vertical columns, one anterior and two posterior, led him to perform anterior osteosynthesis or even combine posterior and anterior osteosynthesis to repair and stabilize each column with the same type of plate.

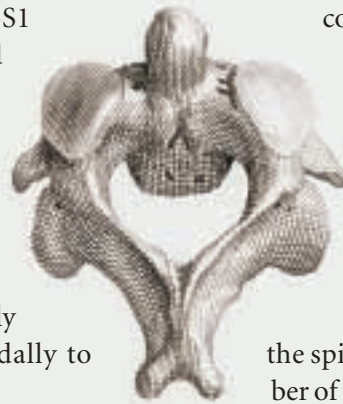Louis began to insert his own plate in 1972.<sup>21</sup> The first plates were made of vitallium, chosen for its excellent tolerance. However, the screws proved to be brittle, and in 1985, he selected stainless steel. The equipment included the plates, screws, and ancillary material, and he designed varied plates according to the vertebral region in question. For L5-S1 osteosynthesis, he created butterfly-shaped monoblock plates resembling the posterior arch and equipped with four holes. The two superior holes are oval shaped for the two L5 pedicular screws, and the two inferior holes are slanted obliquely at 45 degrees outward and caudally to allow for fixation in the sacral ala.

These plates are constructed in three sizes, according to the patient's interpedicular distance. Despite the model, the sacral foramina have been studied according to anatomical data so that the sacral screws can always be positioned away from the S1, S2 roots.

For osteosynthesis extending from L4 or L3 to the sacrum, Louis opted for a pair of symmetrical plates, each having a superior hole for sagittal screw placement into the L3 or L4 pedicles and for two inferior screws for oblique placement in the sacral ala. In the middle section, the plates are equipped with closely spaced holes, four of which are in the L4-S1 plate, allowing for precision screwing of the intermediate pedicles. Louis's system of screw plates for anterior and posterior vertebral osteosynthesis permits short and solid stabilization of the three stabilizing

columns of the spine. The association of a posterior interarticular or anterior intersomatic (interbody) arthrodesis is usually indispensable. An excellent fusion rate at a moderate cost is the principal advantage of this method.

There is much debate in the literature over the optimum spinal internal fixation device that affords the surgeon the benefit of rigid stabilization for fusion maturation while preserving the normal contouring and biomechanics of the spine. For years, the standard was the Harrington rod and hook system. This system allowed the surgeon to manipulate the spinal deformity in the coronal plane, but included excess motion segments in the fusion mass with the additional loss of optimum sagittal contouring. Today, there is great interest in utilizing the pedicle as a means of rigidly instrumenting all three columns of the spine, especially in the presence of posterior element deficiency.



#### ***Transpedicular fixation***

The addition of spinal plates attached to the pedicle screws allows the surgeon to perform wide, aggressive decompressions of the spine while stabilizing a limited number of spinal segments with preservation of the normal contours of the spine.

In 1944, D King first developed the concept of using the pedicle as a means of spinal fixation, and it was not until 1959 that Boucher reported on the actual success of obtaining a posterior fusion by passing screws through the lamina and pedicle into the vertebral body.<sup>17,3,34</sup> Since the early 1960s, numerous surgeons have developed spinal fixation systems using the pedicle as a major component of fixation.<sup>14</sup>

#### **Conclusion**

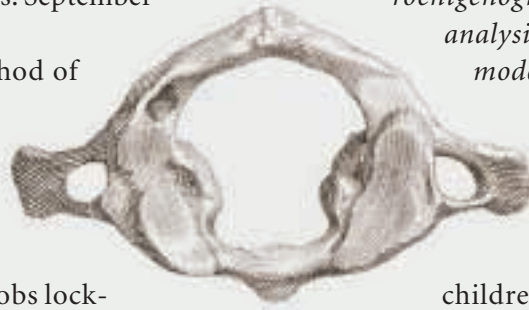Through the practice and persistence of many medical professionals over the years, treatment of spinal injuries has progressed from untreatable to a condition with a variety of options. The second half of this article will continue to cover the considerable advancements in this field.

## About the author

Jeffrey J Cortese, CST, has been a certified surgical technologist for five years. He is employed at Bon Secours Hospital in Grosse Pointe, Michigan. He primarily works with the hospital's staff neurological surgeon, John L Zinkel, MD, PhD. With every case, he and Zinkel are constantly enhancing the hospital's neurological surgery service with minimally invasive procedures as well as new techniques and instrumentation.

## References

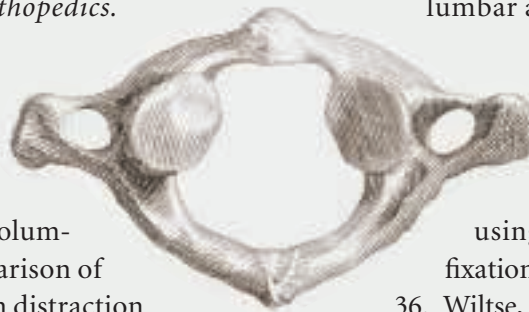1. Albee FH. Transplantation of a portion of the tibia for Potts disease. *Journal of American Medical Association*. 1911; 57. 885-886.
2. Birch, Camp, Corin, et al. Rotational stability of various pedicle hook designs—an in-vitro analysis. Presented at the Annual Meeting of the Scoliosis Research Society. Amsterdam, The Netherlands. September 17-22, 1989.
3. Boucher HH. A method of spinal fusion. *Journal of Bone Joint Surgery*. 1959;41B. 248.
4. Boucher, Burkus, Sutherland, et al. Jacobs locking hook spinal rod and the AO fixator intern for fractures of the thoracic and lumbar spine. Submitted for publication. Unpublished data.
5. Cotrel, Dubousset, Guillaumat. New universal instrumentation in spinal surgery. *Clinical Orthopedics*. 1988; 227. 10-23.
6. Denis, Ruiz, Searls. Comparison between square ended distraction rods and standard round ended distraction rods in the treatment of thoracolumbar spinal injuries. A statistical analysis. *Clinical Orthopedics*. 1984; 189. 162- 167.
7. Denis F. Cotrel-Dubousset instrumentation in the treatment of idiopathic scoliosis. *Orthopedic Clinics of North America*. 1988;19. 291-311.
8. Ecker, Betz, Trent, et al. Computer tomography evaluation of Cotrel-Dubousset instru-



mentation in idiopathic scoliosis. *Spine*. 1988;13. 1141-1144.

9. Edwards CL, Levine AM. Early rod-sleeve stabilization of the injured thoracic and lumbar spine. *Orthopedic Clinics of North America*. 1986; 17. 121-145.
10. Edwards CC. Sacral fixation device—Design and preliminary results. *Scoliosis Research Society Annual Meeting*. Orlando, Florida. 1984.
11. Gertzbein, Jacobs, Stoll, et al. Results of a locking hook spinal rod for fractures of the thoracic and lumbar spine. *Spine*. 1990; 15. 275-280.
12. Gurr, McAfee, Shih. Biomechanical analysis of posterior instrumentation systems after decompressive laminectomy. *Journal of Bone Joint Surgery*. 1988; 70A. 680-691.
13. Gurr, McAfee, Warden, et al. *A roentgenographic and biomechanical analysis of spinal fusions; A canine model*. Baltimore: Scoliosis Research Society. 1988. 77-78.
14. Harrington PR, Tullos HS. Reduction of severe spondylolisthesis in children. *South Medical Journal*. 1969; 62. 1-7.
15. Herrmann HD. Transarticular metal plate fixation for stabilization of the lumbar and thoracic spine. *Acta Neurochir*. 1979; 48. 101-110.
16. Johnston, Ashman, Corrin. *Mechanical effects of crosslinking rods in Cotrel-Dubousset instrumentation*. Hamilton, Bermuda: Scoliosis Research Society. 1986. 77-78.
17. King D. Internal fixation for lumbo-sacral fusion. *American Journal of Surgery*. 1944;66. 357.
18. Krag, Weaver, Beynon, Haugh. Morphometry of the thoracic and lumbar spine related to transpedicular screw placement for surgical spinal fixation. *Spine*. 1988;13. 27-32.
19. Lange F. Support for the spondylolytic by means of buried steel bars attached to the

- vertebrate. *American Journal of Orthopedic Surgery*. 1910; 8. 344-361.
20. Lesion, Bouassakao, Cama, et al. Posttraumatic fixation of the thoracolumbar spine using Roy-Camille plates. *Neurosurgery*. 1982;18. 167-173
  21. Louis R, Maresca C. Lumbo-sacral fusion by internal fixation. *Clinical Orthopedic Research*. 1985;203. 18- 33.
  22. Luque E. The anatomic basis and development of segmental spinal instrumentation. *Spine*. 1982; 7. 256-259.
  23. MacEwen, Bennett, Guille. Autologous blood transfusions in children and young adults with low body weight undergoing spinal surgery. *Journal of Pediatric Orthopedics*. 1990; 10. 750-753.
  24. Magerl FP. Stabilization of the lower thoracic and lumbar spine with external skeletal fixation. *Clinical Orthopedics*. 1984; 189. 125-141.
  25. McAfee, Werner, Glisson. A biomechanical analysis of spinal instrumentation systems in thoracolumbar fractures—Comparison of traditional Harrington distraction instrumentation with segmental spinal instrumentation. *Spine*. 1985;10. 204-217.
  26. Muller, Allgower, Schneider, et al. *Manual of internal fixation*. 3rd ed. Berlin: Springer-Verlag. 1991. 627- 682.
  27. Ogilvie JW, Bradford DS. Lumbar and lumbosacral fusion with segmental fixation. Scoliosis Research Society Annual Meeting. Orlando, Florida. 1984.
  28. Resina J, Alves A. A technique for correction and internal fixation for scoliosis. *Journal of Bone Joint Surgery*. 1977; 59:2. 159-165.
  29. Richards, Birch, Herring, et al. Frontal plane and sagittal plane balance following Cotrel-Dubousset instrumentation for idiopathic scoliosis. *Spine*. 1989; 14. 733-737.
  30. Roy-Camille R, Demeulenaere C. Plating of thoracic, thoracolumbar and lumbar injuries. *Orthopedic Clinics of North America*. 1986; 17. 147-161.
  31. Sasso, Cotler, Reuben. Posterior fixation of thoracic and lumbar spine fractures using DC plates and pedicle screws. *Spine*. 1991;16. 5134-5139.
  32. Schlapfer, Worsdorfer, Magerl, et al. Stabilization of the lower thoracic and lumbar spine: comparative in-vitro investigation of an external skeletal and various internal fixation devices. In: Uhtoff HK, Stahl E, eds. *Current concepts of external fixation of fractures*. New York: Springer-Verlag. 1982. 367-380.
  33. Steffee AD, Sitkowski DJ. Posterior lumbar interbody fusion and plates. *Clinical Orthopedics*. 1988; 227. 99.
  34. Steffee, Biscup, Sitkowski. Segmented spine plate with pedicle screw fixation: A new internal fixation device for disorders of the lumbar and thoracolumbar spine. *Clinical Orthopedics*. 1986;203. 45.
  35. Thalgott, LaRocca, Aebi, et al. Reconstruction of the lumbar spine using AO DCP plate internal fixation. *Spine*. 1989;14. 91-95.
  36. Wiltse, Bateman, Hutchinson, et al. The paraspinous sacrospinalis-splitting approach to the lumbar spine. *Journal of Bone Joint Surgery*. 1968; 50A. 919.
  37. Yashon D. *Spinal Injury*. Appleton-Century-Crofts. 1978. 1-4.
  38. Zindrick, Wiltse, Widell, et al. A biomechanical study of intrapedicular screw fixation in the lumbosacral spine. *Clinical Orthopedics*. 1986; 203. 99.



## Posterior spinal surgery

### Earn CE credit at home

You will be awarded one continuing education (CE) credit for recertification after reading the designated article and completing the exam with a score of 70% or better.

If you are a current AST member and are certified, credit earned through completion of the CE exam will automatically be recorded in your file—you do not have to submit a CE reporting form. A printout of all the CE credits you have earned, including Journal CE credits, will be mailed to you in the first quarter following the end of the calendar year. You may check the status of your CE record with AST at any time.

If you are not an AST member or not certified, you will be notified by mail when *Journal* credits are submitted, but your credits will not be recorded in AST's files.

Detach or photocopy the answer block, include your check or money order made payable to AST and send it to the Accounting Department, AST, 6 West Dry Creek Circle, Suite 200, Littleton, CO 80120-8031.

**Members: \$6 per CE, nonmembers: \$10 per CE**

- Which physician and philosopher proved that interruption of the spinal cord caused paralysis?  
 A. Aretaeus      B. Oribasius  
 C. Galen          D. Hippocrates
- In what year did Albee and Hibbs report a successful fusion?  
 A. 1911          B. 1920  
 C. 1897          D. None of the above
- According to Harrington, instrumentation in the spine would need to withstand \_\_\_\_\_ cycles of loading before fatigue?  
 A. Four thousand      B. One hundred  
 C. Seven million      D. One billion
- Which surgeon developed the sublaminar wiring technique?  
 A. Jacobs          B. Harrington  
 C. Luque          D. Both B and C
- When was the Cotrel-Dubousset instrumentation introduced?  
 A. 1983          B. 1987  
 C. 1984          D. 1978
- Who developed the posterior cervical plating system?  
 A. Edwin Smith      B. Guido Lanfranc  
 C. Roy-Camille      D. CL Edwards
- What was the earliest known document that described surgical procedures of the spine?  
 A. Talmud          B. Edwin Smith papyrus  
 C. Old Testament      D. Galen's diaries
- Segmental fixation of the spine when a technique developed by \_\_\_\_\_ involved placing buried steel rods in the back were fixed to the spinous processes with wires.  
 A. Fritz Lange      B. Rea Jacobs  
 C. Roy-Camille      D. Cotrel-Dubousset
- In Ancient Greece, who discussed the nature of dislocation of the vertebrae and its relationship to paralysis?  
 A. Aretaeus of Cappadocia  
 B. Celsius  
 C. Hippocrates  
 D. Oribasius
- \_\_\_\_\_ is a truly universal spinal instrumentation system that is applicable to any area of the spine and to any spinal pathology for which corrective instrumentation is indicated.  
 A. Louis Plates  
 B. Texas Scottish Rite Hospital Spinal System  
 C. Luque wires  
 D. Harrington rods

### Posterior spinal surgery

Certified Member       Certified Nonmember

Certification No \_\_\_\_\_

Name \_\_\_\_\_

Address \_\_\_\_\_

City \_\_\_\_\_ State \_\_\_\_\_ ZIP \_\_\_\_\_

Telephone \_\_\_\_\_

	a	b	c	d		a	b	c	d
1	<input type="checkbox"/>	<input type="checkbox"/>	<input type="checkbox"/>	<input type="checkbox"/>	6	<input type="checkbox"/>	<input type="checkbox"/>	<input type="checkbox"/>	<input type="checkbox"/>
2	<input type="checkbox"/>	<input type="checkbox"/>	<input type="checkbox"/>	<input type="checkbox"/>	7	<input type="checkbox"/>	<input type="checkbox"/>	<input type="checkbox"/>	<input type="checkbox"/>
3	<input type="checkbox"/>	<input type="checkbox"/>	<input type="checkbox"/>	<input type="checkbox"/>	8	<input type="checkbox"/>	<input type="checkbox"/>	<input type="checkbox"/>	<input type="checkbox"/>
4	<input type="checkbox"/>	<input type="checkbox"/>	<input type="checkbox"/>	<input type="checkbox"/>	9	<input type="checkbox"/>	<input type="checkbox"/>	<input type="checkbox"/>	<input type="checkbox"/>
5	<input type="checkbox"/>	<input type="checkbox"/>	<input type="checkbox"/>	<input type="checkbox"/>	10	<input type="checkbox"/>	<input type="checkbox"/>	<input type="checkbox"/>	<input type="checkbox"/>

Mark one box next to each number. Only one correct or best answer can be selected for each question.