

S16.0  
DFOV 24.0 cm  
choline / creatine  
cursor 3x3

BY BOB CARUTHERS, CST, PHD

# HIGH GRADE ASTROCYTOMA IN THE ADULT

**BIOLOGY,  
PATHOLOGY,  
DIAGNOSTICS,  
AND TREATMENT**

PART 2

2511

R

1  
2  
0

-1



# GRADE ASTROCYTOMA

The current WHO classification system (1993) for astrocytomas illustrates diagnostic concepts that have developed over the years. The first category, covering some 75% of the astrocytomas, is divided into three groups that demonstrate a spectrum of increasing malignancy—astrocytoma, anaplastic astrocytoma, and glioblastoma multiforme. This group of tumors tends to undergo malignant changes and invade the surrounding brain tissues and the meninges. The second category consists of the polycystic astrocytoma, pleomorphic xanthoastrocytoma, and subependymal giant cell astrocytoma.

The second grouping tends to have a better prognosis than the first because they do not demonstrate such an aggressive capacity for invasion of surrounding tissue and are somewhat limited in comparison to the first group in both growth rate and anaplastic progression. A significant histologic distinction can be made between group one and group two. Group one, high-grade astrocytomas, is adept at infiltrating surrounding tissue. The second tumor group, on the other hand, consists of micro-

scopically circumscribed neoplasms. This demonstrates a limited aggressiveness in comparison to the first group.

This article will focus on the tumors of group 1, specifically the high-grade astrocytomas: anaplastic astrocytoma and glioblastoma multiforme. (Part I, published in the March 2001 issue, provides a general discussion of these tumors). A case that began with a mild focal symptom and progressed to hemiparesis secondary to a large right frontoparietal mass will be used throughout the article for illustrative purposes. The treatment section will focus exclusively on the glioblastoma multiforme (GBM). It is presumed that a histologic distinction can be made consistently between the astrocytoma and the anaplastic astrocytoma and glioblastoma multiforme.<sup>21</sup>

## Illustrative case

This case history will be used to demonstrate the application of diagnostic and treatment strategy, as well as modalities. The illustrative case concerns a Caucasian male in his early 50s, right handed with no history of neurological deficit, although he suffered two minor concussions during high school. His presenting complaint was a tingling sensation in the 4th and 5th fingers of his left hand, which he attributed to a compression of the ulnar nerve following a long car trip. Between the time that the appointment was scheduled and the patient's arrival at the doctor's office, a tingling sensation developed in the median nerve distribution. He had no history of headache, nausea, or vomiting, demonstrated no central neurological deficits during the exam, and had a positive Tinel's sign in the ulnar distribution.

The patient was started on prednisone and scheduled for an EMG. The EMG was performed approximately one week after the initial visit with normal results.

By that time, the patient began to notice what he called a "bizarre sensation" on the left half of his body. While attending a social event, he noted that someone caught his arm, and he had not recognized it until he felt off balance. By the next morning, he had developed a droop on the left side of his face and was experiencing difficulty walking without bearing to the left. At that time, he admitted himself to the emergency room and a CT scan was performed. The scan demonstrated a large right-frontoparietal mass consistent with a high-grade astrocytoma. Prior to surgery, a MRI with enhancement was also performed. The preoperative diagnosis was glioblastoma, which was confirmed by histological analysis following surgery.

## Diagnostics

### *Intracranial mass*

As with all diagnostic investigations, the diagnosis of an intracranial mass begins with a good history and physical. Risk factors for glioblastoma multiforme in the adult include: race (Caucasian > African American), gender (male

> female), and age (most common in the 50s and 60s). The most frequent symptom associated with these tumors is headache. However, headache is also common for almost any intracranial mass and a wide range of other diseases and conditions.

The most important signs and symptoms related to glioblastoma multiforme evolve from the specific area of the brain that is invaded. Tumors such as meningiomas do not invade brain tissue. They act as a well-differentiated, slow-growing mass lesion that pushes against the brain tissue. Symptoms from this type of tumor are related to pressure and cellular irritability. The diffuse invasion of the brain employed by the glioblastoma multiforme may allow it to go symptomless until it is quite large. Mild focal symptoms may appear for a period, but symptoms can rapidly progress. Hemiparesis is not uncommon in the emergency room.

### *Differential diagnosis*

Headache and/or mild focal neurologic symptoms could indicate any number of neurologic problems. In practice today, the patient is sent immediately for a CT scan or MRI when the symptoms appear to have a central origin.

### *EMG*

The electromyogram (EMG) is commonly referred to as a nerve conduction study. The EMG is based on the principle that electrically stimulating a nerve should produce a reaction somewhere along the course of the nerve. Properly placed electrodes measure both the response and the conduction time. Recording electrodes are placed on the appropriate muscle belly for motor nerves. For sensory studies, the electrodes are placed over the nerve. Superficial nerves may be stimulated using a skin electrode, but nerves deep within the skin require the use of an insulated needle electrode.

A grounding electrode or, more commonly, a grounding plate is placed between the stimulating and recording electrodes with the two being equidistant from the ground. Electrical current is applied to achieve a maximum response. The

current is then increased again to guarantee a maximum response.

### CT scan

Godfrey Hounsfield conceptualized the technique of the CT scan, and the first clinical use occurred in 1972. This revolutionized the diagnostic approach to intracranial lesions and abnormalities. Because the CT scan allows for direct imaging and differentiation of soft-tissue structures, it is an effective means for identifying space-occupying lesions, tumors and metastases. The scan times with CT imaging vary between 500 milliseconds to a few seconds. This short scan time makes it especially attractive in the emergency room setting.

Developed for purely diagnostic procedures, the CT scan can be used for interventions such as guided biopsy and minimally invasive therapy, may be used to help plan radiation therapy for cancer and to follow the effects of radiation on the tumor. Today, the CT scan can be combined with other computerized-image manipulating techniques to produce three-dimensional images.

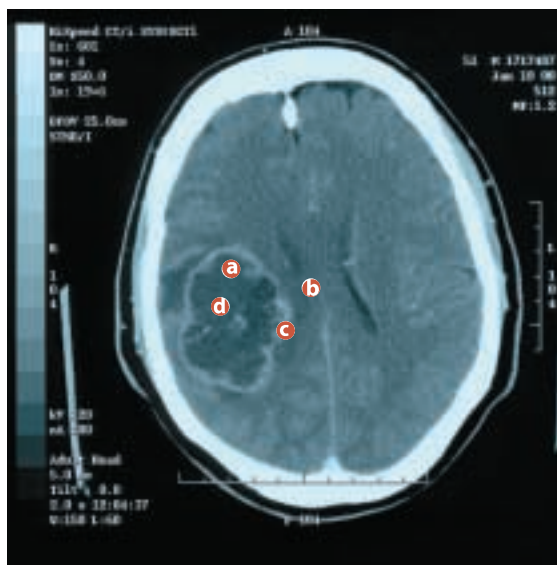
A CT scanner resembles a large box with a 60- to 70-cm hole, large enough to accommodate a human being, in the center. The covers of a CT scanner house a rotating device with an X-ray tube mounted on one side and a banana-shaped X-ray detector opposite. As the rotating frame spins the X-ray tube and detector around the patient, a fan-shaped beam is created. Each time the tube completes a 360° rotation, a thin image is produced, which represents a “slice or cut” through the brain. Each slice is focused between 1-10 mm. Each two-dimensional slice provides limited information alone. Since the scan produces both coronal and transverse slices, the combined films provide a solid interpretation of the three-dimensional aspects of the area being scanned. As the data from a slice is interpreted, the computer assigns a number to each level of density. This number is then converted and added to a color scale by the computer so an image can be produced.

The CT scan can be performed without any type of enhancement of the arteries;

however, it is common for diagnostic scans to involve a contrast agent when vascular information is required. There are four basic types of contrast agents used with the CT scan, which can be categorized based on the method of delivery:

- Intravenous contrast agents
- Oral contrast agents
- Contrast agents given rectally
- Contrast agents given as a gas that is inhaled (Xenon CT).

The most common approach is via intravenous infusion. Typically, between 75 and 100 cc of



**FIGURE 1**

Illustrative case,  
CT scan

performed in ER

contrast medium is used. This varies somewhat on the patient’s age, weight, and the area being scanned. The contrast agent has an iodine base, so allergies to iodine and shellfish must be checked prior to injecting this medium.

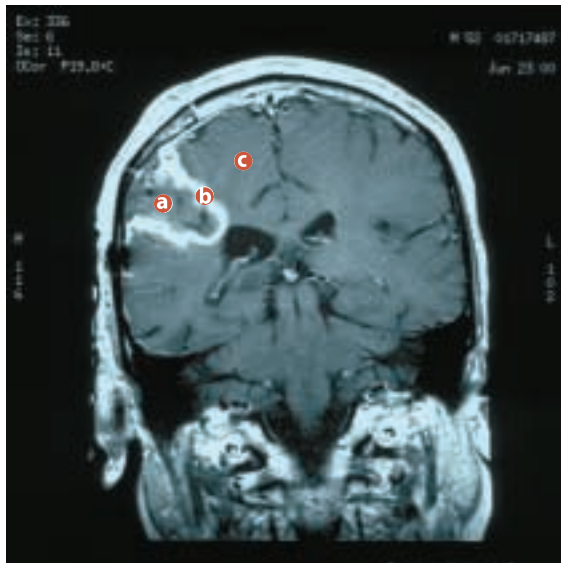
The CT scan uses an X-ray beam that is attenuated as it passes through the body. The different densities of organs create the various shades of gray that are recorded on an X-ray film. Blood vessels filled with the contrast medium are more dense and enhance the image. Although there is a relatively mild risk associated with the use of the contrast medium, the benefits clearly outweigh the risks in almost every situation (Figure 1).

- Ⓐ tumor mass (not radically different in appearance from normal brain tissue)
- Ⓑ mass has collapsed the ventricle
- Ⓒ active peripheral boundary of the tumor
- Ⓓ area ahead of the tumor is actively developing a new blood supply

### Magnetic resonance imaging

Magnetic resonance imaging (MRI) is another noninvasive diagnostic procedure that uses magnets and radiowaves to produce a picture. Like the CT scan, the MRI produces images that are slices of a specific part of the body. Print-outs of the series of coronal and transverse images (Figures 2 and 3) allow the physician to evaluate the three-dimensional structures under consideration.

In comparison to the CT scan, the MRI images are more detailed and provide more overall information. This is particularly true when scanning soft tissues such as the brain. Perhaps the primary difference between the CT scan



**FIGURE 2**

Illustrative case,  
postoperative and  
postradiation MRI  
(coronal cut)

- Ⓐ postoperative cavity containing cellular debris
- Ⓑ enhanced area at remaining tumor border
- Ⓒ brain swelling (note effect on ventricle)

and the MRI is that the former produces images by exposing the body to X-rays. The latter creates a strong magnetic field that causes the atoms within the body to align. A radiowave is then directed at the body to trigger the atoms to respond with radiowaves of their own. These radiowaves create a signal that is detected by the scanner from thousands of different angles around the body. The radio signals are sent to a computer that processes the information and compiles it into a three-dimensional image. These images may be stored on photographic film or videotape.

The risks with MRI are minimal since ionizing radiation is not used. The magnets, however,

are very strong, so precautions must be taken to ensure that metallic objects do not exist inside the patient and that these objects are not carried into the area.

The CT scan is much faster than an MRI; therefore, the CT scan is preferred for emergency use. Large medical centers with a high volume of trauma may have a CT scan unit in their emergency room. Because of the potential problems associated with the strong magnets, the MRI scanner is usually placed in a highly restricted area of the radiology department.

### Illustrative case—diagnostic notes

With the illustrative case patient, doctors first pursued the most likely diagnosis, a neuropathy of the ulnar nerve. (Remember, the patient had no history of headaches or seizures.) By the time the EMG had ruled out a peripheral neuropathy, the patient's condition had rapidly deteriorated making it clear that the problem was centralized. This left two likely possibilities, transient ischemic attack (TIA) or intracranial mass. TIAs were essentially ruled out by history. Symptoms had worsened progressively, not episodically. The CT scan confirmed the mass lesion.

### Astrocytomas

#### Histological distinctions

CT and MRI scans will demonstrate the presence of a mass lesion in an overwhelming majority of the cases, and, as is to be expected, will provide considerable insight into the tumor type. The final diagnostic classification, however, must be made on the histologic nature of the tumor.

Tumors of the astrocytoma classification can be placed in one of three subcategories based on the cell of origin:

- *Fibrillary astrocytoma*—stellate astrocytes are commonly found in the white matter of the brain and spinal cord. These cells are characterized by the presence of long processes and bundles of glial filaments in its cytoplasm. Most astrocytomas originate from these cells.

- *Protoplasmic astrocytoma*—protoplasmic astrocytes are mostly found in gray matter and contain few fibrils but numerous branching processes.
- *Gemistocytic astrocytoma*—gemistocytic astrocytes are round or oval cells containing abundant cytoplasm, glial filaments and an eccentric nucleus (9-19% of astrocytomas).<sup>21</sup> These tumors are often mixed, but greater than 60% of the cells must be gemistocytes to qualify for this designation. More importantly, an astrocytoma with more than 20% gemistocytes generally has a worse prognosis—as many as 80% develop into glioblastomas.<sup>21</sup> Gemistocytic astrocytoma is, in effect, an anaplastic astrocytoma. This factor is sometimes expressed clinically with a comment like: “Grade 3 astrocytomas are always hurrying to become Grade 4 astrocytomas.”

#### ***Anaplastic astrocytoma***

Anaplastic astrocytomas may occur as part of the anaplastic progression of a glioma or as their own entity. There is some thought that the number of these de novo anaplastic astrocytomas will decline as our diagnostic imaging abilities increase. The anaplastic astrocytoma differs from the low-grade astrocytoma in the following ways:

- Cellular differentiation
- Increased cellularity
- Increased mitotic activity
- Increased cellular atypia.<sup>21</sup>

#### ***Glioblastoma multiforme***

Glioblastomas represent about 20% of all primary brain tumors and half of the astrocytoma type. Most glioblastomas develop in astrocytomas and anaplastic astrocytomas. Some develop as multi-lobar or bilateral tumors, or even multicentric tumors. Some glioblastomas appear to develop de novo. These tumors exhibit precisely the kind of histologic structures one would expect from a tumor so malignant:

## Related Terms

### **Blood-brain barrier (BBB)**

Certain characteristics of brain capillaries create a barrier that prevents potentially harmful substances from entering brain, while allowing oxygen and nutrients access to the tissues. These capillaries can also limit or prevent potentially beneficial medications from crossing the barrier.

### **Greenfield® filter**

A multistrutted, spring-style filter designed to protect against pulmonary embolism. The permanent filter is percutaneously implanted in the vena cava.

### **Prednisone (corticosteroid)**

Hydrocortisone and cortisone occur naturally as glucocorticoids and are essential. The synthetic analogs are used to treat many conditions because they have strong anti-inflammatory effects. Prednisone is usually given orally or by injection. (Other corticosteroids will play an important role in treatment once the mass lesion is identified.)

### **Peripheral neuropathy**

A disease or syndrome characterized by muscle weakness, paresthesia, impaired reflexes, and autonomic symptoms in the hands and feet.

### **Tinel's sign**

A sensation of tingling sometimes identified by the patient as “pins and needles,” that is felt in the distal portion of a limb when percussion is made over the site of an injured nerve. The tingling should occur in the normal area innervated by the nerve in question and should reproduce previous symptoms. A positive sign may confirm a lesion during the diagnostic phase or early regeneration in the nerve later on.

### **Transient ischemic attack (TIA)**

A sudden focal loss of neurological function with complete recovery usually within 24 hours. TIAs are caused by a brief period of inadequate blood flow in a section of the carotid or vertebral basilar arteries.

- Demonstrates the extreme of cytologic pleomorphism
- Demonstrates the extreme of nuclear pleomorphism
- High cellularity
- Obvious mitosis
- Necrosis
- Marked endothelial proliferation
- Diffuse invasion of surrounding tissue.

The last four malignant features help explain typical features of a glioblastoma as seen on a CT or MRI scan. Endothelial proliferation is related to angiogenesis. The tumor is working to create its needed blood supply. This area of hypercellu-

acterized by giant cells that are highly varied in cytoarchitecture and often multinucleated. The gliosarcoma is apparently induced by the vascular stroma and may develop into a tumor that demonstrates more sarcomatous characteristics.

### Treatment

Treatment strategy for glioblastoma has varied with the amount of information known about the tumor and with the treatment options available. Both pharmacological and technological advances have expanded the treatment options and the possibility of prolonged life with some acceptable quality of life. The basis for all the treatment schemes is relatively standard:

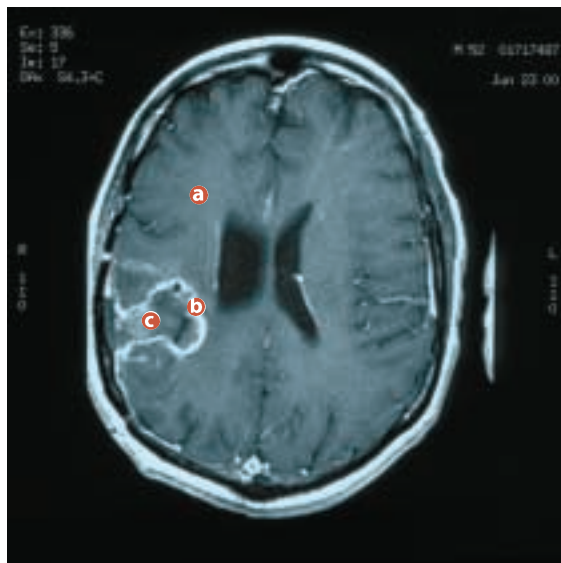
1. Tumor reduction
2. Radiation therapy
3. Chemotherapy
4. Continued monitoring
5. Treatment of other concerns
6. Adjustment of plan as necessary
7. Physical and occupational therapy

### Treatment regimens

A number of therapeutic and chemotherapeutic regimens are used around the world. At this time, at least 64 chemotherapy clinical trials are in progress, not to mention 100 studies focused on treatment schemes—a considerable amount of research on the glioblastoma. Obviously, no singular solution or standard treatment is available and may not be for some time, if ever. Most of the current trials are focused on the use of various combinations of chemotherapeutic agents. To date, reports seem to indicate that the use of several chemotherapeutic agents is more effective than a single-agent approach.

### Other treatment issues

Numerous other concerns are related to treatment of the glioblastoma. Two of these are obvious: the quality of the surgical resection and the complex drug interactions that occur secondary to the variety of medications required during treatment. Because of the tumor's frequent position, hemiparesis is not an unusual event related



**FIGURE 3**

Illustrative case,  
postoperative and  
postradiation MRI  
(transverse cut)

- Ⓐ brain swelling
- Ⓑ enhanced tumor border
- Ⓒ postoperative cavity containing cellular debris

larity causes the leading portions of the tumor to “light up” with the use of a contrast medium. While the tumor is working to produce an adequate blood supply, it often cannot supply the cells closer to the malignant cell of origin. These cells die producing an area of necrotic tissue that shows up on a scan as a darker area inside the tumor. Finally, an area around the tumor appears to be of decreased density and has been correlated to the area of cellular invasion into new tissue.

### Glioblastoma subtypes

Two subtypes of glioblastoma are the giant cell glioblastoma and gliosarcoma. The first is char-

to glioblastoma. This requires physical and occupational therapy, at least, and may require psychological counseling also.

Glioblastomas also have been correlated to a higher-than-usual incidence of blood clot formation and embolism. Anticoagulants are required and must be carefully monitored. A Greenfield filter may be placed if clots form. The brain is generally edematous and subject to both pre- and postoperative swelling. Corticosteroids may be used for a significant period to combat this problem.

Many medications are used during the therapeutic effort. Constant vigilance is required to monitor white blood cell count, platelets, and the international normalized ratio (INR). A change in one medication may cause a change in the effectiveness of all the others. These are monitored weekly.

### **Surgical intervention**

Tumor reduction, especially in small, low-grade tumors may be accomplished by radiation therapy, but reduction of the typical high-grade GBM is generally accomplished by a surgical procedure. Since many of these tumors are found in the frontoparietal area and may be large, reduction is accomplished via craniotomy. Technological advances, such as frameless stereotactic imaging and electrophysiologic measurement of action potentials (intraoperative mapping), have permitted the surgeon to remove more of the tumor while providing some safety to the patient. The primary purpose of tumor reduction is to dramatically reduce the number of tumor cells that need to be killed by radiation or chemotherapy. The amount that the tumor is reduced correlates strongly to the length of survival.

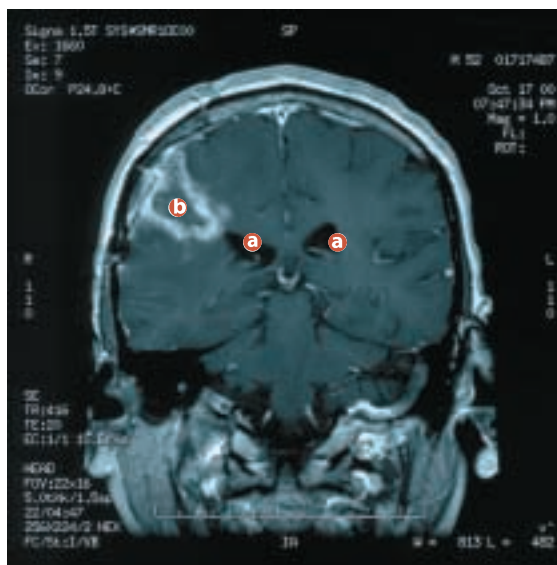### **Radiation therapy**

External beam therapy directs ionizing radiation from a machine to the tumor cells. The total dosage required is calculated using type, grade, and stage information. A fractionated approach is used for delivery (ie a fraction of the total dose is given each session). Typically, four to five radi-

ation sessions are given per week. Dose-time intervals are calculated and the precise angle of the beam is calculated from MRI data.

The affect of radiation on cells is very complex, but the critical factor is the radiation's ability to damage the nuclear DNA in the tumor cells while sparing normal cells. This inhibits reproduction and leads to apoptosis. Either X-rays or gamma rays may be used.

Initially, the patient goes through a simulation procedure where a firm but mesh-like mask is created. Alignment markings are placed on the mask. The mask attaches to the table, guaranteeing that the patient is properly positioned each time.



**FIGURE 4**

Illustrative case, postoperative, postradiation, and post chemotherapy (BCNU) MRI (coronal cut)

- Ⓐ decreased brain swelling; ventricles about the same size
- Ⓑ postoperative site shows no tumor regrowth

Radiation therapy may produce a number of side effects, but these are minimal in most brain tumor cases and probably related to the relatively small area being irradiated.

### **Select medications and chemotherapy agents**

Table 1 provides basic information about a select number of medications and chemotherapy agents. The illustrative case will be used to demonstrate one scheme for the use of these agents.

### **Illustrative case—treatment**

The patient and family met with the neurological oncology team prior to surgery. The team



included a neurosurgeon, neurooncologist, neuropsychologist, director of rehabilitation, and a social worker. The patient, with full understanding of the potential complications, asked the neurosurgeon and neurooncologist to take an aggressive approach. The patient decided to participate in two studies being conducted by the faculty of the medical school. One study concerned the use of the light-activated substance Photofrin. The other was evaluating the use of Irinotecan in combination with other agents.

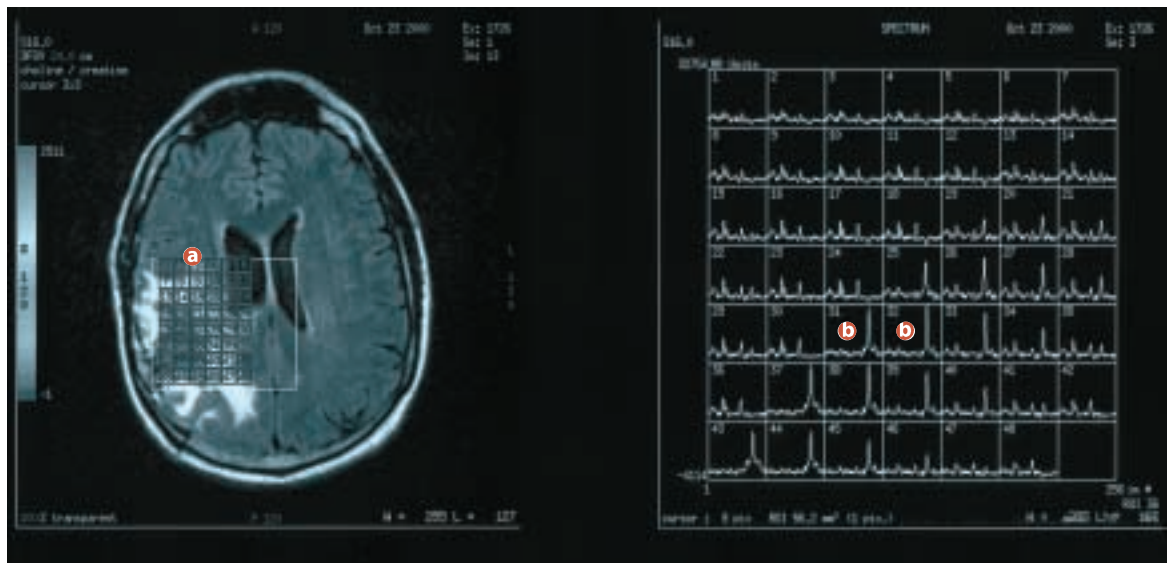The patient began receiving dexamethasone following the diagnosis of an intracranial mass. Prior to surgery, an MRI with enhancement was performed. Approximately 24 hours prior to

six weeks. A blood clot formed in the left thigh. Medications were adjusted and a Greenfield filter was placed in the vena cava.

### Treatment overview

An overview of treatment is as follows:

- Fractional radiation therapy was started as soon as the patient's condition allowed and continued on an outpatient basis for a total of 34 treatments.
- The first of the chemotherapeutic infusions was done during the last week the patient was in the rehabilitation unit. Chemotherapy cycles were scheduled at four-week intervals.



**FIGURE 5**

Illustrative case,  
36 week  
postoperative MR  
spectroscopy

- Ⓐ computerized grid over area of study
- Ⓑ high spikes in 31-32 indicate active tumor cells

surgery, the patient received an infusion of Photofrin. A right frontoparietal craniotomy was performed, and the tumor was debulked. Because of the relationship between the tumor and the motor strip, a frameless stereotatic technique and electrophysiologic intraoperative mapping were used to assist the surgeon.

Following surgery, the patient was hemiparetic on the left side. He was admitted to the neuro intensive care unit, remained for three days before being transferred to the neuro-ortho unit, and moved to the acute rehabilitation unit four days later. Physical and occupational therapy, plus radiation and chemotherapy were initiated prior to dismissal. Total hospitalization time was

- Chemotherapy followed this pattern:
  1. Three cycles of Irinotecan infusion and oral Temodar
  2. Five cycles of Carmustine and Irinotecan infusion with oral Temodar
  3. Five cycles of Irinotecan infusion and oral Temodar
  4. Oral Tamoxifen, taken daily, was added after the first two cycles of Irinotecan.

Tamoxifen is a biologic agent that does not kill tumor cells directly, but slows cell growth with the intent of inducing apoptosis. It is not as toxic as chemotherapy agents and can be taken for a long period of time.

Total chemotherapy time, not including the biologic agent Tamoxifen, covered approximately one year from the date of surgery. Following the completion of radiation and at spaced intervals during chemotherapy, follow-up MRIs were done to monitor the progress of therapy or identify the recurrence of the tumor (Figure 4). MRI evaluations were performed at 24 and 36 weeks.

A new test, the magnetic resonance spectroscopy (Figure 5) uses the MRI machine to establish a grid for a chemical activity survey. Performed at 36 weeks, this imaging technique detects the presence of select chemicals related to tumor-cell activity in the patient. To date, the findings have not been confidently correlated with the clinical situation. Extremes are meaningful. For instance, a lack or significant decrease in these chemicals is clearly good news; a marked increase or return of activity points in the other direction. Most results are less clear. For instance, researchers do not know how long after cell death the chemicals remain and can be measured. Nevertheless, this test represents another step forward and offers a positive area of development.

### Treatment schemes and prognosis

With all the advances and success in the treatment of cancer, why do outcomes for the glioblastoma seem to lag behind? My own experience gained while working with a neurosurgical group and patients suffering from glioblastoma, plus a review of scholarly and clinical literature and personal discussions with two neurosurgeons, a neurooncologist and a neuro-radiologist lead me to the following conclusions:

Biological factors contribute to the slow advance.

- GBMs have developed an unusual ability to resist mechanisms, such as a proptosis, that would ordinarily cause the cells to die.
- The blood brain barrier remains a significant problem in neurooncology.
- The tumors are usually quite large before being diagnosed.

Non-biological factors may be equally or more important.

- These tumors affect a relatively small portion of the population.
- Until recently, the treatment scheme of surgery, radiation, and chemotherapy caused such severe side effects that patients tended to surrender early in therapy.
- Until recently physicians and neurosurgeons typically saw patient after patient deteriorate and die in spite of their best efforts, leading to a palliative versus curative approach.

These factors created an environment in which a truly aggressive approach to GBMs was seldom taken. The highly malignant GBM followed its deadly course, reinforcing the generally perceived hopelessness. Treatment outcomes, then, became a self-fulfilling prophecy. Some of the most significant advances in treatment today have been made in radiation therapy and chemotherapy. Neither treatment mode tends to overwhelm the patient. This allows the patient's body to respond, and patient and oncologist to select an aggressive approach to the GBM.

### Hope for the future

The battle against the glioblastoma multiforme is not only continuing, but in many ways, it has just begun. Hope for the future resides with the following:

- Biological knowledge and deepening understanding of tumor biology
- Technological advances in the area of diagnostics and therapy
- Pharmacologic advances
- A better understanding of the psychology and spirituality of survival.

One illustrative example of hope is the workup being done by JG Cairncross on the oligodendroglioma. These researchers have identified certain biochemicals that allow them to predict the response of a given tumor to chemotherapy and

	Agent	Admin	Action	Complications	Notes
Neurologic & other agents	<b>Phenytoin (Dilantin)</b>	Oral, IM, IV	An antiepileptic drug	CNS toxicity	IM & IV administration must be slow. Blood levels checked routinely.
	<b>Decadron</b>	Oral or IV	Used to decrease brain swelling secondary to tumor disruption of the blood brain barrier and fluid leakage into the surrounding tissue. The common and sought after response includes: a reduction in symptoms, a sense of well being, and improvement in neurologic status.	1-8	Corticosteroids can not be stopped quickly. A long monitored period of dose reduction is required.
	<b>Lorazepam</b>	Oral, IM, IV	Antianxiety agent used to stop or prevent seizures.	Large number of side effects possible. Critical—bronchospasm.	Beware of drug interactions. Patients may need extra help walking for a while.
	<b>Warfarin sodium</b>	Oral	Anticoagulant that interferes with vitamin K dependent clotting factors II, VII, IX, and X.	Hemorrhage	Glomas correlate to a higher incidence of blood clot formation than other brain tumors. Blood levels monitored. (Heparin may be used initially.)

Preparatory agents	<b>Kytril</b>	Oral or IV	Antiemetic and antvertigo medication used to prevent these complications secondary to chemotherapy.	4, 17	Kytril administration should be completed prior to initiating chemotherapy.
	<b>Atropine sulfate</b>	IV	Potent parasympatholytic that blocks acetylcholine action at postganglionic sites. Small doses inhibit salivary and bronchial secretions. Used as part of the chemotherapy preinfusion routine.	1, 2, 17, 21, 22	Inform patient to expect a very dry mouth.

Select chemotherapy agents (used in illustrative case)	<b>Carmustine (BCNU)</b>	IV	Chemotherapeutic agent	1, 2, 3, 14, 17	May be given alone or in combination with other chemotherapeutic agents.
	<b>Irinotecan (CPT-11)</b>	IV	Antineoplastic agent that interferes with DNA's ability to uncoil.	1, 2, 3, 25, 26, 27	May be given alone or in combination with other chemotherapeutic agents.
	<b>Tamoxifen citrate</b>	Oral	A nonsteroidal antiestrogen developed as an antineoplastic for breast cancer. Thought to affect nuclear DNA leading to apoptosis in brain tumors.	1, 2, 3, 4—Generally mild but can increase bone pain and tissue swelling in rare instances.	Originally developed for breast cancer.
	<b>Temozolomide</b>	Oral	Only oral chemotherapeutic agent demonstrated to cross the blood brain barrier. It affects tumor cell growth directly. Does not require metabolic activation.	1, 2, 19, 26	
	<b>Photofrin</b>	IV	Chemotherapeutic agent that is activated during surgery (Photo Dynamic Therapy).	27, 28	Infused 24 hours prior to surgery. Should be cleared from most healthy tissue in 12 hours, but remains in tumor cells.

**Complications:** 1 nausea, 2 vomiting, 3 diarrhea, 4 constipation, 5 stomach irritation, 6 neutropenia, 7 anemia, 8 thrombocytopenia, 9 increased appetite, 10 puffy moon shaped face, 11 mood swings, 12 depression, 13 CNS symptoms, 14 pulmonary complications, 15 renal complications, 16 liver complications, 17 headache, 18 lethargy, 19 skin rashes, 20 elevated liver enzymes, 21 tachycardia, 22 bradycardia, 23 dysrhythmias, 24 dizziness, 25 flushed, hot, dry skin, 26 allergic reactions, 27 birth defect in exposed fetus, 28 myelosuppression, 29 hyperglycemia, 30 water retention causing extreme weight gain

radiation therapy. If this is true for one glioma, one must suspect that it is true for all. Secondly, advances in the technique and clinical application should one day allow for the matching of a chemotherapeutic agent to a given tumor. The battle against the glioma multiforme is far from over, but it continues with high expectations.

### About the author

Bob Caruthers received both his bachelor's and doctoral degrees from the University of Texas at Austin. His interest in neurology has persisted since his first scrub on a craniotomy in 1970. Caruthers has published several articles in *The Surgical Technologist Journal*.

### References

1. Adelman LS (1994). Grading astrocytomas. *Neurosurgical clinics of North America*, 5:1. *Neurosurgery*, 17(3):231-51.
2. Bernstein M, Rutka J. Brain tumor protocols in North America. *Journal of Neurooncology*. 17(3):231-51.
3. Bruner JM (1994). Neuropathology of malignant gliomas. *Semin Oncol*, 21:2.
4. Burger PC (1983). Pathologic anatomy and CT correlations in the glioblastoma multiforme. *Applied Neurophysiology*, 46 (1-4) 180-7.
5. Cukier D, McCullough (current). *The basics of radiation therapy*. [www.health.excite.com](http://www.health.excite.com)
6. Eyre HJ, Eltringham, Gehan EA, Vogel FS, Al-Sarraf M, Talley RW, Costanzi JJ, Athens JW, Oishi N, Fletcher WS (1986). Randomized comparisons of radiotherapy and carmustine versus decarbazine for the treatment of malignant gliomas following surgery: a southwest oncology group study. *Cancer Treatment Reports*, 70(9):1085-90.
7. Fulling KH, Garcia DM (1985). Anaplastic astrocytoma of the adult cerebrum. Prognostic value of histologic features. *Cancer*, 55:5.
8. Greenberg HS, Chandler WF, Sandler HM (1999). *Brain Tumors*. New York: Oxford University Press.
9. Janny P, Cure H, Mohr M, Heldt N, Kwiakowski F, Lemaire JJ, Plagne R, Rozan R (1994). Low grade supratentorial astrocytomas. Management and prognostic factors. *Cancer*, 73 (7):1937-45.
10. Jory VV. CPT-11 (Camptosar®, Irinotecan) Review. On-line paper, [www.virtualtrials.com/cpt11](http://www.virtualtrials.com/cpt11)
11. Kessel D (1998). Photodynamic Therapy. *Science & Medicine*, 11/Aug, 46-55.
12. Kim TS, Halliday AL, Hedley-Whyte ET, Convery K (1991). Correlates of survival and the Daumas-Duport grading system for astrocytomas. *Journal of Neurosurgery*, 74:1.
13. Kleihunes P, Burger PC, and Scheithauer (1994). *Histological typing of tumors of the central nervous system*, ed.2. World Health Organization, Geneva.
14. McLaren BR, Robinson BW, Lake RA (2000). New chemotherapeutics in mesothelioma: effects on cell growth and IL-6 production. *Cancer Chemotherapy Pharmacology*, 45 (6):502-8.
15. Mahaley MS Jr, Mettlin C, Natarajan N, Laws ER Jr, Peace BB (1989). National survey of patterns of care for brain tumor patients. *Journal of Neurosurgery*, 71 (6):826-36
16. Muller PJ, Wilson BC (1995). Photodynamic therapy for recurrent supra tentorial gliomas. *Seminars in Surgical Oncology*, 11: 346-54.
17. Malkin MG (2000). New medical therapies for malignant brain tumors. The Brain Tumor Society, [www.tbts.org/newmed](http://www.tbts.org/newmed)
18. Methodist health care system (current). External beam therapy [www.methodisthealth.com/radiology](http://www.methodisthealth.com/radiology)
19. Tatter S Lab (current). The new WHO classification of tumors affecting the central nervous system [www.neurosurgery.mgh.harvard.edu](http://www.neurosurgery.mgh.harvard.edu)
20. VandenBerg SR (1992). Current diagnostic concepts of astrocytic tumors. *Journal of Neuropathology and Experimental Neurology*, 51(6) 644-57.

# High grade astrocytoma in the adult

## Part 2

### Earn CE credit at home

You will be awarded one continuing education (CE) credit for recertification after reading the designated article and completing the exam with a score of 70% or better.

If you are a current AST member and are certified, credit earned through completion of the CE exam will automatically be recorded in your file—you do not have to submit a CE reporting form. A printout of all the CE credits you have earned, including Journal CE credits, will be mailed to you in the first quarter following the end of the calendar year. You may check the status of your CE record with AST at any time.

If you are not an AST member or not certified, you will be notified by mail when *Journal* credits are submitted, but your credits will not be recorded in AST's files.

Detach or photocopy the answer block, include your check or money order made payable to AST and send it to the Accounting Department, AST, 6 West Dry Creek Circle, Suite 200, Littleton, CO 80120-8031.

**Members: \$6 per CE, nonmembers: \$10 per CE**

- Why do individuals with a tumor in the second grouping have a better prognosis?**
  - The tumor has a less aggressive capacity for invading surrounding tissue
  - The tumor has a limited growth rate
  - The tumor has limited anaplastic progression
  - All of the above
- Why are tumors in the second grouping less aggressive than tumors in the first grouping?**
  - They are microscopically circumscribed neoplasms
  - They are adept at infiltrating surrounding tissue
  - Both A & B
  - None of the above
- Which of the following risk factors apply to glioblastoma in the adult?**
  - Race (Caucasian)
  - Gender (Male)
  - Age (50s and 60s)
  - All of the above
- Meningiomas**
  - Rapidly invade brain tissue
  - Do not invade brain tissue
  - Rapidly invade the spinal cord
  - Rapidly invade the pituitary
- Tinel's sign is defined as**
  - Ringling in the ears
  - Dizziness
  - A sensation of tingling
  - Nausea
- A nerve conduction study is also called a/an**
  - EMG
  - CT Scan
  - MRI
  - Craniotomy
- What is contrast medium?**
  - A means of maintaining clinical specimens for laboratory examination
  - Transparent tissues that allow light rays to refract
  - Radiopaque substance used to enhance visualization of internal body structures
  - None of the above
- What is the most common method of administration for a contrast agent?**
  - Oral
  - Rectal
  - Inhalation
  - Intravenous
- Which of the following is an advantage of CT scan over MRI?**
  - CT is faster than MRI
  - CT uses ionizing radiation; MRI does not
  - The strong magnet the CT scanner is usually located in the radiology department
  - CT uses radio waves; MRI does not
- Glioblastomas represent approximately \_\_\_\_\_ of all primary brain tumors.**
  - 5%
  - 10%
  - 20%
  - 42%

## High grade astrocytoma in the adult *Part 2*

		1	2	3	4	5	6	7	8	9	10		
		a	b	c	d	a	b	c	d	a	b	c	d
<input type="checkbox"/> Certified Member	<input type="checkbox"/> Certified Nonmember	<input type="checkbox"/>	<input type="checkbox"/>	<input type="checkbox"/>	<input type="checkbox"/>	<input type="checkbox"/>	<input type="checkbox"/>	<input type="checkbox"/>	<input type="checkbox"/>	<input type="checkbox"/>	<input type="checkbox"/>	<input type="checkbox"/>	<input type="checkbox"/>
Certification No _____		<input type="checkbox"/>	<input type="checkbox"/>	<input type="checkbox"/>	<input type="checkbox"/>	<input type="checkbox"/>	<input type="checkbox"/>	<input type="checkbox"/>	<input type="checkbox"/>	<input type="checkbox"/>	<input type="checkbox"/>	<input type="checkbox"/>	<input type="checkbox"/>
Name _____		<input type="checkbox"/>	<input type="checkbox"/>	<input type="checkbox"/>	<input type="checkbox"/>	<input type="checkbox"/>	<input type="checkbox"/>	<input type="checkbox"/>	<input type="checkbox"/>	<input type="checkbox"/>	<input type="checkbox"/>	<input type="checkbox"/>	<input type="checkbox"/>
Address _____		<input type="checkbox"/>	<input type="checkbox"/>	<input type="checkbox"/>	<input type="checkbox"/>	<input type="checkbox"/>	<input type="checkbox"/>	<input type="checkbox"/>	<input type="checkbox"/>	<input type="checkbox"/>	<input type="checkbox"/>	<input type="checkbox"/>	<input type="checkbox"/>
City _____ State _____ ZIP _____		<input type="checkbox"/>	<input type="checkbox"/>	<input type="checkbox"/>	<input type="checkbox"/>	<input type="checkbox"/>	<input type="checkbox"/>	<input type="checkbox"/>	<input type="checkbox"/>	<input type="checkbox"/>	<input type="checkbox"/>	<input type="checkbox"/>	<input type="checkbox"/>
Telephone _____		<input type="checkbox"/>	<input type="checkbox"/>	<input type="checkbox"/>	<input type="checkbox"/>	<input type="checkbox"/>	<input type="checkbox"/>	<input type="checkbox"/>	<input type="checkbox"/>	<input type="checkbox"/>	<input type="checkbox"/>	<input type="checkbox"/>	<input type="checkbox"/>

Mark one box next to each number. Only one correct or best answer can be selected for each question.