

paraesophageal



hiatal hernia

Leslie K Browder, MD, and Alex G Little, MD

DESCRIPTION AND IDENTIFICATION

HIATAL HERNIAS MAY BE CLASSIFIED AS FOUR TYPES. THE MOST COMMON, TYPE I, MAY PRESENT AS GASTROESOPHAGEAL REFLUX DISEASE (GERD), AND MAY BE TREATED FOR A TIME AS SUCH. TYPES II, III AND IV, WHEN SYMPTOMATIC, ARE MORE SERIOUS CONDITIONS REQUIRING SURGICAL TREATMENT OF THE HERNIA.

THIS ARTICLE IS THE FIRST IN A TWO-PART SERIES ABOUT THESE SOMEWHAT SIMILAR CONDITIONS. PART I WILL COVER THE FOUR CLASSIFICATIONS OF PARAESOPHAGEAL HIATAL HERNIA AND THE SYMPTOMS AND TREATMENTS FOR EACH. NEXT MONTH'S ARTICLE WILL COVER THE CONDITION OF GERD AND LAPAROSCOPIC TREATMENT OF ANTIREFLUX DISEASE.

Anatomy

The esophagus starts at the termination of the pharynx, travels through the thorax and ends in the abdominal cavity. The esophagus is approximately 25 cm in length in an adult. The esophagus passes into the abdomen through the esophageal hiatus, which is formed by the muscle fibers of the right crus of the aortic hiatus of the diaphragm, with little contribution from the left crus. The phrenoesophageal ligament anchors the gastroesophageal junction in its normal intraabdominal location. Distortion of the natural anatomy results in a hernia. Herniation of abdominal contents into the mediastinum through the esophageal hiatus is termed a hiatal hernia. There are four classifications of this hernia based on anatomical criteria.

Classification

In the common sliding hiatal hernia (Type I), the gastroesophageal (GE) junction migrates above the diaphragm into the thorax, but the esophagus and stomach maintain their normal anatomic relationship (Figure 1). Increased abdominal pressure secondary to pregnancy, obesity, or vomiting may contribute to sliding hiatal hernia occurrence by inducing laxity of the phrenoesophageal ligament.

Type II, or true paraesophageal hernias, are uncommon. The stomach herniates into the thorax but the gastroesophageal junction remains at or below the diaphragm (Figure 2). The phrenoesophageal membrane is weakened anteriorly and laterally to the esophagus. The posterior phrenoesophageal ligamentous anchorage is preserved, thus holding the GE junction in its anatomical position. These hernias are characterized by a peritoneal lined opening in the esophageal hiatus, anterior to the normal GE junction.

In Type III hernias, some or all of the stomach protrudes into the mediastinum. In addition, there is cephalad migration of the gastroesophageal junction (Figure 3). This may be a result of an enlarging Type I hernia, causing a weakened phrenoesophageal membrane which allows the stomach to protrude into the thorax.

It may also occur when a Type II hernia converts to a Type III. These are also paraesophageal hernias as the stomach is alongside the esophagus.

Progressive enlargement of the diaphragmatic hiatus can eventually allow herniation of additional organs into the thorax. In these Type IV hernias, the colon, omentum, spleen and small bowel may herniate into the thorax anterior to the stationary GE junction.

Symptoms

The common Type I hernia, or sliding hiatal hernia, can be associated with incompetence of the lower esophageal sphincter (LES), thus creating symptoms of gastroesophageal reflux disease (GERD). Therefore, patients may complain of chest pain, acid taste, regurgitation, or epigastric discomfort. More often, patients with a Type I hiatal hernia are asymptomatic.

Many Type II hernias remain asymptomatic and are incidentally found on routine chest radiographs. There are usually no complaints of GERD because the LES remains at its normal anatomical position. If symptoms are present, they may include postprandial discomfort, dysphagia, anemia or bleeding. The intrathoracic portion of the stomach is subject to irritation, gastritis, and ulceration, secondary to acid stasis within the hernia, which can cause bleeding.¹

When hernias enlarge to form Type III and Type IV defects, the most common symptoms are the same as for Type II hernias. Postprandial respiratory symptoms, secondary to a large portion of the thoracic cavity being occupied by abdominal contents, may also be present. There is also a higher risk of gastric volvulus or obstruction in the Type III and IV hernias. Patients often present with significant pain in the chest or epigastric region, commonly accompanied by a sense of bloating, nausea, and vomiting. The pain may be severe enough that patients may be misdiagnosed as having a myocardial event. If allowed, the volvulus may progress into strangulation, causing a toxic clinical picture which includes fever and hypovolemic shock. Large Type III and IV hernias may present as a

surgical emergency, although the frequency of these catastrophic complications is quite low.

Overall, Type I hernias account for the majority of hiatal hernias, whereas Type II, III, and IV are more rare.

Diagnosis

The diagnosis of a Type I hernia is often made by investigating the symptoms of GERD. An upper gastrointestinal barium study may show the stomach above the diaphragm or the LES residing in the thorax. An esophagogastroduodenoscopy (EGD) can confirm the defect and esophageal motility studies typically reveal a hypotensive LES.

determine if significant gastroesophageal reflux or pathologic esophagitis is present, and may also be of assistance in guiding treatment modalities.

Treatment

If symptomatic, the reflux associated with Type I hernias is initially treated medically with pH altering medications, postural, and dietetic therapy. Changing the pH of the regurgitate does not protect the mucosa from repeated injury, thus monitoring medical therapy is necessary. Persistent or recurrent symptoms and/or complications of GERD, such as esophagitis or stricture, despite intensive acid suppression therapy, are

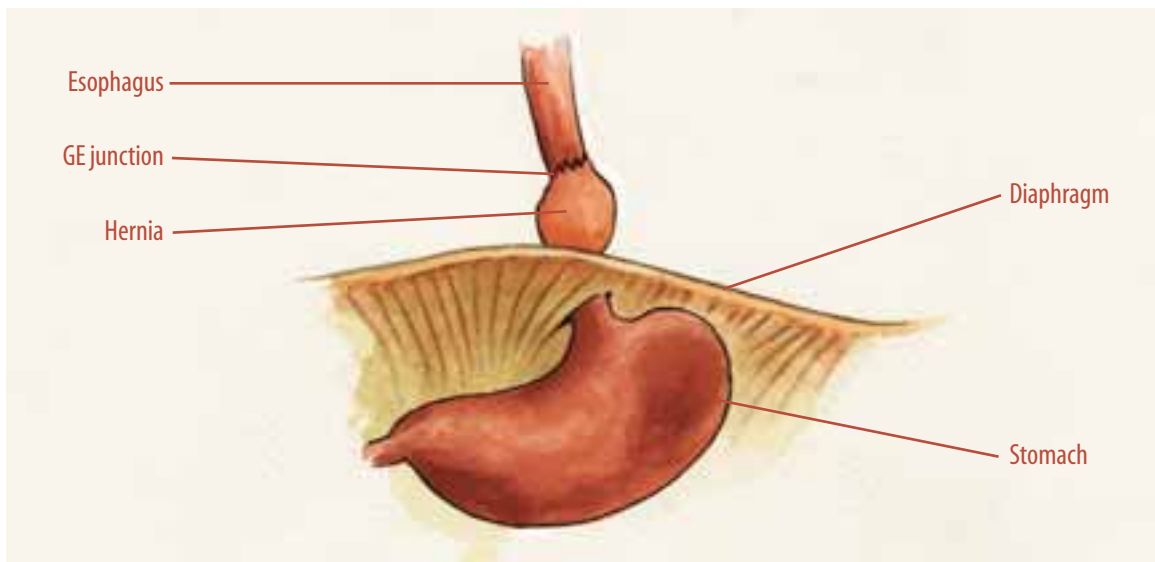


FIGURE 1

Type I hiatal hernia—the gastroesophageal (GE) junction resides above the diaphragm through a defect in the esophageal hiatus.

Paraesophageal hernias are often suspected because of abnormal findings on a routine chest radiograph in an asymptomatic patient. Most commonly, an air bubble with or without an air-fluid level is found in the thorax. In Type III or IV hernias, abdominal contents may protrude into the right chest. The diagnostic study of choice is an upper gastrointestinal barium study, which shows the stomach residing in the chest. A barium enema may be helpful in determining if a portion of the colon is involved. After a paraesophageal hernia is diagnosed, endoscopy and esophageal function testing (EFT) may be required to evaluate the competency of the LES. These investigations may help

indications for surgical intervention. Antireflux surgeries vary and are individualized to each patient. They include Belsey Mark IV fundoplication, the Nissen fundoplication, and the Collis gastroplasty.

There is no appropriate medical treatment of paraesophageal hernias (Type II, III, IV). The indications for surgical repair are the presence of the symptoms noted above. The issue of whether asymptomatic patients require operative intervention is controversial because the likelihood of incarceration and/or strangulation is low but catastrophic. Symptoms, including blood loss, are considered evidence that occasional incarceration is occurring and, therefore, operative

repair is indicated.² Patients presenting with volvulus and/or obstruction should have a nasogastric (NG) tube placed. If the NG tube effectively decompresses the stomach, surgery can be scheduled at the earliest convenience. If decompression is not possible, emergent surgery should follow.

Surgical repair can either be undertaken via the abdomen or the thorax, with either an open or laparoscopic approach. In most circumstances, an intraabdominal approach is used to repair paraesophageal hernias. Thoracotomy is typically reserved for hernias with accompanying esophageal shortening, which require lengthening procedures. In addition, laparo-

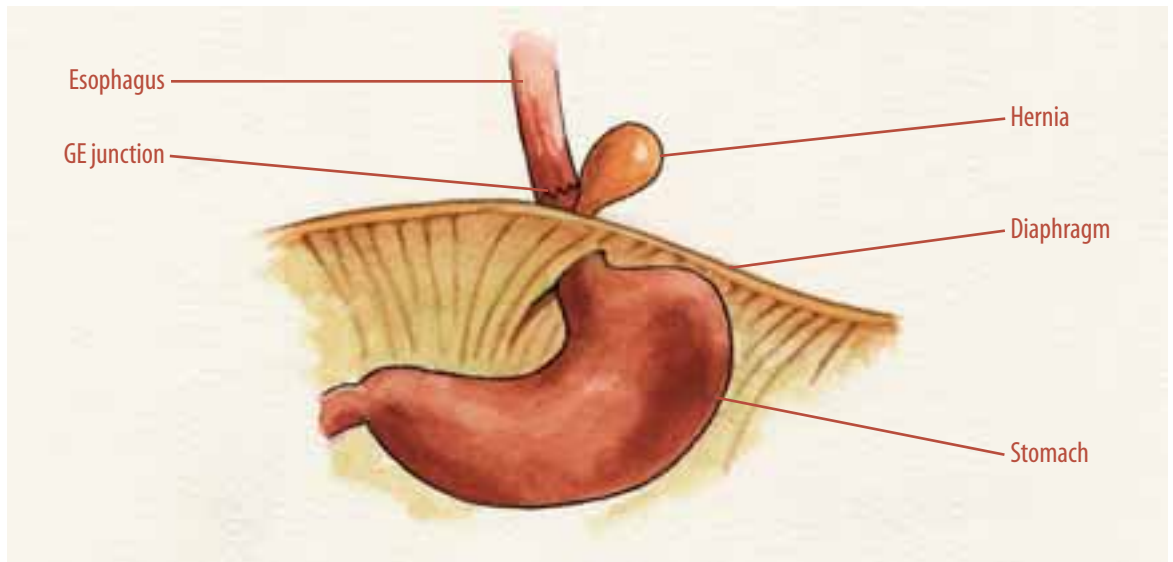
procedure such as a Nissen fundoplication is typically added to prevent the development of postoperative reflux and to help anchor the stomach in the abdominal cavity.^{5,6,7} Some surgeons advocate an antireflux repair in all paraesophageal hernia patients, claiming a high rate of postoperative recurrence if this is not done and the rarity of “true” paraesophageal hernias with the LES remaining intraabdominal and functional.^{8,9}

Summary

Paraesophageal hernias are defined as protrusion of the abdominal contents into the thorax through the esophageal hiatus. They are classi-

FIGURE 2

Type II paraesophageal hernia—the GE junction is in the normal intraabdominal position with a “true” hernia residing in the thorax.



scopic approaches have shown lower associated morbidities when compared with open procedures. The incidence of bleeding, postoperative ileus, ICU days, and overall hospital days are significantly decreased in laparoscopic patients.^{2,3} Furthermore, recurrence rates of hernias are equal for both open and laparoscopic repair.⁴

Overall, the clinical urgency and the functional status of the patient determine the operative decision. With any surgical approach, the objective of the surgery remains the same. The hernia contents must be reduced, the hernia sac must be excised, and the hernia defect in the hiatus must be closed. In addition, an antireflux

procedure such as a Nissen fundoplication is typically added to prevent the development of postoperative reflux and to help anchor the stomach in the abdominal cavity. If symptoms of incarceration are present, surgical repair is indicated.

About the authors

Leslie K Browder, MD, attended medical school at the University of Nevada School of Medicine. She is currently a general surgery resident at the University of Nevada School of Medicine in Las Vegas, having completed two clinical years and currently undergoing her second year of research.

Alex G Little, MD, attended medical school at Johns Hopkins University and trained in general surgery at Johns Hopkins and at the University of Chicago. He completed training in thoracic surgery at the University of Chicago where he was on the faculty for seven years before moving to the University of Nevada as professor and chairman of surgery in 1988.

Bibliography

1. Naunheim KS, Creswell LL. Paraesophageal Hiatal Hernia. In: Shields TW, Lociero J, Poun RB, et al. *General Thoracic Surgery*, 5th edition. Philadelphia, PA: Lippincott, Williams & Wilkins; 2000; (1): 651-659.
2. Schauer PR, Ikramuddin S, McLaughlin RH, et al. Comparison of Laparoscopic versus Open Repair of Paraesophageal Hernia. *Am J of Surg*. December 1998; (176): 659-664.
3. Velanovich V, Karmy-Jones R, et al. Surgical Management of Paraesophageal Hernias: Outcome and Quality of Life Analysis. *Dig Surg*. 2001; (18): 432-438.
4. Matter SG, Bowers SP, Galloway KD, et al. Long-term Outcome of Laparoscopic Repair of Paraesophageal Hernia. *Surg Endosc*. 2002; (16): 745-749.
5. Geha AS, Massad MG, Snow NJ, et al. A 32-year Experience in 100 Patients with Giant Paraesophageal Hernia: The Case for Abdominal Approach and Selective Antireflux Repair. *Surg*. October 2000; 128(4): 623-630.
6. Myers GA, Harms BA, Starling JR, et al. Management of Paraesophageal Hernia with a Selective Approach to Antireflux Surgery. *Am J of Surg*. October 1995; (170): 375-380.
7. Williamson WA, Ellis FH, Streitz JM, et al. Paraesophageal Hiatal Hernia: Is an Antireflux Procedure Necessary? *Ann Thorac Surg*. 1993; (56): 447-52.
8. Maziak DE, Todd TR, Pearson FG, et al. Massive Hiatus Hernia: Evaluation and Surgical Management. *J of Thorac Cardiovasc Surg*. 1998; (115): 53-62.
9. Altorki NK, Yankelevitz D, Skinner DB. Massive Hiatal Hernias: The Anatomic Basis of Repair. *J of Thorac Cardiovasc Surg*. 1998; 115(4): 828-836.
10. Society of American Gastrointestinal Endoscopic Surgeons (SAGES). Guidelines for surgical treatment of gastroesophageal reflux disease. *Surg Endosc*. 1998;12:186-188.

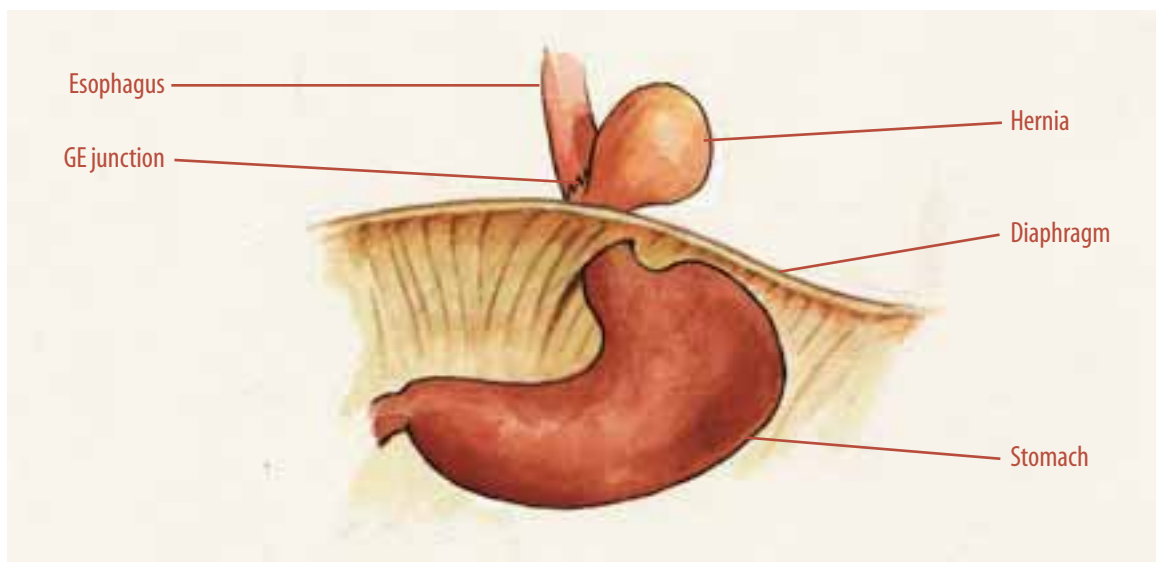


FIGURE 3

Type III paraesophageal hernia—the GE junction migrates above the diaphragm along with a portion of the stomach.

Paraesophageal hernia, part I

Earn CE credit at home

You will be awarded one continuing education (CE) credit for recertification after reading the designated article and completing the exam with a score of 70% or better.

If you are a current AST member and are certified, credit earned through completion of the CE exam will automatically be recorded in your file—you do not have to submit a CE reporting form. A printout of all the CE credits you have earned, including Journal CE credits, will be mailed to you in the first quarter following the end of the calendar year. You may check the status of your CE record with AST at any time.

If you are not an AST member or not certified, you will be notified by mail when *Journal* credits are submitted, but your credits will not be recorded in AST's files.

Detach or photocopy the answer block, include your check or money order (\$6 for members or \$10 for nonmembers) made payable to AST and send it to the Accounting Department, AST, 7108-C South Alton Way, Centennial, CO 80112-2106.

1. In which type of hernia does the stomach move into the thorax, but the GE junction remain in place?
 - a. I
 - b. II
 - c. III
 - d. IV
2. Laxity of the phrenoesophageal ligament may be caused by ____?
 - a. pregnancy
 - b. vomiting
 - c. obesity
 - d. all of the above
3. A cephalad migration of the GE junction may result in ____?
 - a. enlarged Type I hernia
 - b. weakened phrenoesophageal membrane
 - c. the stomach protruding into the thorax
 - d. all of the above
4. Which of the following is mismatched?
 - a. sliding hiatal: GE junction positioned above diaphragm
 - b. Type I: stomach herniates into thorax
 - c. Type III: cephalad migration of the GE junction
 - d. true paraesophageal: peritoneal lined opening in esophageal hiatus
5. Which organ would not likely herniate into the thorax
 - a. small bowel
 - b. kidney
 - c. colon
 - d. omentum
6. Which type of hernia is the most common?
 - a. Type I
 - b. Type II
 - c. Type III
 - d. Type IV
7. In which type of hernia is the patient likely to experience symptoms of GERD?
 - a. Type IV
 - b. Type III
 - c. Type II
 - d. Type I
8. In which types of hernias may the patient be misdiagnosed as having a heart attack?
 - a. Types I & II
 - b. Types II & III
 - c. Types III & IV
 - d. None of the above
9. Medications that alter gastric pH may be used to treat which type of hernia?
 - a. Type I
 - b. Type II
 - c. Type III
 - d. Type IV
10. Which surgical approach is typically reserved for hernias with accompanying esophageal shortening?
 - a. laparoscopy
 - b. thoracotomy
 - c. Nissen fundoplication
 - d. None of the above

Paraesophageal hernia, part I

		a	b	c	d		a	b	c	d
<input type="checkbox"/> Certified Member	<input type="checkbox"/> Certified Nonmember	1	<input type="checkbox"/>	<input type="checkbox"/>	<input type="checkbox"/>	6	<input type="checkbox"/>	<input type="checkbox"/>	<input type="checkbox"/>	<input type="checkbox"/>
Certification No _____		2	<input type="checkbox"/>	<input type="checkbox"/>	<input type="checkbox"/>	7	<input type="checkbox"/>	<input type="checkbox"/>	<input type="checkbox"/>	<input type="checkbox"/>
Name _____		3	<input type="checkbox"/>	<input type="checkbox"/>	<input type="checkbox"/>	8	<input type="checkbox"/>	<input type="checkbox"/>	<input type="checkbox"/>	<input type="checkbox"/>
Address _____		4	<input type="checkbox"/>	<input type="checkbox"/>	<input type="checkbox"/>	9	<input type="checkbox"/>	<input type="checkbox"/>	<input type="checkbox"/>	<input type="checkbox"/>
City _____ State _____ ZIP _____		5	<input type="checkbox"/>	<input type="checkbox"/>	<input type="checkbox"/>	10	<input type="checkbox"/>	<input type="checkbox"/>	<input type="checkbox"/>	<input type="checkbox"/>
Telephone _____										

Mark one box next to each number. Only one correct or best answer can be selected for each question.