



# Microvascular decompression for control of typical trigeminal neuralgia

Jeffrey J Cortese, CST

TRIGEMINAL NEURALGIA (TN), TRIGEMINAL NEURALGIA IS  
OR TIC DOULOUREUX, IS AMONG ORAL MEDICATION. FOR THOSE  
THE MOST ACUTE PAIN KNOWN. PATIENTS WHO DO NOT RESPOND  
TN AFFECTS APPROXIMATE- TO NONINVASIVE TREATMENTS,  
LY 40,000 PEOPLE IN THE UNIT- SURGICAL TREATMENT IS ONE  
ED STATES.<sup>1</sup> THE MOST COM- ALTERNATIVE TO DEAL WITH  
MON FORM OF TREATMENT FOR THIS DEBILITATING CONDITION.

## History of trigeminal nerve surgery

In 1934, Walter Dandy first pioneered the approach to the posterior fossa enroute to the trigeminal nerve complex.<sup>2</sup> Dandy also outlined the theory of vascular compression as a cause of the pain associated with the condition. The artery pinpointed as the source of compression was the anterior inferior cerebellar artery. This pathophysiology will be explained in further detail.

Peter Janetta was the first neurosurgeon to apply the surgical microscope to trigeminal nerve surgery, making it a relatively safe operation to perform.<sup>4</sup> Along with this application, Janetta also devised a nondestructive technique to the decompression of the trigeminal nerve.

## Anatomy involved

The trigeminal nerve, cranial nerve number V, exits from the pons at the base of the brain. The main function of this nerve is to transmit and receive facial sensations. The trigeminal ganglion is divided into three main divisions: the ophthalmic, the maxillary and the mandibular. The ophthalmic or V<sub>1</sub> branch controls sensation in the eyes, upper eyelids and forehead. The V<sub>2</sub> branch, or maxillary, acts upon the cheeks, lower eyelids, nostrils, upper lip and gums. Along with acting upon the jaw, lower lips and gums, the mandibular or V<sub>3</sub> branch also controls some of the chewing muscles (eg the masseters and buccinators).

## Pathophysiology

Although the primary mechanism of TN is not known at the present time, doctors have

observed that an abnormality of the root entry zone into the pons is one source.<sup>1</sup> Vascular cross compression of the nerve is the most common source of the neuralgia. As a person ages, elongation of the vessels is observed. This elongation causes the vessel to adhere to the trigeminal nerve. The pulsation of the vessel, along with the mechanical “rubbing” of the nerve, causes demyelination of the axons, giving the nerve a “raw” spot that makes it susceptible to increased pain sensation.

In 1996, Janetta piloted a study of 1,204 patients that were treated with microvascular decompression of the trigeminal nerve.<sup>5</sup> He observed that the superior cerebellar artery was the source of compression in 75.5% of patients (Table 1). Interestingly, a small unnamed artery, most likely a vascular anomaly, was the source of compression of 15.4% of the patients.<sup>5</sup>

## Clinical presentation

The most common complaint of the TN patient is a sudden onset of lancinating pain that is severe. These electric shock-like pain surges are brief in duration (tics). Some of the triggers observed in the patient are, but are not limited to, light, moving the face while talking, eating and/or brushing the teeth.

Along with the pain associated with trigeminal neuralgia, the patient may have a mild sensory loss in the distribution of the trigeminal nerve. In V<sub>1</sub> neuralgia, the patient may have a decreased corneal reflex. Interestingly, trigeminal neuralgia affects mostly middle age or older women, due to their smaller posterior fossae. That, coupled with the vascular elongation secondary to aging, increases their risk.

Decreased estrogen production has been associated with trigeminal neuralgia in several patients.

## Medical treatment

The first line of treatment for the TN patient is the administration of oral medications.<sup>3</sup> The primary drug of choice is carbamazepine. Traditionally an anticonvulsant, the drug has proven itself as an effective means of drug treat-

TABLE 1 Sources of TN Compression

Superior cerebellar	75.5%
Anterior inferior cerebellar artery	9.6%
Posterior inferior cerebellar artery	0.7%
Vertebral artery	1.6%
Basilar artery	0.7%
Labyrinthine artery	0.2%
Unnamed small artery	15.4%

ment. Most recently, oxcarbazepine has been used without the side effects of carbamazepine (eg drowsiness, syncopal episodes and gait ataxia). Other drugs, like baclofen and gabapentin, have also been used in the treatment of trigeminal neuralgia, but with limited results.

## Surgical treatment

For TN patients who do not respond to noninvasive therapy, surgery is the next course of treatment. There are two categories of surgical treatment for these patients: ablative and nonablative surgeries. The nonablative, microvascular decompression treatment will be discussed first.

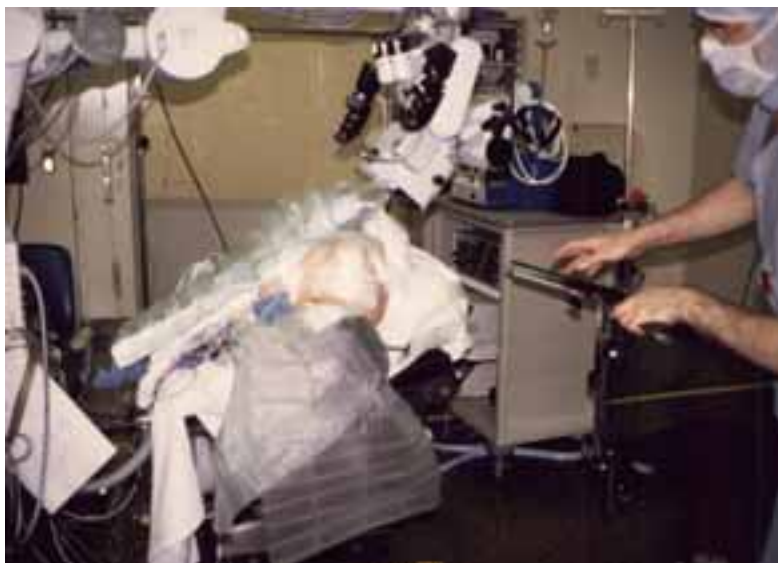The patient is administered general anesthesia and intubated with an endotracheal tube. A three or four-point head-fixation device (Mayfield, Sugita) is attached to the patient's skull. The patient is then rotated into a three-quarter lateral position on the operating table so that gravity aids in the retraction of the cerebellum enroute to the pons. Mannitol and Lasix are administered to help decrease brain bulk, thus eliminating excessive retraction of the cerebellum. Corticosteroids, along with prophylactic antibiotics, are also administered to the patient prior to the incision. The surgeon is seated at the patient's back with the surgical microscope directly across from the surgeon (Figure 1).

A standard craniotomy set-up is all that is needed for this surgery (Figure 2). A variety of microscissors, forceps, and Rhoton dissectors will facilitate the decompression portion of the procedure. Fibrin glue (Tisseal, Hemaseal®) should be mixed and ready prior to the closure of the incision.

After the surgical site is prepped and draped in the usual sterile fashion, the incision site can be infiltrated with lidocaine with epinephrine 1:200,000 to promote hemostasis. A lazy-s incision is made two fingerbreadths behind the hairline with the central third of the incision directly behind the mastoid process. The incision is carried further down to the bone with the monopolar electro-surgical unit. A self-retaining retractor is placed into the wound, while creating a 3 cm by 3 cm exposure via sub periosteal dissection.

A 7 mm round, acorn, or 14 mm craniotome is used to fashion a craniectomy into the posterior fossa. The inner table of the skull is rongeured away using a Beyer-Lempert, Leksell, or a Kerrison rongeur. The borders of the bone removal are determined by the inferior margin of the lateral sinus and the medial margin of the sigmoid sinus. Any bleeding is controlled by application of bone wax. If the sinuses are damaged during exposure, attention to the repair and reconstruction of these sinuses must be undertaken before proceeding with microvascular decompression.

Once a sufficient craniectomy has been performed, the surgical microscope is draped and brought into place. Any vessels on the dural



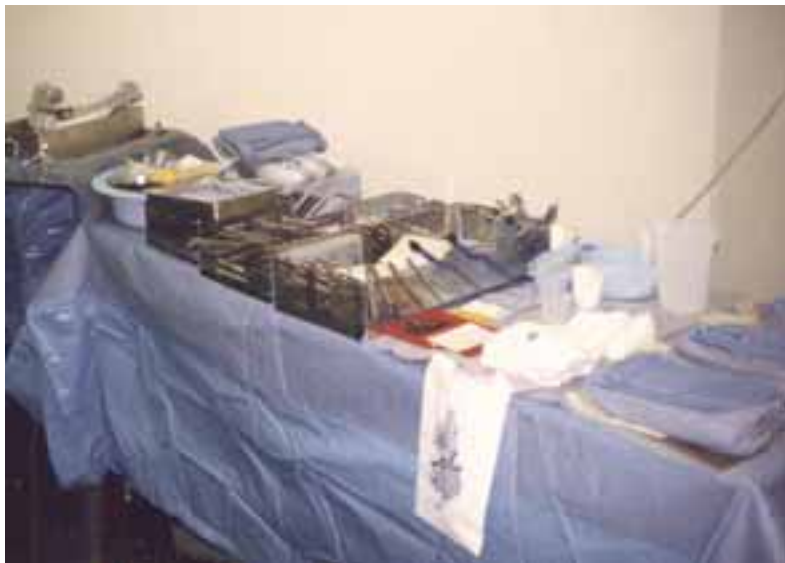surface are coagulated with the bipolar unit prior to the opening of the dura. A durotomy is performed using a #11 blade. The durotomy is extended in a cruciate fashion using Metzenbaum or Jones scissors. The edges of the dura are tacked up using 4-0 silk or braided nylon and a TF needle or tagged with mosquito clamps, exposing the cerebellar hemisphere.

A self-retaining brain retractor (Leyla, Mayfield, Sugita) is attached to the head holder or operating table. A variety of retractor blades should be available to the surgeon, along with various sizes of nonadherent gauze (Adaptic™). The rationale for the gauze is that it is placed under the retractor blades to disperse the force

**FIGURE 1**  
Patient positioned for microvascular decompression.

of the blades onto the gauze instead of on the surface of the brain. The cerebellum is retracted inferiorly and medially, exposing the bridging superior petrosal vein. This vein can be sacrificed with the bipolar unit and divided with microscissors without any side effects to the patient.

Cerebrospinal fluid is evacuated from the subarachnoid space using gentle suction, facilitating the brain retraction and exposure. Any arachnoid fibers are divided by sharp dissection using an arachnoid knife and microscissors. The retractors are further advanced on top of the cerebellum, exposing the lateral portions of the trigeminal and oculomotor nerves (Figure 3).



**FIGURE 2** Further retraction exposes the root entry zone, along with sharp and blunt dissection.

**Standard craniotomy setup.** Final vessel and nerve exposure are achieved using sharp dissection. The offending vessels are identified and teased away into a horizontal position. This can be accomplished using a variety of microdissectors, microscissors, and microforceps. Extreme care must be taken not to manipulate the vessels too much, causing vasospasm. Alternatively, Gelfoam® soaked in papaverine can help prevent this from occurring.

Once the nerve has been satisfactorily decompressed, a small indentation can occasionally be seen where the vessel has been fixed to the nerve (Figure 4). A small piece of wad-

ded-up Teflon® pledget is placed where the vessel once resided, providing a physical padding between the artery and nerve. The padding is also placed at the root entry zone to prevent dislodging as it is wrapped around the nerve (Figure 5). Fibrin glue can be applied to the nerve and padding to coat and help keep the padding in place, but it is not mandatory. A Valsalva maneuver is performed by anesthesia to ensure that the padding is not going to migrate upon increased intracranial pressure.

The brain retractors are carefully removed, and the wound is copiously irrigated with saline containing a bacitracin antibiotic. The retention sutures are removed from the dura edges. The dura is approximated in a watertight fashion using a running locking suture of 4-0 silk or braided nylon and a TF needle. Fibrin glue is then sprayed onto the dura surface, thus decreasing the chance for a cerebrospinal fluid leak. A cranioplasty with methyl methacrylate or hydroxyapatite may be performed at this point, but it is not necessary. The wound retractors are removed, final hemostasis is achieved, and the wound is irrigated again with the antibiotic saline. The fascia is approximated using a CT-1 needle and 0-Vicryl® in an interrupted fashion. The subcutaneous tissue is approximated using an X-1 needle and 3-0 Vicryl®, and the skin can either be stapled or closed with a 5-0 plain gut. A sterile dressing is applied, and the patient is transferred to the stretcher and extubated.

### Complications

Microvascular decompression surgery carries the same complications as any other neurosurgical procedure with the addition of brain stem infarct, hydrocephalus, facial paresis, hearing loss, and bacterial meningitis.<sup>5</sup> Careful attention to detail and preoperative planning can help eliminate these complications.

### Ablative procedures

Along with the microvascular decompression, other surgical options are available to the TN patient. These groups of procedures are aimed at destroying the trigeminal ganglion rather than

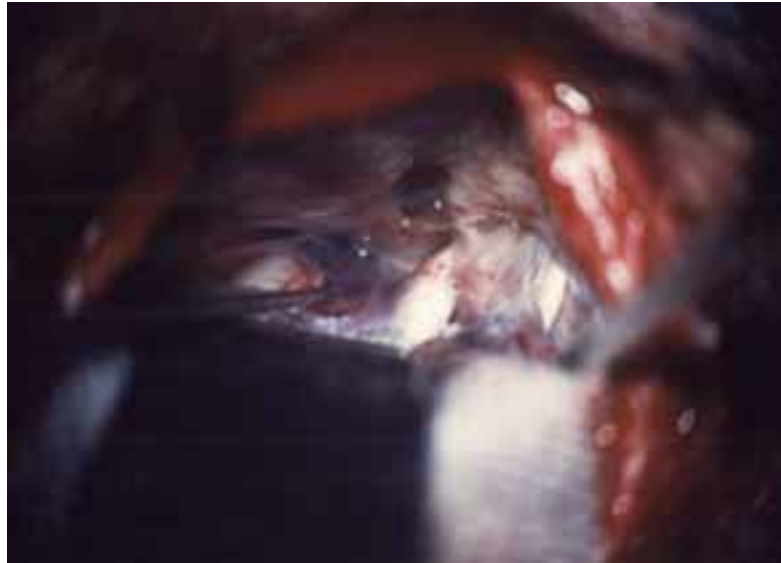

decompressing it. Although these procedures carry the decreased risks associated with conventional surgery, they are typically outpatient procedures and tend to have a less-than-optimal result.

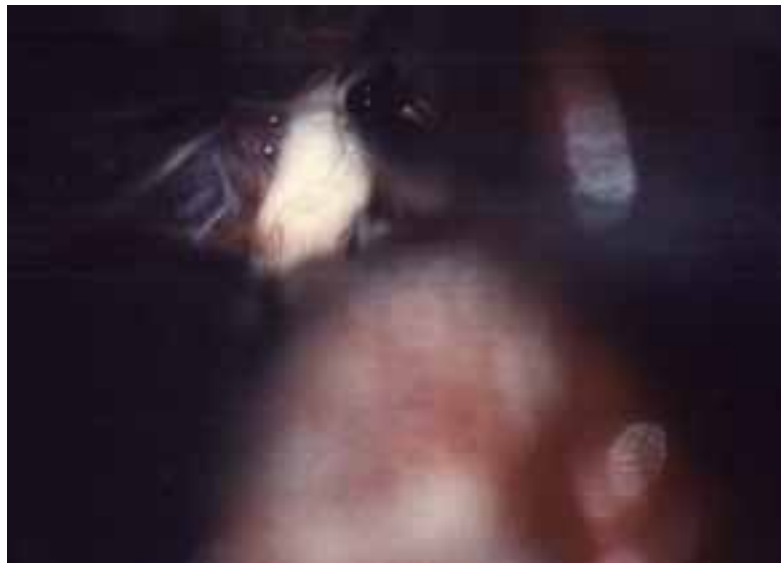The first of these ablative procedures is a percutaneous rhizotomy by injection of glycerol. This procedure, which is performed under local anesthesia, involves a 20-gauge spinal needle inserted under fluoroscopic control into the foramen ovale via the mouth. After a satisfactory position of the needle is achieved, glycerol is injected around the Gasserian ganglion. As stated, this is less invasive than a decompression procedure, but only provides temporary relief of symptoms.

The next ablative procedure performed involves the same approach, but it is performed under general anesthesia with a larger gauge needle. A balloon is introduced and inflated next to the ganglion, causing a compression injury to the nerve root. This ablative procedure is longer lasting than a glycerol injection, but it carries a risk of loss of corneal sensation and decreased action in the chewing muscles.

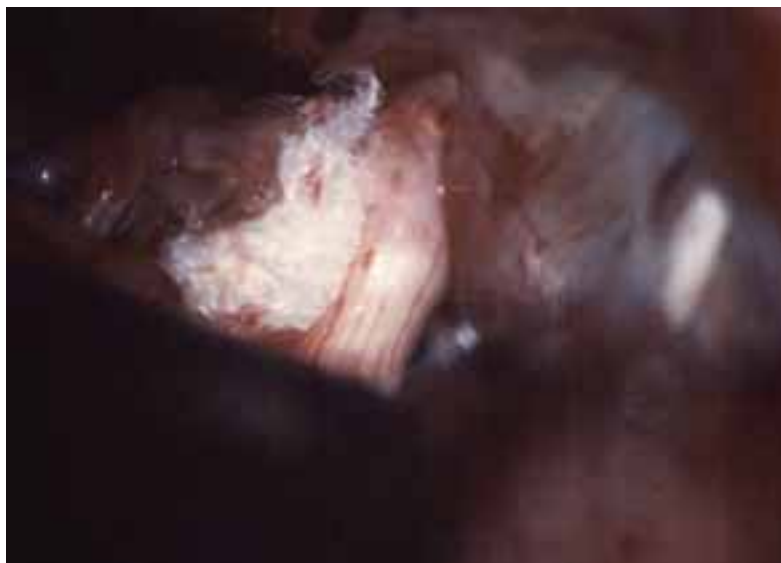
Radio frequency rhizotomies have become the most common ablative procedures in the treatment of trigeminal neuralgia. An electrode is inserted in the Gasserian via the same route as



**FIGURE 3**  
Exposure of the trigeminal and oculomotor nerves.



**FIGURE 4**  
After decompression, an indentation in the nerve is still visible.



**FIGURE 5**  
Padding at the root entry zone prevents dislodging.

the two previously procedures, and a lesion is burned into the nerve, causing the cessation of pain. This procedure, which is performed under local anesthesia with sedation, provides the best long-term results of the ablative procedures, but some facial parasthesia has been noted.

The latest noninvasive treatment available to TN patients is knifeless surgery. By utilizing specifically focused beams of radiation, the neurosurgeon is able to create a lesion at the root entry zone of the trigeminal nerve, thus ceasing the pain impulses. The two systems commercially available on the market for this type of procedure are the gamma probe and CyberKnife®.

Finally, surgeons have developed a minimally invasive treatment for microvascular decompression. By introducing an endoscope to the cerebellopontine angle via a dime-sized craniotomy in the posterior fossa, the same procedure is performed as conventional microvascular decompression, but without the brain retraction and with the enhanced visualization, lighting, and magnification of an endoscope. These patients are usually discharged within 24 to 48 hours of surgery.<sup>5</sup>

## Conclusion

Trigeminal neuralgia is an extremely painful condition that has caused some patients to go as far as to commit suicide to alleviate the pain. TN patients often live for years with the pain before diagnosis. The disorder is commonly misdiagnosed by doctors as oral in etiology. These patients are then referred to the dentist or oral surgeon, who provides the patient with little to no relief. With the appropriate diagnosis, the physician is able to first provide the patient with various means of treatment. The least invasive of these is oral medications. When patients fail to respond, a more aggressive treatment must be employed. The next option for the patient is surgery. The surgical procedure that provides the most long-term pain relief without physically destroying the nerve itself, is microvascular decompression. This surgery, although it carries increased risks, promises the surgical patient with a better quality of life from this

painful and morbid condition. Microvascular decompression offers the best chance of long-term relief and improved quality of life of any of the available surgical procedures, and does so by providing pain relief without producing numbness, as is necessary with the destructive/ablative procedures.

## About the author

Jeffrey J Cortese has been a certified surgical technologist in Michigan for eight years. He is employed at Mount Clemens General Hospital, and William Beaumont Hospital-Troy. Cortese, an adjunct instructor for the Surgical Technology Program at Baker College of Clinton Township, is also a full-time student at Baker College where he is attaining a bachelor's degree in health service administration. He plans to become a physician's assistant specializing in neurological surgery.

## Acknowledgments

I dedicate this paper to the memory of my grandmother, Yolanda M McGuire, who suffered from trigeminal neuralgia. I also wish to thank Jennifer N Prigg, DO, and John L Zinkel, MD, PHD, FACS, for their continued support.

## References

1. Allen, Jr MB and Miller RH. *Essentials of Neurosurgery: A Guide to Clinical Practice*. New York: McGraw-Hill, Inc; 1995:484-488.
2. Dandy WE. Concerning the Cause of Trigeminal Neuralgia. *Am J Surg* 1934;24:447-455.
3. Drug treatment of trigeminal neuralgia. [www.the-support.org](http://www.the-support.org) (accessed 8/18/04)
4. Janetta PJ. Treatment of trigeminal neuralgia by micro-operative decompression. In: *Woman's Neurological Surgery*, 3d ed., Philadelphia: Saunders; 1988:3928-3942.
5. Pessanha Tavares M. Trigeminal Neuralgia-Microvascular Decompression. Medstudents. Medcenter Solutions of Brazil. [www.medstudents.com.br/neuroc/neuroc2.htm](http://www.medstudents.com.br/neuroc/neuroc2.htm) (accessed 8/18/04)

## Microvascular decompression for control of trigeminal neuralgia

### Earn CE credit at home

You will be awarded one continuing education (CE) credit for recertification after reading the designated article and completing the exam with a score of 70% or better.

If you are a current AST member and are certified, credit earned through completion of the CE exam will automatically be recorded in your file—you do not have to submit a CE reporting form. A printout of all the CE credits you have earned, including Journal CE credits, will be mailed to you in the first quarter following the end of the calendar year. You may check the status of your CE record with AST at any time.

If you are not an AST member or not certified, you will be notified by mail when *Journal* credits are submitted, but your credits will not be recorded in AST's files.

Detach or photocopy the answer block, include your check or money order made payable to AST and send it to the Accounting Dept, AST, 6 West Dry Creek Circle, Suite 200, Littleton, CO 80120.

**Members: \$6 per CE, nonmembers: \$10 per CE**

- Which is the trigeminal nerve?
  - IV
  - V
  - VI
  - X
- Who created a nondestructive technique to decompress the trigeminal nerve?
  - Andre Douloureux
  - Walter Dandy
  - Peter Janetta
  - Antonio Valsalva
- Which is mismatched?
  - V<sub>1</sub>: eyes, upper eyelids and forehead
  - V<sub>2</sub>: cheeks, lower eyelids, nostrils, upper lips, gums
  - V<sub>3</sub>: jaw, lower lip, gums, chewing muscles
  - None are mismatched
- The most common form of treatment for TN is:
  - medication
  - open surgery
  - ablative procedures
  - endoscopic surgery
- Which is not a symptom of TN?
  - brief, lancinating pain
  - sensory loss in the distribution of the nerve
  - decreased corneal reflex
  - decreased estrogen production
- TN causes \_\_\_\_\_, making the patient susceptible to increased pain sensations.
  - pulsation of the vessel
  - demyelination of the axons
  - transmission of facial sensations.
  - none of the above
- Which drug used to treat TN has had the best results and fewest side effects?
  - baclofen
  - carbamazepine
  - gabapentin
  - oxcarbazepine
- When is the Valsalva maneuver performed?
  - when nerve exposure is achieved
  - once the nerve has been decompressed
  - prior to craniectomy
  - after cranioplasty
- The most common ablative procedure for TN is:
  - percutaneous rhizotomy by glycerol injection
  - percutaneous rhizotomy by balloon
  - radio frequency rhizotomy
  - knifeless surgery
- The \_\_\_\_\_ decompression procedure prevents brain retraction and provides enhanced visualization, lighting and magnification.
  - endoscopic
  - gamma probe
  - CyberKnife®
  - radio frequency rhizotomy

### Microvascular decompression for control of trigeminal neuralgia

Certified Member    Certified Nonmember

Certification No \_\_\_\_\_

Name \_\_\_\_\_

Address \_\_\_\_\_

City \_\_\_\_\_ State \_\_\_\_\_ ZIP \_\_\_\_\_

Telephone \_\_\_\_\_

	a	b	c	d		a	b	c	d
1	<input type="checkbox"/>	<input type="checkbox"/>	<input type="checkbox"/>	<input type="checkbox"/>	6	<input type="checkbox"/>	<input type="checkbox"/>	<input type="checkbox"/>	<input type="checkbox"/>
2	<input type="checkbox"/>	<input type="checkbox"/>	<input type="checkbox"/>	<input type="checkbox"/>	7	<input type="checkbox"/>	<input type="checkbox"/>	<input type="checkbox"/>	<input type="checkbox"/>
3	<input type="checkbox"/>	<input type="checkbox"/>	<input type="checkbox"/>	<input type="checkbox"/>	8	<input type="checkbox"/>	<input type="checkbox"/>	<input type="checkbox"/>	<input type="checkbox"/>
4	<input type="checkbox"/>	<input type="checkbox"/>	<input type="checkbox"/>	<input type="checkbox"/>	9	<input type="checkbox"/>	<input type="checkbox"/>	<input type="checkbox"/>	<input type="checkbox"/>
5	<input type="checkbox"/>	<input type="checkbox"/>	<input type="checkbox"/>	<input type="checkbox"/>	10	<input type="checkbox"/>	<input type="checkbox"/>	<input type="checkbox"/>	<input type="checkbox"/>

Mark one box next to each number. Only one correct or best answer can be selected for each question.