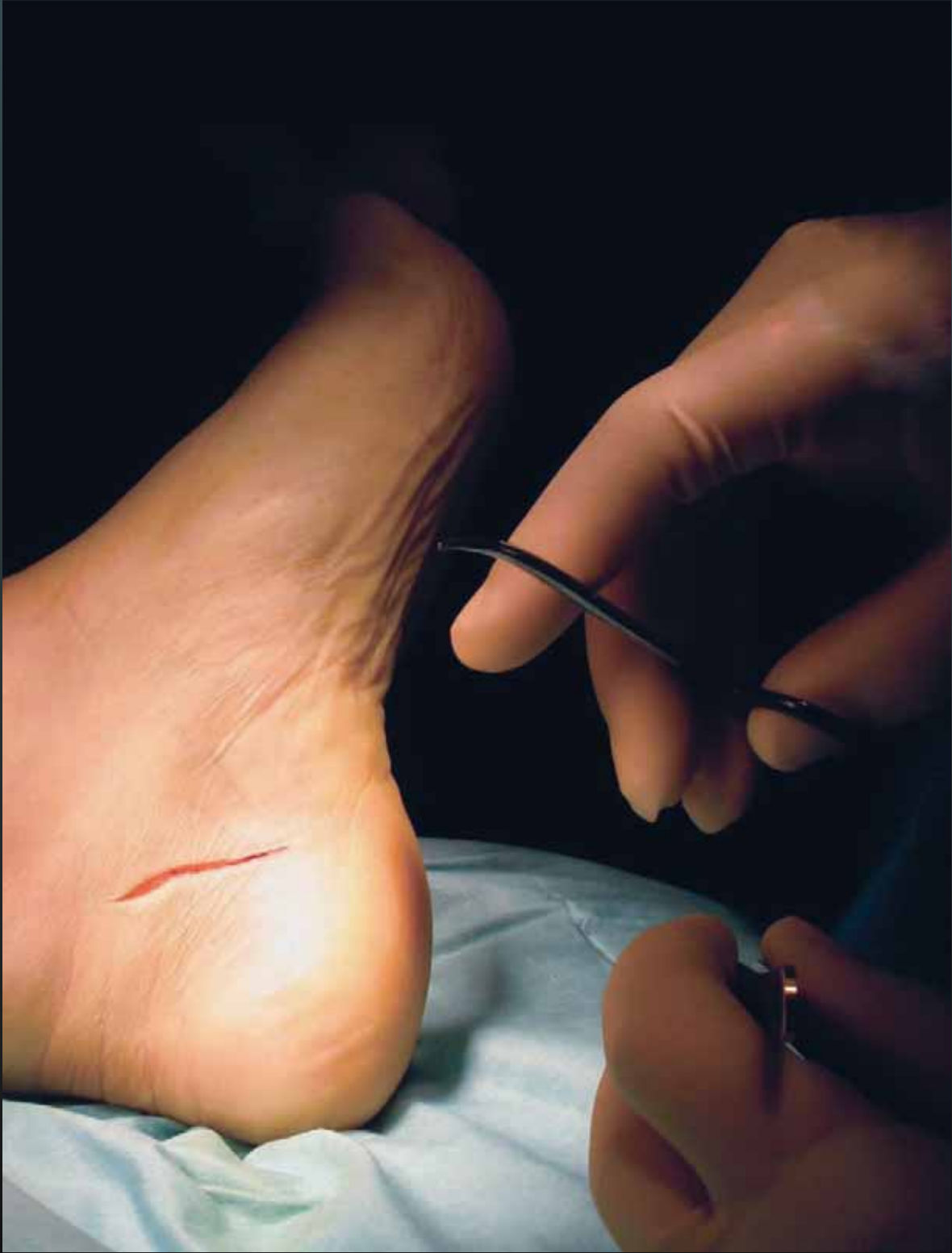



# Acquired Adult *Flatfoot Deformity*

by Angel Webb, CST

*Pes Planus*, or flat foot, refers to the postural appearance of the foot. This condition can be acquired or congenital. This article discusses acquired cases in which there is a change in shape and position of the back and mid portions of the foot.

**A**lthough, 10-25 percent of the population have varying degrees of flatfoot, very few are symptomatic. Those that are symptomatic may complain of painful swelling posterior to the medial malleolus that may extend into the medial arch. They may also, variably, complain of foot, ankle or lateral hindfoot pain.

## ANATOMY

A review of relevant anatomy will help in understanding this topic. The subtalar joint is the articulation of the calcaneus and the talus, with the talus superior to the calcaneus. The talonavicular joint is between the talus and the navicular, and is located on the dorsal foot, just below the ankle. The calcaneocuboid joint consists of the calcaneus and the cuboid. It is located on the anterolateral midfoot (Figure 1). The medial longitudinal arch consists of the calcaneus, talus and navicular, as well as the middle, medial and lateral cuneiforms and the first through third metatarsals. The posterior tibial tendon passes behind the medial malleolus and attaches on the navicular tuberosity (bump on the inside of the instep). The flexor digitorum longus tendon is

## LEARNING OBJECTIVES

- ▲ Review the relevant anatomy for this procedure.
- ▲ Examine the step-by-step process of FDL transfer.
- ▲ Compare and contrast the benefits and risks of motion-sparing procedures to arthrodesis.
- ▲ Assess the surgical alternatives and additions to FDL transfer.
- ▲ Evaluate the rehabilitation process after flatfoot surgery.

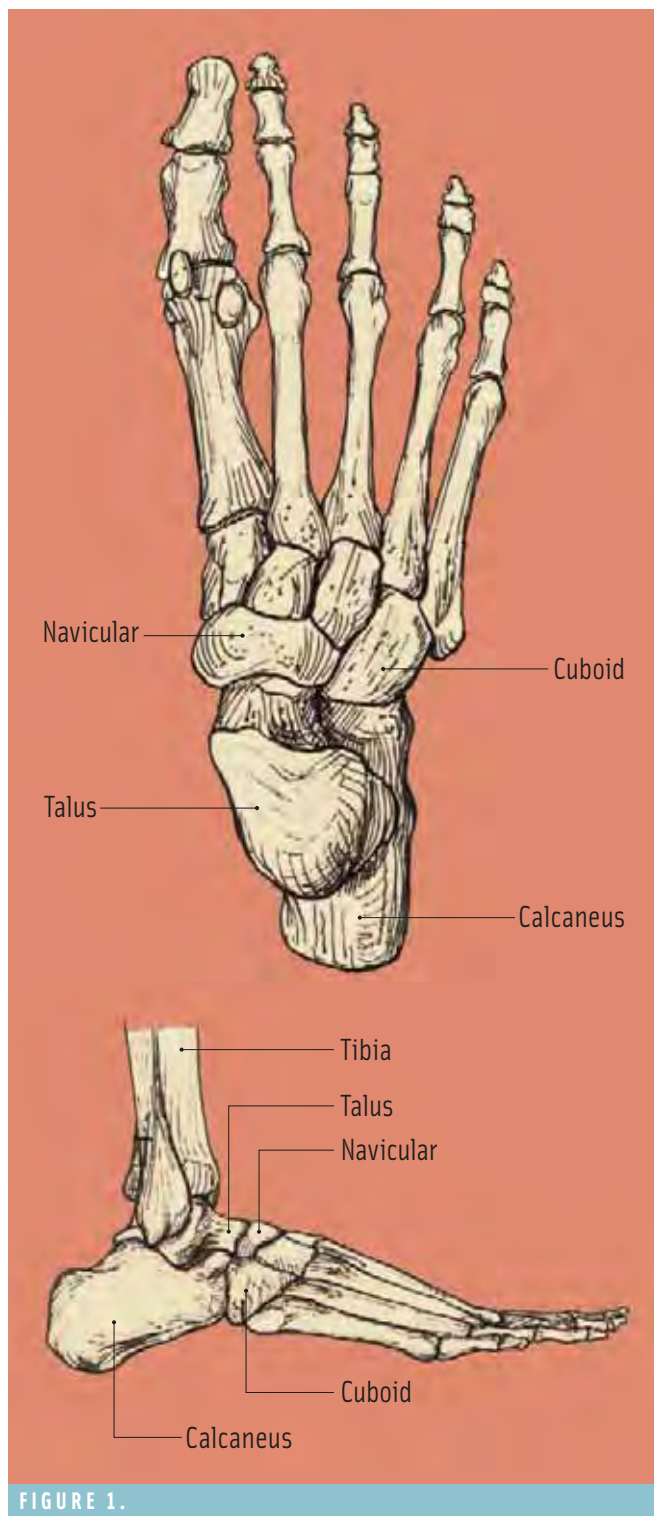


FIGURE 1.

Delmar Cengage Learning

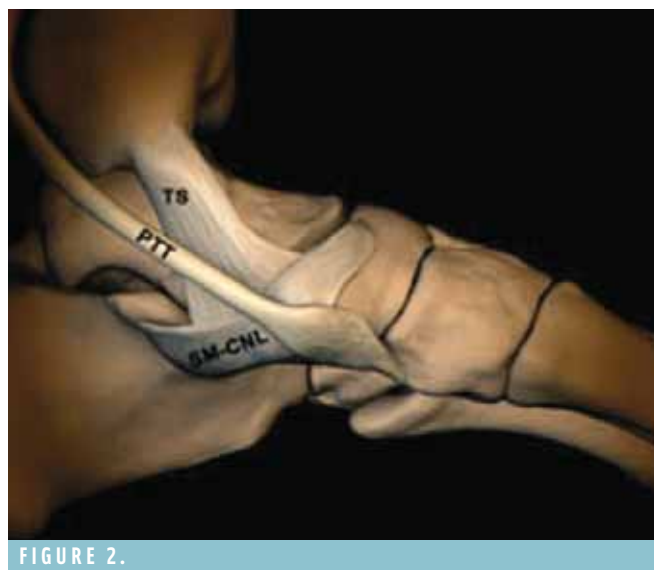

FIGURE 2.

Courtesy of Michael Stanek, MD, RadiSource

just behind and adjacent to the posterior tibial tendon. The spring ligament helps to hold up the arch by forming a supportive sling under the head of the talus (Figure 2).

The most common cause of adult-acquired flatfoot is posterior tibial tendon dysfunction (PTTD). The abnormalities of the posterior tibial tendon are divided into stages. In stage one, there is tendonitis or inflammation, but the tendon is of normal length and not torn. In stage two, the tendon is elongated, but the hindfoot remains flexible. The arch of the foot may appear normal in non-weight-bearing position. In weight-bearing positions, however, the arch appears flattened and the heel moves to the outside (valgus deformity). In stage three, the hindfoot deformity of stage two becomes rigid or “fixed.” The hindfoot is everted (valgus) and the forefoot is abducted (pointing to the outside).

### SURGICAL CONSIDERATIONS

Surgical procedures for correction of the flatfoot vary, but can include: medial displacement osteotomy of the calcaneus and transfer of the flexor digitorum longus (FDL) tendon to replace the posterior tibial tendon; spring ligament reconstruction; subtalar arthrodesis; and triple arthrodesis (fusion).

Indications for medial displacement osteotomy of the calcaneus, and substitution of the posterior tibial tendon using the flexor digitorum longus (FDL), are painful PTTD stage two and a flexible flatfoot deformity. Combining the osteotomy with the transfer of the FDL is useful in improving the posture of the foot and gives some mechanical protection to the tendon transfer.





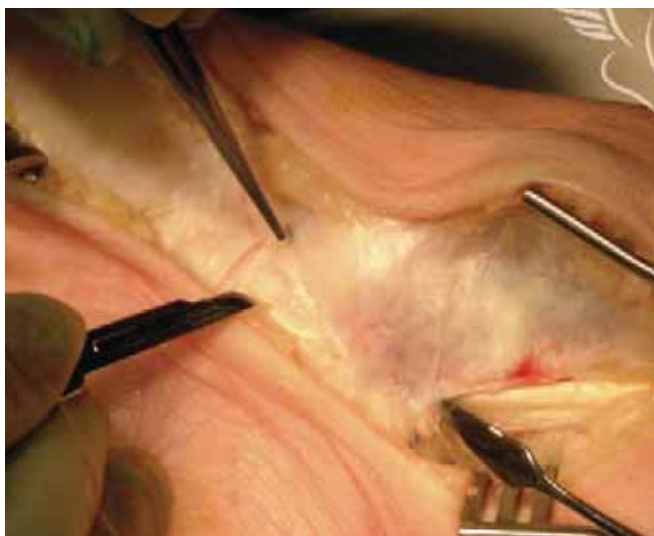


FIGURE 7.

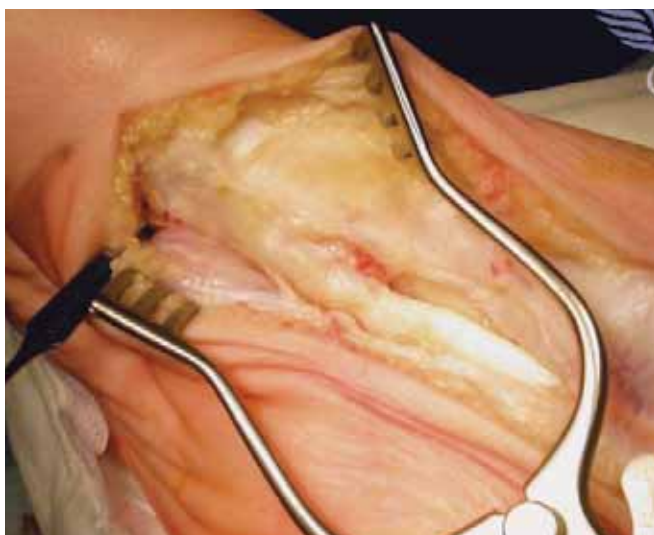

FIGURE 8.

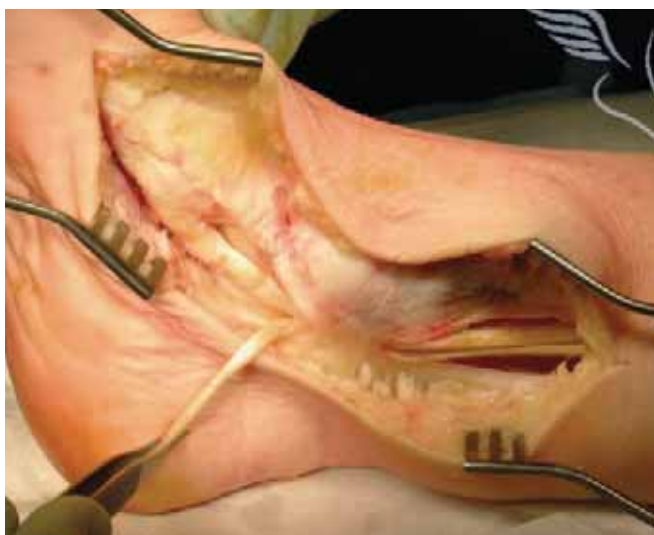

FIGURE 9.

is inserted across the osteotomy site. The screw placement and osteotomy position is radiographically checked (Figure 6). The wound is irrigated and closed in layers using either a 2-0 or 3-0 absorbable suture for the subcutaneous tissues and 3-0 nylon on the skin.

Attention is then turned to the FDL transfer and the medial side of the foot. At this point, it is helpful to have the “bump” removed from the ipsilateral hip, allowing the foot to externally rotate. An incision is made from a point superior to the tip of the medial malleolus to the navicular along the course of the posterior tibial tendon. The tendon sheath is opened and inspected (Figures 7-8). Increased fluid, fissures, change in color and texture of the tendon can be seen. The FDL tendon is identified and dissected into the midfoot (Figure 9). After the tendon is detached, it will serve to replace the damaged posterior tibial tendon. The posterior tibial tendon is usually debrided. If severe, it is largely excised, but may be saved to attach to the newly-transferred FDL to add to its power. This is called a tenodesis. The surgeon may repair the spring ligament. One method by which this is accomplished is to plicate the ligament using 2-0 fiberwire (Figure 10).

The navicular is exposed dorsally. A drill hole is made going from plantar to dorsal. A 3.2 mm drill can be used first to make a pilot hole. The hole can then be enlarged using a 4.5 mm drill to accommodate the thickness of the FDL. Figure 11 shows the hole in the navicular, which can be seen below the Senn retractor, and the FDL tendon stretched across the navicular. The FDL tendon is passed through the hole from plantar to dorsal. The foot is then

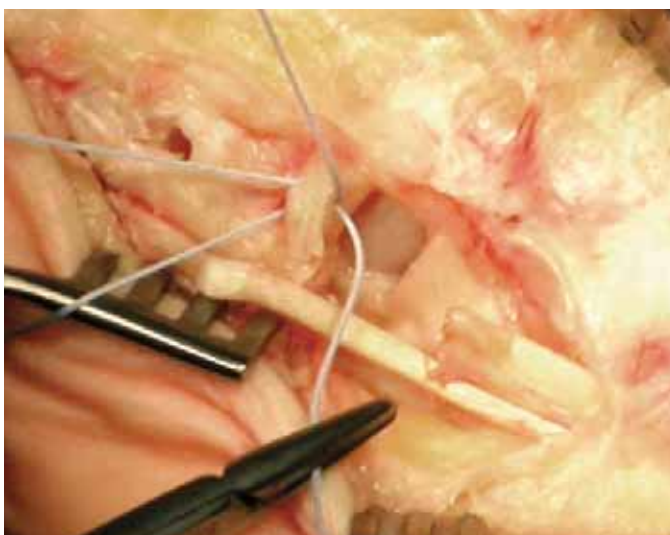


FIGURE 10.

Figures 7-13. Courtesy of Mark Heron, MD, PhD, FRCGS, The Foot Surgery Atlas

positioned into maximum inversion. The tendon is sutured into the periosteum of the navicular, the surrounding tissues, and to itself using #2 nonabsorbable suture.

Another technique of fixating the FDL tendon is the use of an absorbable biotenodesis screw. A 2-0 absorbable suture is stitched to the free end of the FDL starting about 2cm from the end of the tendon so that the ends of the suture (left long) are parallel to the length of the tendon. A long 2.0 drill bit having an eyelet on the opposite end of the flutes of the bit is passed through the navicular from

Surgical procedures for correction of the flatfoot vary, but can include: medial displacement osteotomy of the calcaneus and transfer of the flexor digitorum longus tendon to replace the posterior tibial tendon; spring ligament reconstruction; subtalar arthrodesis; and triple arthrodesis.

plantar to dorsal. A cannulated 5.0mm drill bit is passed over the first drill and removed. The long ends of the suture are threaded through the eye of the first bit. The bit is then pulled through the hole in the navicular, feeding the FDL through. A 5.0 bioabsorbable screw is placed in the hole from the plantar side while tension is applied to the sutures and the foot is held in maximum inversion (Figure 12). The suture is cut and the wound is irrigated (Figure 13). A suction drain may be placed. The wound is closed in layers, starting with a 2-0 absorbable suture for subcutaneous tissue and 3-0 nylon for skin.

After closure, the patient is held in a short-let compressive dressing consisting of a wound dressing, a bulky cotton roll, plaster or fiberglass splints, and an over wrap of an elastic bandage. This is done with the foot in inversion to protect the tendon transfer.

#### POSTOPERATIVE

Sutures are removed at two to four weeks and a short-leg, non-weight-bearing cast is applied with the foot still in inversion. The cast is changed intermittently every few weeks after surgery and radiographs are taken to confirm union of the osteotomy site. The patient is eventually allowed to bear weight in a walking cast and then in a

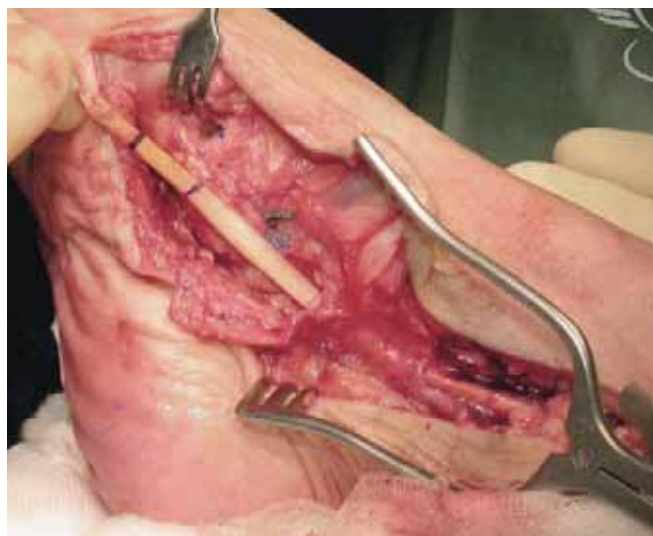

FIGURE 11.

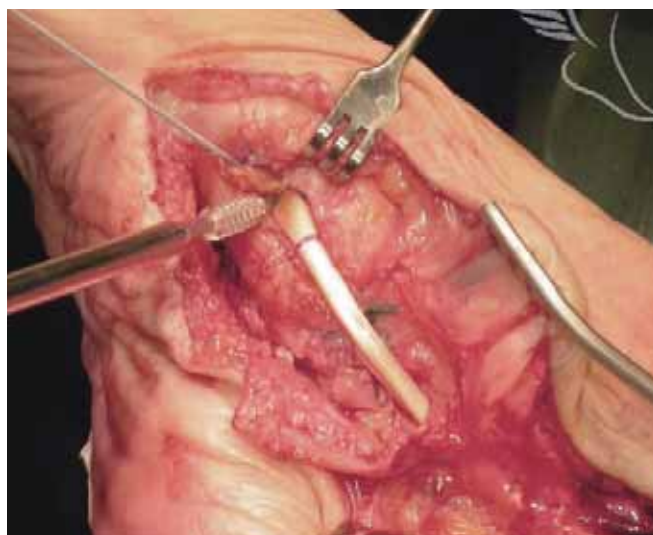

FIGURE 12.

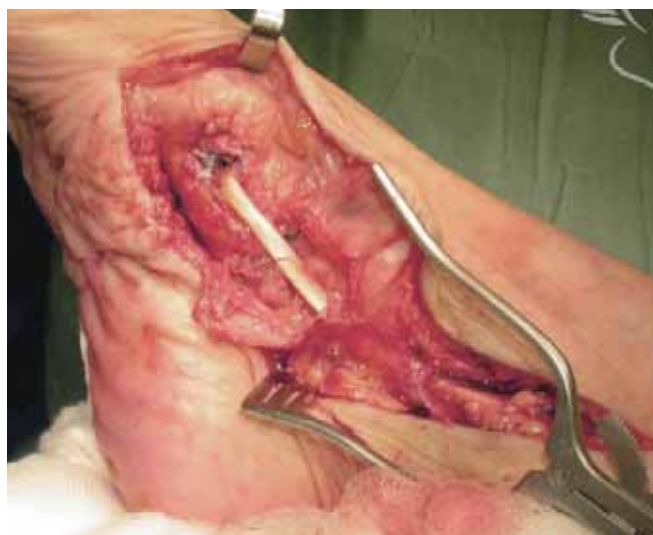

FIGURE 13.

walking boot. After three months, the patient is allowed to gradually discontinue the walking boot and begin unprotected ambulation. Patients are encouraged to begin range-of-motion exercises and are started on physical therapy for strengthening and balance.

Usually, 10-18 months are needed for maximum rehabilitation after the surgery. It is rare to have late failures of the FDL transfer and the functional results of the surgery appear to be durable.

## **SURGICAL ALTERNATIVES**

### *Lateral Column Lengthening*

Another option for patients presenting with stage two PTTD, peritalar subluxation, hindfoot valgus and pain at the distal fibula and lateral calcaneus, is a lateral column lengthening. This is often done through the calcaneocuboid joint with arthrodesis in conjunction with the FDL transfer and a spring ligament repair as described earlier. Iliac

Another option for patients presenting with stage two PTTD, peritalar subluxation, hindfoot valgus and pain at the distal fibula and lateral calcaneus, is a lateral column lengthening.

crest block autograft or structural allograft can be used to lengthen the lateral column.

Anteroposterior and lateral radiographs should be taken. These can show a loss of medial arch height, forefoot abduction, hindfoot valgus, and impingement of the fibula on the calcaneus.

The patient is positioned in supine with a “bump” under the ipsilateral hip to have better access to the lateral side of the foot. A thigh tourniquet is applied. A surgical prep is performed and the leg is draped up to the knee. Consideration must be taken to include concurrent draping of the ipsilateral iliac crest.

A skin incision is made over the calcaneocuboid joint. Care is taken to identify and preserve branches of the sural nerve. The extensor digitorum brevis muscle is reflected dorsally from its inferior margin. The peroneal tendons are retracted dorsally. A lamina spreader is inserted into the calcaneocuboid joint and the cartilage is removed from the joint using an osteotome, curettes, and rongeur. An osteotome may be used to shingle the subchondral bone. This is

when the subchondral bone is slightly raised up in multiple places in such a manner that it looks like shingles on a roof. This is thought to aid in the fusing of bone. Likewise, subchondral bone can also be prepared for fusion by using a 2.5-3.5 drill bit and drilling multiple holes.

A lamina spreader is placed in the joint and distraction is applied. Adduction of the forefoot and restoration of the medial longitudinal arch can be observed with this maneuver. Interoperatively, an anteroposterior image using fluoroscopy is used to assess the coverage of the talar head by the navicular. When the desired coverage is reached then a measurement of the distraction of the calcaneocuboid joint is taken. It usually ranges eight to 12mm.

From the ipsilateral hip, a tricortical graft is taken and contoured into a trapezoidal shape in order to create a wedge. This graft is impacted into place using a bone tamp. Further stabilization is achieved with the use of a small plate.

The iliac crest wound is irrigated and closed in layers with 0 polyglactin 910 , 2-0 polyglactin 910 and 3-0 nylon. The calcaneocuboid wound is irrigated and closed in layers with 2-0 polyglactin 910 and 3-0 nylon.

## **POSTOPERATIVE**

The bump is removed. The spring ligament repair and FDL transfer are

completed in the manner previously described with the foot held in supination by the assistant.

After the wounds are closed, a splint is applied maintaining supination of the foot. The postoperative care is followed as described in the previous procedure.

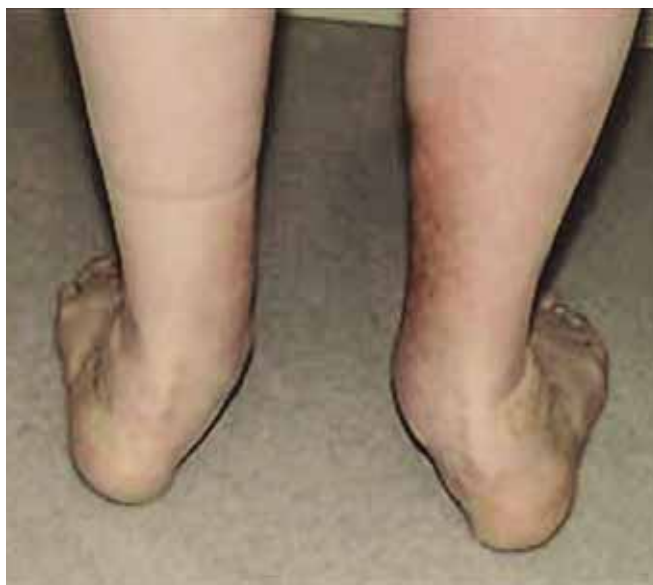### *Subtalar Arthrodesis*

There are some patients for whom the previously-described procedures are not an option due to the presence of arthritis in the subtalar joint or because the subtalar joint is fixed with the hindfoot in valgus. In such cases, a subtalar arthrodesis may be appropriate. It can be an applicable procedure when other hindfoot reconstruction operations have failed such as medial calcaneal osteotomy, posterior tibial tendon reconstruction with FDL transfer, or spring ligament repair.

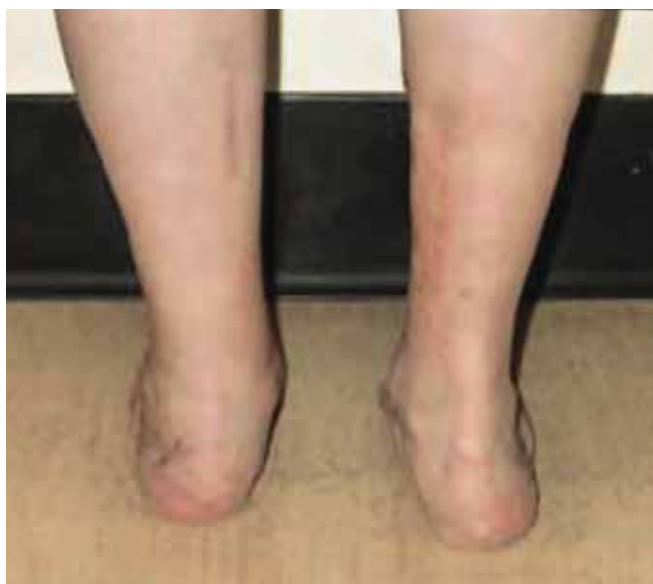Preoperative preparation includes radiographs like those outlined for the above-mentioned procedures.

For surgery, the patient is positioned supine with a “bump” under the ipsilateral hip in order to internally rotate the extremity. A thigh tourniquet is applied.





**BEFORE**



**AFTER**

After prepping and draping is complete and the tourniquet has been inflated, the incision is made starting at the tip of the lateral malleolus and continuing toward the base of the 4th metatarsal. The calcaneal attachment of the extensor digitorum brevis muscle is dissected to create a distally-based flap, allowing exposure to the calcaneocuboid joint. The peroneal tendons and sheath are retracted inferiorly. A lamina spreader is inserted into the sinus tarsi to aid exposure of the articular surfaces. Cartilage is removed using osteotomes, curettes, and ronguer until the subchondral bone is exposed. The subchondral bone is prepared for fusion using a 3.2 drill bit to drill multiple holes. A guide

wire from a 7.0 cannulated set is passed through a longitudinal incision in the heel through the posterior facet of the calcaneus into the talus, allowing for five to seven degrees of valgus. Using a depth gauge, a measurement is taken to determine the length of the screw to be placed. A cannulated drill bit is passed over the guide wire. A partially-threaded screw with a diameter of 7.0 mm having the length somewhat shorter to that shown on the depth gauge is inserted. The reason for using a shorter screw than what is shown on the depth gauge is to allow for compression of the fusion site without having the undesirable effect of the screw protruding.

When a screw is placed through the posterior facet into the talus, it is likely to have a thread length of 16mm due to the height of the talus. Conversely, a 32mm thread length can be used when the screw is placed dorsal to plantar through an incision over the talar neck due to the height of the calcaneus and the angle at which the screw is placed.

The stability is tested and fluoroscopy is used to do a final check on screw and hindfoot placement.

Bone graft may be taken from the proximal tibia using curettes and small osteotomes. If so, it is placed into the fusion site before insertion of the screws. The extensor digitorum brevis muscle is reapproximated over the bone graft and the wound is irrigated and closed in layers using 2-0 polyglactin 910 and 3-0 nylon.

#### **POSTOPERATIVE**

A splint is applied and the patient is made non-weight-bearing. After three weeks, the sutures are removed and a short-leg, non-weight-bearing cast is applied. A walking cast is applied at six to eight weeks postoperatively, and for an additional four to six weeks until evidence of arthrodesis union can be seen radiographically.

Foot and ankle rehabilitation starts after bone healing is complete and the final cast is removed. Patients can expect to have some swelling and aching for many months.

The success rate of this procedure is high for patients having PTTD and flatfoot; however, there are some patients who have more severe deformity and/or arthritis requiring a more extensive procedure such as a triple arthrodesis. Patients having a fixed hindfoot deformity, such as that resulting from posterior tibial tendon rupture with an acquired flat foot, as well as painful arthritis in the hindfoot and the tarsal joints, may need this procedure.



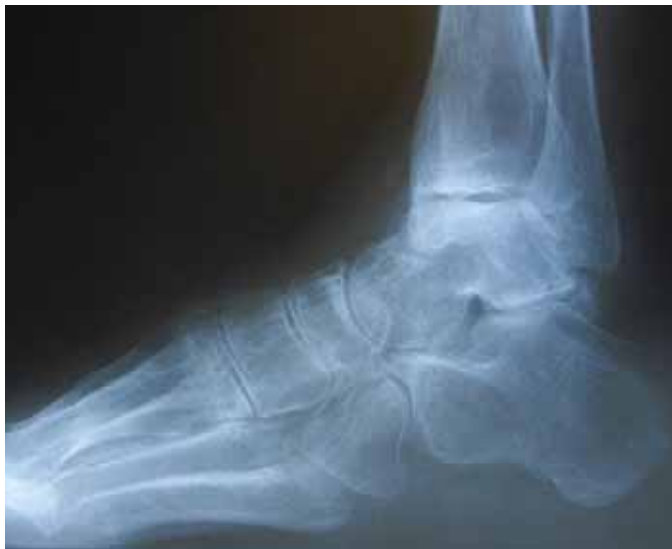

FIGURE 14.

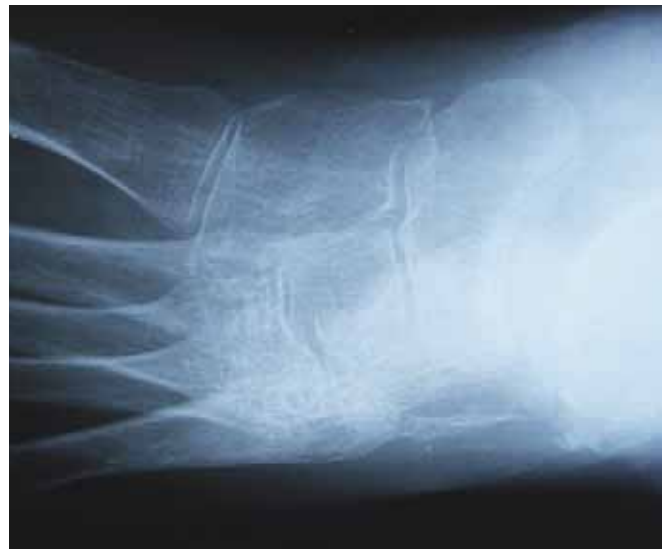

FIGURE 15.

### Triple Arthrodesis

A routine foot and ankle examination and radiographs should be done. These include weight-bearing anteroposterior foot, lateral foot and anteroposterior ankle views (Figures 14 & 15). Also useful are views of oblique foot and mortise of the ankle.

As GEA opened the door for better treatments in women's health, it also opened a door to more career choices for surgical technologists. The office-based procedure provides a different route of employment for surgically-trained personnel.

For surgery, the patient is positioned, prepped and draped in the same manner as with a subtalar arthrodesis.

The incision starts from the distal fibula and runs to the base of the 4th metatarsal. The subtalar joint is prepared as described previously. The calcaneocuboid joint is prepared next using osteotomes, curettes, and ronguer while it is held open with a lamina spreader. The next to be prepared is the talonavicular joint through an anteromedial incision at the level of the talar neck. It is prepared in the same fashion as the subtalar and the calcaneocuboid joints except that a toothless lamina spreader may be used to hold the joint open. With all three joints, the subchondral bone is drilled multiple times. Bone graft is placed in all the fusion sites prior to and following insertion of hardware. Can-

nulated screws are placed across the subtalar joint in the manner previously described. The talonavicular joint can be stabilized using cannulated or solid screws. The screw is placed at a shallow angle in the medial-lateral plane in a retrograde direction. It is important to countersink the entrance hole in the navicular in order to not break the bridge of bone as the screw is tightened. It is important to be sure to hold the talonavicular joint in a reduced position so as to restore the medial longitudinal arch and obtain the correct balance of adduction-abduction and varus-valgus.

The calcaneocuboid joint is stabilized similarly. The screw is placed from the anterior process of the calcaneus into the cuboid (Figures 16 & 17).

Another approach that is used in fusing the talonavicular and calcaneocuboid joints is the use of compression plates. This technique is accomplished with plates that allow one to two screws being placed through the plate that spans the joint. Once the screws are placed, the plate is spread open causing compression of the joint (Figure 18). Even though this is not as common a technique as the one previously described, it's known to be used with a good post-operative result.



FIGURE 18.

Figures 16, ©Integra LifeSciences Corporation 2009. Reprinted with permission.

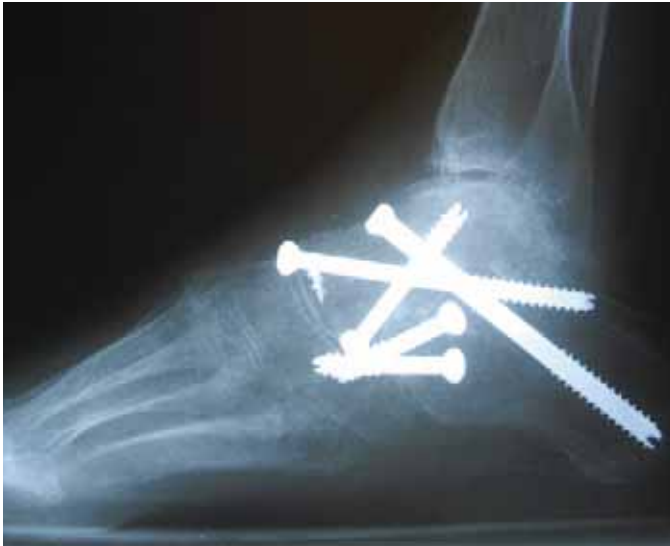

FIGURE 16.

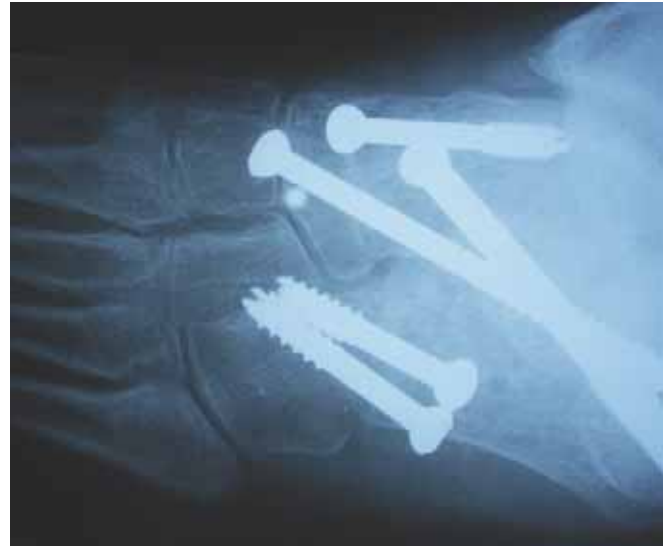

FIGURE 17.

Figures 14-17: Courtesy of James Brasky, MD

Fluoroscopy is used to check fixation placement and alignment. The extensor digitorum brevis muscle is reapproximated using 0 polyglactin 910 . The wound is irrigated and closed in layers using 2-0 polyglactin 910 and 3-0 nylon. A bulky splint is applied to allow for swelling.

**POSTOPERATIVE**

At the first follow-up visit, the splint and sutures are removed. A short leg cast is applied. The patient is to remain non-weight-bearing for six weeks following surgery. At six weeks, if the fusion sites have healed and there is no tenderness in those areas, the patient is allowed to wear shoes and increase activities as tolerated.

There are some possible complications of attempted arthrodesis, including nonunion of the talonavicular joint, occurring in 5-10 percent in most of the reported series in literature. This can be decreased with care in meticulous removal of cartilage and fibrotic bone. Also, the use of cancellous autograft can improve fusion rates. There is a risk for malalignment, usually occurring at the time of surgery. Careful alignment of the joints at the time of surgery helps to avoid malalignment.

**CONCLUSION**


Whenever possible, it is best to do motion-sparing procedures, as described earlier in this article as a first option. As long as there is no painful arthritis or lack of mobility in the hindfoot or tarsals, procedures such as medial displacement calcaneal osteotomy with FDL transfer or lateral column lengthening are motion-sparing and more

often preferred. Subtalar arthrodesis and triple arthrodesis should be reserved for patients having painful arthritis or fixed flatfoot with PTTD. It is also useful to reserve them as a secondary option for salvage procedures when the above-mentioned fail.

**ABOUT THE AUTHOR**

Angela Webb, CST, attended Career West Academy in California, where she majored in surgical technology. After completing her clinical training in Texas, in 1995, she worked at Baylor University Medical Center as a Certified Surgical Technologist. Ms Webb has specialized in orthopaedics for 12 years, focusing primarily on foot and ankle procedures, as well as shoulders. She currently works full-time at Mary Shiels Hospital in Dallas.





**Earn CE Credits at Home**

You will be awarded continuing education (CE) credit(s) for recertification after reading the designated article and completing the exam with a score of 70% or better.

If you are a current AST member and are certified, credit earned through completion of the CE exam will automatically be recorded in your file—you do not have to submit a CE reporting form. A printout of all the CE credits you have earned, including Journal CE credits, will be mailed to you in the first quarter following the end of the calendar year. You may check the status of your CE record with AST at any time.

If you are not an AST member or are not certified, you will be notified by mail when Journal credits are submitted, but your credits will not be recorded in AST's files.

Detach or photocopy the answer block, include your check or money order made payable to AST, and send it to Member Services, AST, 6 West Dry Creek Circle, Suite 200, Littleton, CO 80120-8031.

**Members: \$6, nonmembers: \$10**

# Acquired Adult Flatfoot Deformity

316 APRIL 2010 1 CE credit

1. The talonavicular joint is located \_\_\_\_\_.
  - a. Between the talus and navicular
  - b. On the anterolateral midfoot
  - c. On the dorsal foot, below the ankle
  - d. a & c
2. Attaching the posterior tibial tendon to the transferred FDL is called \_\_\_\_\_.
  - a. Midfoot dissection
  - b. Tenodesis
  - c. Spring ligament repair
  - d. Ligament fixation
3. Surgical procedures to correct flatfoot include \_\_\_\_\_.
  - a. Spring ligament reconstruction
  - b. Triple arthrodesis
  - c. Subtalar arthrodesis
  - d. All of the above
4. Weight-bearing radiographs should be taken \_\_\_\_\_.
  - a. Preoperatively
  - b. Postoperatively
  - c. At the surgeon's discretion
  - d. Only when screws are used
5. The most common cause of adult-acquired flatfoot is \_\_\_\_\_.
  - a. Lateral hindfoot pain
  - b. Navicular tuberosity
  - c. Posterior tibial tendon dysfunction
  - d. Achilles tendonitis
6. The \_\_\_\_\_ can be used to replace the posterior tibial tendon.
  - a. Achilles tendon
  - b. FDL tendon
  - c. Peroneal tendon
  - d. None of the above
7. \_\_\_\_\_ can be used to lengthen the lateral column in this surgical alternative.
  - a. Iliac crest block autograft
  - b. Structural allograft
  - c. FDL transfer
  - d. a & b
8. Varying degrees of flatfoot are present in \_\_\_\_\_ percent of the population.
  - a. 10-25
  - b. 15-30
  - c. More than 50
  - d. Unknown
9. In the lateral column lengthening procedure, the "bump" under the ipsilateral hip provides \_\_\_\_\_.
  - a. Support for the hip
  - b. Relief of a bony pressure point
  - c. Better access to the lateral side of the foot
  - d. Stability for the thigh
10. Patients with painful arthritis or fixed flatfoot with PTTD are usually best served with \_\_\_\_\_.
  - a. Motion-sparing procedures
  - b. Subtalar arthrodesis
  - c. Triple arthrodesis
  - d. b & c

**ACQUIRED ADULT FLATFOOT DEFORMITY 316 APRIL 2010 1 CE credit**

NBSTSA Certification No. \_\_\_\_\_

AST Member No. \_\_\_\_\_

My address has changed. The address below is the new address.

Name \_\_\_\_\_

Address \_\_\_\_\_

City \_\_\_\_\_ State \_\_\_\_\_ Zip \_\_\_\_\_

Telephone \_\_\_\_\_

	a	b	c	d		a	b	c	d
1	<input type="checkbox"/>	<input type="checkbox"/>	<input type="checkbox"/>	<input type="checkbox"/>	6	<input type="checkbox"/>	<input type="checkbox"/>	<input type="checkbox"/>	<input type="checkbox"/>
2	<input type="checkbox"/>	<input type="checkbox"/>	<input type="checkbox"/>	<input type="checkbox"/>	7	<input type="checkbox"/>	<input type="checkbox"/>	<input type="checkbox"/>	<input type="checkbox"/>
3	<input type="checkbox"/>	<input type="checkbox"/>	<input type="checkbox"/>	<input type="checkbox"/>	8	<input type="checkbox"/>	<input type="checkbox"/>	<input type="checkbox"/>	<input type="checkbox"/>
4	<input type="checkbox"/>	<input type="checkbox"/>	<input type="checkbox"/>	<input type="checkbox"/>	9	<input type="checkbox"/>	<input type="checkbox"/>	<input type="checkbox"/>	<input type="checkbox"/>
5	<input type="checkbox"/>	<input type="checkbox"/>	<input type="checkbox"/>	<input type="checkbox"/>	10	<input type="checkbox"/>	<input type="checkbox"/>	<input type="checkbox"/>	<input type="checkbox"/>

Mark one box next to each number. Only one correct or best answer can be selected for each question.