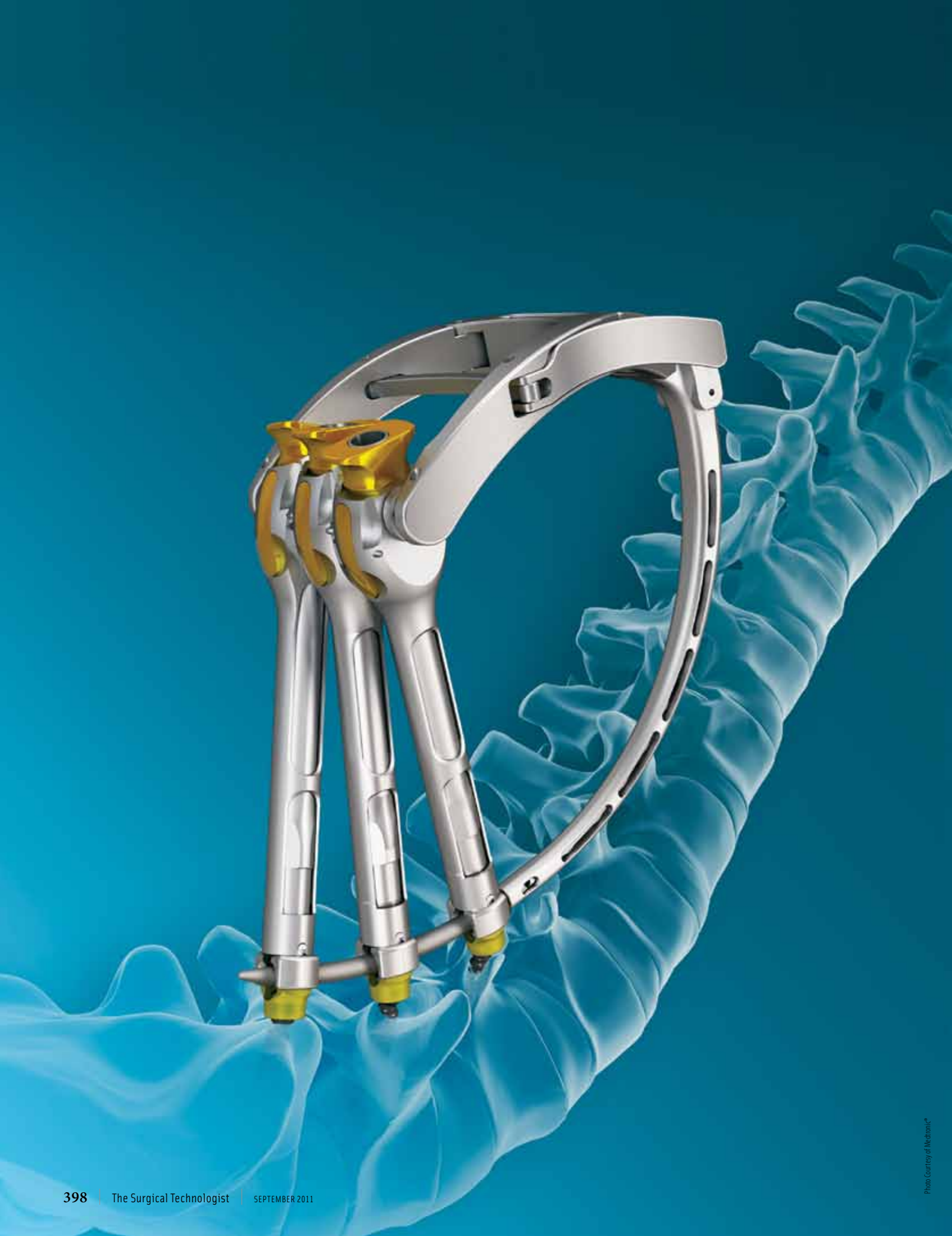



# Minimally Invasive POSTERIOR SPINAL FUSION

by Richard L Demko, CST

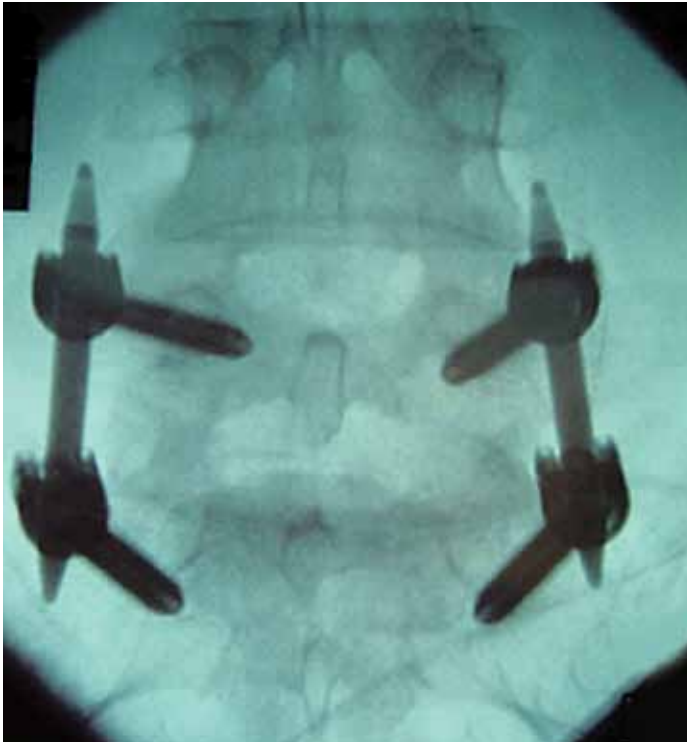**T**he CD Horizon® Sextant™ procedure is a relatively new advancement in the treatment of degenerative disc disease and other spinal instabilities. When used along with the CD Horizon® Minimal Exposure Tubular Retractor system (METRIX™), it gives the option to use the incisional technique by reducing the amount of dissection and exposure needed to perform a traditional spinal fusion. Unlike the open, invasive approach that requires a 6- to 8-inch incision and extensive exposure, this minimally invasive approach only requires 18mm stab incisions and gradual soft tissue and muscle dilatation to access the spine and its related structures.<sup>2</sup> The cosmetic outcome is similar to that of a laparoscopy, and the patient's postoperative pain, recovery time and hospital stay is greatly reduced.

## HISTORY OF THE SEXTANT™ & METRIX™ TECHNIQUE

The Sextant™ procedure was developed in 2000 by neurosurgeon Kevin Foley, MD, at Methodist University Hospital, in Memphis, Tennessee.<sup>1</sup> The procedure was developed to facilitate the percutaneous placement of pedicle screws and stabilization rods under fluoroscopic imaging. The Minimal Exposure Tubular Retractor (METRIX™) system was developed in 1995 by Gary K Michelson, MD<sup>3</sup>, and allows surgeons to perform a microdiscectomy, decompressive laminectomy and intervertebral body fusion using an operative microscope or high powered loupes through bilateral 12 to 18mm ports. By combining the two technologies, it gave birth to a completely minimally invasive procedure and opened new doors into the future of posterior lumbar spinal fusions.

## LEARNING OBJECTIVES

- ▲ Examine how this minimally invasive procedure reduces recovery time and postoperative pain
- ▲ Analyze how the decompressive laminectomy is performed
- ▲ Learn what instruments and equipment are necessary for minimally invasive posterior spinal fusion
- ▲ List the complications associated with this surgery
- ▲ Assess the future of posterior lumbar spinal fusions



*AP Lateral C-Arm Retractor Post*

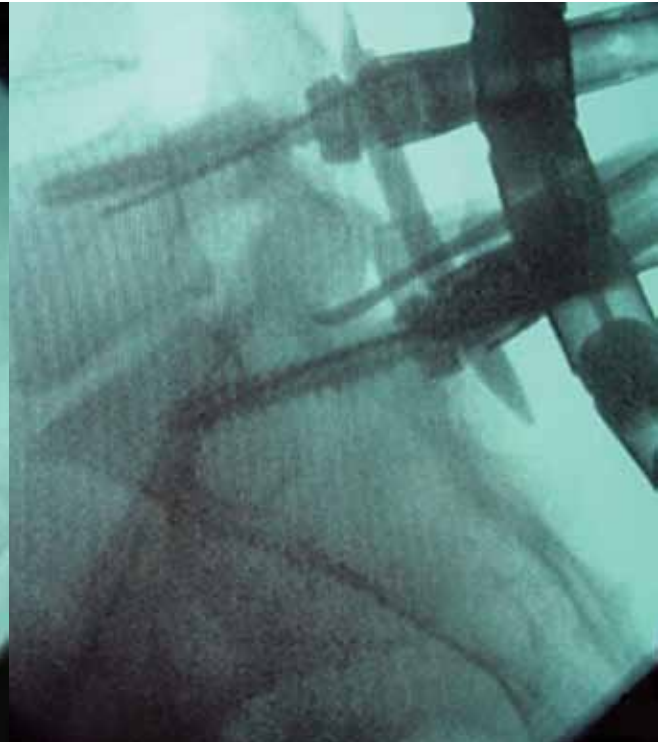


Photo Courtesy of John Awad, MD

### CANDIDATES FOR THE MINIMALLY INVASIVE PROCEDURE

The most common indication for the minimally invasive procedure is severe disc degeneration. Other indications include recurrent disc herniation, spondylolisthesis (misaligned vertebrae) or traumatic fracture. The procedure is indicated for patients that require single to multi-level fusions.<sup>2</sup>

### INSTRUMENTATION AND EQUIPMENT

The set contains pedicle screws ranging from 4.5mm to as wide as 8.5mm diameter that attach to threaded, cannulated screwdrivers. Screw lengths range from 30mm to 60mm increasing in increments of 5mm. The screwdrivers double as a compressor/distracter and rod reducer allowing the placement of the stabilization rods with the rod introducer. The set also contains locking caps to keep the rod affixed to the pedicle screw. Included in the set are various diameter dilation tubes that spread the tissue to create a working channel down to the lamina. Most surgeons prefer to insert the MAST Quadrant™ retractor after dilation to allow for a larger field of vision. The retractor attaches to the Jackson table using a table post connected to an adjustable arm. A disposable light ring to facilitate better viewing in

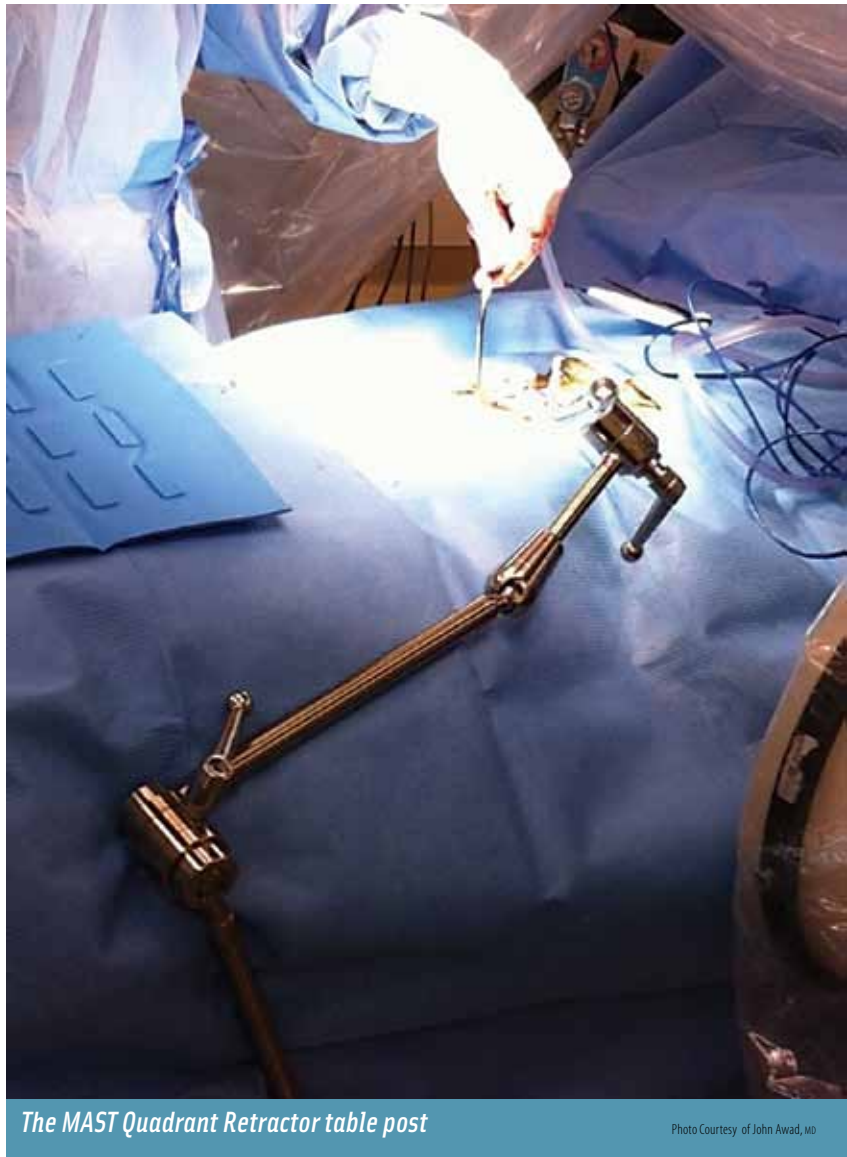the wound attaches to the retractor, thus a light source and light cable is required. The working instruments are similar to traditional spinal fusion instruments with the exception that they are longer and bayoneted to allow easier access to and visualization of the spine through the dilation tubes or retractor system. Since the procedure requires anterior, posterior and lateral imaging, two fluoroscopy machines are needed along with lead X-ray aprons and thyroid shields.

The working instruments are similar to traditional spinal fusion instruments with the exception that they are longer and bayoneted to allow easier access to and visualization of the spine through the dilation tubes or retractor system.

Some surgeons prefer to use an operating microscope instead of loupes. The standard electro-surgery and bipolar machines also are needed. Based on the surgeon's preference, a nitrogen-powered high-speed burr may be required.

### PATIENT PREP AND POSITIONING

The patient is transported in to the operating room on a gurney and the first part of the World Health Organization (WHO) safety checklist is performed by the surgical team. Once the correct patient, surgical site, allergies and procedure are verified, the patient is anesthetized on the gurney in the supine position. When induction is complete, a Foley catheter is inserted. After catheterization, the neuro-monitoring technician inserts electrodes into various nerves and muscles of the arms and legs to monitor the neurological function of the patient during the procedure. The neuro-monitoring technician establishes a baseline electromyogram and the patient is ready to be positioned. With the help of the OR staff, the patient is placed on the Jackson table in the prone position. The hips, knees, chest and any other bony prominences are padded to prevent pressure ulcers. Any hair around the operative site is removed. Both fluoroscopy machines are set up at this time. The first machine images the lateral lumbar spine and the second machine images the anterior/posterior lumbar spine. The fluoroscopy machines are positioned and scout images of the spine are taken to verify their levels before operation. Once the levels are verified, the surgeon marks the skin where the pedicles are located. The patient is then ready to be prepped and draped. The skin prep is performed in a customary manner using a prep solution of the surgeons' choice. The surgical team is gowned and gloved and the drapes are applied. This is done using four square towels, a  $\frac{3}{4}$  sheet and a long transverse laparotomy drape. The electro-surgical pencil cord, bipolar cord, light cable and suction tubings are handed off the field for the circulator to hook up. Both C-arms of the imaging machines are draped with full C-arm drapes and the time out is performed along with the second part of the



The MAST Quadrant Retractor table post

Photo Courtesy of John Awad, MD

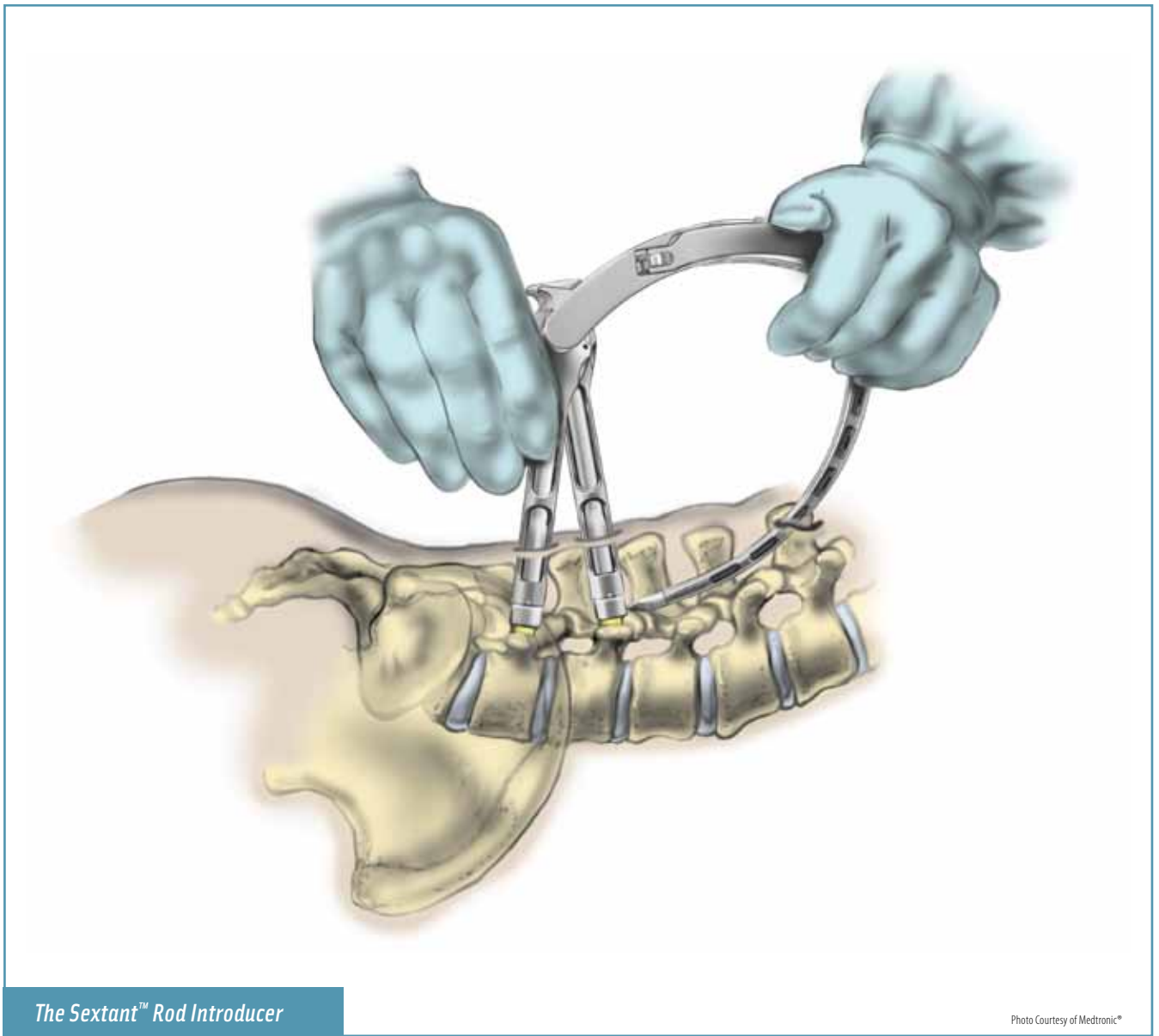
WHO safety checklist. The field is now set for the start of the procedure.

### PROCEDURE

*(Since the minimally invasive procedure is indicated for single and multi-level lumbar fusions, a single level fusion of L3-L4 will be used as the focus of study for the procedural part of this article).*

The surgeon injects 1% lidocaine with epinephrine 1:200,000 into the skin and subcutaneous tissues above the left and right L3-L4 pedicles to provide hemostasis. Using an 11 blade, a stab incision is made into the skin and the soft tissue is dissected using a tonsil clamp. A threaded guidewire is manually inserted into the pedicle using fluoroscopic guidance. Once the guidewire is in place, the sur-





*The Sextant™ Rod Introducer*

Photo Courtesy of Medtronic®

geon inserts a series of muscle-splitting dilators to create a wider field of view down to the pedicle. The incision is retracted using a tubular sheath to create the working port. Once the tissues are dilated and retracted, a sharp, cannulated tap is placed over the guidewire to prepare the pedicle for screw insertion. Using a long ball probe, the surgeon checks the hole that was taped to ensure that the lateral wall of the pedicle is still intact. A measurement is taken from the ball probe to determine the length of the screw needed. The surgical technologist loads the appropriate length screw on the threaded screwdriver and hands it to the surgeon for insertion. With the screw in place, a neurostimulator probe is used to check that the nerve root was undisturbed. The

surgeon repeats the percutaneous screw insertion process for the remaining three pedicles. The surgeon removes the guidewires, but leaves the cannulated screwdrivers in place, which are attached to the screws, so they can be used to introduce the rod and distract the disc space later in the procedure. With all the pedicle screws in place, the next step is to perform a decompressive laminectomy. A stab incision is made in the skin 5mm off the midline on the left side of the spine. The soft tissue is dissected with a tonsil clamp. A threaded guidewire is inserted and advanced down to the edge of the lamina under fluoroscopic imaging. Once the guidewire is in place, the surgeon inserts the muscle-splitting dilators to create a working port down to

The discectomy will start on the side that is giving the patient the most pain, and will be done through the existing working port used for the laminectomy.

the lamina. If the MAST Quadrant™ retractor is used, the surgeon inserts the retractor blades and affixes them to an adjustable arm connected to a table post. The table post is attached to the Jackson table with the help of the circulator. With the retractor in place, the surgeon may wish to use the disposable light ring to enhance visualization of the spine. Using an angled curette, the surgeon removes small portions of bone from the lamina to gain entrance to the spinal canal. Once the spinal canal is reached with the curette, a 2mm Kerrison rongeur is used to remove the lamina that is compressing the spinal cord and nerve root. Using various dissectors, the surgeon probes the edge of the lamina to check for bone fragments and osteophytes. If found, these are removed using a 3mm or 4mm Kerrison rongeur and/or a high speed cutting burr. The surgeon is careful not to disrupt the nerve root during this process.

When the laminectomy is complete on the left side of

the spine, the process is repeated on the right side. Once the spinal cord is decompressed, the surgeon prepares to insert the rods using the rod introducer. Using a caliper that attaches to the retained screwdrivers, the distance between the L3 and L4 pedicle is measured and the proper rod length is selected. The surgical technologist then loads a sharp cutting trocar to the rod introducer. The introducer is attached to the screwdrivers and a stab incision is made at the entry point of the skin where the trocar will be pushed through. The surgeon advances the trocar through the tissues to create a path for the rod. The trocar is then removed from the inserter and the proper length rod is attached. The rod is advanced through the tissues and is positioned between the pedicle screws until the rod is properly seated. When satisfied with the placement of the rod, the surgeon and assistant distract the disc space by pulling the two screwdrivers apart. Locking caps are advanced down the cannula of the screwdriver and are placed on the pedicle screws to secure the rod. This process is repeated for the right side L3 and L4 screws. By distracting the pedicles, it allows the surgeon to access the disc space to remove the degenerative disc and insert an intervertebral body cage or bone graft. Before starting the discectomy, an anterior/posterior and lateral fluoroscopic image is taken to ensure the proper placement of the pedicle screws and to verify that the rod is seated in the saddle of the screw with the locking caps firmly attached. The discectomy will start on the side that is giving the patient the most pain, and will be done through the existing working port used for the laminectomy. A suction nerve root retractor is inserted into the spinal canal

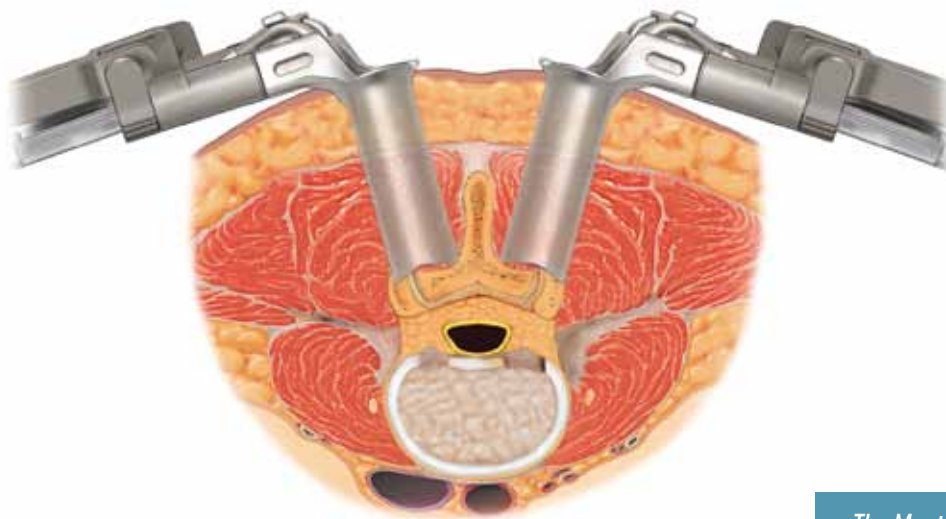


Photo Courtesy of Medtronic®

*The Mast Quadrant™ Retractor*

Within 3 to 4 hours after the procedure, the patient is encouraged to ambulate to aid in the recovery process. Typically with an uneventful procedure, the patient can return home within 24 to 48 hours and can resume normal activity within 3 days of discharge.<sup>2</sup>

to gently retract the spinal cord and allow the surgeon to visualize the disc. Using an 11 blade knife on a bayoneted handle, the surgeon makes an incision into the annulus of the disc. Using various serrated curettes and pituitary rongeurs, the disc is removed. To determine the size of the graft needed to replace the disc, the surgeon inserts a series of trials until the trial sits snug between the top and bottom vertebral end plates. The graft is introduced to the field by the circulator and the surgical technologist loads the graft on the inserter. Some surgeons prefer to place a synthetic bone substitute in the center of the graft prior to insertion to assist in the intervertebral body fusion. Using a mallet, the graft is taped in place and advanced down the disc space using a graft impactor. After the graft is in place, the locking caps keeping the disc space distracted on the rods are loosened, and the surgeon and assistant pull the screwdrivers together. This is done to compress the disc space and keep the graft in place. Once compressed, the locking caps are tightened and a final torque driver is used to ensure the rods are secured to the pedicle screws. The surgeon will then insert a mixture of an osteoenerative protein and bone chips along the lateral gutters of the posterior spinous process. This is done so the patient will generate bone growth aiding in the fusion of the two vertebral bodies. Prior to removing the retractors and screwdrivers, the neuro-stimulator is again introduced into the incisions to verify that the nerve roots and spinal cord were not compromised during the procedure. Final fluoroscopic images are taken to verify the screws, rods and intervertebral grafts are properly in place.

## CLOSURE

The surgical technologist and circulator perform a sponge, needle and cotton patty count. Instruments are counted based on the hospital's policy for percutaneous cases. Once the counts are correct, the retractors and screwdrivers are removed from the wound. The wound is closed with interrupted 0 polyglactin suture on a tapered needle to approximate the deep layers of tissue. The superficial layers are closed with interrupted 2-0 polyglactin suture also on a tapered needle. The subcutaneous tissue is closed with running 4-0 polyglactin on a cutting needle and the skin is approximated using either wound closure strips or a tissue adhesive. Some surgeons prefer to close the skin with a 4-0 nylon suture. If this is to be done, generally the 4-0 polyglactin subcutaneous stitch is omitted. The dressings generally consist of small adhesive bandages. When the closure is complete and the final sponge, needle and cotton patty count are done, the third part of the WHO checklist is completed. The OR staff then returns the patient to the gurney from the Jackson table and the neuro-monitoring leads are removed. The patient is then extubated and transported to the Post Anesthesia Care Unit (PACU).

## RECOVERY

The patient will spend a few hours in the PACU before being transported to the surgical floor of the hospital. Within 3 to 4 hours after the procedure, the patient is encouraged to ambulate to aid in the recovery process. Typically with an uneventful procedure, the patient can return home within 24 to 48 hours and can resume normal activity within 3 days of discharge.<sup>2</sup>

There are several complications that may occur to lengthen the patient's hospital stay. The most common complication of minimally invasive spinal fusions is a dural tear caused during the decompressive laminectomy. Most dural tears can be repaired through the working port, but in some cases the surgeon may have to convert to an open procedure to repair the defect. In this event the patient will spend more time in recovery, and will not be able to immediately return to normal activity. Other complications can include breaches in the pedicle wall, causing the screw to disrupt the spinal cord and/or nerve root; misplacement of the pedicle screw, causing instability of the fusion; hematomas; paralysis; foot drop; and surgical site infection.<sup>4</sup>

## CONCLUSION

With the breakthrough of this minimally invasive technique, patients can return to an active life style within a fraction of the amount of time it takes one to recover from a traditional open spinal fusion. Blood loss is minimal, muscle and tissue is preserved causing less postoperative pain, time spent in the hospital recovering is significantly reduced and the improved cosmetic outcome make this minimally invasive approach more attractive to patients who are candidates for a spinal fusion.




## ABOUT THE AUTHOR

Richard L. Demko, CST, graduated from the surgical technology program at Bridgeport Hospital School of Nursing, in Bridgeport, Connecticut. He completed his clinical rotation at Yale New Haven Hospital where his primary focus was in neuro-spinal and neuro-cranial procedures. He is an active member of AST and the Connecticut General Assembly of Surgical Technologists. Richard was recently elected to the Connecticut AST Board of Directors and serves as the chairman of the Government Affairs Committee. He is currently working at Saint Vincent's Medical Center and serves as a section leader for the spinal surgery service.

## REFERENCES

1. Back and Spine Surgery. Methodist Health Care. 2006. Accessed October 10, 2010. <http://www.methodisthealth.org/methodist/Healthcare+Services/Back+%26+Spine/Back+%26+Spine+Surgery>
2. CDHORIZON®SEXTANT™ FactSheet. Medtronic. 2010. Accessed October 9, 2010. [http://wwwp.medtronic.com/Newsroom/LinkedItemDetails.do?itemId=1101756222541&itemType=fact\\_sheet&lang=en\\_US](http://wwwp.medtronic.com/Newsroom/LinkedItemDetails.do?itemId=1101756222541&itemType=fact_sheet&lang=en_US)
3. "Medtronic Introduces CD HORIZON SEXTANT II; System Provides Improved Instrumentation for Stabilization in Spinal Fusion; Minimally Invasive System Helps Save Muscle Tissue and Reduces Recovery Time." Business Wire. 2005. Accessed October 13, 2010. <http://www.highbeam.com/doc/1G1-136893177.html>
4. Villavicencio AT, Burneikiene S, Roeca CM, Nelson EL, Mason A. Minimally invasive versus open transforaminal lumbar interbody fusion. *Surg Neurol Int.* 2010;1(12). Accessed October 13, 2010. <http://www.surgicalneurologyint.com/text.asp?2010/1/1/12/63905>



## Earn CE Credits at Home

You will be awarded continuing education (CE) credits toward your recertification after reading the designated article and completing the test with a score of 70% or better. If you do not pass the test, it will be returned along with your payment.

Send the original answer sheet from the journal and make a copy for your records. If possible use a credit card (debit or credit) for payment. It is a faster option for processing of credits and offers more flexibility for correct payment. When submitting multiple tests, you do not need to submit a separate check for each journal test. You may submit multiple journal tests with one check or money order.

**Members this test is also available online** at [www.ast.org](http://www.ast.org). No stamps or checks and post to your record automatically!

**Members: \$6 per credit**  
(per credit not per test)

**Nonmembers: \$10 per credit**  
(per credit not per test plus the \$400 nonmember fee per submission)

After your credits are processed, AST will send you a letter acknowledging the number of credits that were accepted. Members can also check your CE credit status online with your login information at [www.ast.org](http://www.ast.org).

## 3 WAYS TO SUBMIT YOUR CE CREDITS

**Mail to:** AST, Member Services, 6 West Dry Creek Circle Ste 200, Littleton, CO 80120-8031

**Fax CE credits to:** 303-694-9169

**E-mail scanned CE credits in PDF format to:** [memserv@ast.org](mailto:memserv@ast.org)

For questions please contact Member Services - [memserv@ast.org](mailto:memserv@ast.org) or 800-637-7433, option 3. Business hours: Mon-Fri, 8:00a.m. - 4:30 p.m., mountain time



# Minimally Invasive Posterior Spinal Fusion

333 SEPTEMBER 2011 1 CE credit

1. The CD Horizon® Sextant™ procedure is a new advancement in the treatment of \_\_\_\_\_.
  - a. Degenerative disc disease
  - b. Spinal instabilities
  - c. Heart transplants
  - d. Both a and b
2. This minimally invasive procedure requires patients to have single to multi-level \_\_\_\_\_.
  - a. Fusions
  - b. Weak screws
  - c. Degenerations
  - d. Bone slips
3. Once the tissues are dilated and retracted, a sharp, cannulated tap is placed over the \_\_\_\_\_ to prepare the pedicle for screw insertion.
  - a. Infuser
  - b. Guidewire
  - c. Mayo stand
  - d. Screwdriver
4. During the procedure, the surgeon inserts a mixture of \_\_\_\_\_ and bone chips along the lateral gutters of the posterior spinous process.
  - a. Lidocaine
  - b. Epinephrine
  - c. Osteogenerative protein
  - d. Tissue
5. Using a(n) \_\_\_\_\_, the surgeon removes small portions of bone from the lamina to gain entrance to the spinal canal.
  - a. Neuro-simulator
  - b. Angled curette
  - c. Guidewire
  - d. All of the above
6. Within \_\_\_\_\_ hours after the procedure, the patient is encouraged to ambulate to aid in the recovery process.
  - a. 6 to 12
  - b. 1 to 2
  - c. 24 to 48
  - d. 3 to 4
7. The most common complication of minimally invasive spinal fusions is a \_\_\_\_\_.
  - a. Dural tear
  - b. Bleeding
  - c. Discharge
  - d. Posterior discomfort
8. This minimally invasive approach is more attractive to patients who are candidates for spinal fusion because there is less \_\_\_\_\_.
  - a. Blood loss
  - b. Postoperative Pain
  - c. Recovery Time
  - d. All of the above
9. Using a(n) \_\_\_\_\_ on a bayoneted handle, the surgeon makes an incision into the annulus of the disc.
  - a. Screwdriver
  - b. 11 blade knife
  - c. 15 blade knife
  - d. Neuro-simulator
10. The fluoroscopy machines image the \_\_\_\_\_ and the \_\_\_\_\_.
  - a. Lateral lumbar spine and the stab incisions
  - b. Anterior/posterior lumbar spine and the annulus
  - c. Lateral lumbar spine and anterior/posterior lumbar spine
  - d. None of the above

## MINIMALLY INVASIVE POSTERIOR SPINAL FUSION 333 SEPTEMBER 2011 1 CE credit

NBSTSA Certification No. \_\_\_\_\_

AST Member No. \_\_\_\_\_

My address has changed. The address below is the new address.

Name \_\_\_\_\_

Address \_\_\_\_\_

City \_\_\_\_\_ State \_\_\_\_\_ Zip \_\_\_\_\_

Telephone \_\_\_\_\_

Check enclosed  Check Number \_\_\_\_\_

Visa  MasterCard  American Express

Credit Card Number \_\_\_\_\_

Expiration Date \_\_\_\_\_

	a	b	c	d		a	b	c	d
1	<input type="checkbox"/>	<input type="checkbox"/>	<input type="checkbox"/>	<input type="checkbox"/>	6	<input type="checkbox"/>	<input type="checkbox"/>	<input type="checkbox"/>	<input type="checkbox"/>
2	<input type="checkbox"/>	<input type="checkbox"/>	<input type="checkbox"/>	<input type="checkbox"/>	7	<input type="checkbox"/>	<input type="checkbox"/>	<input type="checkbox"/>	<input type="checkbox"/>
3	<input type="checkbox"/>	<input type="checkbox"/>	<input type="checkbox"/>	<input type="checkbox"/>	8	<input type="checkbox"/>	<input type="checkbox"/>	<input type="checkbox"/>	<input type="checkbox"/>
4	<input type="checkbox"/>	<input type="checkbox"/>	<input type="checkbox"/>	<input type="checkbox"/>	9	<input type="checkbox"/>	<input type="checkbox"/>	<input type="checkbox"/>	<input type="checkbox"/>
5	<input type="checkbox"/>	<input type="checkbox"/>	<input type="checkbox"/>	<input type="checkbox"/>	10	<input type="checkbox"/>	<input type="checkbox"/>	<input type="checkbox"/>	<input type="checkbox"/>

Mark one box next to each number.  
Only one correct or best answer can be selected for each question.