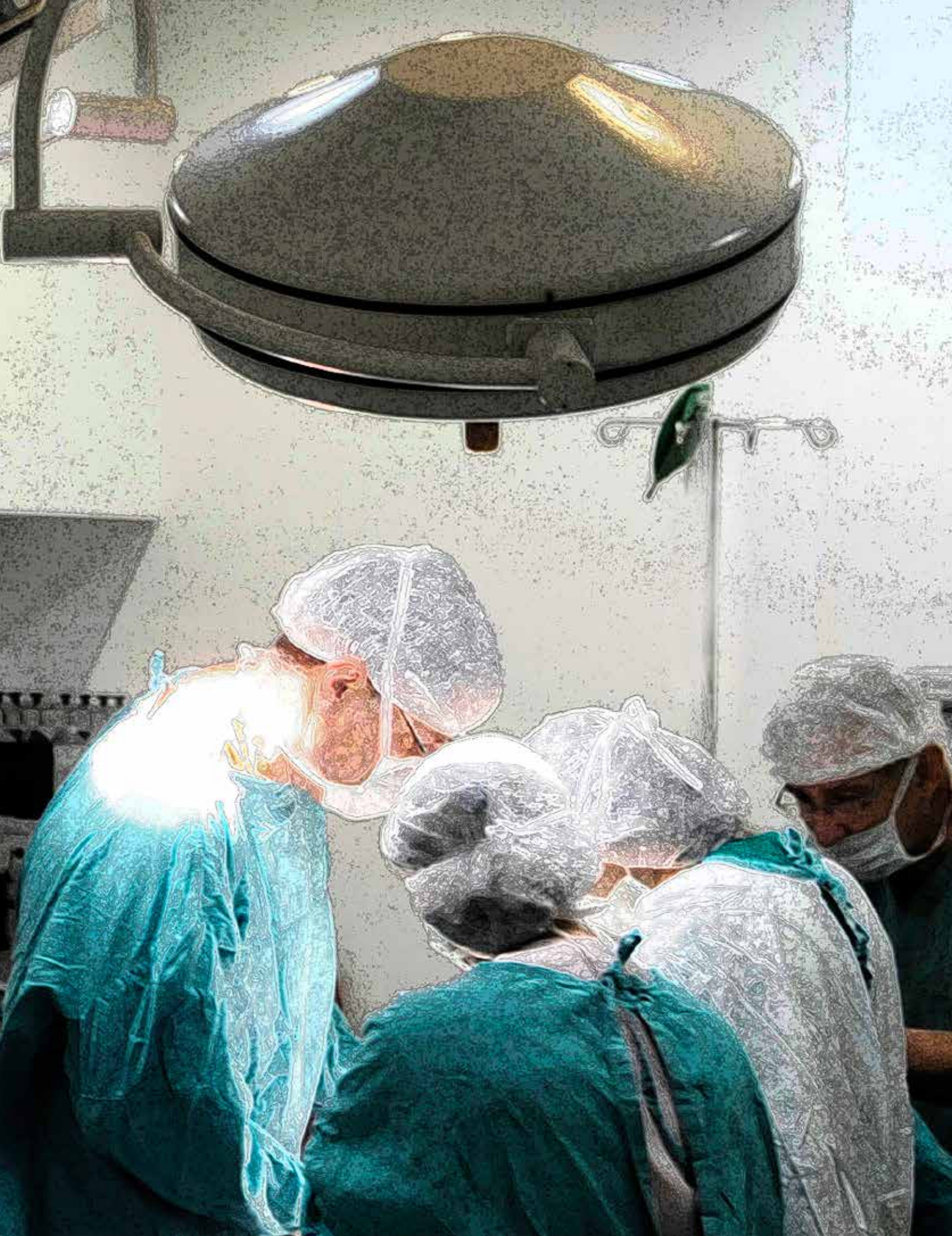



Left Ureteral Reimplantation

MANUELA SHARBER, CST

A left ureteral reimplantation procedure is done to treat the reflux in the urinary system that is caused by duplication within the same ureteral sheath. This condition can be presented on either the left or the right side of the body, but in this case it was presented only on the left. The approach for this case was an open approach through a Pfannenstiel incision in the lower abdomen. Recovery time for the patient is usually quick even though it is an invasive procedure.

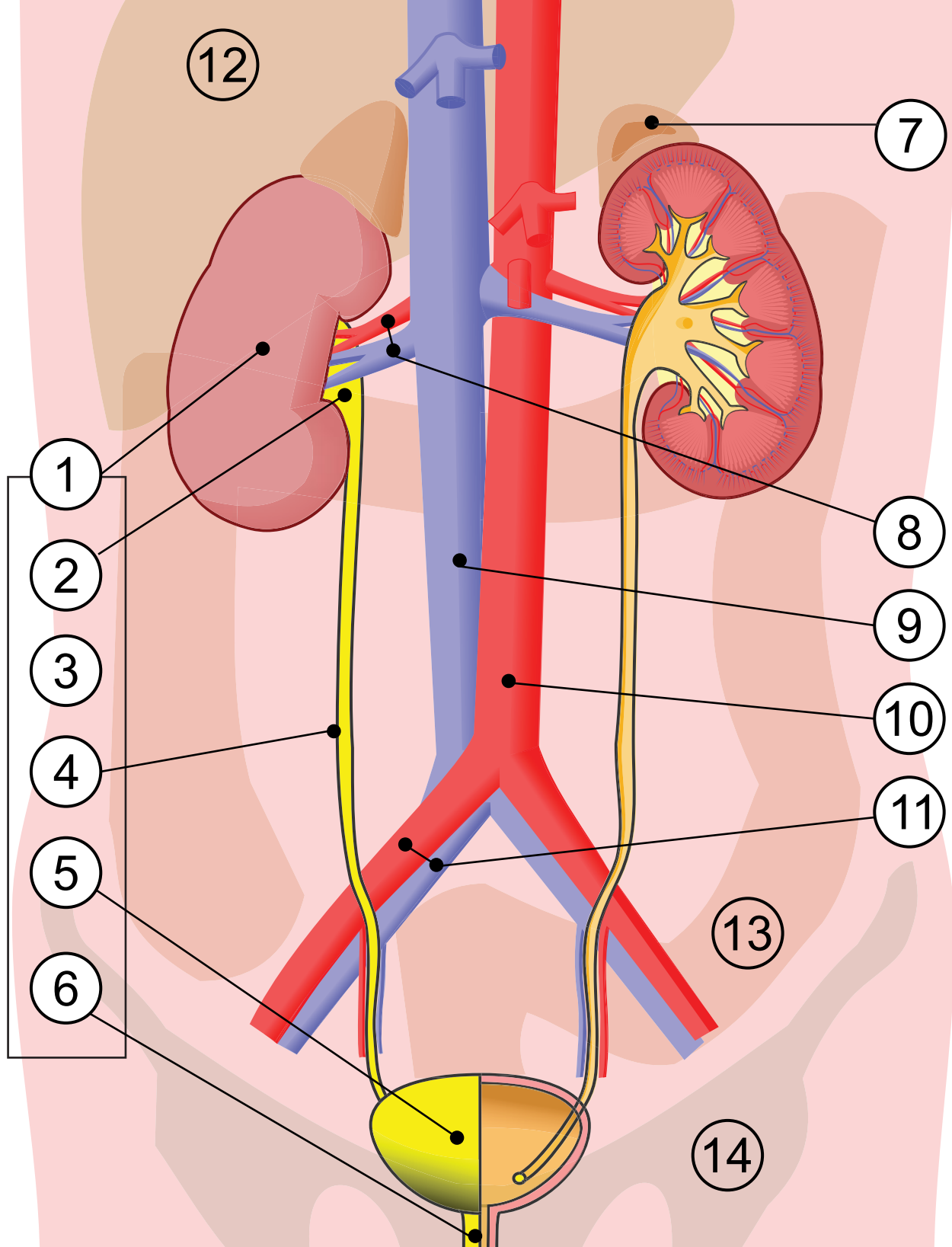
PATHOPHYSIOLOGY

In this case, the pediatric patient was diagnosed with a duplicated ureteral duct within the left vesicoureteral common sheath, which can lead to vesicoureteral reflux and can destroy the healthy kidney tissue leaving the patient with end stage renal disease. Common signs of this condition in adults include urinary tract infections, elevated blood pressure, protein found in the urine and hydronephrosis.⁷ Most patients also experience fever, abdominal or flank pain and retaining urine to circumvent the burning sensation caused by UTIs. Pediatric patients make this condition more difficult to diagnose; however, some nonspecific symptoms can include diarrhea, lack of appetite, irritability and an unexplained fever.⁵

High blood pressure also may be present due to a chronic disease being present in the kidneys. The type of hypotension viewed in these cases is identified as a secondary hypotension, which is mainly caused by kidney disease. Due to the amount of reflux, the adrenal glands secrete excess amounts of hormones and cause the hypotension.⁷

LEARNING OBJECTIVES

- ▲ Review the instrumentation and supplies needed for a left ureteral reimplantation
- ▲ Determine the signs and symptoms of this condition
- ▲ Examine the techniques used for this procedure
- ▲ List the complications that can occur from this type of surgery
- ▲ Identify the pathophysiology associated with these specific cases



- 1. Urinary system
- 2. Kidney
- 3. Renal pelvis
- 4. Ureter
- 5. Urinary bladder

- 6. Urethra
- 7. Adrenal gland
- 8. Renal artery and vein
- 9. Inferior vena cava
- 10. Abdominal aorta

- 11. Common iliac artery and vein
- 12. Liver
- 13. Large intestine
- 14. Pelvis

TESTS AND DIAGNOSIS

There are many different tests done for this type of condition with one of them being an ultrasound of the left and right kidneys, bladder and both left and right ureters. The KUB test is used to detect abnormalities, and in this case it was done to detect the reason behind the patient's reflux. For this case, it was determined that there was a duplicated left ureter that was contained within the same sheath. It also was discovered that the left kidney was slowly deteriorating due to the reflux of urine.⁷

Once the ultrasound was performed, the patient's physician ordered a voiding cystourethrogram to be performed. For this test X-rays are taken and the bladder is monitored closely as it empties. In this case, the voiding of the bladder was normal but there was a small amount of urine going backward toward the left kidney due to the duplicated ureter.⁷

A radionuclide cystogram was also performed. This examination utilizes a radioactive tracer or a radioisotope to ensure the urinary tract is working properly. In this case, when the bladder was full, the physician noted that some of the solution was being refluxed toward the kidney. These tests confirmed that surgical intervention was the best option to treat this patient.

When a child is diagnosed with a vesicoureteral reflux due to a duplicated ureter found within one sheath, surgery is the best way to repair such defect. Most of the time, physicians will order some antibiotics such as gentamicin or amoxicillin to decrease the amount of bacteria being grown in the urinary system prior to surgery. For this case, a 10-day antibiotic therapy course was prescribed.⁵

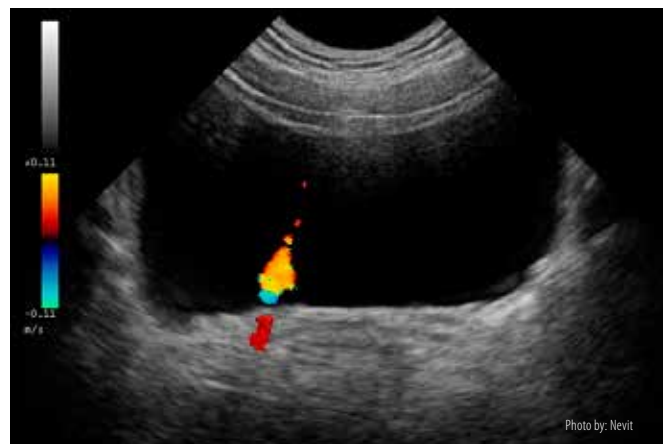
PROCEDURAL STEPS

Following anesthesia, the patient will be positioned in the supine position with their legs placed in the frog position. A pillow will be placed underneath the patient's head and their legs will be bent outward with the bottom of the patient's feet pressed together. Two rolled towels or sheets will be placed under their knees to prevent damage to the ligaments in the groin region. The patient's arms will be tucked along his or her sides and will be kept in place by adhesive tape.

Skin prep will begin at the incision site and is worked in a circular motion superiorly to the umbilicus, inferiorly to mid-thigh, and laterally from table to table. For this case, since the vagina was being prepped as well, it will be the last thing prepped so there is no cross contamination.

A time out is performed and once the entire team is gowned and gloved, the patient is draped. Four square blue towels will be used to outline the site of the incision, and a disposable laparotomy drape with adhesive backing will be placed over the outlined area. The lap drape is extended to the head of the bed, then toward the foot of the bed. The surgical technologist will bring up the Mayo stand and set up the electrocautery unit and suction for use. Sterile light handles will be placed on the OR lights.

The surgeon will create a Pfannenstiel incision in the lower abdomen just above the symphysis pubis, about three



Common signs of this condition in adults include urinary tract infections, elevated blood pressure, protein found in the urine and hydronephrosis.⁷ Most patients also experience fever, abdominal or flank pain and retaining urine to circumvent the burning sensation caused by UTIs. Pediatric patients make this condition more difficult to diagnose; however, some nonspecific symptoms can include diarrhea, lack of appetite, irritability and an unexplained fever.⁵

to four inches in length. The surgeon will cut transversally through the skin. Once the fascia is dissected, the rectus abdominus muscle is separated by making a longitudinal incision and the peritoneum is retracted with two Adson tissue forceps with teeth. The peritoneum is nicked with the knife blade and cut through using curved scissors.

Once the bladder is in view, the surgeon will proceed with a transverse cut through the muscularis, mucosa and

INSTRUMENTS/SUPPLIES/EQUIPMENT
3 French feeding tube
5 French feeding tube
Foley catheter
Micro dissection needle tip
Peanut sponges
Raytec sponges
Laparotomy sponges
Sodium chloride mixture for irrigation
Sterile water for irrigation
Antibacterial ointment
Major laparotomy pack
Suction machine
Electrosurgical unit
4-0 Polyglactin 910 suture
4-0 Poliglecaprone 25 suture
4-0 Polypropylene suture
Major laparotomy tray
Urology Tray
Non-locking 0.5 Castroviejo forceps
Non-locking 0.5 Castroviejo forceps
Liquid adhesive
Sterile bandages
Abdominal pads
Transparent wound dressings

submucosa tissue layers of the bladder. The surgical technologist will ensure that the knife used to incise the skin is not used during this step to prevent cross contamination. The O'Sullivan/O'Connor self-retaining retractor will be placed to keep the wound open.

The surgeon will identify where the bladder neck is located, as well as where the ureteral openings are. They will be marked by placing a 3 French feeding tube on the side where the duplicated ureter is located and a 5 French feeding tube where the single ureter is located. Once the feeding tubes are in place and the surgeon has verified their correct positions, a 4-0 polypropylene RB-1 suture will be used to secure the tubes into place prior to dissection.

A small right angle clamp will be used to elevate the tissue surrounding the left ureter so it can be dissected freely from the bladder with the electrocautery pencil with a 4-cm micro dissection needle tip so it can be repositioned to treat

the vesicoureteral reflux exhibited in this patient. Once this step is executed, the ureter is free from the bladder.

The left ureter will be moved across the superior portion of the bladder transversally and held by the first assistant. After the surgeon verifies that hemostasis has been achieved, the ureter will be placed in a safe area within the bladder. A submucosal tunnel will be created to feed the left ureter through so it can be anchored in for final placement. The surgeon will anchor the ureter with a 4-0 poliglecaprone 25 RB-1 using an interrupted suture technique. The area that was left open due to the separation of the ureter will also be sutured with a 4-0 poliglecaprone 25 RB-1 but will be performed by a running suture technique. The suture holding the feeding tubes will be removed and the tubes will be removed from the patient. The bladder will be irrigated with a sodium chloride mixture before closure.

A 4-0 absorbable suture will be used to close the bladder. The bladder will be closed in a two-layer closure with interrupted suture for better tensile strength and to ensure a strong seal to prevent urine leaks while the patient is recovering from this procedure. Once the bladder is closed, the peritoneum will be closed with a 4-0 polyglactin 910 with a running type suture. The rectus abdominus muscle will be sutured in the same manner. Finally, the subcutaneous layer and the skin will be closed using an interrupted suture with a 4-0 polyglactin 910. The surgeon will then insert a Foley catheter with a 150 cubic cm catch bag to aid with visualization of any blood or infection that may occur in the bladder due to this procedure.

With this type of surgery, there will be a minimum of four counts performed. An initial count before the operation, and a count after each of the bladder, peritoneum and skin are closed.

The wound will be cleaned with a sponge and sterile water and will then be dried off so the dressing will stick. A liquid adhesive will be applied to the wound to help prevent early dehiscence of the incision, then a few ½-inch adhesive bandages will be applied perpendicularly onto the incision. A 4x4 abdominal pad will be applied over the incision site and held in place by transparent dressings. The drapes then will be removed and the rest of the abdomen will be cleaned of any residual prep solution to prevent chemical burns to the patient's skin. The patient will be brought out of anesthesia, extubated and sent to the post anesthesia care unit for early recovery.

POSTOPERATIVE CARE

Once the patient has been in the recovery room an intense antibiotic treatment will be started within a few hours. The use of antibiotics will be used to prevent any type of urinary tract infection or an infection within the surgical site. As well as an antibiotic therapy, an anticholinergic agent will be prescribed to help with transient detrusor over activity that is commonly seen with this procedure. Pain medication also will be prescribed.

The patient will usually stay in the hospital overnight for close observation and a checkup will be scheduled with the surgeon a week after being discharged from the hospital, with an additional checkup performed between four and five weeks following the surgery.

COMPLICATIONS

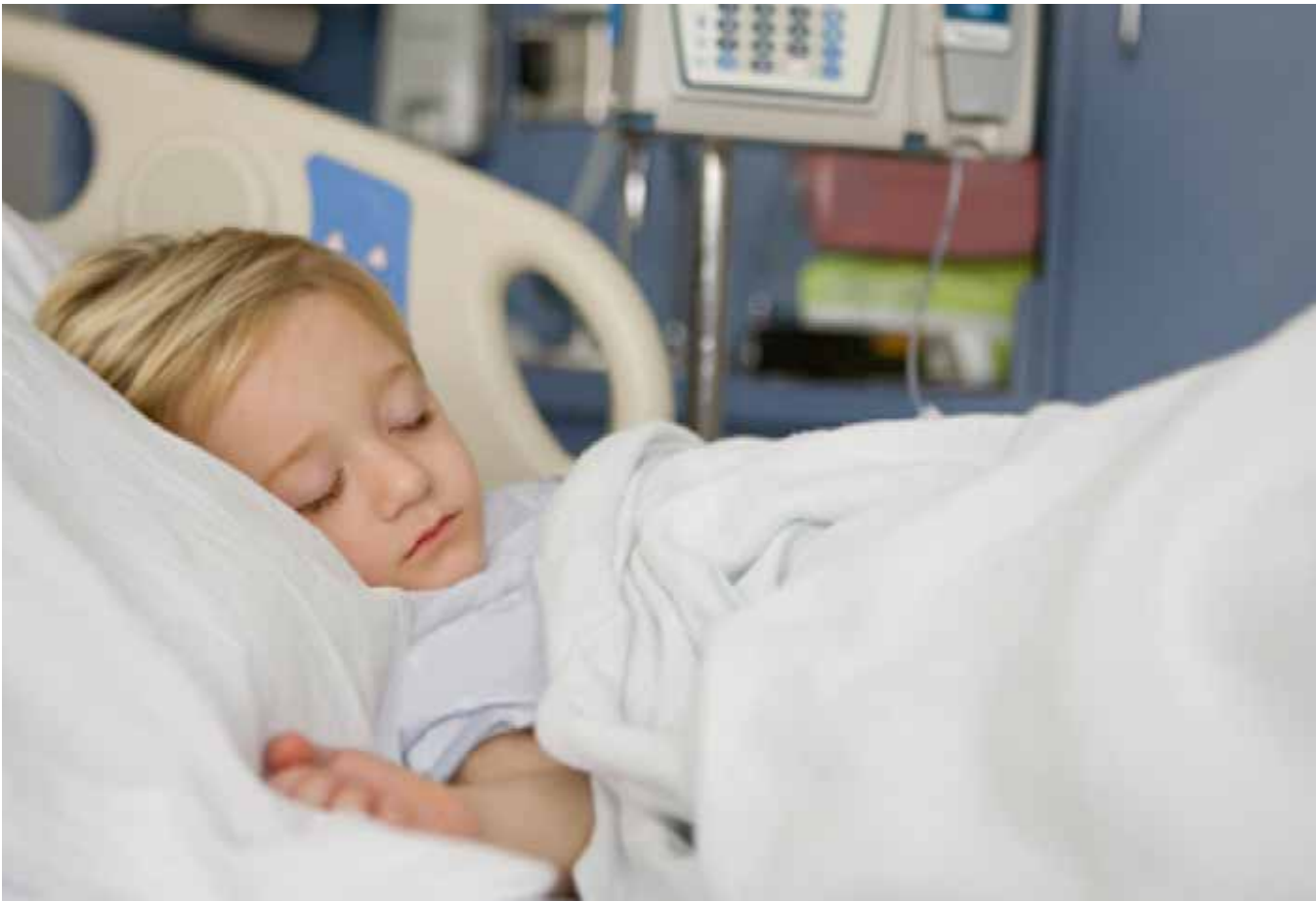Just like any other surgery, hemorrhage and infection are two of the most common complications associated with this surgery. Acute complications that can occur include extravasation of urine, ureteral obstruction, hematuria and bladder spasms. Long-term complications that can devel-

op include persistent reflux, contralateral reflux, ureteral obstruction or urinary fistula.⁴

During the case, damage to the urethra by not identifying it correctly when the bladder is opened or by inserting the catheter incorrectly may cause extravasation of urine. This could lead to a severe infection that may result in necrotizing cellulitis.⁴

Ureteral obstruction may occur due to edema of the mucosa layer of the bladder, or kinking of the ureter when it is reimplemented. Most times this side effect will disappear once the ureter has accommodated to its new place in the bladder; however, if the patient starts to show persistent pain, nausea leading to vomiting and elevated creatinine levels, then a placement of a stent may be necessary to ensure the health and well-being of the patient.⁴

Bladder spasms may occur due to urinary urgency and usually occur within the first postoperative week. The condition will be treated with anticholinergic therapy until the patient can demonstrate that they can empty their bladder adequately. In most cases a bladder scan is performed to ensure that there is no residual fluid built



up once the bladder has been emptied.⁴


If a patient develops a persistent reflux following the surgery, it is most likely due to the submucosal tunnel created for the reimplantation of the ureter and has created a higher intravesicular pressure causing the flow of urine to revert back to the kidney as it was before the procedure was done.⁸ Contralateral reflux usually occurs because different approaches can be made and it can result in the urine falling from the left ureter to enter into the right ureter and go up toward the right kidney. Most of the times this type of reflux may spontaneously resolve itself once the urinary system accommodates to its new set up.⁴

Making the angle higher than it should be on the placement of the reimplanted ureter may cause kinking and lead to another reimplantation surgery.⁴

With this case the main concern was preventing renal failure. Due to the upward flow of urine toward the kidney, it caused a considerable amount of scarring. Scarring can lead to loss of function in the filtering part of the kidney. Renal failure due to renal scarring may occur acutely or it may develop over time, which can lead receiving dialysis as an artificial mean to filtrate the waste from the body until a kidney becomes available for transplantation.⁴

REFERENCES

1. *Anatomy of the skin.* (nd) Retrieved from http://medicalcenter.osu.edu/patientcare/healthcare_services/skin_conditions/anatomy_skin/Pages/index.aspx
2. Chen, L. (2011). *Evaluation of the pediatric surgical patient.* Retrieved from <http://emedicine.medscape.com/article/936148overview?pa=q4DBzKJRADuaClXbq/blnEjCqllunlG46aqG3S7sus67co9PzGQRnNqkexrIJe56MI7dGTgNawPfsOtJla9Q==>
3. Children's Hospital of Central California. (2013). M000907768. Unpublished patient chart, patient name excluded due to HIPPA regulations
4. Ellsworth, P. (2011). *Ureteroneocystostomy.* Retrieved from <http://emedicine.medscape.com/article/1893904-overview>
5. Fisher, D. (2011). *Pediatric urinary tract infection medication.* Retrieved from <http://emedicine.medscape.com/article/969643-medication>
6. Kaji, D. (2013). Ureteral reimplantation common sheath preference card. Unpublished surgical preference card, Children's Hospital of Central California
7. MayoClinic Staff. (2011). *Vesicoureteral reflux.* Retrieved from <http://www.mayoclinic.com/health/vesicoureteralreflux/DS00999/DSECTION=riskfactors>
8. Primary Surgery. (nd) *Extravasation of urine complicating urethral injuries.* Retrieved from <http://www.primary-surgery.org/ps/vol2/html/sect0309.html>
9. RXList. (nd) *Cantil.* Retrieved from <http://www.rxlist.com/cantil-drug/clinical-pharmacology.htm>
10. RXList. (nd) *Hylenex.* Retrieved from <http://www.rxlist.com/hylenex-drug.htm>
11. Scherr, D. (nd) *Bladder anatomy.* Retrieved from <https://www.cornellurology.com/clinicalconditions/bladder-cancer/bladderanatomy/>
12. Urology care foundation. (2011). *Radionuclide cystogram.* Retrieved from <http://www.urologyhealth.org/urology/index.cfm?article=81>
13. Wax, M. (2012). *Rectus abdominis relevant anatomy.* Retrieved from <http://emedicine.medscape.com/article/880615-overview>
14. Wexner medical center. (nd) *Anatomy of the urinary system.* Retrieved from http://medicalcenter.osu.edu/patientcare/healthcare_services/urinary_bladder_kidney/anatomy_urinary_system/pages/index.aspx
15. Wheelless, C. (nd) *Pfannenstiel incision.* Retrieved from <http://www.atlasofpelvicurgery.com/9AbdominalWall/1PfannenstielIncision/ch9sec1.html>



Earn CE Credits at Home

You will be awarded continuing education (CE) credits toward your recertification after reading the designated article and completing the test with a score of 70% or better. If you do not pass the test, it will be returned along with your payment.

Send the original answer sheet from the journal and make a copy for your records. If possible use a credit card (debit or credit) for payment. It is a faster option for processing of credits and offers more flexibility for correct payment. When submitting multiple tests, you do not need to submit a separate check for each journal test. You may submit multiple journal tests with one check or money order.

Members this test is also available online at www.ast.org. No stamps or checks and it posts to your record automatically!

Members: \$6 per credit

(per credit not per test)

Nonmembers: \$10 per credit

(per credit not per test plus the \$400 nonmember fee per submission)

After your credits are processed, AST will send you a letter acknowledging the number of credits that were accepted. Members can also check your CE credit status online with your login information at www.ast.org.

3 WAYS TO SUBMIT YOUR CE CREDITS

Mail to: AST, Member Services, 6 West Dry Creek Circle Ste 200, Littleton, CO 80120-8031

Fax CE credits to: 303-694-9169

E-mail scanned CE credits in PDF format to: memserv@ast.org

For questions please contact Member Services - memserv@ast.org or 800-637-7433, option 3. Business hours: Mon-Fri, 8:00a.m. - 4:30 p.m., MT

Left Ureteral Reimplantation

360 DECEMBER 2013 1 CE credit - \$6

1. For this procedure, the patient was placed in the _____ position?

- a. Supine
- b. Lateral
- c. Frog
- d. Reverse

2. Skin prep begins at the incision sites and is worked in a circular motion _____ to the umbilicus.

- a. Inferiorly
- b. Superiorly
- c. Laterally
- d. None of the above

3. The Pfannenstiel incision made in the lower abdomen just above the symphysis pubis is _____ in length.

- a. 3-4 mm
- b. 3-4 inches
- c. 3-4 cm
- d. 1 foot

4. The _____ is nicked with the knife blade and cut through with curved scissors.

- a. Fascia
- b. Mucosa
- c. Submucosa
- d. Peritoneum

5. The ureteral openings will be marked by _____.

- a. Adson forceps
- b. Polypropylene suture
- c. Feeding tubes
- d. Right angle clamp

6. A submucosal tunnel is created to feed the _____ through so it can be anchored for final placement.

- a. Left uterer
- b. Right uterer
- c. Uterus
- d. Bladder

7. Most patients that undergo this procedure have a reoccurrence of which ailment?

- a. Elevated blood pressure
- b. UTIs
- c. Flank pain
- d. Diarrhea

8. A left uteteral reimplantation procedure is done to treat _____ in the urinary system.

- a. Kidney disease
- b. Scarring
- c. Renal disease
- d. Reflux

9. Adhesive tape will help keep the patient's _____ still during the surgery.

- a. Legs
- b. Hands
- c. Arms
- d. Feet

10. A _____ is used to elevate the tissue surrounding the left ureter so it can be dissected freely from the bladder.

- a. Kocher clamp
- b. Right angle clamp
- c. Needle tip
- d. Electrocautery pencil

LEFT URETERAL REIMPLANTATION 360 DECEMBER 2013 1 CE credit - \$6

NBSTSA Certification No. _____

AST Member No. _____

My address has changed. The address below is the new address.

Name _____

Address _____

City _____ State _____ Zip _____

Telephone _____

Check enclosed Check Number _____

Visa MasterCard American Express

Credit Card Number _____

Expiration Date _____

	a	b	c	d
1	<input type="checkbox"/>	<input type="checkbox"/>	<input type="checkbox"/>	<input type="checkbox"/>
2	<input type="checkbox"/>	<input type="checkbox"/>	<input type="checkbox"/>	<input type="checkbox"/>
3	<input type="checkbox"/>	<input type="checkbox"/>	<input type="checkbox"/>	<input type="checkbox"/>
4	<input type="checkbox"/>	<input type="checkbox"/>	<input type="checkbox"/>	<input type="checkbox"/>
5	<input type="checkbox"/>	<input type="checkbox"/>	<input type="checkbox"/>	<input type="checkbox"/>
6	<input type="checkbox"/>	<input type="checkbox"/>	<input type="checkbox"/>	<input type="checkbox"/>
7	<input type="checkbox"/>	<input type="checkbox"/>	<input type="checkbox"/>	<input type="checkbox"/>
8	<input type="checkbox"/>	<input type="checkbox"/>	<input type="checkbox"/>	<input type="checkbox"/>
9	<input type="checkbox"/>	<input type="checkbox"/>	<input type="checkbox"/>	<input type="checkbox"/>
10	<input type="checkbox"/>	<input type="checkbox"/>	<input type="checkbox"/>	<input type="checkbox"/>

Make It Easy - Take CE Exams Online

You must have a credit card to purchase test online. We accept Visa, MasterCard and American Express. Your credit card will only be charged once you pass the test and then your credits will be automatically recorded to your account.

Log on to your account on the AST homepage to take advantage of this benefit.