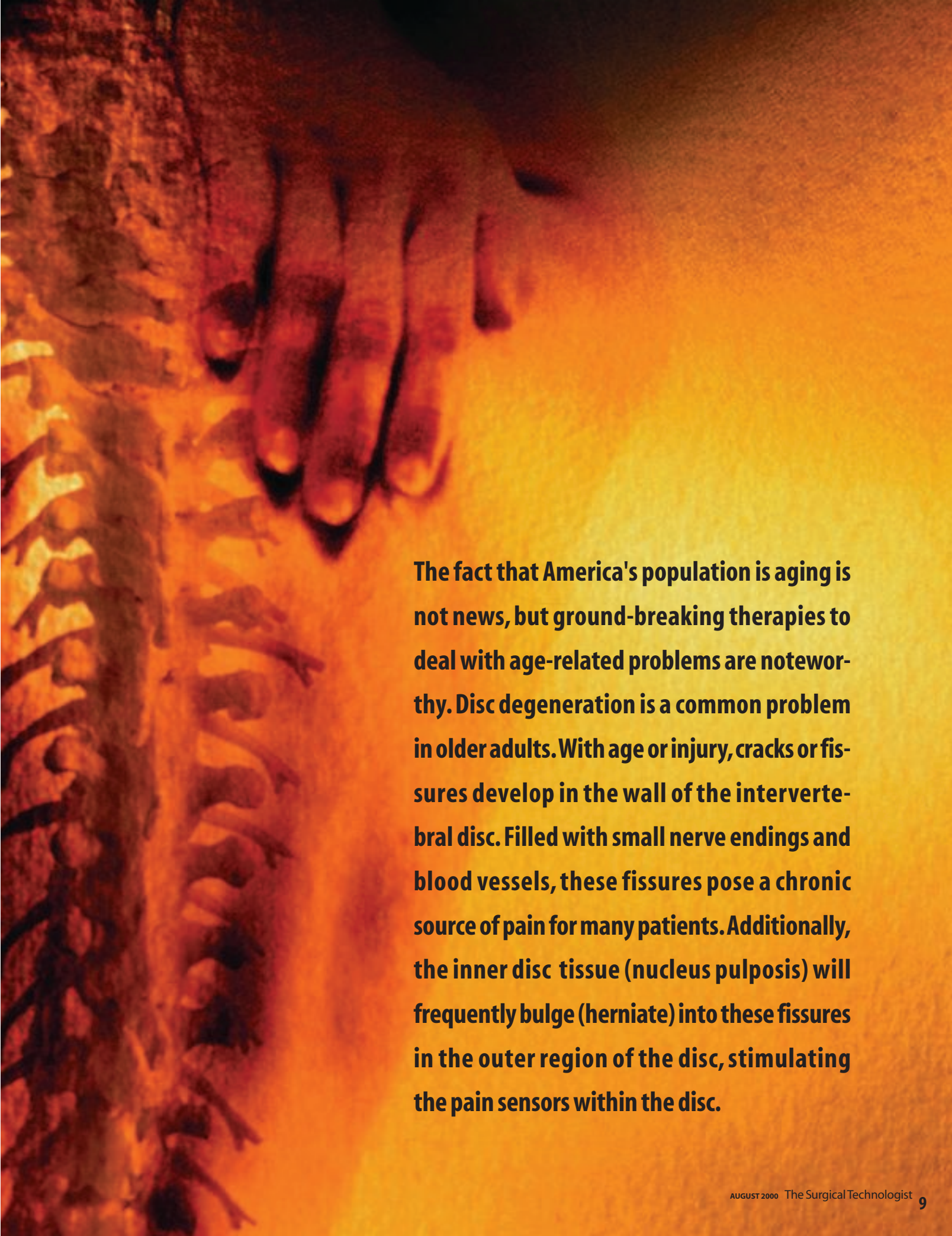




***IntraDiscal  
ElectroThermo  
Therapy™***

*a novel approach to lumbar disc  
degeneration and herniation*

**Jeffrey J Cortese, CST**



**The fact that America's population is aging is not news, but ground-breaking therapies to deal with age-related problems are noteworthy. Disc degeneration is a common problem in older adults. With age or injury, cracks or fissures develop in the wall of the intervertebral disc. Filled with small nerve endings and blood vessels, these fissures pose a chronic source of pain for many patients. Additionally, the inner disc tissue (nucleus pulposus) will frequently bulge (herniate) into these fissures in the outer region of the disc, stimulating the pain sensors within the disc.**

ntraDiscal ElectroThermo Therapy™ (IDET™) is a minimally invasive treatment in which the physician applies controlled levels of thermal energy (heat) to a broad section of the affected disc wall. This heat contracts and thickens the collagen of the disc wall and raises the temperature of the nerve endings. Therapy may result in contraction or closure of the disc wall fissures, a reduction in the bulge of the inner disc material, and desensitization of the pain sensors within the disc itself.

## Bone and ligament anatomy supporting the spinal cord

### Vertebral Column

The spinal column has 33 vertebrae joined by ligaments and cartilage. The cervical thoracic and lumbar vertebrae are mobile, but the sacral and coccygeal segments are fused to form the sacrum and coccyx.<sup>1</sup> There are seven cervical, twelve thoracic, five lumbar, five sacral, and four coccygeal (Coc1 to Coc4) vertebrae (Figure 2). Aging may cause sacralization (fusion of the sacrum and the L5 vertebra) or lumbarization (non-fusion between the sacrum and the S1 vertebra), and congenital spinal variations with partial or complete fusion. Identifying congenital abnormalities is important in the patient with a herniated lumbar disc, since the surgeon must identify the level of the ruptured disc. The level is determined by counting the vertebral bones on routine thoracic and lumbosacral X-rays and correlating the level with imaging studies. Additionally, the L5 and S1 vertebrae may be identified at the time of surgery by their mobility and resonant timbre, the L5 vertebra being mobile and having a sharply resonant sound upon tapping. If levels are questionable, intraoperative X-rays will provide positive identification.

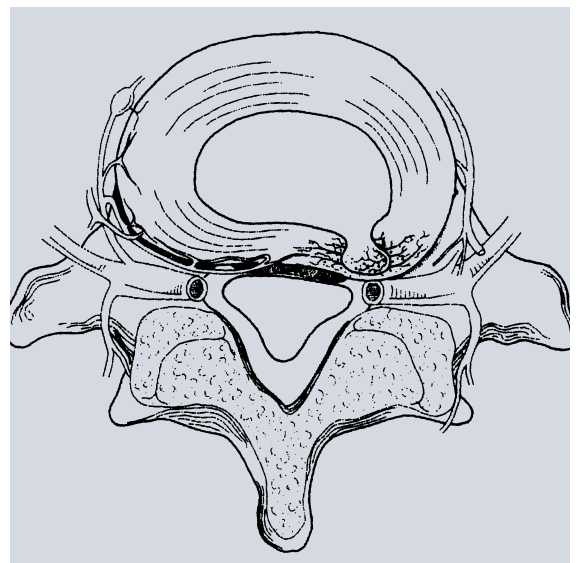
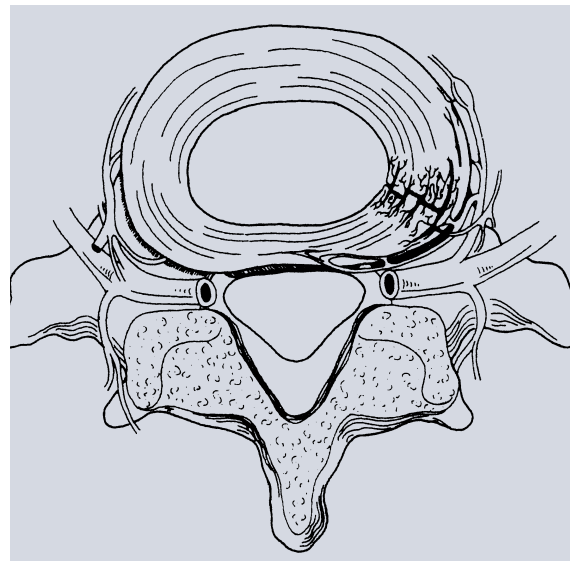
The vertebral column has an S-shaped curve when viewed laterally. The cervical and lumbar spine are lordotic and the thoracic spine is kyphotic. The term normal lordotic refers to ventral convexity. Kyphosis, or “hump back,” occurs with cervicothoracic tumors, trauma, osteomyelitis, degenerating spondylosis, and in

ankylosing spondylitis.<sup>2</sup> Straightening of the lumbosacral spine or abnormal lordosis can be seen in discogenic disease, trauma, tumors, stenosis, and paraspinal muscle spasm.

### Vertebrae and Lumbar Spine

Although the lumbar vertebrae are massive compared to other regions, traumatic fractures do occur regularly in the lumbar region, but neurologic injury is less common than in injuries at higher levels. The L1 vertebra is most prone to fracture as it lacks the rib cage support of its more rostral counterpart, the T12 vertebra.

Importantly, the lumbar spinal canal has an average AP diameter of 15 to 25 mm.<sup>1</sup> A diame-



## FIGURE 1

Disc degeneration and disc herniation.

ter of less than 12 to 13 mm is considered diagnostic of lumbar stenosis. Neurogenic claudication, a symptom of spinal stenosis, is a common and disabling disease that causes bilateral and posterolateral leg pain, cramping and weakness. Compromise of the AP diameter of over 50 percent is usually associated with neurologic deficit.<sup>2</sup>

Compression fractures require decompression and stabilization through anterior and posterior routes. One such treatment for this is interbody fusion. The article, "Operative Solutions to Axial Lumbar Pain" in the May 2000 issue of the *Journal*, details the anatomy of the vertebrae and lumbar spine, as well as procedures for anterior and posterior lumbar interbody fusions.

### *Intervertebral Disc*

Intervertebral discs are made up of a central core, the nucleus pulposus, surrounded by bands of fibrous tissue, the annulus fibrosis. In the annulus, the fibers are arranged in concentric rings so that each successive ring has a different slant than that of the preceding one (Figure 3). This criss-cross arrangement of the fibers gives elasticity to the annulus. Under normal tension, the fibers of two adjacent layers are lengthened and thinned, while with compression they are shortened and broadened. The most peripheral fibers of the annulus insert into the edge of the bone of the vertebral body. The remainder insert into the hyaline cartilage that lies superior and inferior to the disc, covering the cancellous bone of the vertebral body.

The chief component of the nucleus pulposus is a mucoid material containing embedded reticular and collagenous fibers. The nucleus contains 70 to 80 percent water, which gradually decreases from birth to old age. The nucleus is not quite centrally placed, positioned somewhat posterior to the center of the body of the vertebra. The posterior annulus fibrosus behind the nucleus pulposus is thinner than it is in front of the nucleus.

With its high water content, the nucleus pulposus itself is essentially incompressible. However, the pliability of the nucleus pulposus and the

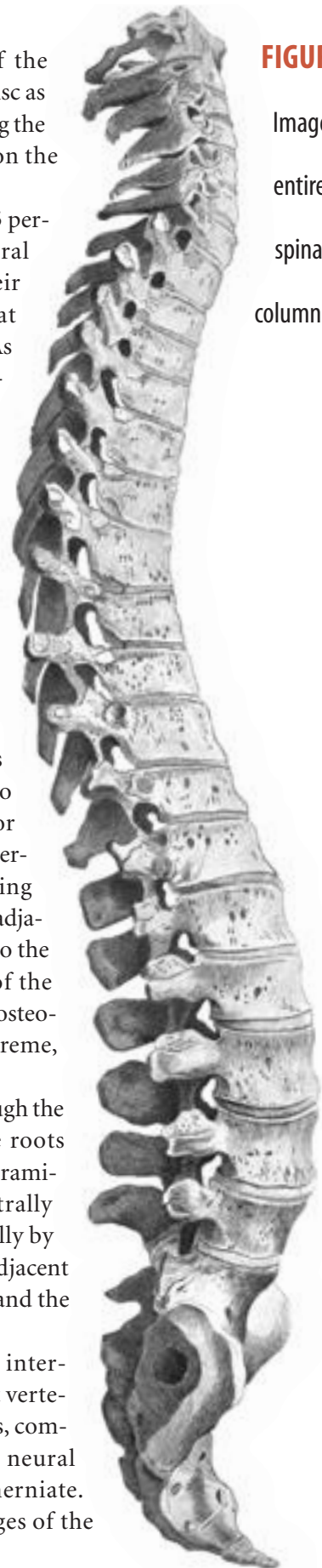
compressibility and stretch of the annulus allow the shape of the disc as a whole to be changed, permitting the movement of one vertebra upon the next.<sup>4</sup>

The discs contribute about 25 percent of the length of the vertebral column above the sacrum. Their high water content means that they are subject to dehydration. As the structure of its polysaccharides undergoes change, the disc loses much of its hydrophilic property,<sup>3</sup> resulting in dehydration. In addition, fibers of the internal layers of the annulus fibrosis grow progressively into the nucleus pulposus.

The disc becomes amorphous, sometimes discolored, and increasingly fibrotic. It develops more tears, loses height, and frequently breaks through cartilaginous plates into the vertebral body, protruding or expelling fragments out of the intervertebral spaces into surrounding areas. This results in pressure on adjacent structures and contributes to the development of hypertrophy of the adjacent bone edges, producing osteophytes, a process that, in the extreme, results in traction spurs.<sup>4</sup>

As the spinal cord passes through the spinal canal, it gives off nerve roots which exit through the neural foramina into spaces maintained rostrally and caudally by pedicles, dorsally by the facets, and ventrally by the adjacent surfaces of the vertebral bodies and the intervertebral discs.

Degenerative changes of the intervertebral discs and the adjacent vertebral bodies, or of the bony facets, compromise the spinal canal and neural foramina. Discs protrude or herniate. Osteophytes develop at the edges of the



**FIGURE 2**  
Image of  
entire  
spinal  
column.

vertebrae, or facets and bony misalignments occur.

### Mechanism of IDET

The idea of electrothermal annuloplasty was first conceived by Jeffrey A Saal, MD, and his brother, Joel S Saal, MD, in conjunction with Gary S Fanton, MD. These three doctors founded Oratec Interventions, Inc to develop techniques and instrumentation for the modification of collagen with the use of thermal energy. The doctors had first used human cadavers for a benchmark study of IntraDiscal ElectroThermal therapy. After several trials on cadaveric and animal models, the authors concluded that the whole nucleus pulposus was reduced by 7 percent and the focal point of contact between the disc and electrode was reduced by 20 percent.<sup>7</sup>

A pilot study was then initiated with 37 patients who had pain reproduction following discography. The patients were given the option of an interbody spinal fusion or IDET. All 37 patients chose the IDET procedure. After the study, 28 of the patients had reported reduction of their pain by 57 percent, improved sitting tolerance, and reduction of their pain medications.<sup>7</sup> None of the patients developed any neurological deficit or radicular pain as a result of the procedure.

The doctors had proven that thermal energy has profound changes in the collagenous and neurovascular annular structures of the degen-

erated discs. The collagen fiber molecules composing the annular wall are held in a triple helix structure by heat-sensitive hydrogen bonds. Precise levels of thermal energy break these bonds, contracting and thickening the molecules and, ultimately, the fibers.<sup>8</sup> An excellent analogy of this process is the reaction of a plastic wrap to a heat source. Within a certain period of time, the wrap will shrink.

### Room set-up

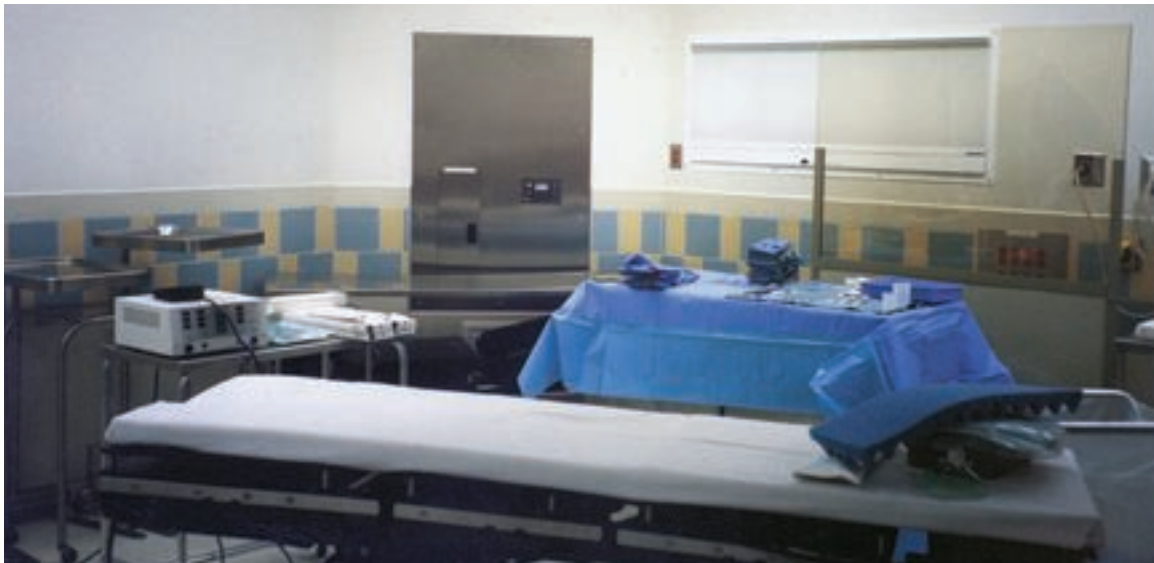The IDET procedure can be performed in any setting that is capable of fluoroscopy. At Bon Secours Hospital, the team uses the operating room for the comfort of the patient, since some sedation is required for the procedure. An electric operating table capable of accommodating the fluoroscope is necessary to allow the surgeon to guide the needle(s) into the disc space(s) (Figure 4). Ideally, a bi-plane C-arm should be used for instantaneous images of the AP and lateral plane of the spine. However, a standard fluoroscopy unit will suffice. A small back table or the top of a case cart is adequate for the minimal amount of instrumentation and supplies needed to perform the procedure. The room is kept absolutely quiet during the procedure. Direct communication between the patient and the surgeon is very important to help guide the needle into the disc space and for the actual “heating” of the disc.

## FIGURE 3

The intervertebral disc.  
Note the concentric rings  
of the annulus fibrosis  
and the central nucleus  
pulposus.




Illustration © Michael Reinhold



**FIGURE 4**

The operating room set-up. The electric operating table is reversed to facilitate the use of the fluoroscopy unit and the case cart is utilized as the back table.

### Patient preparation

Prior to the IDET procedure, the patient undergoes a procedure called a discogram. Using the same approach described for IDET, the surgeon overinflates the disc with contrast media to recreate the patient's symptoms. This exam allows the surgeon to visualize the disc itself by looking at the X-ray films (Figure 5).

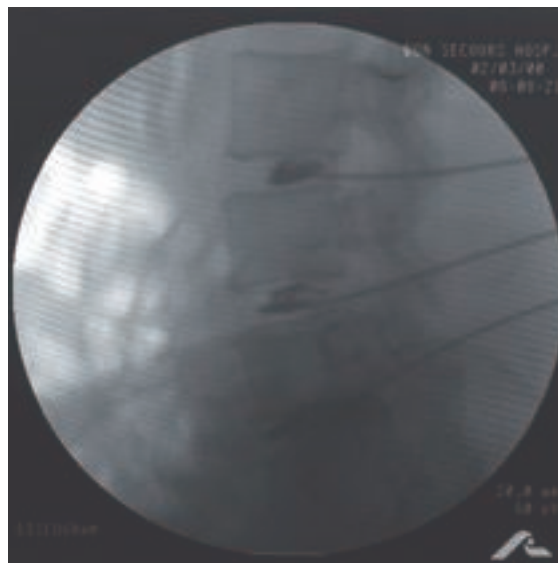
The patient is given 2 g of Cefazolin IV piggyback as a preoperative antibiotic. Muscle relaxation and anxiety reduction is achieved with 1 to 5 g of Midazolam (Versed) titrated based on patient need. If the patient becomes too sleepy during the procedure, Romazicon (.1 to .3 mg over 15 seconds) may be given to help reverse the Midazolam.

The patient is placed in a prone position on a well-padded table with blanket rolls and pillows to simulate a Wilson frame.

### Surgical preparation

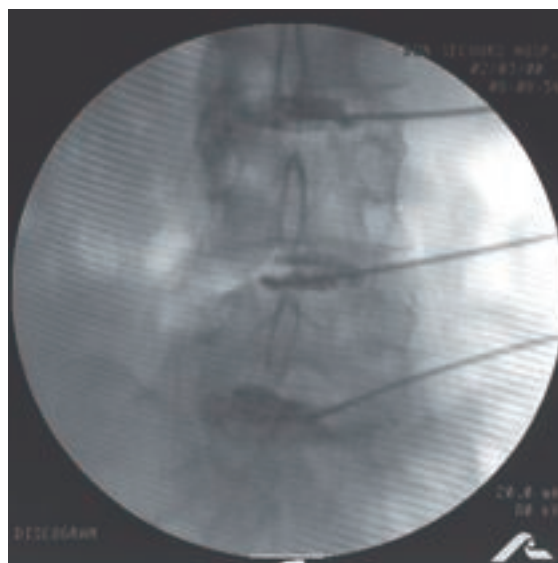
Preoperative scout fluoroscopy images are taken to align the vertebral bodies in the AP as well as lateral planes. The surgeon must line up both pedicles of the vertebral body to ensure that he or she is on the right trajectory into the disc space without entering the spinal nerve foramen. The C-arm is then moved away for the prep of the skin.

The skin prep consists of mechanically scrubbing the patients back for 10 minutes with a half-



**FIGURE 5**

The Discogram X-ray shows the disc spaces of L3-L4, L4-L5, and L5-S1. Note the annular degeneration of the L5-S1 inter space.



and-half mixture of Betadine scrub and solution. After blotting the mixture with a sterile towel, the assistant changes gloves and proceeds to paint the skin with Betadine solution.

The draping of the site only consists of four cloth towels secured with towel clips. This is strictly the surgeon's preference.

### Instrumentation

The same instrument set may be used for discography and IDET procedures (Figure 6). It consists of an instrument stringer, preferably one that has a swivel end, a long Kelly clamp, Crile hemostatic forcep, and a pair of straight Mayo scissors. Along with the basic instrumentation, introducer needles (17 g, 6"), an 18 g 6" spinal needle, and the SpineCATH™ are needed to complete the procedure.

### Operative procedure

The C-arm is brought back into the field. Using the instrument stringer as a pointer, images are taken to determine the entry point of the needle in the skin. The appropriate intervertebral levels are selected and marked with a sterile marking pen. These marks are then transferred 6 cm lateral to the midline for a far-lateral approach to the disc space (Figure 7). The skin is infiltrated with 0.5 percent Marcaine drawn up in a 10 cc slip-tip syringe mounted to a 30 g needle. The needle size is the surgeon's choice, but a 30 g nee-

dle works very well. The patient should feel no more pain than when having an IV line started.

Once the entry site(s) have been sufficiently anesthetized, the spinal needle is introduced through the skin and through the subcutaneous fat. X-ray images are used to confirm the trajectory of the needle in the AP as well as the lateral plane to confirm that the needle is not heading too far medially toward the foramen. Just before the thoracolumbar fascia is entered with the spinal needle, the stylet of the needle is removed, and the syringe containing Marcaine is attached to the needle to add a little more anesthetic to the site. Entrance without Marcaine is quite painful and should be avoided.

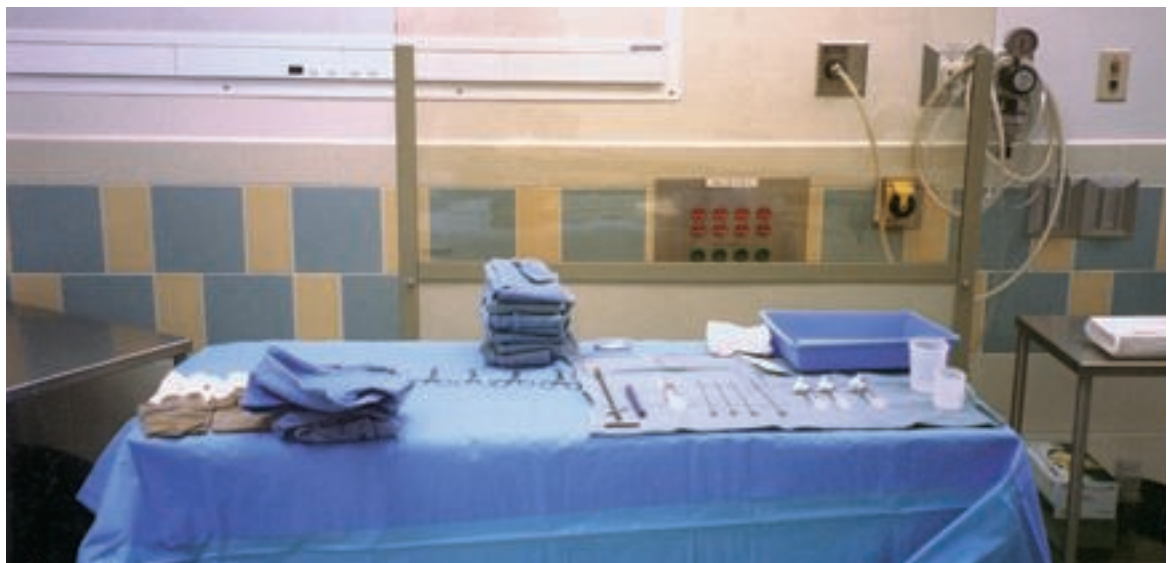Once the needle approaches the disc space, the surgeon will ask the patient to describe any pain in the back, hip, or leg. This is important because any type of radicular pain down the leg indicates that the needle may be brushing up on a nerve root. If this is the case, the surgeon has to withdraw the needle and reposition it. Once the disc space is entered, a slight amount of resistance is met, but very little is felt once the needle is placed. These steps are repeated for as many levels as are being treated.

### IDET

Once all the needles are in place, the surgeon may opt to distend the affected disc spaces with saline to confirm that the disc spaces are indeed

**FIGURE 6**

Very few instruments are required to perform the IDET procedure.



the ones causing the problem. Once this step is done, the SpineCATH™ is inserted through the spinal needle and into the disc space. In a staged fashion the flexible catheter is advanced along the inner annular margin until the resistive heating coil rests along the dorsal inner annular wall, ideally achieving full 360° penetration (Figures 8 and 9).

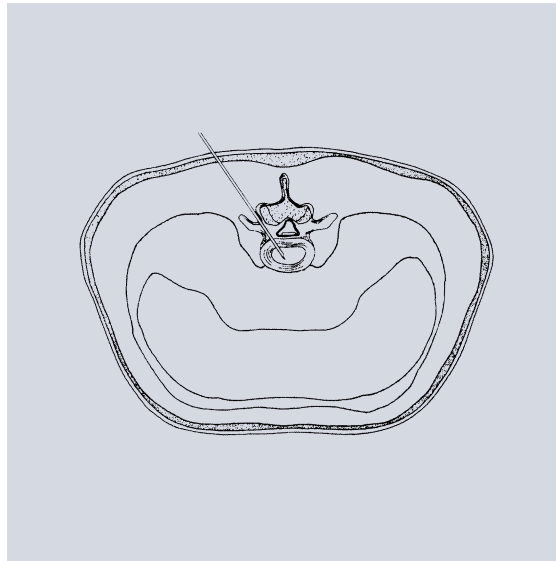
Electrothermal heat is generated in the heating section of the catheter starting at 65° C and increasing incrementally to 90° C, a process that can take 14 to 17 minutes. During this portion of the procedure, it is normal for the patient to feel some discomfort deep in the back. But, if the pain starts to radiate down the leg, the generator is stopped. If the generator is too close to the annular wall and the nerve root or spinal cord is being heated, the catheter is repositioned in the disc space.

In the catheter treatment, the surgeon heats a very large section of the disc, usually, from the three o'clock position to the eight o'clock position of the back wall of the disc.

Complete treatment of one disc takes about hour. Once the desired levels are treated, the SpineCATH™ is withdrawn, the spinal needles are withdrawn swiftly, the back is washed of the prep solution, and small dot-type adhesive bandages are applied to the skin. The patient typically recovers in the hospital anywhere from 40 to 60 minutes before going home.

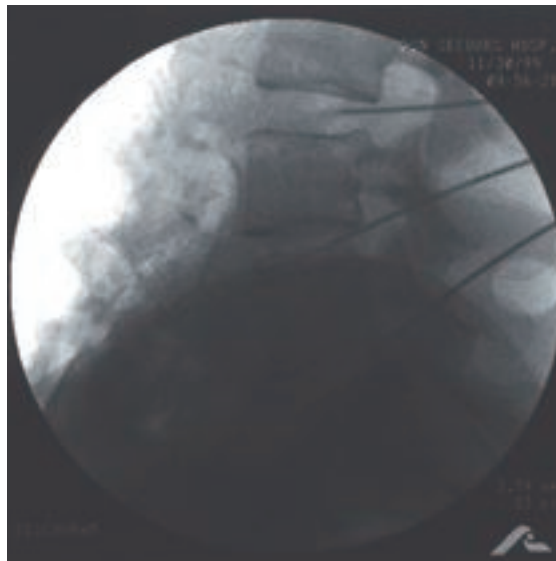
### Postoperative management

For most people there is a period of mildly increasing pain lasting a few days or weeks after the procedure. The normal treatments prescribed for this are rest, ice, pain medications, and anti-inflammatory medications. The patient is instructed not to exert him or herself for the first few weeks, including no housework, lifting or bending. Short walks are restricted to 15-20 minutes, but are not advised within the first postoperative week. Gradually over a month, patients may do light lifting, but they are still restricted from bending, twisting, or heavy lifting. Within the second, third, and fourth postoperative month, the patient is instructed to main-



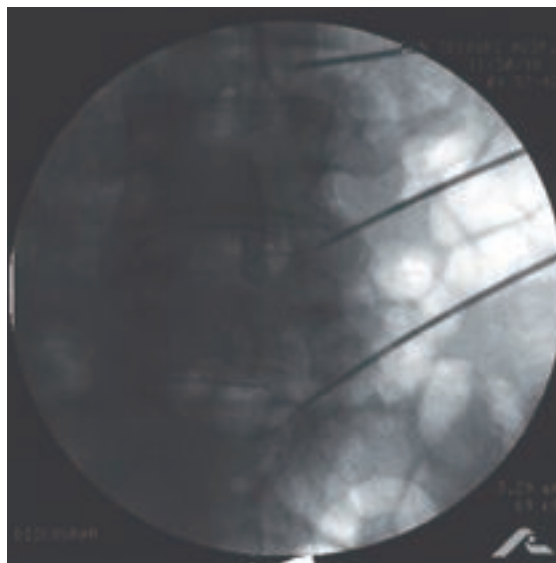
**FIGURE 7**

The trajectory of the spinal needle into the disc space.



**FIGURE 8**

SpineCATH™ electrodes in the discs of L4-L5 and L5-S1 are apparent on these X-rays. The electrode sits along the dorsal inner annular wall providing a full 360-degree penetration.





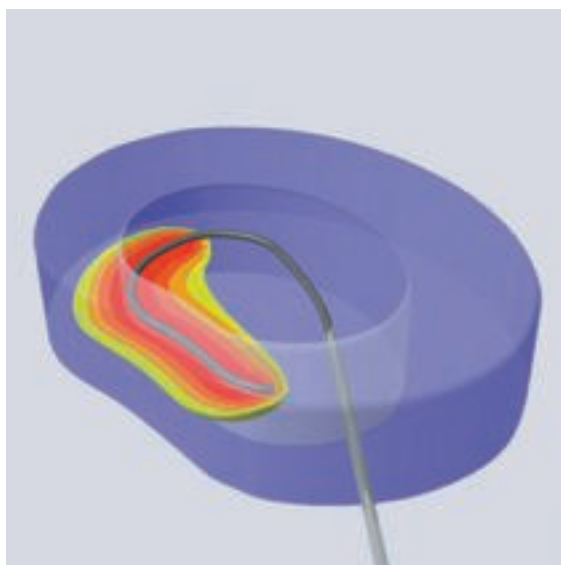
tain good body mechanics. If the patient chooses to do so, mild exercise may be resumed with specialized training. Under no circumstances is heavy work or aggressive physical activity allowed for at least six months following treatment.

### Conclusion

Stable articulations between the mobile vertebrae of the human spine control motion in three planes, flexion-extension, axial rotation, and lateral bending. Like any joint, the articulations may face large and varying loads and ultimately may degenerate and fail. As in the hip and knee,

**FIGURE 9**

Thermal heating of the annulus fibrosus.



degeneration of the spinal joints leads to pain, deformity, and altered function.

Ailments of the “overextended” spine are frequent, accounting for the fifth most common reason for time lost from work and physician office visits, just after the common cold.

The IDET procedure offers a less invasive outpatient procedure with a more convenient recovery. It costs a fraction of that of a comparable surgical fusion and is a less radical alteration in spinal anatomy. The hope is that carefully chosen patients will find this procedure as effective and more appealing than more invasive surgery. The long-term success of the IDET procedure remains to be proven but appears to be promising.

### About the author

Jeffrey J Cortese, CST, has worked at Bon Secours Hospital in Grosse Pointe, Michigan, for five years. He is also a biology/pre-medicine major at Wayne State University and works part-time as a research assistant for the school's department of neurological surgery.

*Illustrations courtesy of Oratec Interventions and Science and Medicine.*

### References

1. Truex RC, Carpenter MB: *Human Neuroanatomy*. Baltimore, Williams & Wilkins, 1973, pp 1-290
2. Youmans JR: *Neurological Surgery*, vols 1-6. Philadelphia, Saunders, 1982, pp 551-617.
3. Gower WE, Pedrini V: Age-related variations in proteinpolysaccharides from human nucleus pulposus, annulus fibrosus, and costal cartilage. *J Bone Jt Surg* 51A: 1154-1162, 1969.
4. Hendry NGC: The hydration of the nucleus pulposus and its relation to intervertebral disc derangement. *J Bone Jt Surg* 40B: 132-144, 1958.
5. Feinberg SB: The place of discography in radiology as based on 20 cases. *AJR* 92: 1275, 1964
6. SpineCATH™ IntraDiscal ElectroThermal™ Therapy (IDET™), *Procedure Information*. Brochure. Oratec Interventions, Inc. 1999
7. Saal JA, Saal JS, Ashley J: Thermal Characteristics of the Lumbar Disc: Evaluation of A Novel Approach to Targeted Intradiscal Thermal Therapy. NASS Thirteenth Meeting. San Francisco, California 1998
8. Derby R, Eek B, Ryan DP: Intradiscal Electrothermal Annuloplasty: NASS Thirteenth Meeting. San Francisco, California 1998
9. Rothman RH, Simeone FA: *The Spine*. Philadelphia, Saunders, 1982.
10. Frymoyer JW: *The Adult Spine*. New York, Raven, 1991.
11. Personal interview with John L Zinkel, MD, PhD, FACS, 2000.
12. Bao QB, Yuan HA: The Artificial Disc. *Science & Medicine* 5(1):7, 1998.