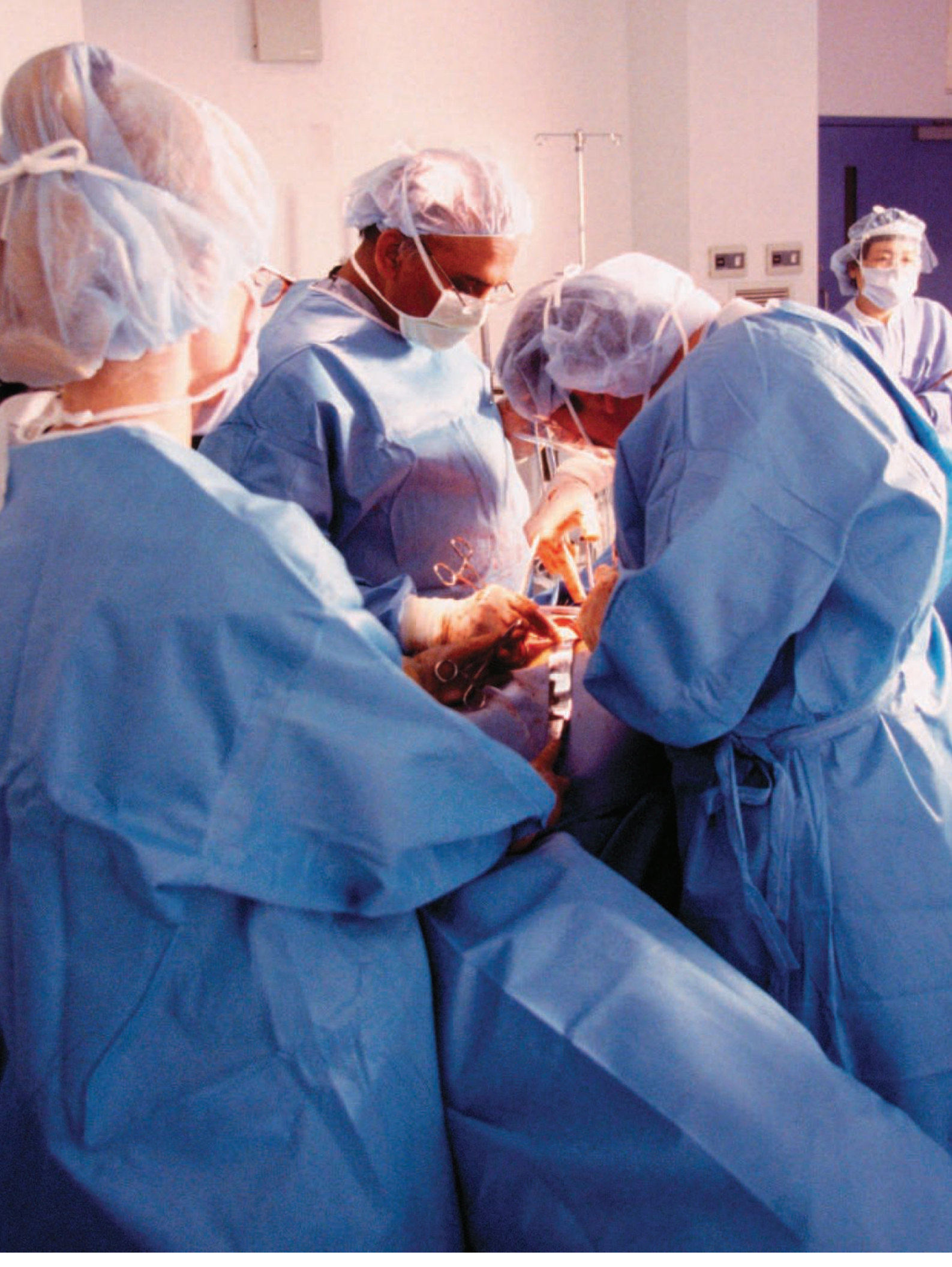



Total Abdominal Hysterectomy

DOUGLAS HUGHES, CST, CRCST

Total abdominal hysterectomy (TAH) is commonly used to treat patients suffering from a variety of pathologies, such as hemorrhage, fibroids, abdominal pain and various types of cancer. Approximately 500,000 hysterectomies are performed in the United States each year.¹³

Hysterectomy is indicated typically in the following three conditions: as a life-saving intervention, as a corrective procedure for serious functional problems, and to improve the patient's quality of life. Some of the more common, specific indications for surgery include uterine cancer, ovarian cancer, cervical cancer, fibroids, endometriosis, prolapse, precancer of the uterus, pelvic adhesions, unusually heavy bleeding, and pelvic pain.⁸

Hysterectomy may be performed either vaginally or abdominally, depending on the patient's diagnosis and age, the size of the uterus, and other related factors.¹³ The abdominal approach is most commonly employed when nearby structures, such as regional lymph nodes, must be examined, when the ovaries and fallopian tubes will be removed in conjunction with the uterus, and when large tumors are present.

The vaginal approach may be indicated when the size of the uterus is determined to be less than that during 12 weeks of gestation, when no other related pathology is suspected, and when the hysterectomy will be done in conjunction with cystocele, rectocele, or enterocele repair.^{3,13}

This article will chronicle the preoperative, intraoperative, and postoperative case management of a 38-year-old patient undergoing total abdominal hysterectomy for treatment of large symptomatic uterine fibromata.

PATIENT INFORMATION

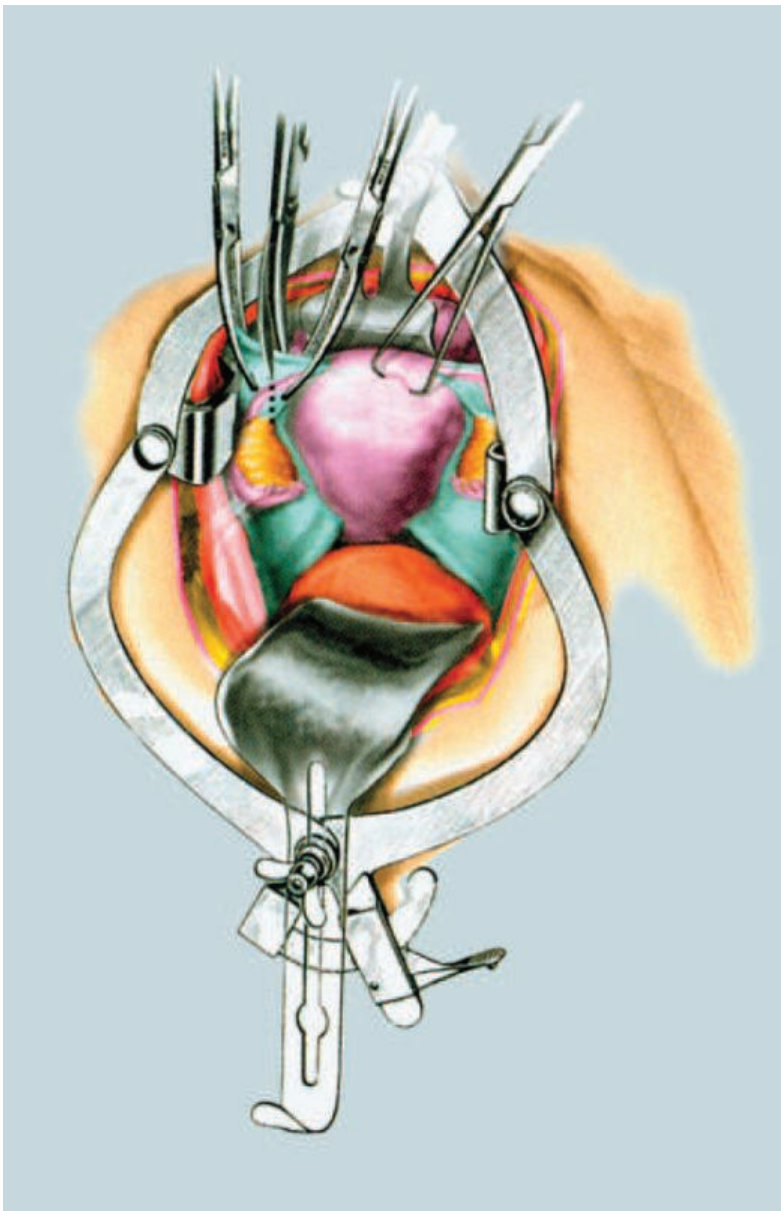
The patient is a 38-year-old caucasian female approximately 5'3" tall who weighs 146 pounds. She has no known drug allergies and is currently taking nonsteroidal anti-inflammatory drugs to relieve menstrual cramping and

heavy menstrual bleeding. She has also been taking nonprescription iron supplements to correct anemia caused by fibroid-related blood loss.

The patient's blood type is O negative. The patient has admitted to heavy illegal drug use in the past, but indicates she has been free of any drug or alcohol use, including smoking, for approximately eight months prior to surgery.

A pelvic examination done prior to admission revealed a uterine mass. Sonohysterography was later performed and confirmed the diagnosis of uterine fibroids, leading to the current surgical intervention.

FIGURE 1:
Total abdominal
hysterectomy (TAH):
Division of round
ligament.



Courtesy Thomson Delmar Learning, *Surgical Technology for the Surgical Technologist: A Positive Case Approach*, © 2004.

MEDICAL HISTORY

The patient reported that her symptoms have lasted approximately nine months and have become progressively worse. Symptoms include dysmenorrhea, consistent episodes of urinary frequency and urgency, abdominal distension, chronic lower-back pain, and dyspareunia. No trauma that may be associated with these symptoms was reported.

The patient's medical history includes mild asthma, generalized anxiety disorder and a previous cesarean section.

Current medications include:

- Ibuprofen—400 mg every four hours
- Ferrous sulfate—300 mg per day
- Inhaled sympathomimetic—180 mcg (two inhalations) every four to six hours as needed
- Benzodiazepine—0.25-0.50 mg three times daily, not to exceed 4 mg per day

PHYSICAL CONDITION AT ADMISSION

The preoperative physical examination revealed that the patient was in good health and that she was well nourished. Her skin was warm, dry, had good texture, and was free of any notable lesions or abnormalities. Normal, wet mucosa was noted during evaluation of the patient's ears, nose and throat. No pathologies were encountered. An evaluation of the patient's neck produced normal results with no masses found.

Auscultation of the lungs indicated they were normal and without congestion or other anomaly. Examination of the abdomen revealed palpable masses and distention, though bowel sounds were normal.

The patient's extremities were normal and without edema, cyanosis, other pathology, or vascular abnormality. No neurologic disorders were noted, and the patient was alert.

Vital signs were normal and stable:

Heart rate	84 bpm
Respirations	18 breaths per minute
Blood pressure	126/82 mm/Hg
O ₂ saturation	98%
Temperature	98.8° F

SURGERY INDICATED

Drugs on the field included 1,000 cc of normal saline irrigation fluid, 30 cc of 0.25% bupivacaine with epinephrine for local anesthesia, and triple antibiotic ointment (neomycin, polymyxin, and bacitracin zinc) for application with the dressing.

ANESTHESIA

Prior to anesthesia induction, the patient's jewelry and wristwatch were removed. General anesthesia was administered via an endotracheal tube. Vital signs and airway were managed, and the patient's level of consciousness was assessed. Nothing abnormal was reported.

Intravenous induction and maintenance agents used:

- Midazolam Hydrochloride
- Propofol
- Fentanyl Citrate

Inhalation agents used:

- Oxygen
- Desflurane

PATIENT POSITIONING

The patient was transported to the O.R. via gurney and transferred to the operating table with the assistance of the surgical team. Her head was placed on a gel donut headrest. The patient was then covered with a blanket for warmth and privacy.

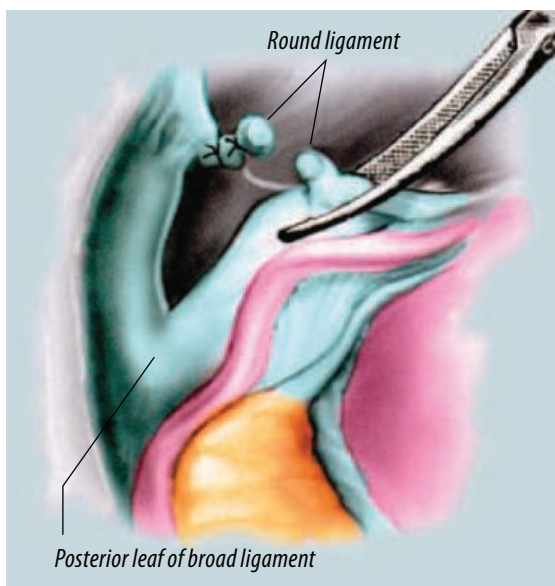
The patient was positioned in the supine position with padding under bony prominences and a restraint proximal to her knees to prevent falling. Arms were extended laterally on padded armboards and were positioned to slightly less than 90°.

A pulse oximeter was applied to the right index finger, and a blood pressure cuff to the upper right arm. The electrosurgical unit dispersive pad was placed under the left buttock.

Following intubation and induction of anesthesia, the blankets were repositioned, and a Foley catheter was inserted.

SKIN PREPARATION

The patient had no known allergy to iodine-based chemicals, so a standard iodine prep solution was used in accordance with the surgeon's



Courtesy Thomson Delmar Learning, *Surgical Technology for the Surgical Technologist: A Patient Care Approach*, ©2004.

FIGURE 2: Broad ligament—posterior and anterior leaves.

preference card. Abdominal and vaginal preparation techniques were employed.

An impervious drape with a reservoir was placed under the buttocks to collect excess prep solution. Disposable towels were placed at the patient's sides. For the vaginal prep, a downward movement was used over the genitalia and perineum. Each sponge was discarded after prepping over the anus. The upper thighs, pubis, vulva, labia, perineum and anus were prepped. The vaginal vault was prepped with sponge sticks, and each was discarded after use.

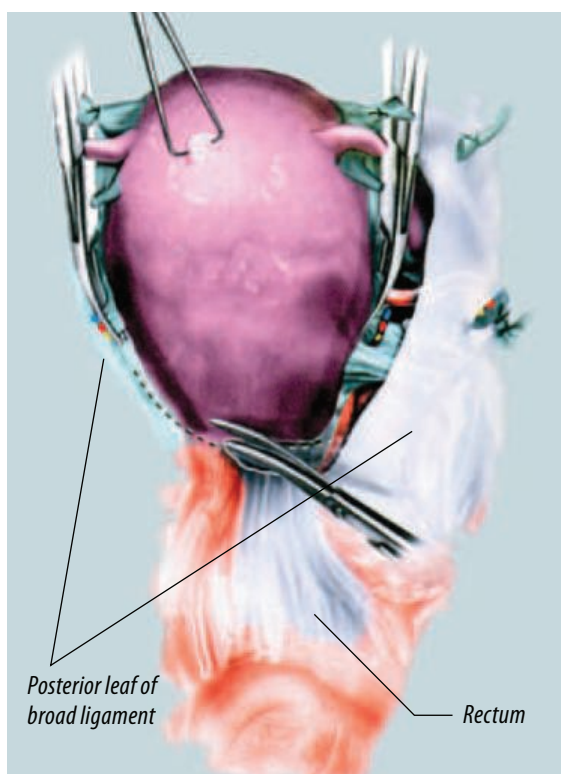
The abdomen was prepped beginning at the incision site (low transverse) and extending from the nipples to midhighs, and laterally as far as possible. This was accomplished using circular motions starting from the incision site outward. A sterile, disposable towel was used to collect and dry any excess solution.

DRAPING

Folded towels and a laparotomy drape were used to create the sterile field. Sterile blue towels were placed one-by-one around the planned incision site in order to outline the area for placement of the drape. Towel clips were not used to secure the towels, as it was determined that they would not be needed.

The protective strips were removed from the adhesive backing of the laparotomy drape, and it was passed to the surgeon. The drape was orient-

FIGURE 3:
Dissection line.



Courtesy Thomson Delmar Learning. *Surgical Technology for the Surgical Technologist: A Positive Care Approach*. ©2004.

ed for maximum exposure of the surgical site just superior to the mons pubis. The sheet was slowly unfolded bilaterally and stabilized. The head of the drape was extended and passed to the anesthesia provider, who fastened it to IV poles located on either side of the patient's head. The foot of the drape was extended downward beyond the operating table to cover the body.

The electrosurgical pencil and suction apparatus were placed on the drapes and secured with non-metallic, nonperforating towel clips. Finally, sterile light handles were attached, and the lights were positioned for maximum exposure of the operative site.

TIME-OUT AND INCISION

A surgical time-out was done to verify correct patient and procedure, and a low transverse (Pfannenstiel) incision was made superior to the pubic symphysis and extended transversely to approximately 10-15 cm with a #10 blade on a #3 knife handle. Rat-toothed forceps were used to assist with manipulation of the tissues.

The subcutaneous (adipose) tissue was incised with electrocautery, and hemostasis was maintained by coagulation. The anterior rectus sheath

was incised with curved Mayo scissors and reflected superiorly using two Kocher clamps. The bellies of the rectus muscles were dissected longitudinally, and the peritoneum was incised vertically with a #10 blade and toothed forceps, to elevate it from underlying structures. A medium Richardson retractor was used to aid in exposure of the operative site.

PROCEDURAL OVERVIEW

Once entrance into the peritoneal cavity was achieved, the uterus and surrounding structures were assessed for any unsuspected pathology. The adnexae, including the ovaries and fallopian tubes, were also assessed. The operating table was put in the Trendelenburg position to improve visualization of the abdominal cavity and operative site.

The bowel was positioned away from the operative area and packed with five laparotomy sponges moistened with warm normal saline. The surgical site was exposed with an O'Connor-O'Sullivan self-retaining retractor, which was placed into the abdominal cavity.

Short instruments on the Mayo stand were replaced by extra long instruments in order to reach deeper anatomy. Incorporating the round and ovarian ligaments, Phaneuf clamps were placed across each broad ligament close to the cornu. Some of the clamps were left in place along with perforating towel clips to aid in elevating and manipulating the uterus during excision.

0 Vicryl® ties were used to ligate the round ligaments, which were divided and cut with curved Mayo scissors. Anterior and posterior leaves were created on the broad ligaments, which were incised using Metzenbaum scissors.

The peritoneum of the bladder was separated from the lower portion of the uterus. A sponge stick was used to bluntly dissect the bladder away from the uterus and cervix along an avascular plane. The retroperitoneum was opened to expose the iliac vessels and ureters underneath. Once these important structures were identified, they were protected for the remainder of the procedure.

The infundibulopelvic ligament and uterine artery were exposed by enlarging the peritoneal opening. A Heaney clamp was placed medial to

the ovary. The infundibulopelvic ligament was double-ligated with a stick tie and divided. Cephalad retraction of the uterus was achieved, and it was deviated laterally. Exposure of the uterine vessels was thus attained, and the vessels were cross-clamped with a curved Phanuef clamp. The vessels were then ligated and cut.

The rectum was mobilized from the posterior portion of the uterus and reflected inferiorly. Following a clamp-clamp-cut-tie routine, the cardinal ligament was clamped, ligated and divided bilaterally. Incorporating the uterosacral ligaments, curved clamps were placed bilaterally as the uterus was retracted cephalad.

A basin was made available to receive the specimen. The uterus was freed using Jorgensen scissors and was placed, along with dirty instruments, in a stainless steel kidney basin by the surgical technologist. The vaginal cuff was then closed using 0 Vicryl suture on a CT-1 needle.

A count of all disposable supplies was initiated and was reported as correct. Extra long forceps were used to facilitate closure. The peritoneum was closed in a similar fashion. Warm irrigation fluid was prepared for use in the peritoneum. The abdominal cavity was thoroughly irrigated with approximately 700 cc of 0.9% sodium chloride irrigation fluid.

Irrigation fluid was aspirated using a Via-Guard® suction device over a Yankauer suction tip, and hemostasis was achieved. The ureters were then assessed for integrity and proper position. As no

other pathology of the ovaries was detected, they were left and sutured to the lateral pelvic walls.

The abdomen was then prepared for closure. The self-retaining retractor and five laparotomy sponges were removed and counted. The peritoneum was closed using 2-0 Monocryl® CT-1 suture. The peritoneal count was initiated and consisted of a complete count of all disposables and instrumentation. The count was reported as correct.

The fascia, muscle and subcutaneous tissue were closed using 0 Vicryl CT-1 suture. Toothed tissue forceps were used to aid in closure. The skin was then closed with staples. Toothed Adson forceps were used to aid in approximation of the skin.

The skin count was initiated upon closure, and the count of all disposables was correct. Triple antibiotic ointment was applied to the staple line, followed by Telfa pads for non-adhesive contact with the wound, 4x4 fluffs and ABDs for absorption, and paper tape as an adhesive layer for support of the dressing. All equipment was disconnected, and the drape was removed.

The patient emerged from anesthesia successfully and was assessed and extubated by the anesthetist. The restraints were removed, and the patient was transferred to PACU by the surgical team. No postoperative complications were noted. Intraoperative blood loss was approximately 150 cc. Total urine output was 140 cc.

The specimen was transferred to a biohazardous materials specimen container, which

Brief overview of fibroids

A fibroid, also known as a uterine fibroma (or, more correctly, uterine leiomyoma), is a benign tumor of the myometrium.^{2,13} These tumors grow from the middle layer of the uterine wall and are composed of muscle and fibrous tissue. Fibroids are common in women, especially those over 35 years of age, and they are the most frequent indication for hysterectomy.⁸

As many as 50% of women have fibroids. Although the condition is typi-

cally asymptomatic, many women experience such complications as dysmenorrhea, menorrhagia, leukorrhea, pelvic pain and discomfort, and pressure on other surrounding tissues and organs.⁸ The various types of symptoms experienced are directly related to the location of the tumors.

Fibroid size can vary from a few millimeters in diameter to a tumor large enough to fill the entire abdominal cavity. The size of the tumor may be affected by

the age of the patient with regard to their reproductive capability. Fibromata are usually much larger in younger patients and tend to regress after menopause.¹³

There are several treatment options available, including induction of leutinizing hormone-release hormone (LHRH), which will temporarily shrink fibroids; electrosurgical removal during hysteroscopy; myomectomy; laser removal; cryoablation; and hysterectomy for more severe cases.^{8,13}

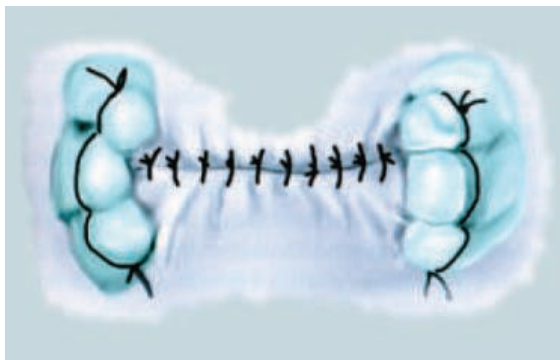
was labeled with patient information according to facility policy. The specimen was prepared by adding a formaldehyde solution and was transported to pathology by the circulating nurse.

DISCHARGE AND PROGNOSIS

A discharge letter and discharge information packet was signed and dated by the patient on the fourth postoperative day. The patient was voiding normally and ambulating well without aid. Wound dressings were clean and dry, and there was no sign of surgical site infection. The patient was instructed by the doctor that she would be able to return to normal activities after six to eight weeks.

At the time of discharge, the patient was given a prescription for hydrocodone 500 mg for pain. The patient was instructed to follow a regular diet and not to lift anything over 20 lbs. A follow-up appointment was scheduled for one week postsurgery.

FIGURE 4:
Vaginal cuff closure.



Courtesy Thomson Delmar Learning. *Surgical Technology for the Surgical Technologist: A Positive Care Approach*. ©2004.

POTENTIAL COMPLICATIONS

Complications following total abdominal hysterectomy occur in approximately 10–15% of patients.¹ Potential complications include bowel obstruction or damage, bladder injury, wound infection or dehiscence, injury to the ureters, and hemorrhage.⁹

ABOUT THE AUTHOR

Douglas Hughes currently works as a Certified Surgical Technologist and Certified Registered Central Service Technician at Mercy Medical Center at Nampa, Idaho. In February, 2007, he graduated with an associate degree from San Joaquin Valley College in Fresno, California and received his CST credential shortly after graduation.

References

1. Carter J. Alternatives to Total Abdominal Hysterectomy. *JLS*. 1997;1:259-262. Available at: http://www.obgyn.net/women/women.asp?page=/ah/articles/specialtwo_6-99. Accessed September 16, 2006.
2. Chelmow D, Lee S, and Evantash E. Gynecologic Myomectomy. 2005. Available at: <http://www.emedicine.com/med/topic3319.htm>. Accessed September 17, 2006.
3. Dhillon T. Total Abdominal Hysterectomy Preference Card. 2006. Unpublished surgical preference card, Madera Community Hospital, California.
4. Drugs.com. Drug Information from Desflurane (Inhalation-Systemic). 2006. Available at: <http://www.drugs.com/cons/Desflurane.html>. Accessed September 16, 2006.
5. Goldman M. *Pocket Guide to the Operating Room, 2nd ed.* Philadelphia, Pa: FA Davis;1996.
6. Long P. Generalized Anxiety Disorder. 2005. Available at: <http://www.mentalhealth.com/dis1/p21-an07.html>. Accessed September 16, 2006.
7. Mayo Clinic. Uterine Fibroids. 2006. Available at: <http://www.mayoclinic.com/health/uterine-fibroids/DS00078/DSECTION=3>. Accessed September 16, 2006.
8. New York State Department of Health. Hysterectomy. 2002. Available at: <http://www.health.state.ny.us/nysdoh/consumer/women/hyster.htm>. Accessed September 16, 2006.
9. Price P, Frey K, & Junge TL, eds. *Surgical Technology for the Surgical Technologist: A Positive Care Approach, 2nd ed.* New York, NY: Thomson Delmar Learning;2004.
10. RxList. Diprivan: Clinical Pharmacology. 2006. Available at: http://www.rxlist.com/cgi/generic2/propof_cp.htm. Accessed September 17, 2006.
11. Spratto G, Woods A. *PDR Nurse's Drug Handbook, 2006 edition.* New York, NY: Thomson Delmar Learning;2005.
12. University of California, San Francisco Medical Center, Comprehensive Fibroid Center. Fibroid Diagnosis—How Do I Know I Have Fibroids? Available at: http://www.ucsf.edu/fibroids/bg_diagnosis.html. Accessed September 16, 2006.
13. Venes D, ed. *Taber's Cyclopedic Medical Dictionary, 20th ed.* Philadelphia, Pa: FA Davis;2005.
14. Wikipedia. Benzodiazepine. 2006. Available at: <http://en.wikipedia.org/wiki/Benzodiazepine>. Accessed September 16, 2006.

Vicryl® and Monocryl® are registered trademarks of Ethicon, Inc. Via-Guard is a registered trademark of SurgiMark, Inc.