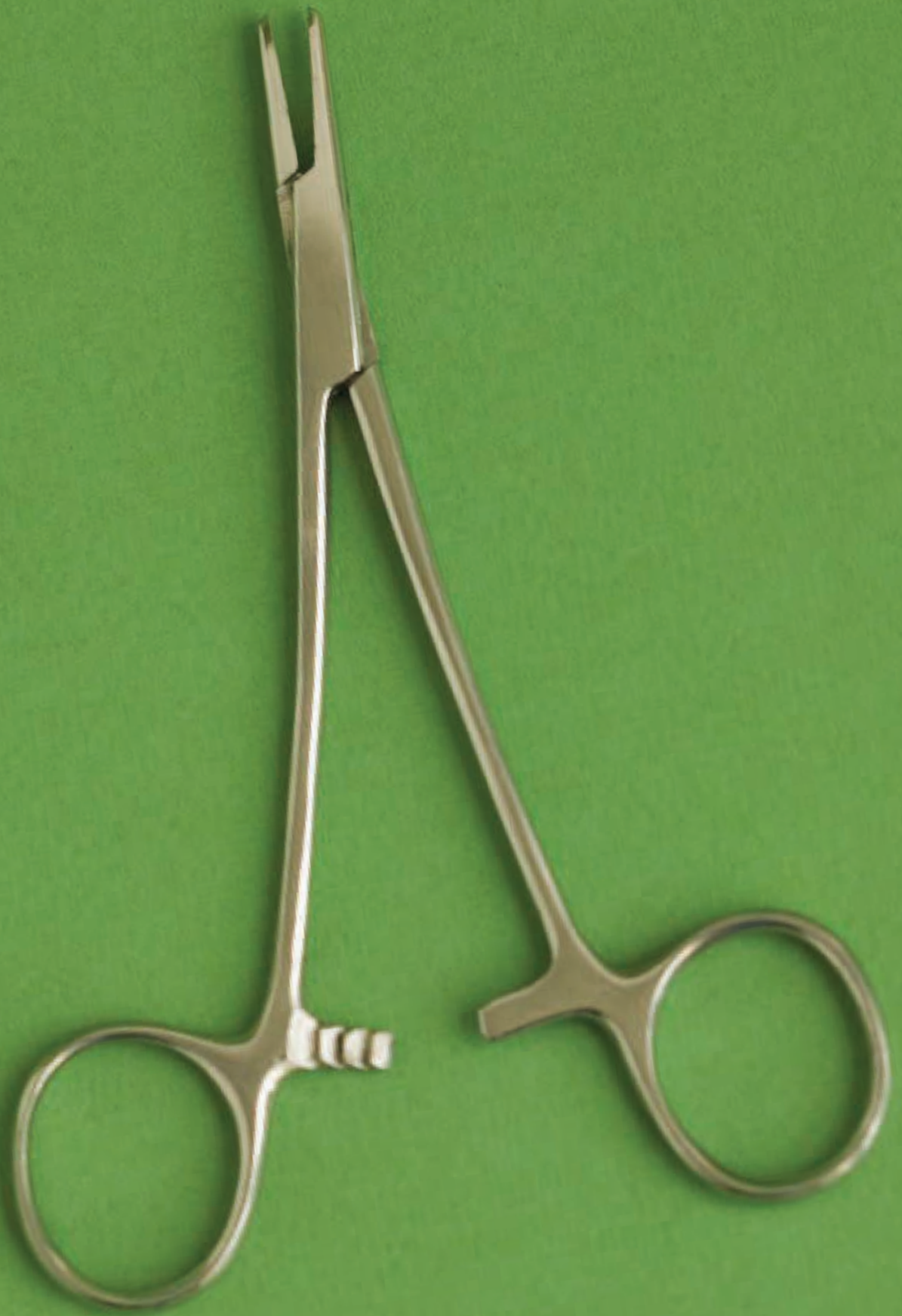



When Unexpected Complications Arise During Surgery—

A Case Study of a Total Abdominal Hysterectomy with Bilateral Salpingo-oophorectomy

KELLIE CARDOZA LONGATTI

A total abdominal hysterectomy is defined as the surgical removal of the uterus.

The procedure may be done in conjunction with the removal of one or both of the fallopian tubes and one or both of the ovaries. If all structures are removed, the procedure is called a total abdominal hysterectomy with bilateral salpingo-oophorectomy—or TAH-BSO.

NATIONAL STATISTICS

Total abdominal hysterectomy (TAH) is considered “the most common non-obstetrical procedure for women in the United States.”² Approximately 500,000 procedures are performed per year with a decrease of about 20% favoring the cervix-preserving supracervical hysterectomy.¹³

SURGICAL INDICATIONS

TAH-BSO can be performed for multiple conditions and pathologies, including:

- “Endometrial, tubal or ovarian malignancies
- Uterine sarcoma
- Uterine fibroids, both asymptomatic (if larger than 12 weeks of gestation size) and symptomatic
- Benign adnexal masses in postmenopausal women
- Dysfunctional uterine bleeding
- Endometriosis, chronic pelvic inflammatory disease and pelvic pain syndromes¹⁷

TAH is generally the preferred approach when patients present with malignancies or large uterine fibroids. This approach facilitates easier access to lymph nodes, surrounding structures and large masses.

The abdominal approach is also considered the foundation for treatment of uterine and ovarian cancers, because it allows for extensive inspection of other tissues.²

PROCEDURAL OVERVIEW

This article will describe the pre-, intra- and postoperative surgical case management of an 83-year-old female diagnosed with a pelvic mass. The prescribed treatment in this case was an exploratory laparotomy with TAH-BSO.

PATIENT'S MEDICAL HISTORY

The patient's medical history included several surgeries, including a thyroidectomy, cholecystectomy, fixation of multiple upper and lower extremity fractures, cervical spine surgery, breast biopsy and splenectomy.

The patient had been treated recently for a lower extremity blood clot and acid reflux.

At the time of admittance, the patient was hypertensive with a blood pressure of 180/130 mmHg.

Her medications prior to admittance included:

- Synthroid®, 125 mg daily, to compensate for the removed thyroid gland;
- Nexium®, 40 mg daily, to treat acid reflux; and

- Diovan® HCT, 185 mg daily, for treatment of hypertension.

PATIENT CONDITION UPON HOSPITAL ADMISSION

The patient presented with syncope and emesis. Her syncopal episodes were accompanied by the perception of a halo of light. According to the patient's chart, the patient had been referred to a cardiologist in the past for treatment of syncopal episodes.

The patient also complained of frequent emesis, frequent urination and pelvic pain.

The patient was alert and oriented at the time of arrival at the hospital. A physical examination revealed a soft, smooth cystic mass in the abdomen without ascites.

A pelvic exam revealed postmenopausal vaginal atrophy. The patient's cervix was deemed to be effaced.

The patient was admitted to the hospital for further testing due to the findings of the pelvic and physical exams. Further tests included an ultrasound, which determined the location of the pelvic mass, confirmed that no ascites was present and revealed that the mass was uterine in origin.

Frontal and lateral chest radiographs were taken, which revealed no chest masses, but displayed evidence of recent rib fractures. These were attributed to a fall related to her recent syncopal episodes.

Labwork results showed an elevated white blood cell count and the presence of protein in the patient's blood and urine, but were otherwise inconclusive.

Due to the inconclusive nature of the histology and urologic findings—combined with the presence of abdominal pain, a pelvic mass and syncopal episodes, it was determined that an exploratory laparotomy with TAH-BSO was indicated.

PREOPERATIVE DIAGNOSIS

The patient's preoperative diagnosis was a pelvic mass. The pathophysiology, which was subsequently discovered during the course of surgery,

was determined by pathologists to be advanced squamous cell carcinoma.

During the course of surgery, carcinoma was discovered in several tissues, including the peritoneum, cervix, vagina, bladder and bowel. The carcinoma was so pervasive that some structures—including the ovaries, fallopian tubes and much of the uterus and cervix—were not distinguishable from surrounding structures.

The tissue was found to be dark in color. In some locations, black, depressed spots were visible from a distance. Some of the tissue was stringy and friable, and in some areas—such as the cervical region—the tissue had the texture of thick liquid. The damage caused by the carcinoma was extensive.

ROOM PREPARATION

Surgical intervention began with preparing the room for the procedure. The anesthesia cart and supplies were placed at the head of the operating room table. The back table and Mayo stand were positioned toward the back of the operating room.

The case cart was brought into the room approximately 30 minutes before the procedure was scheduled to begin. For a complete list of equipment and supplies, see “Contents of Case Cart” on pg 163.

Once the case cart was opened, the back table pack was opened, followed by the basin set, the instrument set and the Bookwalter retractor set. A prep stand was prepared for the circulator, which included the Foley catheter and two sterile towels.

The surgical technologist began to scrub approximately 20 minutes before the procedure was scheduled to begin.

Once the surgical technologist was scrubbed in, the Mayo stand was used for gowning and gloving. The circulator disposed of the gown and glove wrappers, so the Mayo stand could be dressed by the surgical technologist.

The Mayo stand cover was placed on the Mayo stand, followed by two sterile towels laid flat and one sterile towel rolled to keep free ties and instruments steady.

The back table was arranged in a practical and useful manner, and the instrument tray was brought to the back table. Once the instruments had been inspected for sterility and all items were laid out appropriately on the back table, the surgical technologist and the circulator performed an initial count.

The count included the abdominal hysterectomy instrument set, the long dissection instrument set, the Bookwalter retractor, the large vein retractor, X-ray-detectable and laparotomy sponges, all three #10 blades, electrosurgical pencil tips and scratch pad, and all of the suture, excluding the free ties.

The items placed on the Mayo stand were positioned according to their order of use. Free ties were taken out of the packaging and placed under the roll towel, with approximately two inches protruding for access and to prevent tangling.

Two of the free ties were clamped within two tonsil clamps in preparation of ties on passes. The instruments on the roll towel included two Kelly clamps, two Mayo clamps, two Pean clamps, two long Aliss clamps, six long Kocher clamps, two tonsil clamps, two right-angle clamps, two Heaney clamps, two curved Ballentine clamps and two straight Ballentine clamps.

The remaining available space on the Mayo stand held one pair of long Metzenbaum scissors, one pair of curved Mayo scissors, one pair of straight Mayo scissors for suture, one long Debaquey forceps, one regular Debaquey forceps, one pair of Russian forceps, two medium Richardson retractors, two Army/Navy retractors and two X-ray-detectable sponges.

The three #10 blades were loaded onto knife handles. The first blade was placed onto a #3 knife handle for use on skin. The second blade was placed on a #3 knife handle for use on deeper tissues. The third blade was placed on a #3 long knife handle for the cervical incision. All of the #3 knife handles were placed on the Mayo stand as well.

Long Mayo-Hegar needle holders were loaded with 2-0 Chromic suture ligatures and placed on the Mayo stand.

A sterile towel was placed over these instruments. Then two light handles, suction tubing

with Yankauer suction tip attached, a nonperforating towel clamp and the handheld electrosurgical pencil were placed on the Mayo stand.

The Bookwalter retractor was set up on a second prep stand. The items in the Bookwalter set were counted in the initial count. The items were laid out in such a way that the surgeon could pick out the blades he wanted to use with ease. The oval ring was placed on the back table so that it could be brought up to the field after the peritoneum was opened and the abdomen was packed.

The surgical technologist prepared a pitcher filled with approximately 500 cc of warm normal saline. A small basin was filled with the remaining 500 cc.

Five laparotomy sponges were soaked in the saline-filled basin. The Asepto syringe was filled with approximately 60 cc of warm saline from the pitcher and set aside on the back table.

POSITIONING THE PATIENT

At this time, the patient was brought into the operating room on a gurney. The patient was awake and alert and had been given a sedative.

The patient was asked to aid in positioning herself onto the operating table and was compliant. Once in the supine position, a safety strap was secured approximately six inches above the patient's knees.

The patient's arms were placed on padded arm boards, and a blood pressure cuff and pulse oximeter were secured.

An IV line had been placed while the patient was in the preoperative holding area, and a 1,000-cc bag of lactated Ringers solution was secured to her IV tubing.

The anesthesiologist proceeded with a full induction sequence, and the patient was intubated.

Once under general anesthesia, the patient's vital signs were noted as follows: blood pressure

Procedural overview—Total abdominal hysterectomy with bilateral salpingo-oophorectomy

The steps typically taken in completing a routine TAH-BSO are as follows:

- Open abdomen and retract intestines to expose reproductive organs.
- A tenaculum is placed at the fundus of the uterus for ease of manipulation.
- Heaney clamps are placed around the broad ligaments encompassing the round and ovarian ligaments bilaterally.
- The round ligaments are secured with suture ligatures and then divided with curved Mayo scissors, which creates anterior and posterior flaps—or“leaves”—of the broad ligament.
- The anterior and posterior flaps are then incised with Metzenbaum scissors.
- The bladder is dissected from the uterus and cervix using blunt dissection.
- The broad ligament is dissected from the lateral portions of the uterus using blunt dissection.
- Any bleeding vessels are clamped and tied.
- The posterior portion of the broad ligament is cut with a scissors or scalpel.
- The ureters and external iliac vessels are identified and protected.
- The uterus is manipulated upward and toward the lateral position to facilitate exposure of the uterine vessels and lower ligaments.
- The curved Ballentine clamps are passed, and the vessels are clamped, cut and tied.
- The rectum is freed from the cervix and mobilized out of the way.
- The cardinal ligaments are clamped, cut and tied.
- The uterus is manipulated upward again.
- The uterosacral ligaments are located and then clamped, cut and tied.
- The cervix is amputated from the vagina with a scissors or scalpel.
- The specimen is removed from the pelvic cavity and passed off the field.
- Kochers are passed to elevate and approximate the vaginal cuff, which is then sutured in interrupted fashion.
- The ligament remnants are sutured to the vaginal cuff.
- The peritoneum is approximated over the bladder, vaginal vault and rectum.
- The abdomen is irrigated, and all laparotomy sponges are removed.
- A full count is performed.
- The abdomen is closed, and a final count is performed.

was 180/130 mmHg, O₂ saturation was 96%, and temperature was 97.6° F.

The patient's arms were secured to the arm boards with towels placed around the arm and arm board and fastened with perforating towel clamps.

At this time, the surgeon entered the operating room and began to examine the surgical site. The abdomen was palpated, and the surgical site marked with a sterile marking pen.

The surgeon then left the room to begin his scrub. The patient's legs were put into a slight "frog leg" position.

SKIN PREPARATION

The blanket and gown were pulled back to expose the abdominopelvic area. The abdomen was prepped by the circulator using Betadine® gel and one sterile towel to smooth the gel over the entire abdominal area from just under the breast area to the iliac crests.

A vaginal preparation was performed using Betadine® solution applied to the upper, middle and lower thighs toward the vagina and to the vaginal area from the urethral meatus to the rectum.

The Foley catheter balloon was tested and deemed to be in working order. The Foley catheter was then inserted, and the collection bag was placed below the table in a conspicuous area visible to the circulator. The patient was returned to the supine position.

PROCEDURAL OVERVIEW

Upon re-entering the room, the surgeon was gowned and gloved. The surgeon informed the surgical technologist that an assistant would be assisting him later in the case. The surgical technologist then requested another gown and gloves for the assistant.

Four, folded sterile towels were passed to the surgeon who then used them to square off the surgical site. They were not secured with clamps.

The laparotomy drape was passed to the surgeon, and the tabs were peeled off. The surgeon and the surgical technologist then opened the drape and laid it appropriately on the patient,

allowing for the fenestration to reveal the surgical site.

The anesthesiologist clamped the drape to the IV poles, and the Mayo stand was brought up to the field.

The light handles were handed to the surgeon, while the surgical technologist fastened the electrosurgical pencil and suction tubing to the drape with a non-perforating towel clamp.

The electrosurgical scratch pad and holster were placed conspicuously on the field.

Two X-ray-detectable sponges were laid near the surgical site, and the sterile towel over the instruments was removed and placed on the back table. The back table was then brought to the surgical technologist by the circulator, and no contamination was noted.

The anesthesiologist informed the surgeon that the patient was experiencing hypertension, but to proceed.

The circulator called for a "time-out," and the patient's name, surgeon's name and planned treatment were called out and confirmed.

The #3 scalpel was passed to the surgeon, and an eight-inch midline incision was made from approximately four inches below the xiphoid process to the symphysis pubis—avoiding the fal-ciform ligament on the right side of the patient's umbilicus. The cut time was 1:45 pm.

The subcutaneous and adipose tissues were dissected with the electrosurgical pencil. X-ray-detectable sponges and the electrosurgical pencil were used to achieve hemostasis.

The adipose tissue was dissected from the rectus fascia with the electrosurgical pencil, and Army/Navy retractors were passed for retraction of the skin, subcutaneous tissue and adipose tissue.

The second #3 knife was passed, and the rectus abdominus fascia was incised. The curved Mayo scissors were passed to the surgeon, and he cut the fascia vertically toward the xiphoid and then down toward the symphysis pubis.

The underlying rectus muscle was spread with Metzenbaum scissors in an opening and closing motion to create an opening which was then retracted with medium Richardson retractors.

Once the opening was sufficient, two Kelly clamps were passed to grasp the peritoneum at each end of the opening. Once the peritoneum was grasped and lifted off the bowel, Metzenbaum scissors were passed, and the peritoneum was cut.

Once the peritoneum was opened, the skin, subcutaneous tissue, adipose tissue, fascia, muscle and peritoneum were pulled and stretched by the surgeon and the surgical technologist preceptor.

A large opening was created by the stretching and pulling, and the bowel was retracted back by hand. The soaking laparotomy sponges were wrung out and passed to the surgeon and the X-ray-detectable sponges were removed. The surgeon used the sponges to pack away the bowel.

The surgeon then asked for the patient to be placed into a slight Trendelenberg position. This allowed for ease of packing away the bowel and for placement of the Bookwalter retractor.

The oval ring of the retractor was passed, and the preceptor held it in place while the surgeon looked for the blades he preferred.

He picked one Balfour blade with ratchet, and three 2"x4" Kelly blades and ratchets. He placed one Kelly blade at the superior portion of the incision and two Kelly blades at the lateral portions of the incision.

He then identified the uterus and manipulated it upward. Using blunt dissection, the surgeon removed the visceral bladder reflection from the uterus.

A laparotomy sponge was placed over the bladder, and the bladder blade was positioned in a manner that retracted the bladder away from the uterus.

Once the Bookwalter retractor was secured, the surgeon asked the anesthesiologist to return the patient to a level position.

The assistant arrived, and the surgical technologist gowned and gloved him. During this time, the surgeon began to study the anatomy of the patient. The surrounding anatomy appeared abnormal.

The uterine tissue appeared jaundiced and, upon palpation, was able to be depressed with a finger as in the manner of a fluid-filled sac.

The surgeon ordered a washing specimen. The Asepto syringe containing warm, normal saline was passed to the assistant, who expressed the saline into the pelvic cavity.

The surgeon then advised the assistant to collect as much of the fluid as possible for cytologic examination.

The assistant collected approximately 40 cc of fluid and passed it to the surgical technologist. The surgical technologist passed the syringe to the circulator, who labeled it appropriately. The cytologist was then called.

Once the cytologist entered the operating room, the specimen was collected and processed in cytology. During the course of the surgery, the cytologist did not report back to the surgeon, but to the circulator.

The surgeon requested a gallbladder trocar to drain the uterus. The circulator located and passed the trocar onto the field.

Once the trocar was inserted into the uterus, it was discovered that the myometrium of the uterus was no longer intact and had become purulent. The visceral layer of the uterus was the only portion still intact.

The drainage of the uterine contents contained approximately 300 cc of ichorous pus. Strings and masses of tissue could be visualized in the suction canister.

At the surgeon's request, the pathologist was called to retrieve the suction canister and examine the contents of the uterine sac.

The uterine sac collapsed and remained attached to the suspensory ligaments. The anesthesiologist reported maintained hypertension and advised the surgeon to proceed quickly.

Due to the pathology and anatomy of the patient, many of the steps typically performed in a TAH-BSO (see sidebar, pg 160) were not able to be carried out during this procedure.

Upon examination, it was noted that the broad ligament and round ligament were intact. The surgeon and the assistant began the process of dividing the ligaments bilaterally.

Debaquey forceps were passed to the surgeon, so he could grasp the round ligament. Then, a Heaney clamp was passed, and the right round

ligament was clamped. Debaquey forceps and a Heaney clamp were passed to the assistant for clamping the round ligament on the left side of the uterus.

A long needle holder was passed to the surgeon with a 2-0 Chromic suture ligature. The surgeon tied the suture, and the assistant cut it with suture scissors.

The surgeon requested another suture ligature to finish ligating the round ligament. The suture was tied and then cut with suture scissors.

The round ligament was then divided with curved Mayo scissors. The broad ligament was clamped with a Heaney clamp and incised with a #3 knife. The broad ligament was dissected bluntly away from the lateral borders of the uterus.

At this time, bleeding began from the vessels of the broad ligament. Electrocautery was used for cessation of the bleeding, but had little effect.

The vessels on both the right and left sides were ligated with approximately ten 2-0 Chromic and 2-0 Vicryl® free ties and stick ties.

Blood loss from the broad ligament was approximately 700 cc. At this time, the surgical technologist requested approximately 20 additional laparotomy sponges to aid in hemostasis.

The anesthesiologist reported that the patient was tachycardic and that the surgery should proceed quickly.

The patient was placed in a slight Trendelenberg position to aid in restoring normal heart rate.

The ovarian ligaments could not be identified, nor could the fallopian tubes or ovaries. There was insufficient mesosalpinx to be noted.

The surgeon manipulated the uterine sac upward to view the posterior sheath of the broad ligament, which was incised using Metzenbaum scissors. At this time, the ureters could not be identified, and bleeding from the uterine vessels became overwhelming.

1 Chromic sutures were passed one after the other in an attempt to stop the bleeding. Laparotomy sponges were passed to apply pressure to the bleeding area.

The case cart used in this procedure contained the following:

- One abdominal hysterectomy instrument set
- One Bookwalter retractor
- One long dissection instrument set
- One large vein retractor
- Gowns and gloves for all team members
- Three six-pack sterile towels, one major abdominal pack, one laparotomy sheet
- One double basin set, one Klenzyme® one-ounce package
- One handheld electrosurgical pencil, one electrosurgical pencil extender tip, one 10" grounding pad
- Two green bed sheets, one case cart cover
- One 3,000-cc suction canister, one canister lid, one biohazard tag
- One 16-FR Foley catheter tray, one uc/cath strip fastener
- One surgical marking pen with sterile labels, one four-ounce specimen container
- One box of 10 X-ray-detectable sponges, one package of 10 18x18 laparotomy sponges
- One plastic Poole suction tip, one Asepto bulb syringe
- One skin scrub tray, one bottle of Betadine gel
- Two Primapore™ 11.5"x4" sterile dressing, one Primapore 8"x4" sterile dressing
- One kidney basin, two specimen cups, one pour pitcher, one small basin
- One back table garbage bag, one Mayo stand cover, one needle safety counter
- One medium Ligaclip applier and Ligaclips
- One large Ligaclip applier and Ligaclips
- One suction tubing, one plastic Yankauer suction tip
- Three #10 blades, two #3 knife handles, one #3 long knife handle
- One 3-wide skin stapler
- Free ties: 1 Chromic 18", 2-0 Silk 18"
- Stick ties: 2-0 Chromic SH 27"
- Peritoneum: 2-0 Vicryl CT-1 36"
- Fascia: 0 Vicryl CT-1 36"
- Uterus: 1 Chromic CT-1 36"
- Vaginal cuff: 1 Chromic CT-1 36"
- One bottle sterile water 500 cc, one bottle 0.9% sodium chloride 1,000 cc
- 0.5% bupivacaine plain 50 cc

The surgical technologist requested 10 more laparotomy sponges and five 1 Chromic sutures.

Once the bleeding had been controlled, the anesthesiologist requested that the circulator call the blood bank to have one unit of type O whole blood sent to the operating room.

At this time, blood loss was estimated at 3,000 cc. The anesthesiologist consulted with the surgeon, and it was determined to proceed with the case.

The bladder was observed, and some abnormal spotting was noted. Using blunt dissection, the bladder was separated from a mass of tissue that had once been the cervix. The external os and the fornix of the vagina were partially intact. The inferior portion of the intact cervix was grasped with a long Allis, and curved Mayo scissors were passed.

The inferior portion of the cervix was amputated from the vagina. When the surgeon pre-

pared to pass the specimen, the tissue frayed and was removed in string-like masses. The surgeon ordered that the pathologist be called to collect the specimen.

As the vaginal cuff was being grasped with long Kochers, bleeding started again. Several 1 Chromic sutures and laparotomy sponges were passed to aid in hemostasis. The blood loss became so significant that the anesthesiologist ordered the surgery halted.

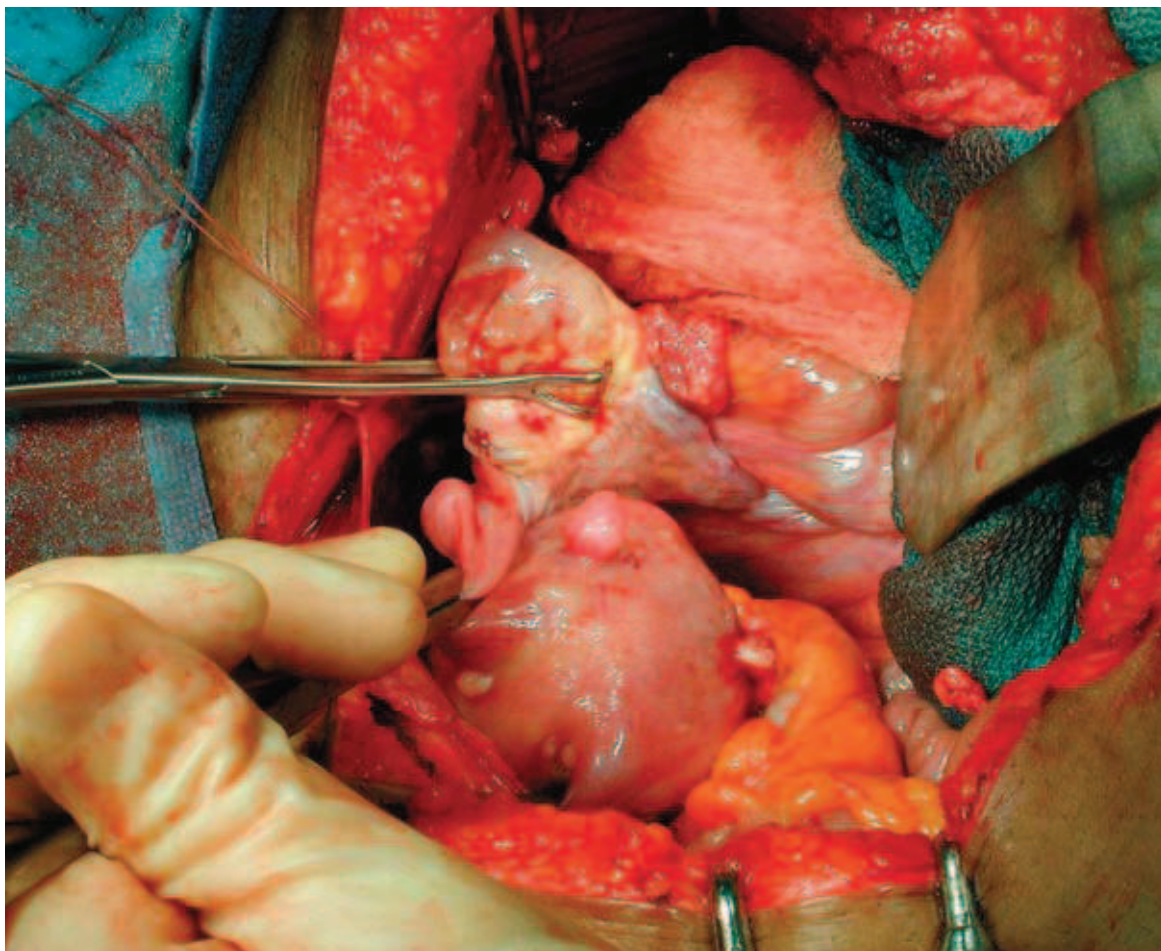
The abdomen was packed with approximately 10 laparotomy sponges, and pressure was held. Blood loss at this point was approximately 9,000 cc, and the patient was extremely hypotensive with a blood pressure of 60/40 mmHg.

The patient was also bradycardic, pale and diaphoretic. The anesthesiologist began resuscitative efforts.

The anesthesiologist ordered four units of packed red blood cells and a blood warmer. The

Figure 1

The right ovary, as viewed during a TAH.



Courtesy: Healthline.com

circulator requested that the OPS manager be present for the remainder of the case, and the crash cart was placed just outside the operating room by a surgical services associate.

The anesthesiologist ordered 2,000 cc of warmed lactated Ringers be given intravenously and began IV drug therapy. The anesthesiologist then began administering dopamine to aid in vasoconstriction and myocardial contractility and to increase heart rate, blood pressure and cardiac output.

With assistance from the OPS manager, the circulator and another RN, the anesthesiologist attained central line access and was able to administer norepinephrine and hydrocortisone for acute adrenal insufficiency.

The blood warmer and four units of packed red blood cells arrived, and the anesthesiologist and circulator immediately began their administration. The anesthesiologist then ordered four more units of packed red blood cells.

Once the patient had stabilized enough to continue, the anesthesiologist gave the surgeon permission to proceed.

At this time, the pathologist reported back to the surgeon that there were no clear margins in the specimen collected earlier and that the tissue could not be identified.

The surgeon removed the laparotomy sponges from inside the abdomen and attempted the suturing of the vaginal cuff again. The vaginal cuff was grasped with Kochers, and 1 Chromic sutures with CT-1 needles were passed on long needle holders. The suture scissors were passed to the assistant.

After the first suture was passed through the tissue, the surgeon noted that the tissue was friable and not capable of holding suture. The surgeon began to pull the tissue out in strings in an attempt to reach viable tissue.

Twenty-seven attempts were made to close the vaginal cuff by suture. At this point, the blood loss warranted halting the surgery again. The time was 5:30 pm, and blood loss was estimated at approximately 15,000 cc.

By this time, 65 laparotomy sponges and 34 1 Chromic sutures had been used. The circulator

had wrung out the used laparotomy sponges and collected the blood for measurements.

The surgical technologist and surgical technologist preceptor were relieved for the day. The relief person ordered 20 additional laparotomy sponges and 10 additional 1 Chromic sutures, assisted the surgeon and assistant in hemostatic efforts, and maintained the sterile field.

The anesthesiologist once again began hemostatic, pharmaceutical and cardiac life-saving measures. At 7:02 pm, the patient went into a state of paroxysmal atrial fibrillation, and the anesthesiologist required that the surgery be terminated.

The surgeon packed the vagina and pelvic region with laparotomy sponges and closed the midline incision with a running stitch.

Total blood loss during the procedure was approximately 16,000 cc, and 15 units of packed red blood cells and one unit of platelets were administered. Urine output was approximately 300 cc; gross hematuria was notable.

The patient was transported to the ICU, where several diagnostic tests were performed. Histology results indicated hypothyroidism, stress hypoglycemia and hypokalemia.

The patient was diagnosed with post-traumatic hypoxia, paroxysmal atrial fibrillation, hemorrhagic shock and advanced squamous cell carcinoma.

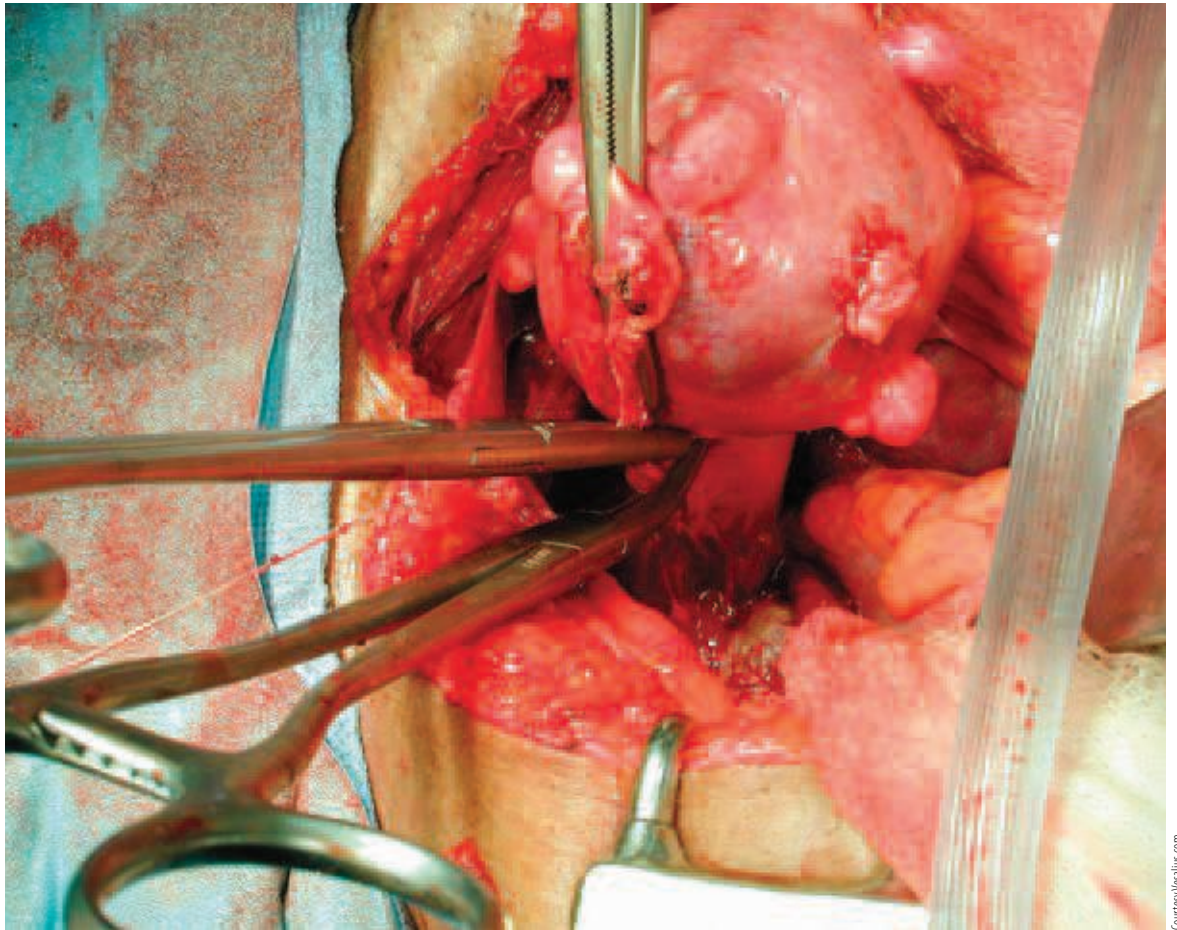
While in the ICU, the patient received one more unit of packed red blood cells and six units of platelets.

At 11:42 pm, the patient was deemed stable enough to finish the previous procedure and was taken back to the operating room. She was placed in high lithotomy position, and the vaginal area was prepped with Betadine solution.

Due to the extent of bleeding from the previous surgery, the vaginal cuff was left open and packed with laparotomy sponges. During the second procedure, the laparotomy sponges were removed vaginally and replaced with fresh sponges.

At 12:32 am, the patient was taken to the ICU, where antibiotics were administered by request of the surgeon after noting the presence of thick, white vaginal secretions.

Figure 2
The uterine artery is clamped during a TAH.



The patient remained intubated, and her airway was managed mechanically. The patient was sedated and restrained due to combativeness and an attempt to extract the endotracheal tube. The patient did not experience wakefulness, but did respond to basic commands, such as raising her arm.

Upon physical examination at 7:30 am the following day, abdominal distention and firmness was noted. However, it was deemed that the patient could not tolerate any further surgical exploration or correction at that time.

The patient was placed on an insulin drip for treatment of hyperglycemia, fluids and electrolytes to correct fluid imbalance, vancomycin for treatment of infection, and phenylephrine hydrochloride and amiodarone hydrochloride for treatment of paroxysmal atrial fibrillation.

The patient had an advanced directive, which gave the patient's spouse the authority to make critical care decisions on her behalf.

In the presence of several of the patient's family members, the final postoperative care performed before the patient died was the administration of the Sacrament of the Sick.

PROFESSIONALISM AMID GRIEF

Although the patient in this case did not have a positive outcome, it is crucial to remember the surgical technologist's motto: *Aeger Primo*—the patient first.

Regardless of a procedure's possible outcome due to the patient's age, pathology or other circumstances beyond one's control, the patient must come first. Every decision that the surgical team makes must be for the ultimate benefit of the patient.

A surgical team must not be mediocre, unsympathetic or thoughtless. Surgical team members must be willing to continually strive for the best for their patients.

Overview of relevant anatomy

The anatomy of the pelvic cavity pertinent to TAH-BSO is quite extensive.

Peritoneum

The peritoneum is a serous membrane made up of epithelial cells. The peritoneum can be divided into two layers: the parietal layer, which lines the cavities, and the visceral layer, which covers internal organs.¹

The function of the peritoneum includes protecting nearby organs and providing frictionless surfaces for organs to slide over. The peritoneum also carries blood, lymphatic vessels and nerves.¹

Intestine

While the small and large bowel are typically not disturbed surgically during a TAH-BSO, it is important to note that these structures must be retracted back to expose the pelvic contents. Therefore, a brief description of these structures is necessary.

The large and small intestine are the absorbers of the digestive tract. The small intestine absorbs nutrients, water and minerals from digested food. The large intestine also absorbs water and creates waste products.¹

The large and small intestine collectively reach between 15 and 25 feet in length and are compressed into a space that measures approximately 16"x12"x8".¹

Ovaries

The ovaries are the reproductive glands of the female. Typically, females have two ovaries located bilaterally next to the uterus. The ovaries are approximately four centimeters in length and are held in place by the suspensory, broad and ovarian ligaments.^{1,8}

The ovaries house approximately 300,000 eggs. The glandular portions of the ovaries—the corpus luteum—produce estrogen and progesterone.^{1,8}

The oviducts, also called fallopian tubes, are the passages through which the ova travel to the uterus. The fallopian tubes are made up of

smooth muscle and are controlled by peristalsis. They are approximately 5" long and extend from the fundus of the uterus to near the ovaries. The proximal ends are called fimbriae and are "finger-like" projections that produce small, wave-like motions that sweep the ova into the tubes for fertilization.^{1,19}

Uterus

The uterus measures approximately three inches long and is considered a hollow organ consisting of three layers of tissue: the endometrium (the interior lining), the myometrium (the muscular layer), and the perimetrium (the visceral layer).

The uterus is supported by several ligaments and suspensory systems.

The broad ligament consists of folded peritoneum housing the ovarian and uterine vessels, the ovarian ligament and cellular tissue. The broad ligament extends from the pelvic wall to the lateral borders of the uterine corpus. The broad ligament also creates the mesosalpinx, mesovarium and mesometrium.^{8,19}

Bilaterally, the round ligament extends from inferior to the fallopian-uterine attachment, then connects to the broad ligament and continues through the inguinal ring and downward, terminating at the labia major.¹⁹

Cervix

The cervix is the opening of the uterus to the vagina. It begins at the internal os, leads through the cervical canal and the external os, terminating in the proximal end of the vagina. The cervix is also considered the neck of the uterus. It is approximately one inch long and its opening measures less than one millimeter in diameter.¹⁹

Vagina

The vagina is considered the distal portion of the birth canal and measures approximately three inches in length. It is composed of epithelial tissue and is lined with a mucous membrane. The mucous membrane creates folds, called rugae, which increase the surface area of the vaginal canal and expand during childbirth.¹

Bladder and ureters

The urinary bladder and ureters are important anatomic landmarks during a TAH-BSO. Both structures must be identified and retracted away from the surgical site.

The urinary bladder is the collection point for urine. The bladder consists of many layers such as mucosa, connective tissue, involuntary muscle, and peritoneum. The inner layer of the bladder has mucosal folds or rugae much like the interior of the vagina. These are present throughout with the exception of a triangular spot which is in the inferior portion of the bladder called the trigone. The trigone provides bladder stability and does not allow either urine back-flow or ureteral stretching.¹

The ureters, although extraperitoneal, are exposed to some danger during a TAH-BSO. They run bilaterally from the kidneys to the urinary bladder and lie exposed during bladder retraction. The ureters are comprised of epithelial tissue and controlled by gravity and peristalsis. They carry urine from the kidneys to the urinary bladder.¹

Additional

There are several vessels that add vascularity to the pelvic cavity. The smaller vessels include the uterine vessels, the obturator vessels, and the superior vesicle artery, which runs throughout the mesosalpinx and broad ligament.

The larger vessels, which are exposed during a TAH-BSO, are the external iliac vessels. These provide the major blood supply for the pelvic region.¹¹

There are also several lymphatic vessels in the pelvic region, including the periaortic lymph nodes, the common iliac lymph nodes, the external iliac lymph nodes and the deep inguinal lymph nodes.¹¹

The nerve branches that innervate the pelvic region originate from the hypogastric plexuses and are controlled by the autonomic nervous system.¹¹

ABOUT THE AUTHOR

Kellie Cardoza Longatti currently works at a hospital in California. She graduated from San Joaquin Valley College in October, 2007. She wrote this article prior to graduation.

EDITOR'S NOTE:

All procedure-specific clinical information was obtained from the patient's chart and the surgeon's preference card with permission.

References

1. Cohen BJ. *Memmler's The Human Body Health and Disease*. Baltimore, MD: Lippincott Williams & Wilkins; 2005.
2. Crandall CJ. Hysterectomy. Available at: <http://www.medicinenet.com/hysterectomy/article.htm>. Accessed May 4, 2007.
3. Doherty GM, Lowney JK, Mason JE, Reznik SI, Smith MA, eds. *The Washington Manual of Surgery*, 3rd ed. St Louis, MO: Lippincott Williams & Wilkins; 2002.
4. Dominowski G. Pathology: Squamous Cell Carcinoma. Available at: <http://www.emedicine.com/ent/topic671.htm>. Accessed May 4, 2007.
5. Lee JA. *Abdominal Exploration Series*. University of Maryland Medical Center. Available at: <http://www.umm.edu/ency/article/002928.htm>. Accessed May 4, 2007.
6. Marcucci L. Total Abdominal Hysterectomy (Uterus Removal). Available at: <http://www.insidesurgery.com/OBGynsurgery>. Accessed May 4, 2007.
7. National Cancer Institute. *Dictionary of Cancer Terms*. Available at: http://www.cancer.gov/Templates/db_alpha.aspx?Cdrid=46056. Accessed May 4, 2007.
8. Netter F. *Atlas of the Human Body*. New York, NY: Icon Learning Systems; 2006.
9. Patient chart and surgeon preference card. Obtained with permission.
10. Price P, Frey K, Junge TL, eds. *Surgical Technology for the Surgical Technologist: A Positive Care Approach*, 2nd ed. New York, NY: Delmar Learning; 2004.
11. Rothrock JC. *Alexander's Care of the Patient in Surgery*, 13th ed. St Louis, MO: Mosby Elsevier; 2007.
12. Sharma K, Khurana N, Chaturvedi KU. Primary Squamous Cell Carcinoma [Electronic version]. *Journal of Gynecological Surgery*, December 2003.
13. Sills ES. Abdominal Hysterectomy: Trends, Analysis, and Sexual Function. *OBGYN.NET Publications*. Available at: http://www.obgyn.net/women/womanasp?page=/ah/articales/special_5-99. Accessed May 4, 2007.
14. Spratto GR, Woods AL. *PDR Nurse's Drug Handbook*, 2006 ed. New York, NY: Thomas Delmar Learning; 2005.

15. Tighe SM. *Instrumentation for the Operating Room: A Photographic Manual*, 6th ed. St Louis, MO: Mosby; 2003.
16. Vilanova Jr, P. Anesthesiology: Sedation of Patients in the ICU. Available at: <http://www.medstudents.com.br/anest/anest4.htm>. Accessed May 8, 2007.
17. Webb MJ. *Mayo Clinic Manual of Pelvic Surgery*, 2nd ed. Philadelphia, PA: Lippincott Williams & Wilkins; 2000.
18. Winter WE, Gosewehr JA. Uterine cancer. Available at: <http://www.emedicine.com/med/topic2832.htm>. Accessed May 5, 2007.
19. Venes D, ed. *Taber's Cyclopedic Medical Dictionary*, 19th ed. Philadelphia, PA: FA Davis; 2001.

Betadine is a registered trademark of Purdue Pharma LP.

Diovan is a registered trademark of Novartis Pharmaceuticals Corporation.

Klenzyme is a registered trademark of Steris Corporation.

Nexium is a registered trademark of Astra Zeneca LP.

Primapore is a registered trademark of Smith and Nephew.

Synthroid is a registered trademark of Abbott Laboratories.

Vicryl is a registered trademark of Johnson & Johnson.