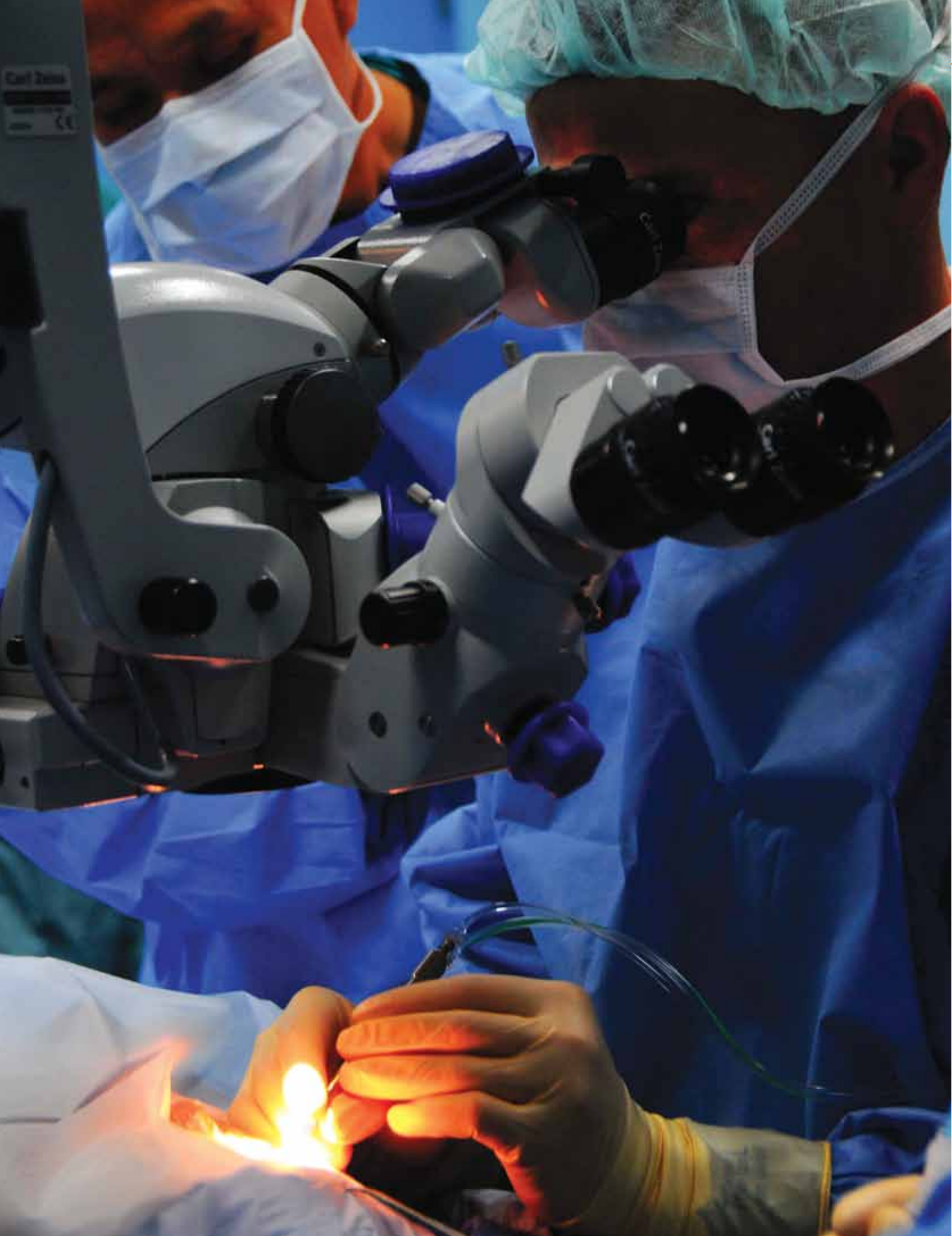



# Cannulated Retinal Surgery

by Donna Mrugala, CST, BS

**T**he eye is one of the most complex organs of the human body. There are many small structures within the eye that work together to form the basis for one of our most valued senses – sight. When the eye is compromised or damaged, surgical intervention may be needed to repair it. Cannulated retinal surgery is one of the most common procedures performed on the eye.

## ANATOMY OF THE EYE

The sclera, or white of the eye, is the outermost part of the eye. It is approximately 1 mm of tough, opaque, white connective tissue. The sclera's job is to protect the eye and provide support and structure. It extends posteriorly all the way to provide an opening for the optic nerve. The sclera is attached to tendons that connect to four primary muscles and two oblique muscles that move the eyeball.

The choroid is a layer of blood vessels and connective tissue that is situated between the retina and the sclera. It is part of the uvea and supplies nutrients to the inner parts of the eye. It connects with the ciliary body toward the front of the eye and is attached to the edges of the optic nerve at the back of the eye.

The conjunctiva extends from the limbus (also known as the pars plana) of the cornea and covers the exposed area of the globe. It folds back onto the inner surfaces of the eyelids. The pars plana is an avascular area that is clear of major intraocular structures.

The front covering of the eye, or cornea, is a translucent structure that is approximately 0.5 mm thick. Together with the sclera,

## LEARNING OBJECTIVES

- ▲ Review the relevant anatomy for this procedure
- ▲ List the required equipment for pars plana vitrectomy
- ▲ Evaluate the step-by-step process of pars plana vitrectomy
- ▲ Assess the possible risks and complications associated with this procedure
- ▲ Explore advancements in the field of eye surgery

the cornea makes up the outermost layer of the eye. It is composed of five, distinct layers: the epithelium, Bowman's membrane, stromal, descemes and the endothelium. The cornea is avascular unless the patient is afflicted with blood vessel neo-vascular disease. The cornea allows light to be bent and focused on the retina.

A pars plana vitrectomy (PPV) involves the surgical removal of foreign matter or blood from the vitreous. In some instances, it can include the removal of the vitreous itself.

The uvea, or uveal tract, is made up of three parts: the iris, ciliary body and choroid. The uvea provides the main blood supply through this vascular compartment of the eye. The iris is the colored muscular diaphragm that opens and closes in front of the eye. The ciliary body is a band-like structure that encircles the inside of the sclera toward the front of the eye, and the choroid is a continuation of the ciliary body in the form of a layer of tissue that lies between the sclera and the retina. It is made up largely of blood vessels that nourish the outer layers of the retina.

The crystalline lens is a transparent structure that is centered immediately behind the iris and suspended in the posterior cavity. It is held in place by transparent fibers called zonules that radiate from the lens and attach to the ciliary body. Tiny muscles within the ciliary body can change the tension on the zonules. When these muscles, the ciliary muscles, are stretched tight, the lens is flattened, allowing for distance vision. When the muscles are relaxed, the lens is rounded for near vision. The change in shape of the crystalline lens to allow for near and far vision is called accommodation.

The vitreous is a clear, jelly-like substance that fills the posterior chamber of the eye. This connective tissue helps maintain the global structure of the eye. It is optically transparent and may liquefy as part of the aging process, occasionally producing small clumps or strands of concentrated gel floating in the now-fluid vitreous. These particles are called floaters.

The retina itself is a transparent layer of tissue that forms the innermost lining of the globe. This layer consists mainly of nerve cells, and is actually an extension of the brain. The

retina is composed of an inner layer of nerves containing two types of photoreceptors (or light sensitive cells): the rods and the cones. Rods are responsible for both night and peripheral vision. The cones are used during the day and interpret sharp images and color perception. The central retinal artery enters and the central retinal vein exits at a

location called the optic disc or the optic nerve head. There is no vision at the optic disc. The macula, which is located close to the center of the retina, is a specialized area because most of the cone cells are concentrated there for the proper function of this area, which is crucial to finely-detailed central vision. The area of sharpest vision is the fovea centralis. The optic nerve

is stimulated by light to the rods and cones in the retinal photoreceptor layer. The resulting electric (nerve) impulses are relayed to the bipolar cells, which lie above the rods and cones. The impulses pass to ganglion cells at the top, or inner-most layer, of the retina. These ganglion cells possess long, fiber-like axons, which course over the retina and converge at the optic disc at the back of the eye. The axons from the ganglion cells form the optic nerve.

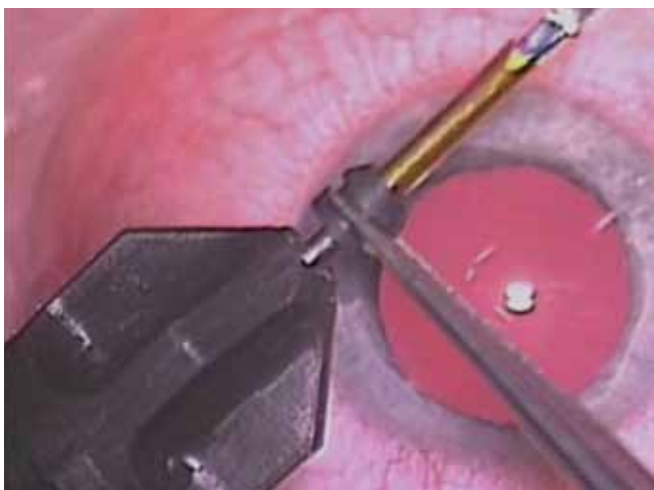Bruch's membrane is a thin, cell-free membrane made up of sheets of connective tissue. It separates the choroid from the retina while allowing nutrients to pass through. It naturally thickens with age and defects in the membrane can develop in diseases such as age-related macular degeneration (AMD) and severe myopia, or nearsightedness.

The retinal pigment epithelium (RPE) is located at the outermost layer of the retina, adjacent to Bruch's membrane. It serves as a barrier between the choroid and the retina and provides nourishment to the eye. RPE cells contain pigment granules, which absorb excess scattered light that might otherwise strike the photoreceptors.

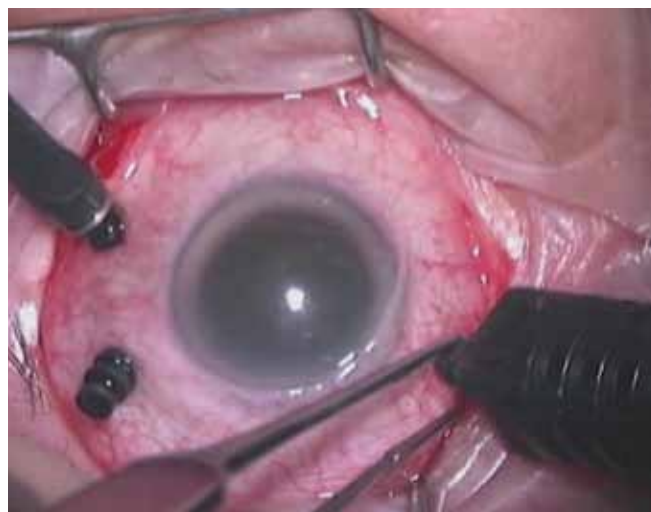## PROCEDURE OVERVIEW AND EQUIPMENT

A pars plana vitrectomy (PPV) involves the surgical removal of foreign matter or blood from the vitreous. In some instances, it can include the removal of the vitreous itself. This procedure removes scar tissue, membranes and traction, restoring the retina to its normal physiologic position. The surgeon may opt for a biopsy of the vitreous for diagnosis before treatment.

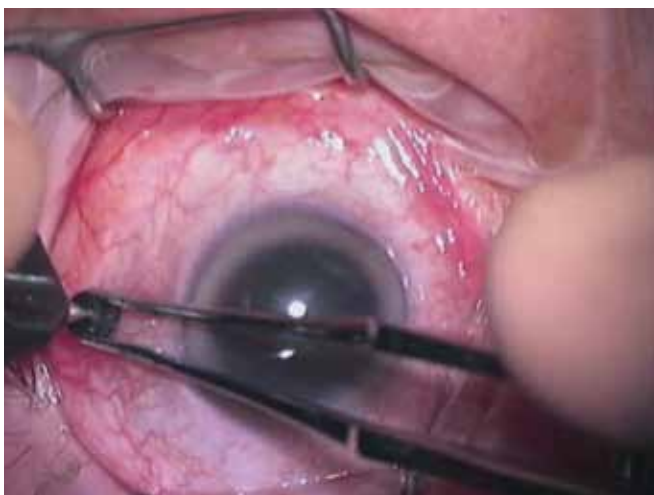
Some of the required equipment includes a Binocular Indirect Ophthalmomicroscope (BIOM) for panoramic



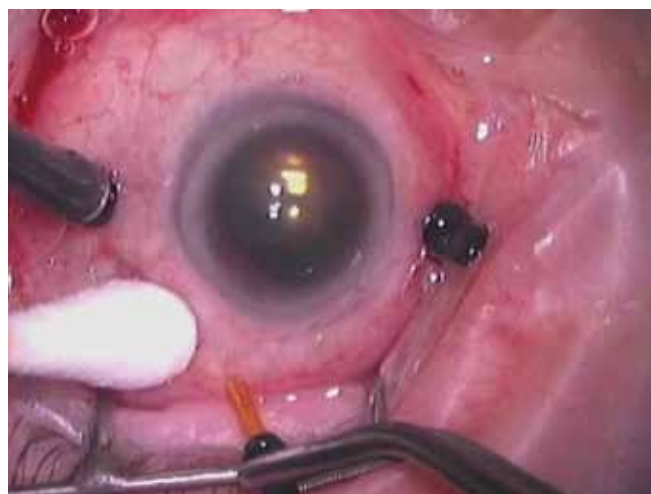*The trocar blade and outside cannula are held with a trocar cannula forceps.*



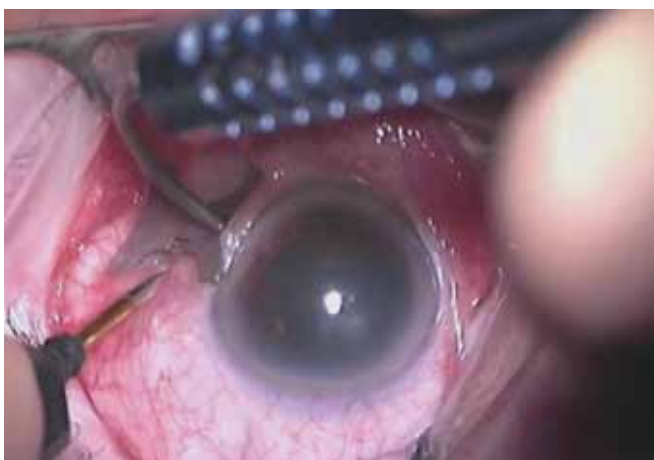*Three ports are used for the vitrectomy surgery. One is for the infusion used to maintain the globe. This port connects to a special adaptor and fine 20-gauge tubing that connects to a stopcock. The three-way stopcock connects the infusion port in the eye to the macro drip tubing to a bottle of BSS, and the third port is for an air line if one is needed.*



*The trocar and cannula are measured on the sclera 3-3.5 mm from the limbus cornea so that the conjunctiva falls back, covering the wound, when the cannula is removed.*



*Removal of the cannulas using Nugent forceps.*



*The trocar blade and cannula are inserted into the globe 3-3.5 mm from the limbus.*

At this time, while the smaller-gauge instruments (23- and 25-gauge) continue to evolve and show promise, certain cases may require larger gauge instrumentation.

viewing; a computer-programmed vitrectomy machine; an indirect ophthalmoscope; and endolaser and indirect laser.

The patient is placed in the supine position and the patient cart is positioned for optimum microscope usage. The patient receives retrobulbar anesthesia, which is composed of 4 ml bupivacaine (0.75 percent), 4 ml of plain lidocaine (two percent) and 30 U vitrase 0.2 ml in a 10 ml syringe with a 25 gauge 1.5-inch needle. Proparacaine drops are administered to the operative eye prior to injection or prep.

The patient is prepped with betadine paint (10 percent) mixed with saline in a 1:1 ratio. The operative eyelashes are cleaned using cotton swabs dipped in the betadine paint mixture. The operative eye and surrounding orbit are then painted in the same manner.

#### **THE PARS PLANA VITRECTOMY PROCEDURE (19- AND 20-GAUGE)**

In 1981, vitrectomy was done using a 19-gauge ocutome probe that required disassembly and reassembly to clean. By the late 1980s, surgeons were working with disposable 20-gauge probes. The Accurus machine – a computer-operated device—appeared in 1995. It also featured a 20-gauge probe and introduced a higher cut rate. The cut rate began at 600 cuts per minute (cpm), then was upgraded to 1,800 cpm and finally to 2,500 cpm.

To begin the procedure, the surgeon cuts down into the conjunctiva at three sites in order to expose the sclera three to four mm from the limbus, also known as the pars plana. Vessels are cauterized as needed. One of the cut sites maintains the integrity of the globe by use of infusion. The other two are the insertion points for instrumentation into the eye: a vitrector and a light source.

Next, a 20-gauge infusion cannula is sutured into one sclerotomy, usually in a lateral position, and the line is taped down to the drape in order to prevent any unnecessary or inadvertent movements when the lights are off in the room. Placement is checked before infusion is turned on to verify location.

The surgeon then completes the two remaining sclerotomies and inserts 19-gauge or 20-gauge plugs. The plugs are inserted to maintain pressure within the globe. The illumination probe, which provides a fiber-optic light source to provide light when the microscope light is turned off, and the vitrector, which is used for cutting the

vitreous, are inserted to begin the procedure.

Once the vitrectomy is complete, the surgeon closes the two sites where the surgical instruments were placed with either 8-0 polyglactin, 910 suture or 6-0 plain suture on a TG140-8 needle. Plugs are used to maintain pressure in the eye as one port after the other is closed. Finally, the infusion cannula is removed and that site is sutured shut. Upon removal of infusion, the ability to maintain the globe pressure rests on the suture sites.

The surgeon checks and adjusts the intraocular pressure and balanced salt solution (BSS) is injected with a 30-gauge needle if the eye is too soft.

The conjunctiva is closed, completing the tissue closure. Cycloplegic or mydriatic ointment (antibiotics) and steroid drops are injected to decrease the chance of infection or inflammation. A patch and shield is applied to protect the eye from possible injury.

#### **PARS PLANA VITRECTOMY PROCEDURE (23- OR 25-GAUGE)**

Using a caliper, the surgeon marks the insertion site three to four mm from the limbus and, using 23- or 25-gauge trocar cannulas, inserts the infusion cannula into the globe, stabilizing the eye with an applicator. The infusion cannula is checked before the infusion is turned on to verify proper position. The infusion line maintains pressure in the globe. If the surgeon is using a pressure plate with a caliper, it is done together.

The other two ports are entered and the plugs are inserted to maintain pressure in the globe when the globe is cannulated. The plugs are removed one at a time and the illumination probe is inserted first, followed by the vitrector. The illumination needs to be inserted first and turned on in order to begin surgery. The vitrector is inserted second. After the procedure is completed, the cannulas are removed one at a time, with the infusion line being removed last. The sites are checked for leakage and sutured if necessary.

## POSTOPERATIVE RECOVERY

The patient will wear an eye patch for the first night following the procedure. The surgeon likely will remove the eye patch the day after surgery, but it is recommended that the patient wear sunglasses or prescription glasses during the day and a protective eye shield over the operative eye while sleeping for the first week postoperatively. Some pain or discomfort is normal after the procedure. Narcotic pain medication may be prescribed for pain in the first few days following surgery, but NSAIDs should be sufficient to control discomfort shortly thereafter. A moderate amount of drainage can be expected during the first week postoperatively and will gradually decrease.

Patients will be discharged with several eye drops or ointments. One medication is a mydriatic, or dilating drop, used to keep the eye dilated. Another drop is an antibiotic, which may be combined with a steroid, to prevent infection and promote healing. Occasionally, a third drop is used to control the pressure in the eye. The eye drops and ointments are typically used for four to eight weeks.

## CONCLUSION

Historically, 20-gauge vitrectomy has been both well tolerated and effective with high rates of successful outcomes and low rates of complications, such as endophthalmitis, an inflammatory condition of the intraocular cavities (aqueous or vitreous) usually caused by infection. Noninfectious, or sterile endophthalmitis may result from various causes such as retained native lens material after an operation or from toxic agents.

There are two types of endophthalmitis: endogenous and exogenous. Endogenous endophthalmitis results from the hematogenous spread of organisms from a distant source of infection. Exogenous endophthalmitis results from direct inoculation as a complication of ocular surgery, foreign bodies and blunt or penetrating ocular trauma.

For more than 30 years, 20-gauge vitrectomy has been the standard of care, and as such, most vitreo-retina surgery instruments have been designed for 20-gauge instrumentation.

At this time, while the smaller-gauge instruments (23- and 25-gauge) continue to evolve and show promise, certain cases may require larger gauge instrumentation. Membranes, sometimes referred to as scar tissue in diabetic eyes, can be found connected to the retina and can be very proliferative. Membranes also can cause macular holes by tugging on the macula creating a macular hole. When membranes

are removed for retinal detachments, it allows the retina to reattach. When the membranes are removed that are responsible for macular holes, the patient's fine-focus area of the eye is allowed to heal, improving vision.

Bimanual technique requires a light source to be inserted into the globe that the surgeon does not hold. This allows the surgeon to use scissors and forceps together on very prolific membrane eyes, shortening operating time.

When using proliferative vitreoretinopathy, membrane peeling, or when bimanual techniques are used, it may be advantageous to consider 20-gauge vitrectomy procedure. More instrument options are available for 20-gauge vitrectomy versus 23- or 25-gauge vitrectomy. Traction retinal detachments sometimes require huge retinectomies that utilize a membrane peeling cutter (MPC), which can be useful for segmenting or delaminating. The MPC is only available in 20-gauge.

Crystalline lens or retained lens material after cataract surgery is removed typically with 20-gauge fragmenting instrumentation. Fragmentation is only available in 20-gauge. Thus, when it is necessary to remove the crystalline lens, because of cataract or dislocation, fragmentation with 20-gauge instrumentation is the most efficient means to do so. If only small cortical pieces are present, 25- or 23-gauge vitrectomy without fragmentation may be sufficient. However, when large amounts of nuclear material or dense nuclear material are present, 20-gauge vitrectomy with fragmentation is usually necessary.

Removal of silicone oil (whether 1,000 or 5,000 centistoke oil) becomes a challenge through a 23- or 25-gauge for aspiration and replacement of oil with BSS. Fluids involved in exchange of different liquid densities require higher pressures to maintain the globe. Complications and risk in globes becoming soft are choroidal hemorrhages. Ischemic changes can occur after surgery as well.

While efficiency and patient comfort are great reasons for using smaller gauge vitrectomy instrumentation, drawbacks do exist besides to use 20-gauge vitrectomy surgery. The steps involved in opening the conjunctiva and closing it add to patient discomfort and increase corneal astigmatism. A 20-gauge, trocar-based sutureless system is currently on the market. The purpose of par plana vitrectomy with a 20-gauge transconjunctival cannulated sutureless (TCS) is combining the advantages of smaller-gauge trocar cannulas with economical advantage of not needing to purchase additional handheld instruments. However, sclerotomies are larger and self-sealing sclerotomies may not be as easily done.

Like the smaller gauge, the 20-gauge transconjunctival sutureless vitrectomy is associated with complications that include premature dislodging of cannula, retinal tear, hypotony, hemorrhagic choroidals, subconjunctival gas and less-than-full gas fill. A possibly higher sclerotomy suturing rate, relative to smaller-gauge approaches, is a disadvantage of this technique.

In the effort to improve comfort and to increase operative efficiency the smaller gauges were presented.

#### ABOUT THE AUTHOR



Donna Mrugala, CST, BS, has worked as a surgical technologist since 1975. She spent five years at St Joseph's Hospital in Milwaukee before spending six months abroad studying at Jagellonian University in Krakow, Poland. She returned

to Milwaukee County, where she began working in ophthalmology and has remained in this discipline, where her sub-specialty is vitreo-retinal surgery. Ms Mrugala has a BS in biology and conservation and has participated in health care volunteer projects at home and abroad.


#### REFERENCES

1. Newmark E, ed. *Ophthalmic Medical Assisting: An Independent Study Course, 4th ed.* American Academy of Ophthalmology. 2006.
2. Dansby-Kelly A, ed. *Ophthalmic Procedures in the Operating Room and Ambulatory Surgery Center 3rd ed.* American Society of Ophthalmic Registered Nurses. 2006.

## Write for the Journal, earn CEs!

Did you know that you can earn CE credits by writing for the Journal? Authors receive four CE credits for every 2,000 words. If you write a 4,000-word CE article, you will receive eight CE credits upon publication! This is a wonderful opportunity for you to enhance your knowledge, share your experience, earn CE credits and help promote education for your fellow CSTs!

If you are interested in writing for the Journal, please contact Jodi B Farmer at [jodi.farmer@ast.org](mailto:jodi.farmer@ast.org). Even if you have never written before, AST's editorial staff will help you through every step of the process. It's a rewarding experience in more ways than one!



#### Earn CE Credits at Home

You will be awarded continuing education (CE) credits toward your recertification after reading the designated article and completing the test with a score of 70% or better. If you do not pass the test, it will be returned along with your payment.

Send the original answer sheet from the journal and make a copy for your records. If possible use a credit card (debit or credit) for payment. It is a faster option for processing of credits and offers more flexibility for correct payment. When submitting multiple tests, you do not need to submit a separate check for each journal test. You may submit multiple journal tests with one check or money order.

**Members this test is also available online** at [www.ast.org](http://www.ast.org). No stamps or checks and post to your record automatically!

**Members: \$6 per credit**  
(per credit not per test)

**Nonmembers: \$10 per credit**

(per credit not per test plus the \$400 nonmember fee per submission)

After your credits are processed, AST will send you a letter acknowledging the number of credits that were accepted. Members can also check your CE credit status online with your login information at [www.ast.org](http://www.ast.org).

#### 3 WAYS TO SUBMIT YOUR CE CREDITS

**Mail to:** AST, Member Services, 6 West Dry Creek Circle Ste 200  
Littleton, CO 80120-8031

**Fax CE credits to:** 303-694-9169

**E-mail scanned CE credits in PDF format to:** [memserv@ast.org](mailto:memserv@ast.org)

For questions please contact Member Services - [memserv@ast.org](mailto:memserv@ast.org) or 800-637-7433, option 3. Business hours: Mon-Fri, 8:00a.m. - 4:30 p.m., mountain time