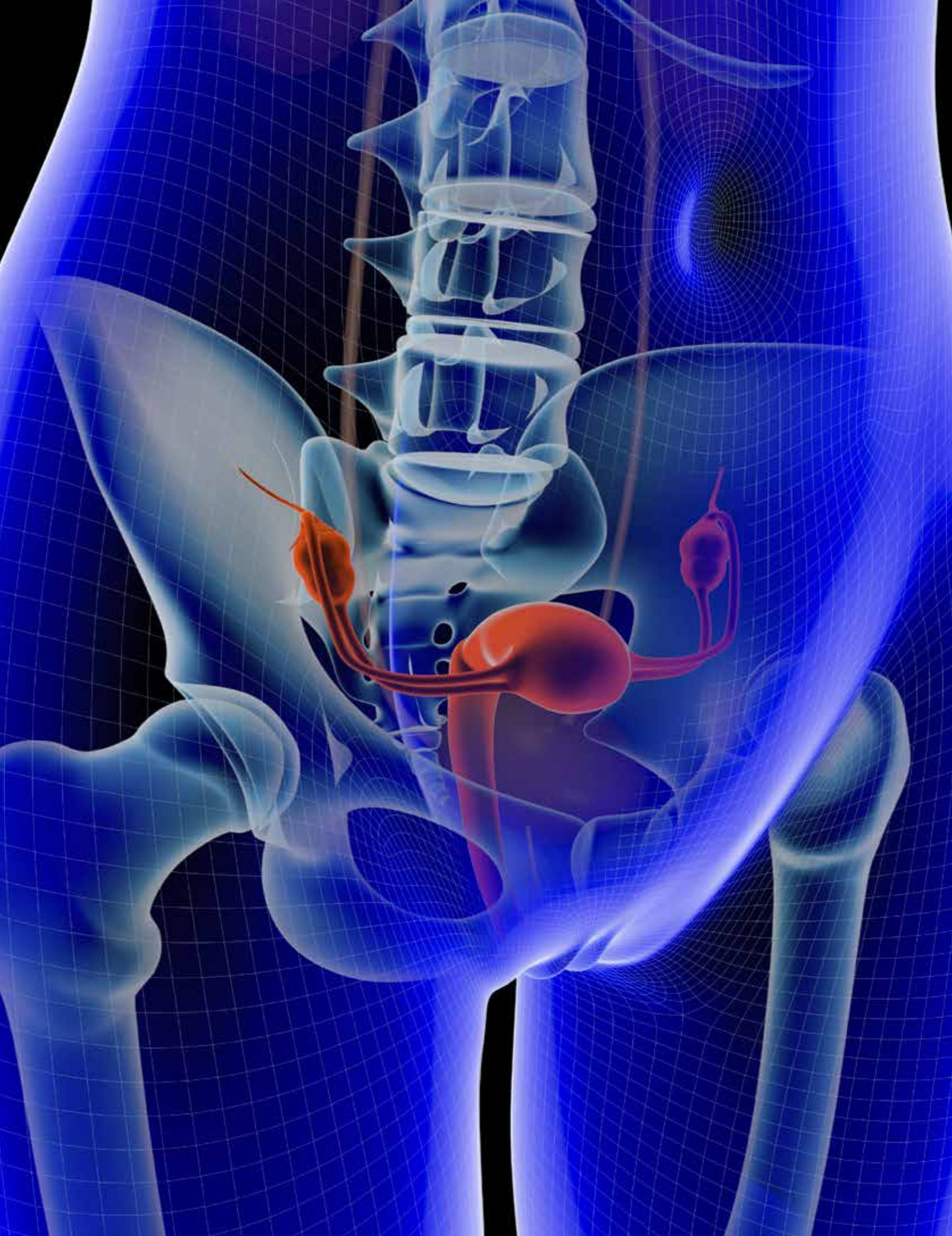

# Total Abdominal Hysterectomy

JESSICA DE LA CRUZ, CST

One of the indications for a total abdominal hysterectomy with bilateral salpingo-oophorectomy is that the patient is suffering from menometrorrhagia, excessive or irregular menstrual flow that occurs between or during a female's menstruation cycle. Menometrorrhagia is an indication of an urogenital malignancy (such as cervical cancer), uterine fibroids, hormonal discrepancies or endometriosis. If left untreated, anemia can result from menometrorrhagia. Depending on the severity of the condition, the only treatment options recommended for menometrorrhagia are hormonal supplemental therapy, such as birth control pills or a hysterectomy.<sup>2,4,8</sup>

**U**terine fibroid is another condition where a hysterectomy would be recommended. Also known as a myoma, this benign growth usually develops in the myometrium layer of the uterus. The symptoms commonly associated with uterine fibroids are painful intercourse, heavy or long menstruation cycles, noticeable lower back and pelvic pain or frequent urination. Uterine fibroids are so common that it is estimated approximately 20 percent of women in their childbearing years may have a myoma and at least half of all women by the age of 50.<sup>2,4</sup>

Other treatment options may vary depending on the number, size and location of the uterine fibroid and whether the individual is or plans on becoming pregnant. If the uterine fibroid does not interfere or disrupt a woman's normal everyday activity, they are usually left untreated. Treatments for myomas include hormonal therapy, myomectomy, embolization and hysterectomy. Iron supplements, birth control, short-term injections and nonsteroidal anti-inflammatory

## LEARNING OBJECTIVES

- ▲ Learn about the anatomy of the uterus
- ▲ Identify the ways patients are diagnosed as a candidate for this type of procedure
- ▲ Review patient prep and positioning for this surgery
- ▲ Evaluate the surgical steps needed for the two areas the procedure affects
- ▲ List the instruments and equipment needed for a Total Abdominal Hysterectomy with Bilateral Salpingo-Oophorectomy



drugs (NSAID) are the noninvasive options used to treat uterine fibroids. If the patient desires the ability to bear children, a myomectomy or embolization will be considered. A myomectomy is the surgical removal of uterine fibroids. However, a common complication of this procedure is additional development of uterine fibroids. Another treatment alternative is the elimination of blood supply to the uterine fibroid, known as embolization. During this procedure, a catheter is inserted into the patient's femoral artery and thread to the uterine artery. Polyvinyl alcohol particles are then injected into the uterine artery, causing a blockage and thereby killing off the blood supply to the uterine fibroid. The outcome of an embolization of the uterine artery will be the shrinking and death of the uterine fibroid.<sup>6</sup>

Other possible indications for a hysterectomy with bilateral salpingo-oophorectomy include endometriosis, ovarian cysts, pelvic inflammatory disease (PID) and cancer of the ovaries, uterus and/or cervix. Endometriosis arises when endometrial cells from the uterus migrate to the outside of the uterus and begin to grow. The isthmus of the fallopian tubes is responsible in preventing endometriosis due to its function to act similar to a sphincter. As a result, they begin to bleed during a woman's menstrual cycle due to the hormones that control menstruation. Consequentially, this will cause pain, scarring and irritation of the surrounding tissue.<sup>6,9</sup>

Ovarian cysts are semisolid or fluid-filled sacs that grow externally or internally in an ovary. Symptoms of ovarian cysts usually are nonexistent; however, some women tend to suffer from sharp or dull pain in their abdomen. The three types of ovarian cysts include follicular, corpus luteum and dermoid. Ovarian follicular cysts often occur during the menstrual years of a female and are absent in women who are not ovulating or are postmenopausal. Ovarian corpus luteum cysts are sometimes found at the beginning months of pregnancy or during woman's menstruation years. Dermoid cysts are made up of different material, including teeth, skin, fingernails and hair. They are the result of the outer layer cells of an embryo and are found on occasion in the ovary.<sup>6,9</sup>

One of the most serious and widespread outcomes of infection that is associated with sexually transmitted diseases is pelvic inflammatory disease. This condition originates at the vagina and cervix and travels up to the uterus, ovaries and fallopian tubes of the upper female reproductive tract. The common symptoms associated with pelvic

## ANATOMY OF THE UTERUS

The uterus is a thick pear-shaped organ that is located between the rectum and the bladder. The average uterus is approximately one inch deep, three inches long and two inches wide. However, the uterus tends to grow when a woman has borne children and smaller when a woman has reached their postmenopausal stage. The uterus consists of the fundus, corpus and cervix. The fundus is the superior rounded portion that is located slightly above the tubal entrances of the uterus. Below the fundus is the corpus, which is also known as the body of the uterus. The corpus narrows to the neck region of the uterus that is known as the cervix, which leads out into the vagina.<sup>8</sup>

The uterus is composed of three different layers. The outermost layer of the uterus is known as the peritoneum or the serous. The muscular layer of the uterus is the myometrium, which contains the blood vessels, nerves, lymphs and involuntary muscles of the uterus. The endometrium, also called mucosal, is the innermost layer of the uterus. This layer lines the uterine cavity and changes every month during a woman's menstruation cycle. This change is due to the uterus natural ability to prepare to nourish a fertilized egg. If egg is not fertilized in that time, the lining breaks down and results in a woman's menstruation.<sup>8</sup>

The uterus is supported and suspended inside the pelvic cavity by the broad, cardinal, round and uterosacral ligaments and the levator ani muscle. The broad ligament covers the sides and floor of the pelvis. This ligament contains the uterine tubes and is the result of folds of the peritoneum. The round ligament consists of bands of fibromuscular tissue that enters through the inguinal ring and connects to the labia majora connective tissue and the skin. The cardinal ligament is located anterior of the uterus and consists of smooth muscle fibers with connective tissue. The posterior continuation of the peritoneum, which is located inferior to the uterus, is the uterosacral ligament.<sup>8</sup>

The uterus receives its blood supply via the uterine artery, which is a branch off the paired internal iliac arteries. Venous drainage of the uterus occurs from the utero-ovarian pedicle, which then travels to the external iliac area. Innervations for the uterus is supplied via the hypogastric and ovarian plexus, the first lumbar and twelfth thoracic spinal segment, and second through fourth sacral spinal root.<sup>4</sup> Described as a fibromuscular canal, the vagina is located between the cervix and external genitalia and measures approximately six to eight centimeters in length. It contains nonkeratinized epithelium

that is complemented by the cervical mucosa. The vagina serves the female human body in many ways. It serves to lubricate, provide sensation, and accept the male penis during sexual intercourse. The vagina also carries the blood from a woman's menstruation cycle by acting as a channel from the uterus to the external genitalia. During childbirth, the vagina is the terminal end of the birthing canal.<sup>4,8</sup>

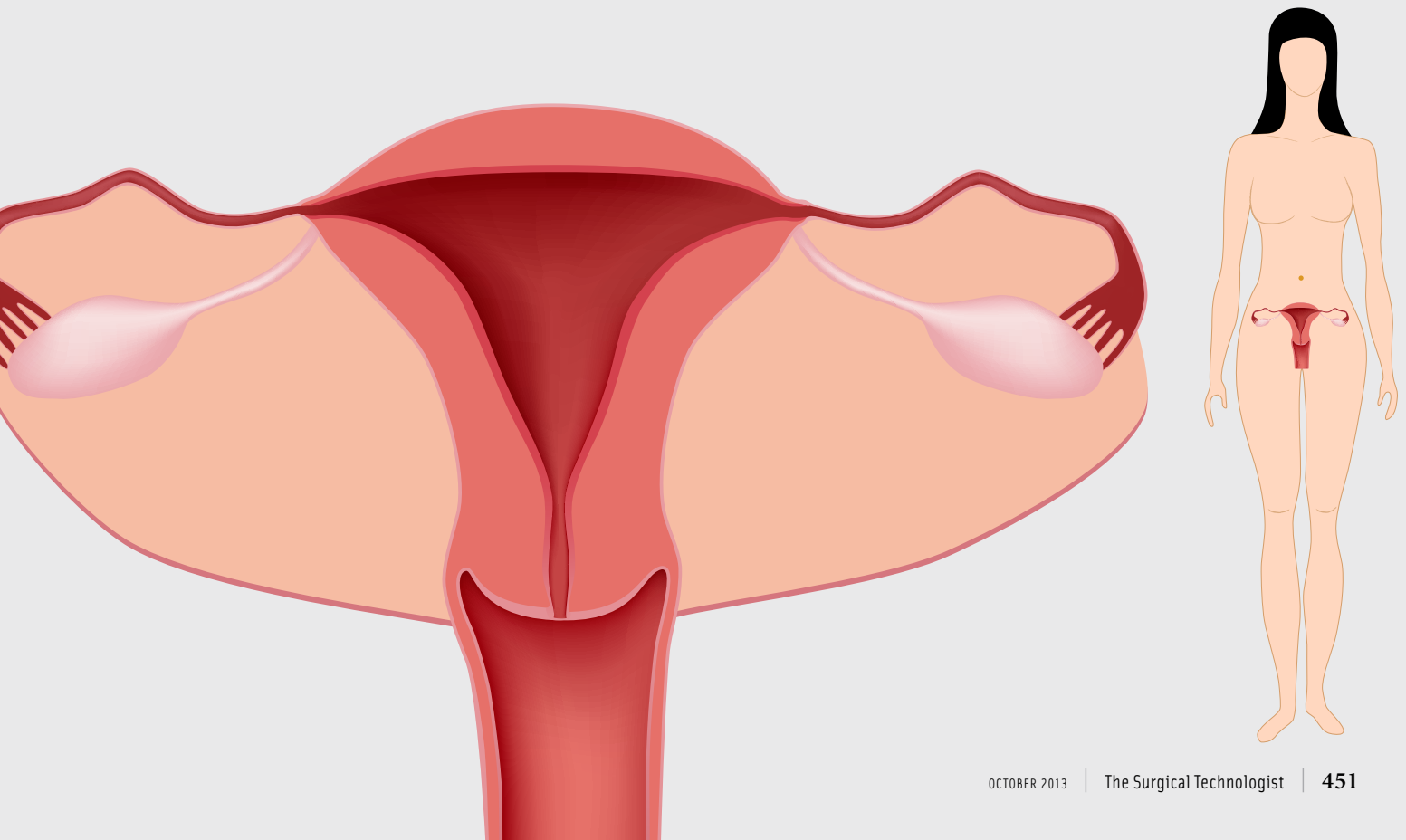
The vagina receives its blood supply via the branches of the internal iliac arteries. These branches include the middle rectal, uterine, vaginal and internal pudendal arteries. Venous drainage occurs through the vaginal veins, which connects to the internal iliac venous system. Innervation for the vaginal is supplied by the pudendal nerves, pelvic splanchnic nerves and the vaginal plexus.<sup>4</sup>

The uterine appendages, also known as the uterine adnexa, of the uterus are the fallopian tubes and the ovaries. The paired fallopian tubes, also known as the oviducts, are approximately 10 to 13 centimeters long and consist of an inner and outer layer. The external layer is composed of longitudinal fibers of smooth muscle and is covered in peritoneum, while the internal layer contains circular fibers of smooth muscle and a ciliated epithelium lining. The oviducts include of four sections which include the fimbria, ampulla, isthmus, and intramural. Beginning at the terminal end of the oviducts, is the fimbria which contain finger-like projections that function to sweep the ovarian egg from the ovary to the

uterus. The ampulla, consisting of a thin twisted wall, is the largest section of the fallopian tubes. The muscle portion of the fallopian tubes that acts similar to a sphincter is the isthmus. It measures approximately two to three centimeters in length. The final portion of the fallopian tubes is the intramural, which is located within the wall of the uterus. From here, the intramural portion connects with the uterus at the point of the cornu.<sup>4,8</sup>

Located in a depression known as the ovarian fossa, the paired ovaries are found on each side of the uterus and are supported by the ovarian ligament. Each ovary consists of an epithelium coating and is composed of an inner portion called the medulla and an outer portion known as the cortex. The medulla of the ovary is comprised of blood vessels, nerves, and lymph vessels and is made up of connective tissue. The ovarian cortex consists of graafian follicles during the stages of developmental maturity. The function of the ovaries is the production of hormones, progesterone and estrogen, and the manufacturing and discharge of oocytes.<sup>4,8</sup>

The fallopian tubes and ovaries of the uterus receive their blood supply via ovarian and uterine blood vessels. Innervations for the adnexa of the uterus is supplied by parasympathetic fibers, from the second through fourth sacral nerve and the ovarian plexus, and sympathetic fibers, plexuses of the tenth thoracic through the second lumbar. Lymph drainage occurs by means of the pelvic and lumboaortic lymph nodes.<sup>4,8</sup>



inflammatory disease are lower abdominal pain, irregular bleeding, fever, vaginal discharge and odor, painful urination and painful intercourse. If pelvic inflammatory disease is left untreated, it can cause serious damage to the female reproductive system, such as infertility, abscess formation, frequent ectopic pregnancy and persistent pelvic pain.<sup>6,9</sup>

Nearly 10 percent of all hysterectomies performed are due to cancer in the cervix, ovaries and uterus. Cancer occurs due to the rapid and uncontrollable growth of cells in body. As the cells grow, they have the ability to travel from their place of origin and affect other tissues and organs of the human body. In order to prevent the metastasis of cancer in the female reproductive tract, all the affected organs are removed.<sup>6</sup>

### DIAGNOSTIC TESTING

In order to properly diagnosis the patient and recommend the correct course of treatment, diagnostic tests are performed. One of the most common and universal test performed is a Papanicolaou smear. A Pap smear is a swab sample of the epithelial cells taken from the cervix. This sample is placed on a microscope slide and examined for abnormal growth.<sup>4</sup>

After the patient is cleared through a Pap smear, the physician may order an endometrial biopsy. An endometrial biopsy is the removal of an endometrium with the use of a small plastic tube. The cervix is prepped with an antiseptic and grasped with a tenaculum. The cervix is dilated and the hollow tube is inserted to removal a small sample of uterine lining. The sample is sent to pathology to be exam-

In order to properly diagnosis the patient and recommend the correct course of treatment, diagnostic tests are performed. One of the most common and universal test performed is a Papanicolaou smear.

ined under a microscope for abnormalities. An endometrial biopsy is performed on women older than 35 and to find the cause of heavy, irregular menstrual bleeding.

Patients might undergo X-rays prior to surgery. In this case, the patient had a chest X-ray performed by her anesthesia provider in order to examine the patient for any

abnormalities in the patient's lungs that may hinder the gas exchange during surgery.<sup>2,4,8</sup> Electrocardiograms may also be performed to access the patient's heart prior to surgery. A complete blood count is a standard diagnostic test for surgery. A pelvic examination may also be performed and is usual done so in conjunction with a Pap smear. In the case of fibroids or suspected tumors, an ultrasonography may be ordered. A urinalysis, the microscopic, physical, and chemical examination of a urine specimen, is routine diagnostic test that is typically performed prior to surgery after the patient has checked into the hospital.<sup>4,5</sup>

For this procedure, the patient is a 46-year-old female who has a history lower left quadrant pain, menometrorrhagia and urinary stress incontinence. She has an cesarean section scar due to two prior pregnancies. In addition, she has a pigmented peri-umbilical lesion and excess abdominal wall skin. The patient has recently undergone a hysteroscopy and was diagnosed with a uterine fibroid found in the fundal area of the uterus, approximately seven to eight centimeters in mass.<sup>2</sup> Her past surgeries included a bilateral tubal ligation, two cesarean sections and a colonoscopy. Her endometrial biopsy was determined to be negative and her pap smear was normal for malignancy. Based on the advice and information provided by her physician, the patient has requested to have a hysterectomy with bilateral salpingo-oophorectomy. Due to the patient's request to have the excess abdominal wall skin removed and her recent diagnoses of fibroids, it was recommended by her physician to select the abdominal hysterectomy approach.<sup>2</sup>

### SURGICAL INTERVENTION

The surgical technologist must be knowledgeable of the surgeon's needs and wants. In order to be ready for the procedure, the surgical technologist should be familiar with the surgeon's preference card.

### POSITIONING AND POSITIONING AIDS

For this procedure, the patient is placed in the supine position and offered warming blankets.

The armboards are connected to the OR table and the patient's arms are placed on the armboards, with the palms placed in anatomical position. After the patient is placed under general anesthesia, the safety strap is positioned and secured approximately two inches proximal to the knees, while allowing at least two finger widths of space. The arm-

<b>SUPPLIES</b>
Operating table
Two armboards
Safety straps: for above the knee and both arms
Padding for the bony prominences
Foam headrest
Elbow pads
Abdominal hysterectomy pack
Antiembolitic hose
Blades: #10, #20
#20 gauge needle
Basin set
Gloves: 8 and 7.5 Triflex (surgeon)
Needle magnet or counter
Sponges: Ray-tecs, Laparotomy sponges
Suction Tubing
Drain: 18 Fr Foley catheter w/tubing and drainage unit, Jackson Pratt 10mm flat with 100mL reservoir bulb (for excess skin removal)
Dressings: 4x4 gauze (10 pk), abdominal pads, abdominal binder 9 in (for excess skin removal), 4x4 in drain sponge (for Jackson Pratt drain), vaginal dressing
Basin to contain large specimen
Medications: Marcaine 0.25% 30mL, Bacitracin
Miscellaneous: 0.9% sodium chloride for irrigation 1000mL <sup>3</sup>
<b>EQUIPMENT</b>
Forced-air warming blanket (if ordered)
Suction apparatus
Electrosurgical Unit
<b>SUTURE</b>
Skin stapler 3m: skin closure
0 polyglactin 910: for uterus and vaginal cuff
0 polyglactin 910: closure of peritoneum and fascia
0 polyglactin 910 ties: ligaments and vessels
2-0 polyglactin 910: ligament stumps
2-0 Chromic SH: used for "bleeders"
2-0 Silk: Drain
4-0 absorbable suture: subcutaneous closure <sup>3</sup>
<b>INSTRUMENTS</b>
Abdominal hysterectomy tray:
– Schroeder tenaculum forceps
– Curved Heaney forceps (single toothed with horizontal serration)
– Curved Mayo uterine scissors
– Straight Heaney-Ballantine Hysterectomy forceps (double toothed with vertical serrations)
– Long angled #3 knife handle
– Crile/Kelly forceps
– Tonsil forceps
– Jorgenson scissors
– Foerster sponge forceps
– Self retaining retractor - Turner Warrick

boards are extended at no more than a 90 degree angle in order to prevent hyperextension of the shoulder joint. All bony prominences must be protected with padding in order to prevent tissue and nerve damage to the patient's body, especially to the ulnar nerve.<sup>4</sup>

#### **PREP SOLUTION AND AREA PREPPED**

After the patient is properly positioned, the surgeon is paged to the operating room to mark the incision site. This is done prior to the skin prep because the surgeon outlines the area of excess abdominal wall skin he would like to remove. After the incision site is marked, the pubis is shaved by the circulator and paper tape is used to remove any loose hair. The two areas that are prepped for a total abdominal hysterectomy with bilateral salpingo-oophorectomy are the vaginal and abdominal area. The circulator performs a vaginal prep with Betadine scrub/paint. The first step of a vaginal prep is that the patient is placed in a frog-legged position and disposable pads are placed under the buttocks. The prep begins at the pubic symphysis and moves downward over the female external genitalia. After each sponge comes into contact with the anus, it is discarded. The sponges on sponge forceps are inserted into the vagina in order to complete the vaginal prep. While the circulator is performing the vaginal prep, the surgical technologist prepares the urethral catheter by testing the balloon with a syringe filled with sterile water to check for any leaks or tears. Once the circulator completes the vaginal prep, an 18 French Foley catheter is provided to the circulator to be inserted into the patient.<sup>3,4</sup>

After the incision site is marked, the circulator dons sterile gloves and begins with the abdominal prep of the patient. Using Beta Gel solution, the umbilicus is first cleaned with Q-tips. In a circular motion, the prep begins at the umbilicus and extends from the nipple line to the level of the midthigh and laterally from bed line to bed line. This process is repeated with each sponge that is supplied in the prep pack. The used sponges are discarded and an electro-surgical dispersive pad is applied to bottom of the patient's right thigh.<sup>3,4</sup>

#### **DRAPING**

After the patient is prepped, the surgeon enters the operating room and is gowned and gloved by the surgical technologist. The surgical site is outlined with the use of four towels. The protective covers of the adhesive portion of the laparotomy drape are removed by the surgical technologist.

Standing on opposite sides of the operating table, the surgeon and surgical technologist position the fenestrated portion of the laparotomy drape in the middle of the surgical site. The drape is slowly opened bilaterally by the surgeon and surgical technologist. While the surgical technologist stabilizes the sheet with one hand, the surgeon and surgical technologist cuff their hand under the head portion of the drape and extend it up (making sure the armboards are completely covered) to the anesthesiologist so it can be secured. The surgeon and surgical technologist reposition their hands, cuff their gloved hand, and extend the foot portion of the laparotomy drape. The surgical technologist applies the sterile light handles to the operating room lights and positions them to the center of the surgical site. The suction tubing and electro-surgical cords are placed on the drape and the correct ends are passed off to the circulator to be connected.<sup>4</sup>

Due to the removal of excess abdominal skin and cosmetic reasons in this case, the surgeon and patient opted for a lower abdominal transverse incision called Pfannenstiel. The skin and subcutaneous layer are cut to the fascia. The fascia is incised transversely to the rectus muscles. The linea alba is cut vertically and both sides of the rectus muscle are stretched. The peritoneum is carefully incised vertically to avoid damage to the patient's bladder. Another incision option for this type of procedure is a midline incision. This vertical incision begins at the umbilicus and extends to the pubic symphysis and provides a better view of the abdominal cavity. The midline incision is preferred if the patient is suffering from a malignant disease.<sup>4</sup>

## PROCEDURE STEPS

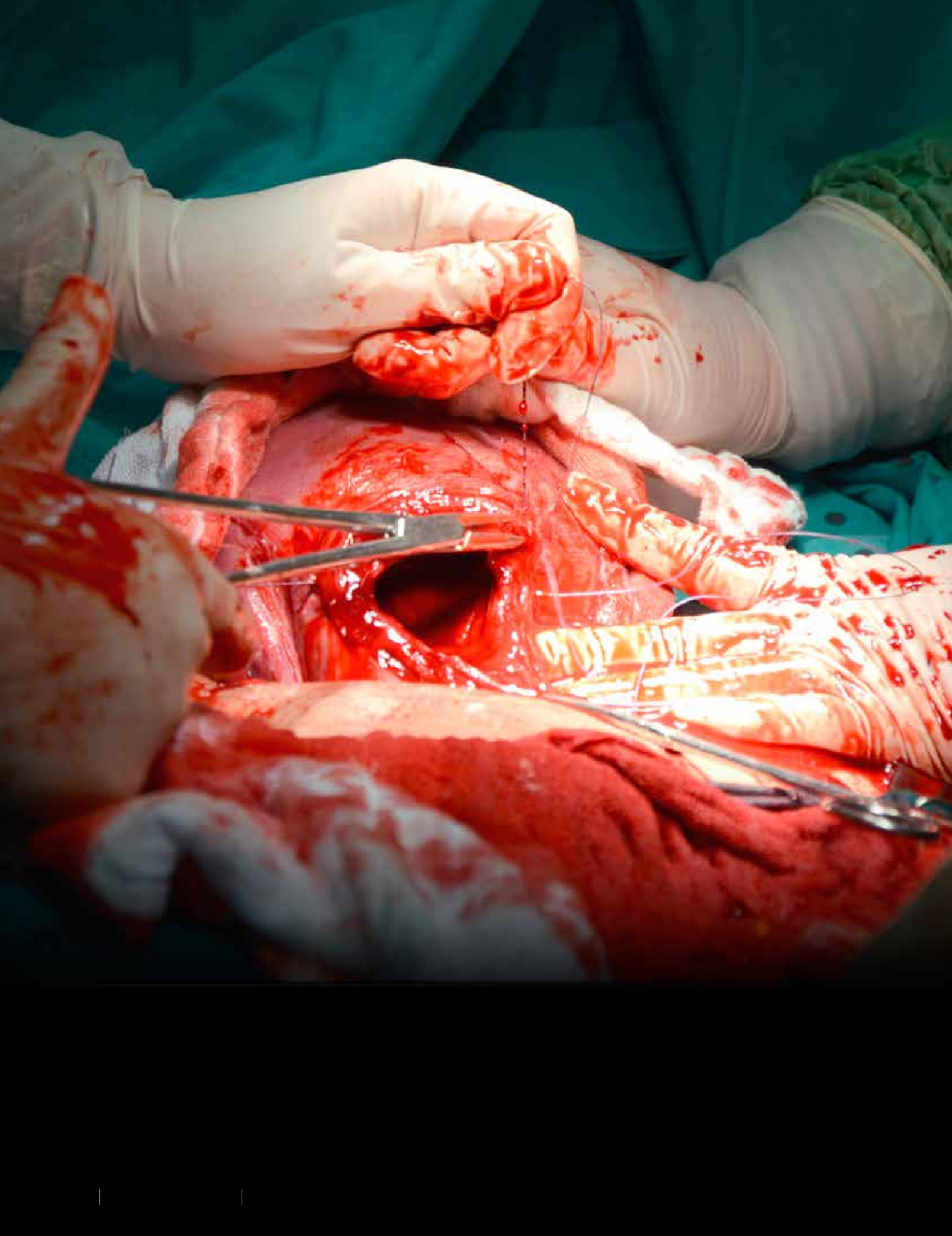
The timeout is performed before the start of the procedure. The surgeon then injects the incision site with 0.25% Marcaine. A lower transverse incision is made with a 20 blade on a number 4 knife handle. Using the prior incision markings, the surgeon carefully dissects away the excess abdominal skin with use of the electro-surgical pen and the scalpel. The electro-surgical pen is used to achieve hemostasis and deepen the incision to the fascia layer. The surgeon continues the dissection to remove the excess skin. The excess skin is then handed off to the surgical technologist and discarded. The surgical technologist passes the surgeon two Kocher clamps so the fascia can be grasped. The surgeon incises the fascia, exposing the rectus muscles. The linea alba is cut

vertically and both sides of the rectus muscle are stretched by the surgeon and his assistant. Two Richardson retractors are passed to the assistant to provide the surgeon visualization as the peritoneum is opened carefully in order to avoid damage to the bladder. The abdominal cavity is explored by the surgeon for any damage, bleeding or abnormalities. The surgeon asked the anesthesiologist to place the patient in Trendelenburg position in order to displace the abdominal organs superiorly and enhance visualization of the patient's reproductive organs. The Turner Warrick retractor, a self-retaining retractor, is placed into the abdomen. The surgical technologist provides the surgeon with five moist lap sponges that will be placed into the patient's abdomen, in order to avoid damage from the retractor blades to the tissue. The surgical technologist verifies the number of lap sponges and it is noted by the surgical technologist and

After the patient is properly positioned, the surgeon is paged to the operating room to mark the incision site. This is done prior to the skin prep because the surgeon outlines the area of excess abdominal wall skin he would like to remove.

circulator. A Schroeder tenaculum is passed to the surgeon and used to grasp the fundus of the uterus to gain control of the organ. The left side of round ligament and ovarian ligament are double clamped, cut, and ligated by the surgeon with the use of two Heaney clamps, Metzenbaum scissors and 0 polyglactin 910. The process is repeated by the assistant on the right side. The "leaves" of the broad ligament are incised anteriorly and posteriorly with two Heaney clamps, Metzenbaum scissors and 0 polyglactin 910 suture. The bladder is dissected off the lower end of the uterus and cervix with a sponge on a stick and the surgeon's finger. The infundibulopelvic ligament is double clamped, cut, and the distal stump is ligated with 0 polyglactin 910 ties and 2-0 polyglactin 910. Extra care is taken not to injure the ureters or iliac vessels. At this point the surgical technologist must anticipate the "clamp, clamp, cut, tie, cut" routine. Since the steps are methodical, the surgical technologist can expect the surgeon may use the curved Heaney clamps and curved Mayo scissors or the straight Ballantine clamp and a #10 blade on a #3LA knife handle. This routine will be repeated throughout the procedure. The surgeon then uses two long







Kocher forceps, a stick tie on a Tonsil clamp, and curved Mayo scissors to clamp, ligate, and incise the uterine vessels. The paracervical fascia is dissected with Metzenbaum scissors and long tissue forceps with teeth. The cardinal ligament and uterosacral ligaments clamped with two straight Ballentine clamps, cut with #10 blade on a #3LA knife handle, and tied with 2-0 polyglactin 910. The surgeon frees the uterus, fallopian tubes and ovaries with the use of a #10 blade on a #3LA knife handle and Jorgenson scissors. The uterus, fallopian tubes, and ovaries are placed on the back

The postoperative visit will include a checkup and the removal of the wound staples and 10mm Jackson Pratt drain. The patient is expected to return to normal activities approximately six to eight weeks following surgery.<sup>2</sup>

table until the circulator is able to retrieve it and permission is granted by the surgeon. The vaginal cuff is closed by the surgeon with interrupted 0 polyglactin 910. The abdomen is irrigated thoroughly with Bacitracin and inspected for damage and bleeding. The Turner Warrick retractor is removed by the surgeon and the five moist lap sponges are accounted for and verified by the surgeon, surgical technologist and circulator. The peritoneum and fascia are closed with 0 polyglactin 910, as the surgical technologist and circulator begin to perform their first count. Prior to closure of the subcutaneous layer, the patient is placed back into supine position and the 10mm Jackson Pratt drain is placed. The surgeon makes a nick incision into the skin and pulls the drain tubing through the skin with a tonsil forcep. The drain is sutured into place with 2-0 silk suture. The reservoir bulb is placed on tubing of drain by the surgical technologist. The subcutaneous layer is closed with 4-0 absorbable. The skin is closed by the surgeon with a 3m skin stapler as the assistant pulls the skin together with two Adson tissue forceps. The surgical technologist and circulator perform their final count at this point. The wound is cleaned and dressings are applied to the drain and wound. The surgeon then carefully removes the patient's pigmented peri-umbilical lesion with

a #10 blade on a #3 knife handle. The umbilical wound is closed with dissolvable sutures and adhesive tissue.<sup>1,4,6,9</sup>

After the wounds were cleaned with moist and dry lap sponges, a 4x4 in drain sponge was placed around the tubing of the Jackson Pratt drain. A 4x4 gauze and abdominal pads were placed over the incision site and a nine inch abdominal binder was used to hold the dressings in place and create a pressure dressing. Adhesive tissue is placed over the umbilical wound of the patient and allowed to dry prior to covering the patient with blankets. A vaginal dressing is also placed over the external genitalia area of the female patient. The staples and drain will be left in for a week and then the patient will return to the surgeon's office to have them removed.<sup>2</sup>

#### POSTOPERATIVE CARE

The patient was transported to the PACU following the total abdominal hysterectomy with bilateral salpingo-oophorectomy. The patient was awake and extubated as she was placed on the gurney. While recovering in the hospital, the patient was given antibiotics and pain medications. The patient was also prescribed an estrogen replacement. The patient was discharged from the hospital two days after surgery and scheduled for a postoperative visit a week following surgery. The postoperative visit will include a checkup and the removal of the wound staples and 10mm Jackson Pratt drain. The patient is expected to return to normal activities approximately six to eight weeks following surgery.<sup>2</sup>

#### COMPLICATIONS

There are a number of complications and risk that can occur intraoperatively and postoperatively. Intraoperatively, a patient can experience hemorrhage, damage to adjacent organs, such as the urinary bladder, ureters, intestines, or bowel, or an adverse reaction to anesthesia. Postoperatively, a patient may or will experience hemorrhage, infection, death, depression, pain, fatigue, a low-grade fever, constipation, urinary retention, blood clots, early menopause, sexual dysfunction or weight gain.<sup>2,4,8,9</sup>



#### ABOUT THE AUTHOR

Jessica De La Cruz, CST, graduated from San Joaquin Valley Fresno last year and passed the National Certification Exam in November 2012.