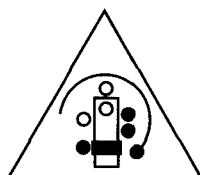


---

# Surgical Specialties Collected Editions Series

## SURGERY OF THE KNEE

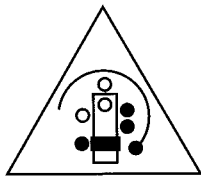


ASSOCIATION  
OF SURGICAL  
TECHNOLOGISTS

*AEGER PRIMO -  
THE PATIENT FIRST*

---





ASSOCIATION  
OF SURGICAL  
TECHNOLOGISTS

*AEGER PRIMO -  
THE PATIENT FIRST*

**Association of Surgical Technologists**  
7108-C S. Alton Way  
Englewood, CO 80112-2106  
303-694-9130

ISBN 0-926805-10-X

Copyright © 1995 by the Association of Surgical Technologists, Inc. All rights reserved. Printed in the United States of America. No part of this publication may be reproduced, stored in a retrieval system, or transmitted, in any form of by any means, electronic, mechanical, photocopying, recording, or otherwise, without the prior written permission of the publisher.

---

## INTRODUCTION

### Purpose

The purpose of this module is to provide the learner with information concerning specific surgical procedures performed on the knee. The articles that follow originally appeared in *The Surgical Technologist* and have been reprinted in this series. Upon completing this module, the learner will receive 3 continuing education (CE) credits in category 3G.


### Using the Module

1. Read the information provided, referring to the appropriate figures.
2. Complete the enclosed exam without referring back to the text. The questions are in a multiple-choice format and are taken directly from the corresponding article. Choose your answer based on the information presented in the article itself. Do not choose a response based on your personal experience, but instead select the best answer from the alternatives given.
3. Mail the completed exam answer sheet to AST, SSCE Series, 7108-C S. Alton Way, Englewood, CO 80112-2106. Please keep a copy of your answers before mailing the answer sheet.
4. Your exam will be graded, and you will be awarded CE credit upon achieving a minimum passing score of 70%. If you are an AST member, your credits will be recorded automatically and you do not need to submit the credits with your yearly CE reporting form.
5. You will be sent the correct answers to the exam. Compare your answers with the correct answers to evaluate your level of knowledge and determine what areas you need to review.

---

# Anterior Cruciate Ligament: History, Anatomy, and Reconstruction

ARTICLE BY BERNICE R. ROSS, CST; PATRICE M. MOORE, RN, BSN;  
AND BERNARD R. BACH, JR, MD



The purpose of this article is to provide surgical technologists with a better understanding of anterior cruciate ligament (ACL) reconstruction. It will cover a brief history of the ACL and its anatomy, diagnosis, and treatment.

Acquiring a better understanding of any surgical procedure can only enhance performance level and broaden the professional knowledge base.

## Historical Background

One of the characteristics of modern surgical practice is the delusion that we are the first to present new concepts and treatments to our profession, only to discover upon closer examination that we have "reinvented the wheel." We sometimes forget that all our accomplishments are only a few stones added to the massive wall of medical knowledge already built by our medical ancestors.

Snook accurately accounts the history of the anatomical and physiological study of the ACL in *The Crucial Ligaments*. He records that Claudius Galen of Pergamum and Rome must be given credit for first describing the anatomy and nature of the ACL. Before his writing, ligaments were thought to be part nerve and to have some sort of contractile power. Galen wrote that ligaments were the supporting structures of diarthrodial joints, serving as stabilizers of these joints and limiting abnormal motion.

Interest in the structure lapsed for the next 1,600 years as medical

attention was drawn to infectious disease and major trauma. The injured ligament was mentioned only in connection with dislocations and severe sprains. A knee with an injured ligament could always be braced.

In 1850, Stark treated patients with casts. In recovery, he found they had slight residual disability.

By 1917, Grone used different procedures such as replacement of the bony fragments by detaching a strip of fascia lata from its insertions and routing it through a tibial tunnel. Two years later, this procedure was modified by detaching a graft from its origin rather than from the insertion. This operation is the basis of the intraarticular reconstruction we use today.

In 1918, Alwyn Smith presented an overall review of the anatomy, biomechanics, mechanism of injury, diagnosis, and treatment of injuries to the ACL. He recommended reconstruction of the neglected tears by bringing the end of the graft up to the medial femoral condyle to reinforce the medial collateral ligament. He advanced the sartorius insertion to provide extraarticular reinforcement and was the first to attempt prosthetic reconstruction using a silk substitute. Many theses have been published on injuries to the ligaments of the knee joints.

By 1941, study of the ACL was still limited to case reports or descriptions of new procedures. A thorough study of sections of different ligaments and an analysis of the abnormal movement that resulted in the interactions between the several ligaments and menisci were

discussed in a paper published by Brantigan and Voshell entitled "The Mechanics of the Ligaments and Menisci of the Knee Joint." This paper is usually quoted in any discussions of the biomechanics of the knee joint.

At the end of World War II, there was a rise in the popularity of athletics and the development of antibiotics. Infectious diseases ceased to be the major preoccupation of the medical profession. At the same time, surgery became safer because of antibiotics and the improvements in anesthesia techniques.

Shortly after this period, the concept began of dynamic reconstruction of the ACL by transplanting semitendinous tendon through the back of the knee forward into the tibia.

More progress was made in the diagnosis and treatment of injuries of the ACL. Simultaneous advances were made in other fields of medicine that had a direct effect upon the study of the ligament. The first of these was the improvement of radiologic diagnosis, especially arthrography.

In 1905, 10 years after Roentgen announced his discovery, Wendorff and Robinson performed the first arthrogram, a gas arthrogram of the knee. Lindblom in the late 1930s became the major proponent of arthrograms, but the popularity of the technique did not surge until the development of water-soluble media and the many technical developments in radiography in the late 1950s.

Advances in the treatment of ACL injuries occurred when a few orthopedic surgeons started work-

ing as physicians for American football teams. Coaches had been using films for scouting and teaching purposes since the early 1930s, and in this high-risk sport, the orthopedic surgeon could also use them to analyze the mechanics of injury to the intact knee. With the development of fiberoptic transmission of light, the use of arthroscopic surgical techniques increased rapidly through the work of several pioneers: Ward Casscells, Richard O'Connor, Robert Jackson, Lanny Johnson, Robert Metcalf, and many others.

Early diagnosis is important in the treatment of ACL injuries. DeHaven recommended the early use of the arthroscope in acutely injured knees in the presence of hemarthrosis. This procedure has led to early diagnosis and repair of injuries, sparing the patient the more difficult reconstruction with its prolonged recovery. Today, arthroscopy is performed on an outpatient basis.

#### **ACL Anatomy**

The cruciate ligaments are bands of oriented, dense connective tissue that connect the femur and tibia. They are surrounded by a mesentery-like fold of synovial membrane that originates from the posterior intercondylar area of the knee and completely envelops the ligaments. The cruciate ligaments are intraarticular and also extrasynovial.

The ACL is an intraarticular structure inserted between the anterior horns of the medial and lateral menisci, originating on the lateral femoral condyle posteriorly and inserting on the anterior tibia. It measures approximately 4cm by 1.1 cm. It is responsible for guiding the tibia during flexion and extension and assists in the proper rollback of the femoral condyle. If the ACL is not properly functioning, the tibia is able to sublux anteriorly. This translation during knee motion may cause meniscal damage and increased articular cartilage destruction.

#### **Femoral and Tibial Attachment**

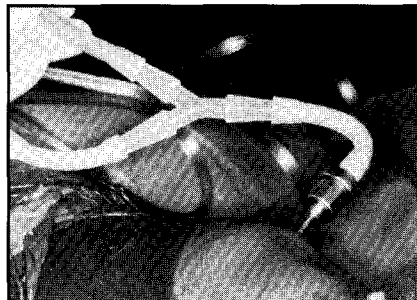
The ACL is attached to a fossa on the posterior aspect of the medial surface of the lateral femoral

condyle. The femoral attachment is in the form of a segment of a circle with the anterior border straight and the posterior border convex. The long axis of the femoral attachment is tilted slightly forward from the vertical, and the posterior convexity is parallel to the posterior articular margin of the lateral femoral condyle.

The ACL is attached to a fossa in front of and lateral to the anterior tibial spine. At this attachment, the ACL passes beneath the transverse meniscal ligament. A fascicle of the anterior of the ACL may blend with the anterior attachment of the lateral meniscus. The tibial attachment of the ACL is wider and stronger than the femoral attachment.

#### **Ligament Bone Attachment**

The cruciate ligaments attach to the femur and tibia via the interdigitation of collagen fibers of the ligament with that of adjacent bone. The abrupt change from flexible ligamentous tissue to rigid bone is



**Figure 1.** Arthroscopy inflow setup, showing Argyle 'Y'.

mediated by a transitional zone of fibrocartilage and mineralized fibrocartilage. The structure from ligament to bone allows for a graduated change in stiffness and prevents stress concentration at the attachment site.

#### **Vascular Anatomy**

The major blood supply to the anterior and posterior cruciate ligaments arises from the ligamentous branches of the middle genicular artery as well as some terminal branches of the medial and lateral inferior genicular arteries. The synovial membrane, which forms an envelope about the ligament, is richly endowed with vessels that

originate predominately from the ligamentous branches of the middle genicular artery. A few smaller terminal branches of the lateral and medial inferior genicular arteries also contribute some vessels to this synovial plexus through its connection with the infrapatellar fat pad. The synovial vessels arborize to form a web-like network of periligamentous vessels that insheath the entire ligament. These periligamentous vessels then give rise to smaller connecting branches that penetrate the ligament transversely and anastomose with a network of endoligamentous vessels. These vessels, along with their supporting connective tissues, are oriented in a longitudinal direction and lie parallel to the collagen bundles within the ligament.

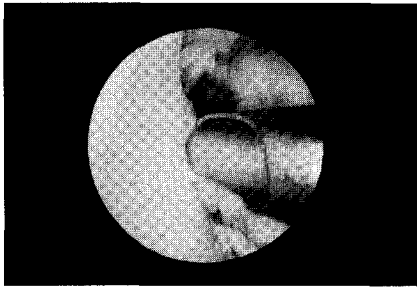
The anterior and posterior cruciate ligaments are supplied with blood from soft tissue origins. While the middle genicular artery gives off additional branches to the distal femoral epiphysis and proximal tibial epiphysis, the ligamentous-osseous junctions of the cruciate ligaments do not contribute to the vascular scheme of the ligaments themselves.

#### **Nerve Supply**

The cruciate ligaments receive nerve fibers from branches of the tibial nerve (posterior articular branch of the posterior tibial nerve). These fibers penetrate the joint capsule posteriorly and along with the synovial and periligamentous vessels surrounding the ligaments to reach as far anteriorly as the infrapatellar fat pad. Smaller nerve fibers have been observed throughout the substance of the ligaments. While most fibers are associated with endoligamentous vasculature and appear to have a vasomotor function, some fibers have been observed to lie alone among the fascicles of the ligament. These latter neural elements are located within multiple clefts in the tibial origin of the ACL and in its richly vascularized synovial coverings.

#### **Diagnosis**

By virtue of its shape, the knee possesses very little inherent stability. It



**Figure 2.** Motorized arthroscopic shaver debriding residual tissue.

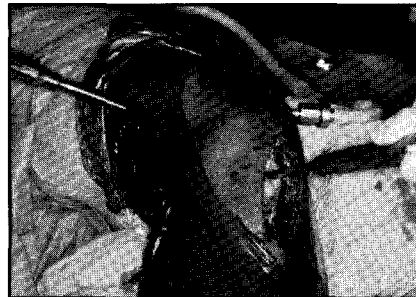depends on its ligaments, menisci, and the dynamic action of its surrounding muscles working together, in concert, to provide stability. John A. Feagin, editor of *The Crucial Ligaments*, poetically wrote that "the knee is a harmonious symphony of ligaments in which no ligament stands alone." The ACL has been termed by some as the "watchdog" of the knee. It is generally felt that when this ligament is disrupted, other problems will inevitably occur.

Rupture of the ACL usually occurs when forces generated by an individual in either changing direction or decelerating exceed the tensile strength of the ligament. An example of this would be that of a running athlete stopping suddenly or changing directions. Simply landing from a jump, as in skiing or basketball, is also a common mechanism by which the cruciate is ruptured. When an ACL rupture occurs, the individual usually experiences a popping sensation, severe pain, a giving-way movement of the knee, and an inability to continue present activity; rapid swelling of the knee within 3 hours occurs in 75% of the cases. The popping sensation occurs because the structural arrangement of the ACL allows it to store considerable energy before its elastic limit is reached. As a result, when this limit is reached, the ligament tears and the patient defines the sensation as a "pop." This pop is a classic sign of a tear or severe injury to the ACL and is noted in 40% of patients. A rapid, tense hemarthrosis occurs in 75% of patients.

#### **Treatment Options**

The decision to reconstruct the ACL

should be made with the understanding that the condition may alter the patient's lifestyle but will not shorten his or her life span. The ability to ambulate may be somewhat impaired and the activity level may need to be altered, but ACL insufficiency is not a life-threatening condition. A study was conducted involving Naval recruits with torn anterior cruciates. Surgical reconstruction was not employed and good results were obtained in 30% of the cases (good results being defined as the ability to resume normal activity). According to a study conducted by Noyes, a basic rule of thirds generally applies to patients suffering from a torn ACL. He concluded that without surgical intervention, one-third of all individuals

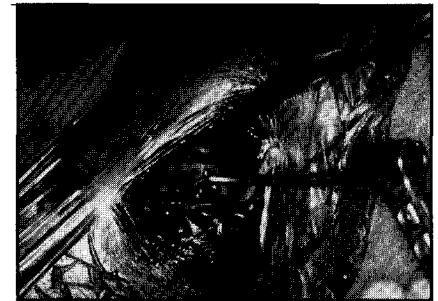

**Figure 3.** Intraarticular passage of J-shaped guide.

with ACL-insufficient knees will return to normal activity, one-third will have to adapt their activity by wearing a brace or giving up certain sports activities, and one-third will have chronic instability despite brace wear. There is no current literature that can indicate scientifically how to differentiate which patients will have a potentially quiescent ACL-deficient knee from those who will develop functional instability, meniscal tears, and posttraumatic arthritis.

If, however, the decision to reconstruct is made, a graft medium must be selected. There are several types of graft options available that are used in substitution for the ACL. The most commonly used is the central third of the patellar tendon. This tendon is 168% stronger than the original cruciate. This percentage decreases, however, during the devascularization period

experienced by the graft. Once revascularization and biological remodeling occur, the original bio-



**Figure 4.** Attachment of rear entry guide to J-shaped guide passer.

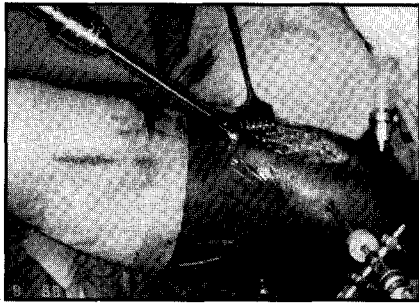
mechanical strength is regained and the graft is a stronger structure than its predecessor. Other grafts used are the semitendinous tendon, the gracilis tendon, the iliotibial band, or a synthetic ligament augmentation device (LAD). The selected tendon can be an autograft, which is harvested from the patient; an allograft, which is harvested from a cadaver; or a xenograft, which is harvested from a different species. The most commonly used graft is the autogenous central third of the patellar tendon.

#### **ACL Reconstruction**

No matter which graft is selected, the goals of surgery include normal stability, preservation of motion, muscular rehabilitation, and a return to sports unbraced. The steps performed in an ACL reconstruction are reasonably standard but the order in which they are performed may vary from surgeon to surgeon. The following procedure is an outline of the steps performed by Bernard R. Bach, Jr, MD, director of sports medicine at Rush-Presbyterian-St Luke's Medical Center in Chicago.

#### **Preoperative Testing**

A thorough exam is performed while the patient is in a supine position and under anesthesia. This allows the physician to examine the knee freely without interruption from the patient due to discomfort. The Lachman, pivot-shift, and KT-1000 tests are routinely performed. The results of these tests help to reaffirm the original diagnosis and



**Figure 5.** Tibial site overreaming.

provide a presurgical reference base to compare with postsurgical results.

### Diagnostic Arthroscopy

The first operative step performed is a diagnostic arthroscopy. During this stage, a general overview of the knee joint is performed. The knee joint is examined and evaluated for the presence of any degenerative joint disease, torn menisci, an existing ACL injury, and the status of residual ACL tissue. Any additional meniscal debridement or meniscal repair that needs to be performed is diagnosed and performed at this time. Prior to the scope insertion, a solution of epinephrine 1:300,000 is injected intraarticularly at the superomedial fluid inflow site and the inferolateral and inferomedial portal sites. The hemostatic property of this solution can generally allow the diagnostic arthroscopy to be performed without inflating the tourniquet. ACL reconstruction and possible meniscal repair usually require tourniquet inflation; however, minimizing total tourniquet time is always a goal.

Fluid infusion is obtained by gravity using four 3,000-cc bags of 0.9 normal saline connected to two TUR tubings and to an inflow cannula by means of an Argyle 'Y' connector (Figure 1). However, inflow pumps are now being used by some physicians for this purpose.

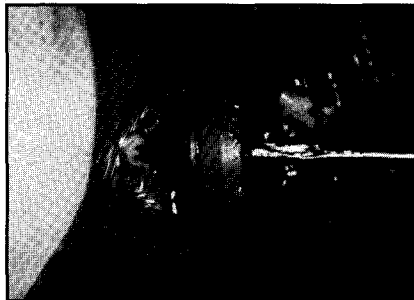### Intercondylar Preparation

After the diagnostic arthroscopy has been completed, intercondylar preparation is performed. During this process any residual tissue is debrided using a motorized arthroscopic shaver (Figure 2). If an ACL remnant is noted, it is also debrided.

It is important to debride residual tissue aggressively to visualize the intercondylar wall of the lateral femoral condyle and the ligament insertion site on the tibial eminence. If the tibial eminence region is not debrided, soft tissue incarceration may occur as the graft is passed intraarticularly.

### Notchplasty

Following ACL tissue debridement, a notchplasty is performed. A notchplasty is the act of expanding the intercondylar notch of the femur.

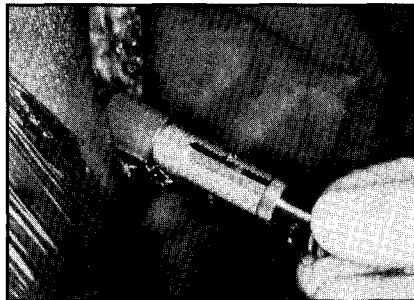


**Figure 6.** Concept carrot.

The purpose of the notchplasty is twofold. The primary purpose is to protect the graft from abrasion in the area that the graft must lie and pass through. Its secondary purpose is to assist in visualization during graft placement and femoral drill hole placement.

### Procurement of the Graft

Once the notchplasty and all intercondylar preparation have been completed, the autograft is



**Figure 7.** Isometry testing with strain gauge.

procured. A longitudinal skin incision is made, using a No. 15 blade, medial to the region of the patellar tendon. The tendon is marked and outlined with a No. 10 scalpel incision. An oscillating saw is used to

deepen the outline and obtain bone blocks on each end of the graft, one from the tibial tubercle and the other from the patella. The graft is then lifted from its bed with a curved 1/2-inch to 5/8-inch osteotome. The fat pad is dissected from the patellar tendon with Metzenbaum scissors. Leaving the fat pad intact at the patellar tendon site should help prevent any extravasation of irrigation fluid as a result of harvesting the patellar tendon segment. All sharp bone edges of the graft are contoured to facilitate passage through femoral and tibial holes. Three holes are placed at each end of the graft using a .062 K-wire. One No. 5 braided polyester nonabsorbable suture is passed through each drill hole. The graft is then wrapped in an antibiotic-soaked lap sponge and placed in a safe place on the back table.

### Supracondylar Femur Preparation

The preparation of the supracondylar femur follows the graft procurement. This involves making an incision in the midline of the lateral supracondylar area of the femur. The iliotibial band is noted and divided parallel to its fibers for a similar length to the incision. The vastus lateralis is identified and retracted with a Chandler elevator. The knee is then placed approximately in 45-degree flexion and the lateral supracondylar geniculate vessels are located and cauterized. Dissection is continued with a Cobb elevator until the surgeon is able to place a finger over the lateral femoral condyle and palpate the "over-the-top" extracapsularly.

### Femoral and Tibial Drill Holes

The next step, and probably one of the most crucial steps, is the placement of the drill holes. Inadequate placement of these drill holes can cause improper graft placement. The entire success of the operation depends on where the drill holes are placed. If the holes are off by even a few millimeters, it can significantly affect the strain on the graft, causing it to either stretch or elongate. An Acufex system (Acufex, Inc., Mansfield, Massachusetts) is what is presently employed at the authors'

institution for drill-hole placement. For the placement of the femoral drill hole, a J-shaped guide is passed through the midpatellar rent intraarticularly and under arthroscopic visualization passed over the top, entering the lateral supracondylar area to the lateral incision previously made (Figure 3). The re-entry guide, right or left according to the operative leg, is then attached to the J-shaped guide passer, introduced and positioned (Figure 4). Position is checked arthroscopically, and if correct, a Richards F 3/32 guide pin is then drilled. Placement is then verified by using an arthroscopic probe with reference to the "over the top" position. The next hole to be drilled is in the tibia. A 1.5-cm to 2.0-cm osteoperiosteal flap is created on the tibia with electrocautery and a Cobb elevator. The tibial eminence is visualized arthroscopically and an intraarticular guide wire is then drilled at an angle that when overdrilled will be in the center of the original insertion site of the ACL. If the placement is satisfactory, with a guide wire in place, a cannulated disposable drill is used for overreaming (Figure 5). If any further debridement is needed, it is performed at this time using a synovial resector. An arthroscopic rasp is now used to smooth the intraarticular openings and eliminate potential points of high stress on the graft. In order to decrease fluid extravasation, the holes are temporarily occluded using a Concept carrot (Concept, Inc., Largo, Florida) (Figure 6).

#### Isometry Testing

Now the moment of truth arrives: isometry testing. This is the means by which accuracy of drill hole placement is tested. This test can indicate the amount of strain that a graft placed through these drill holes and anchored in this position would experience. This isometry testing is done by first replacing the guide wire in the lateral femoral condyle with a monofilament suture that is secured with a hemostat. A strain gauge suture is attached and drawn back through the tibia, the joint, and out of the lateral femur and secured with a hemostat. The

knee is then extended from 90° to 0° noting the strain gauge reading (Figure 7). If the reading is greater than 2.5 mm, the drill-hole placement is not acceptable. The joint must be inspected with the arthroscope and the problem located and corrected, which may include redrilling. When the strain gauge excursion is less than 2.5 mm, the suture attached to it may be replaced by a .062 K-wire, which is eventually overreamed by a previously determined size disposable cannulated reamer. The posterior cruciate ligament is protected during femoral overreaming.

#### Graft Placement

Graft placement is the final step taken. The graft is taken from its secure place on the back table and admitted into the femoral side, through the joint, and into the tibial tunnel where it is secured. Ligament passage is facilitated by use of a Yankauer suction tube passed retrograde or by use of a commercially available ligament passer. Manual external tension is placed on the sutures and the new ligament is visualized and probed arthroscopically for any laxity that may exist. An assessment of the new ligament is made by taking the knee through full extension and checking for any impingement. If everything tests well, the graft is secured using Kurosaka interference screws. The primary advantage of using interference screw fixation is that it allows for a rigid fixation that permits a more aggressive early rehabilitation program. Care, however, must be taken to avoid screw divergence, convergence, graft or suture laceration, graft advancement, or intraarticular placement of the screw. Once secured, the graft is once again examined arthroscopically and palpated with a probe to assess tension and orientation. The knee is again placed through a full range of motion testing to assess the need for further notchplasty. The pivot-shift and Lachman tests are now repeated and the results are compared with the preoperative findings. The pivot-shift should be normal and the Lachman should have a firm end point and a 2-mm to 3-mm translation.

#### Conclusion

Scrubbing for an ACL reconstruction is both a challenging and professionally rewarding experience. The array of equipment utilized can be overwhelming. However, once a structured system is contrived and made familiar, the anxiety level diminishes substantially and is replaced with an air of confidence and accomplishment.

The value of learning this or any ACL reconstruction procedure in detail through outside reading and discussion with surgeons cannot be overemphasized. Being able to follow the steps of the procedure and anticipate the needs of the surgeon becomes a monumental asset to the entire team, an asset from which everyone, including the patient, eventually benefits. Δ


#### Bibliography

- Bach BR. Arthroscopy-assisted patellar tendon substitution for anterior cruciate ligament insufficiency. *Am J Knee Surg.* Jan 1989: 3-20.
- Cassells SW. *Arthroscopy: Diagnostic and Surgical Practice.* Philadelphia, Pa: Lea & Febiger; 1984.
- Dandy DJ. *Arthroscopy of the Knee: A Diagnostic Color Atlas.* Philadelphia, Pa: Lea & Febiger; 1984.
- Insall JN, ed. *Surgery of the Knee.* New York, NY: Churchill Livingstone; 1984.
- Jackson DW, Drez D. *The Anterior Cruciate Deficient Knee.* St Louis, Mo: CV Mosby; 1987.
- Jenkins DHR, ed. *Ligament Injuries and Their Treatment.* Gaithersburg, Md: Aspen Publishers; 1985.
- Snook G. The ACL: A historical review. In: Feagin JA, ed. *The Crucial Ligaments.* New York, NY: Churchill Livingstone; 1988: 157-159.
- Symposium on Arthroscopy and Arthrography on the Knee.* St Louis, Mo: CV Mosby; 1978.



# Meniscal Repair in the Knee

ARTICLE BY GARY J. ALLEN, CST



This article is intended as an overview of a procedure that is rapidly gaining popularity within the orthopedic community: meniscal repair in the knee. In the course of this presentation, the following will be discussed: relevant anatomy, types of meniscal injuries, considerations for repair, the patient's interoperative experience, repair techniques, complications, and rehabilitation. Although meniscal repair is commonly performed in conjunction with reconstruction of the anterior cruciate ligament, the latter will not be discussed. A general knowledge of anatomy, arthroscopy, and medical terminology is assumed of the reader.

The relatively brief history of the arthroscope has proven it to be an invaluable tool, and its application to many techniques involving the knee are well documented. With its limited intervention, arthroscopy has virtually replaced open arthrotomy for the resection of damaged menisci and is now being employed to repair, rather than remove, the fibrocartilage in the hopes of maintaining the integrity of the joint. This conservative approach is gaining recognition and is indicative of the dynamic nature of surgery, of which surgical technologists should be aware.

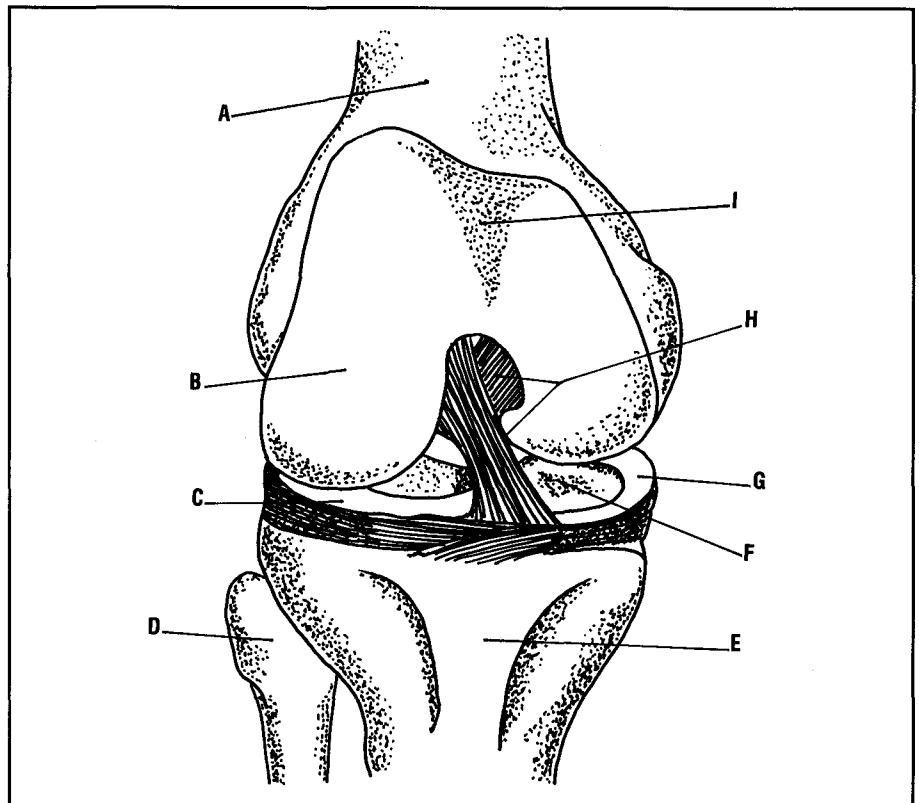
## Historical Background

Prior to the advent of arthroscopy in 1975, the standard treatment of meniscal injuries entailed open arthrotomy and total meniscectomy. This approach was rationalized by the belief that meniscal tissue, like

the appendix, was an evolutionary remnant, presumably of muscular origin, which served no function. Its excision, therefore, was regarded as proper therapy. It was not until 1948 when W. Fairbanks reported poor results following total meniscectomies that this avenue of thought began to change.<sup>1</sup>

The arthroscope provided excellent diagnostics without extensive surgical intervention. Its versatility was immediately evident and con-

current developments in prosthetics drew attention to the importance of the menisci's design. Early arthroscopic techniques focused on simple procedures (eg, removing loose bodies, resecting meniscal cartilage, and releasing constraining ligaments), but in the past decade attention has turned to more complicated tasks, such as anterior ligament reconstruction. Today, this continuing trend includes repair of damaged menisci.



**Figure 1.** Anterior view of knee (patella removed). A, Femur; B, Femoral articular surface; C, Lateral meniscus; D, Fibula (extra-articular); E, Tibia; F, Tibial articular surface; G, Medial meniscus; H, Cruciate ligaments; and I, Patellar surface.

## Anatomy of the Knee

The knee, or tibiofemoral joint, is the largest articulation in the body and is a hinge-type joint that allows for movement along a single plane. The knee's role in weight-bearing subjects it to a considerable amount of stress, and aberrant motion will frequently cause injury to the joint's supportive structures.

**Bones.** The convex surfaces of the medial and lateral femoral condyles sit upon the somewhat flat surface of the tibial plateau, forming two compartments that are separated by the tibial spine (intercondylar eminence). Likewise, the convex undersurface of the patella glides over a slight concavity in the anterior femur (patellar surface). This interaction results in the creation of three joint surfaces: the lateral tibiofemoral, the medial tibiofemoral, and the intermediate patellofemoral.<sup>2</sup>

**Soft Tissues.** Strength and stability in the knee are conferred by ligaments and tendons that join the tibia and femur medially, laterally, and posteriorly and the patella anteriorly. A thick capsule, lying inferior to these structures, is lined with a soft, vascular synovium. The synovium gives rise to the menisci, which will be discussed shortly, and also produces fluid that nourishes and lubricates the internal structures. The cruciate ligaments (anterior and posterior) insert along the tibiofemoral midline. Their "X" configuration controls the femoral "roll-back" on the tibia surface, lending primary joint stability (Figure 1).

**Menisci.** The two menisci are fibrocartilagenous structures that are contiguous with the synovium and lie between the femur and tibia. Crescent-shaped to follow the outer curve of the tibial plateau, these pads lie medial and lateral to the tibial spine.<sup>2</sup> There are bony attachments to the midline of the tibia at the anterior and posterior poles (Figure 2). In cross-section, each meniscus looks like a wedge, with its base lying at the synovial junction and a sharp inner edge forming the apex. A normal meniscus is whitish-yellow, smooth in texture, fibrous, and pliant. Its blood supply, the extent of which is an

important consideration in meniscal repair, is mainly dependent upon the synovium.<sup>3</sup>

## Meniscal Function

The meniscal "remnant theory" was first disputed by A. Fick, in 1910, who perceived that the menisci provided joint stability.<sup>1</sup> In 1936, D. King supported this view with experiments on canine menisci that displayed measurable protection from articular cartilage degeneration.<sup>3</sup> He also proposed that there was both a lubricating and shock absorption quality to the meniscus.<sup>3</sup>

Prosthetic trials in the 1970s showed that the menisci give stability to the joint by maintaining the position of the femur atop the tibia. This was evidenced by the failure of early implants, which mimicked the flatness of the tibial plateau, to retain knee integrity. Under load the femur was inclined to slide across the tibia (shear) and rapid surface breakdown occurred. Once the wedge shape of the meniscus was incorporated into the design of the plastic tibial insert the full value of joint replacement was appreciated.

Today it is acknowledged that the menisci perform all of these functions, as well as the redirection of femoral pressure upon the tibia.<sup>1</sup> Known as "hoop stress," this pressure acts upon the knee much like the contents of a barrel does upon its staves. Barrel hoops maintain an equilibrium, so a break in one results in an uneven displacement of pressure and a bulging of the underlying

stave in response. The menisci act like the hoop and ensure an even, radial distribution of femoral pressure. This lessens the impact upon and the consequent wear of the tibia.

## Meniscal Tears

Meniscal tears are caused by a tibiofemoral interaction that results in shearing and compression.<sup>2</sup> Examples of such movement are rotation and femoral subluxation, which are both exhibited during sports-related activities. Tears may be of partial thickness or extend through both its superior (femoral) and inferior (tibial) surfaces. Tears within the peripheral third of the meniscus are more likely to heal due to the excellent vascularity in that area. Another factor to consider prior to initiating repair is the type of defect.

**Radial.** Radial tears are divisions of the meniscal fibers on a perpendicular or vertical plane and generally arise from the tapered edge and extend towards the periphery (Figure 3, A). Repair of these defects is not common; however, attempts have been made to reunite the ends in an effort to retain meniscal integrity rather than subject the joint to cushioning loss.

**Horizontal.** These tears develop along a horizontal plane and give the appearance of meniscal layering called "fish mouting" (Figure 3, B).<sup>4</sup> Horizontal tears are treated by resecting flagellate tissue and abrading between the layers to encourage healing.

**Longitudinal.** Referred to as "bucket handles," these tears arise

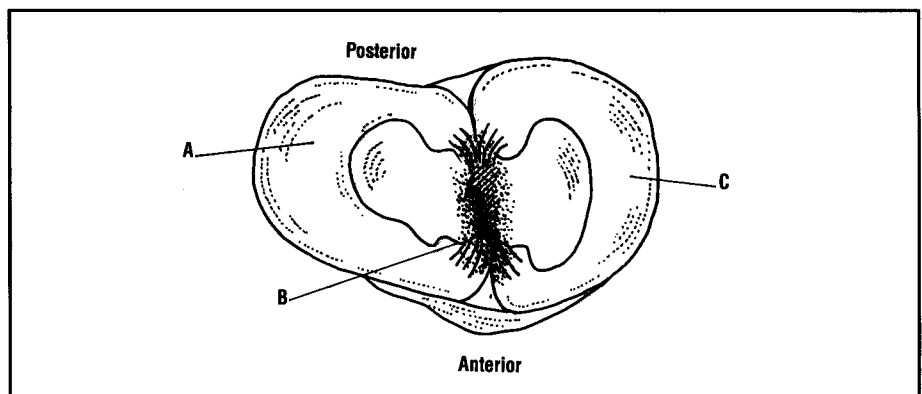
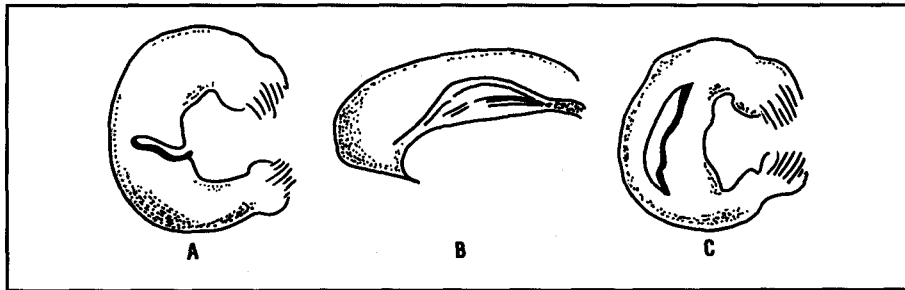


Figure 2. Superior view of tibia. (Note anterior and posterior attachments.) A, Lateral meniscus; B, Intercondylar eminence; C, Medial meniscus.



**Figure 3.** A, Superior view of radial tear in the lateral aspect of meniscus. (Note defect's perpendicular plane.) B, Anterior view of horizontal posterior horn tear demonstrating "fishmouthing" effect; and C, Superior view of longitudinal tear of posterolateral aspect of meniscus demonstrating "bucket handle" effect.

along the curve of the meniscus and separate rather than divide the fibrocartilagenous fibers (Figure 3, C).<sup>4</sup> This condition and their usual proximity to the nourishing synovium make these tears the best candidates for arthroscopic suturing techniques.

Due to shearing and the menisci's configuration, medial compartment tears are predominantly longitudinal, whereas those in the lateral compartment are usually radial.<sup>5</sup>

#### Indications for Repair

Clinical indications suggest that damaged menisci that cannot be left alone (as seen with short radial or partial thickness tears) or repaired should be prudently resected to lessen the impact of its loss on the joint. Otherwise suturable defects that exhibit tissue loss or further deformity due to wear are also treated in this manner. The age of the tear is not a major consideration in regard to healing; however, its long-term effect upon the articular cartilage is a concern.

Although open repairs were first documented by T. Annadale in 1885 and have been vigorously attempted since 1976, the arthroscopic technique has only gained popularity since the mid-1980s.<sup>3</sup> Longitudinal defects greater than 7 mm can usually be treated arthroscopically, unless occurring in the anterior portion of the meniscus. This area's location creates a technical challenge that is best solved by arthrotomy since ideal arthroscopic suturing requires perpendicular traction.

#### Diagnosis

The patient generally exhibits pain in the lateral or medial aspect of the

knee, corresponding to the damaged meniscus, accompanied by tightness or clicking within the joint upon flexion. Swelling may also be present due to the synovial response to injury. The use of magnetic resonance imaging (MRI) makes effective diagnosis awkward, as it may interpret a natural wrinkle in the meniscus as a tear. The once popular arthrography is now rarely used.

#### Arthroscopic Meniscal Repair

For this discussion, a longitudinal tear in the peripheral posterior horn of the right medial meniscus is assumed to exist.

**Preoperative Preparation.** Preoperative protocol for arthroscopic meniscal repair follows the same format as arthroscopy including same-day admittance, charting, and site preparation, followed by transfer to the operating room. There the patient is placed in the supine position and inducted with general anesthesia.

A tourniquet is applied to the right thigh and a leg holder is secured to the frame of the table and placed against the extremity at a point adjacent to the pneumatic cuff. This acts as a fulcrum against which the leg is manipulated to open the knee's medial and lateral compartments for proper examination.

The entire extremity is prepped and draped free both to facilitate repair and to decrease contamination. All required lines (light cord, in-/out-flow tubings, monitor camera, electrodriven chondrotome, and cautery) are secured to the field and joined to their respective equipment. One device, a pump, can regulate

both irrigant flow and internal joint pressure, an asset in arthroscopy because good visualization is essential. Steady flow keeps the distention medium clear and pressure monitoring helps reduce tissue extravasation.

**Arthroscopic Examination.** A thorough arthroscopic examination is made of the knee to assess the suspect tear and inspect other tissues for damage or degeneration. When meniscal repair is anticipated, the arthroscope is usually introduced through a portal in the affected (ipsilateral) compartment, in this case the medial compartment. The probe (used to test meniscal integrity and determine a tear's extent) and repair instruments, are manipulated through a portal in the opposite (contralateral) space (lateral). Out-flow is via a suprapatellar portal.

A 30° arthroscope normally provides a good anterior view of the entire joint, but a 70° lens, passed through the intercondylar notch, is best for evaluating posterior tears. A constant joint pressure of 35 mm to 40 mm of mercury is desired and, in general, tears less than 1.5 cm in length are not repaired. However, all tear surfaces, regardless of other treatment are rasped to encourage revascularization and healing.<sup>1</sup>

**Meniscal Repair.** After evaluation, the surgeon selects the appropriate repair cannula (Figure 4). The cannula is curved to accommodate the anatomic contours of the knee with fluted distal ends to provide better visualization during suturing. The proximal tip is covered with a rubber cap that allows passage of the needle yet retards irrigant loss. The curve also dictates the use of a needle that is flexible yet has a high "memory" for repeated usage. The illustrated needle (Figure 5) is reusable (one per case) and requires the use of nonabsorbable free ties. Other suturing material includes swagged-on, single-use needles that are seemingly less cost-effective.

Location of the tear in the posterior horn of the medial meniscus necessitates the creation of a posteromedial incision in order to retrieve the needle and repair sutures. The incision is 2 in long and is dissected to the fascia with particular attention

given to avoid damage to the nearby saphenous neurovascular bundle.

The surgeon inserts the repair cannula through the lateral portal and positions it against the superior surface of the inner meniscal fragment (Figure 6). The knee is now flexed to provide the proper angle and the loaded needle is passed slowly through the cannula and meniscus and into the back of the knee. A retractor is placed in the posteromedial incision to protect the nerve and serve as a stop. An assistant retrieves the needle and guides it and the nonabsorbable suture out of the joint. The cannula is then repositioned radially to a point on the meniscus 2 mm to 3 mm from where it was first placed and the other end of the strand is passed on the needle in the same manner. When both suture ends exit the wound they are tagged, and the process is repeated until enough sutures have been passed to effect a secure repair.

Ideally, the first stitch is positioned at the most anterior aspect of the tear with subsequent sutures spaced 3 mm to 4 mm apart, the last one lying at the most posterior end of the tear (Figure 7).<sup>3</sup> Unfortunately, tears that extend to the posterior meniscal attachment to the tibia still present a repair problem, as suture placement is limited by the neurovascular structures in this area. Proper suturing may require the use of more than one meniscal cannula to effectively bypass the tibial spine.

The distance between the insertion points of each stitch is dependent upon both the location of the tear and the overall width of the meniscus. Alternating sutures may be placed along the inferior meniscal surface, as the peripheral width allows. This technique serves to counteract the "cupping" that superior surface placement alone can exhibit. The surgeon must also avoid placing the sutures too close to the apex, as traction can result in the tapered edge curling under the inferior meniscal surface.

Once all sutures are passed, they are tied together over the fascia and the repair is inspected arthroscopically. If satisfied, the surgeon removes the arthroscope and flushes

the knee with antibiotic solution. Equipment is removed from the field, and the incisions are closed and dressings applied.

**Postoperative Care.** After removal of the drapes, the patient is extubated and transferred to recovery, where he/she remains for about 2 hours. The knee is immobilized and crutches are provided for the patient's use. A follow-up visit is normally scheduled 7 to 10 days postoperatively.

### Complications

The general complications of arthroscopy include articular damage caused by the introduction of instrumentation; infection, which is uncommon and mostly attributed to improperly sterilized equipment; burns by light cords and sterilizing solutions; and neurovascular injury, caused by injudicious portal placement. During lengthy procedures, irrigant extravasation may also occur.

Complications particular to meniscal repair are generally related to saphenous or peroneal neurovascular damage during dissection of the retrieval incision. Repair failure is usually attributed to a lack of vascularity within the tear's surfaces. Recurrence has shown to be reduced when compared with resection.

### Rehabilitation

Clinical studies reveal that 80% to 90% of all repairs in the peripheral third of the meniscus are successful.<sup>5</sup> This is true of both open and closed approaches and is indicative of the role that vascularity plays in healing. High success rates are also due to proper rehabilitative efforts.

All patients are advised to limit activity for 4 to 6 weeks. The most important factor in healing is avoidance of full weight-bearing in flexion or squatting, as both movements put direct pressure on the meniscus. Light exercise can begin in 2 months, but strenuous motion should be avoided for up to 4 months. Meniscal healing has been observed as soon as 8 weeks postoperatively.

### Other Repair Techniques

Limited meniscal vascularity has prompted the attempt to encourage




Figure 4. Concept Zone Specific™ cannula set. (Photo courtesy of Linvatec Corp, Largo, FL)

vessel infiltration by drilling holes in the cartilage. Fibrin clots are also used as a means to promote healing.<sup>5</sup>

A method of open meniscal replacement entails cadaveric allografts. Each graft is harvested in accordance with criteria set by the American Association of Tissue Banks and includes the taking of tibial bone plugs at the anterior and posterior ends of the meniscus. Once implanted, these offer an immediate blood supply. The periphery and synovium are also

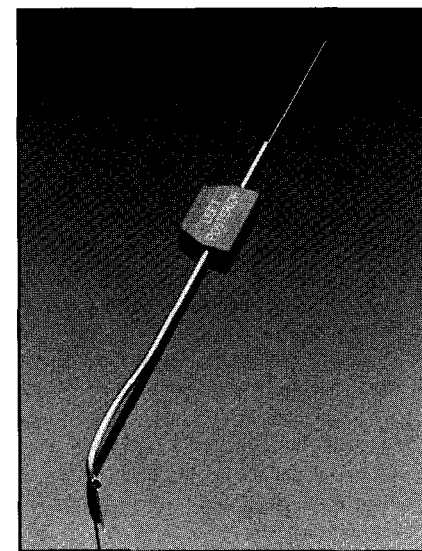
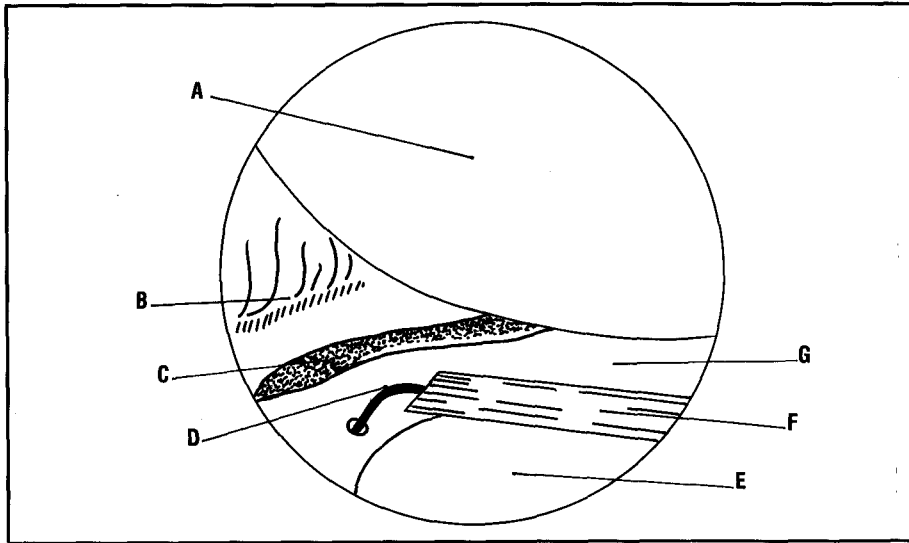


Figure 5. Flexible eye meniscal repair needle in Concept™ cannula. (Photo courtesy of Linvatec Corp, Largo, FL)



**Figure 6.** Arthroscopic view of cannula positioning. A, Medial femoral condyle; B, Synovial junction; C, Meniscal defect; D, Repair suture; E, Tibial surface; F, Cannula; and G, Medial meniscus.

abraded and sutured together. Cadaveric grafts are cryopreserved, but a fresh graft can be used within 4 to 6 hours. However, many conditions contribute to failure including rejection, infection, insufficient cellular viability, and degeneration. Results currently await compilation.<sup>3</sup>

#### Conclusion

The patient benefit derived from this approach to meniscal salvaging exceeds anything ever realized with the menisectomies of old. Likewise,

patient morbidity from arthroscopy is virtually nonexistent and cosmesis is markedly improved when compared with open arthrotomy. Meniscal loss can end a sports career, as well as cause an early onset of articular degeneration. These and many other reasons warrant the effort to salvage damaged menisci.

As with any evolving surgical procedure, acceptance depends upon greater numbers of clinical applications. Although the early focus has been on tears in the

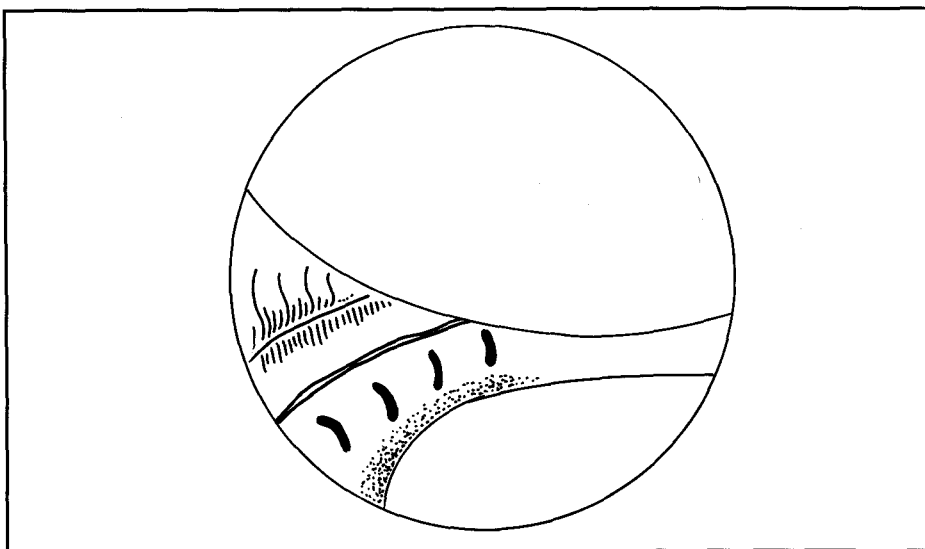
peripheral third of the meniscus, recent findings indicate that healing also occurs in defects extending two-thirds of the meniscal width.<sup>3</sup> This is very encouraging. The surgical technologist should take note that operations similar to these ensure arthroscopy's expanding role in corrective treatments of knee injuries.Δ

#### Acknowledgements

The author gratefully acknowledges Joseph Sklar, MD, of New England Orthopaedic Surgeons, in Springfield, Massachusetts, without whose guidance and input this paper would not have been possible. He would also like to acknowledge the cooperation of Kris Gamble and Brian Salle of Linvatec Corporation, Largo, Florida, for providing photographs of and information on their Concept™ line of meniscal repair products.

#### References

1. Mow VC, Arnoczky SP, Jackson DW. *Knee Meniscus, Basic and Clinical Foundations*. New York: Raven Press; 1982.
2. Tortora GJ, Anagnostakos NP. *Principles of Anatomy and Physiology*. 5th ed. New York: Harper & Row Publishers; 1983.
3. Marzo J, et al. Arthroscopic meniscal repair. *Am J Knee Surg*. Fall 1991.
4. Gruendemann BJ, Meeker MH. *Alexander's Care of the Patient in Surgery*. 7th ed. St Louis, Mo: C.V. Mosby Co; 1989.
5. Rosenthal E. New repairs for torn knee cartilage. *New York Times*. November 11, 1992.



**Figure 7.** Arthroscopic view of repair. (Note four sutures and closed defect.)

# Bilateral Patellar Tendon Rupture

ARTICLE BY RONALD ALSTON, CST

**I** am a 34-year-old black male who considers myself to be in the best of health, a very active participant in most recreational sports, and a competitive bodybuilder. At this time, I am not taking any medication and have no prior knee injuries.

In an instant, my life changed. On Thursday, September 16, 1993, during a recreational touch football game, I attempted to jump for a ball thrown to an opposing player and felt immediate pain in both knees before hitting the ground. This pain lasted approximately 20 minutes and was localized in both knees just below the patella. I was unable to ambulate but could move both feet and had numbness in both of my knees. I was removed from the playing field about 25 minutes later by four teammates and waited to be transferred by ambulance to a nearby emergency room, not knowing the extent of my injury. The pain had now subsided. After being seen by the physician on-call for orthopedic trauma, the admitting physical examination showed bilateral patella alta (high riding kneecap) with palpable infrapatellar soft tissue defect and localized swelling (Figure 1). There was no active knee extension and no other ligamentous laxity of the knee. Both my legs were neurovascularly intact.

This article will acquaint the reader with the surgical procedure of bilateral patellar tendon repair as well as postoperative responses and rehabilitation from the unique perspective of a patient as well as a CST.

## Radiologic Examination and Immediate Treatment

X-rays films were taken and read by the on-call radiologist who reported both knees with patella alta with some bony deposits and no bony fragments. Despite the unremarkable x-ray film, there was severe injury to both of my knees. Both of the patellar tendons had ruptured, making active knee extension impossible. The treatment for bilateral patellar tendon rupture is surgical repair of the patellar tendon disruption with bilateral application of plaster splints. Full-leg Robert Jones dressings were applied to both legs to keep them immobile. Surgery was scheduled for the next morning and medication was given for pain.

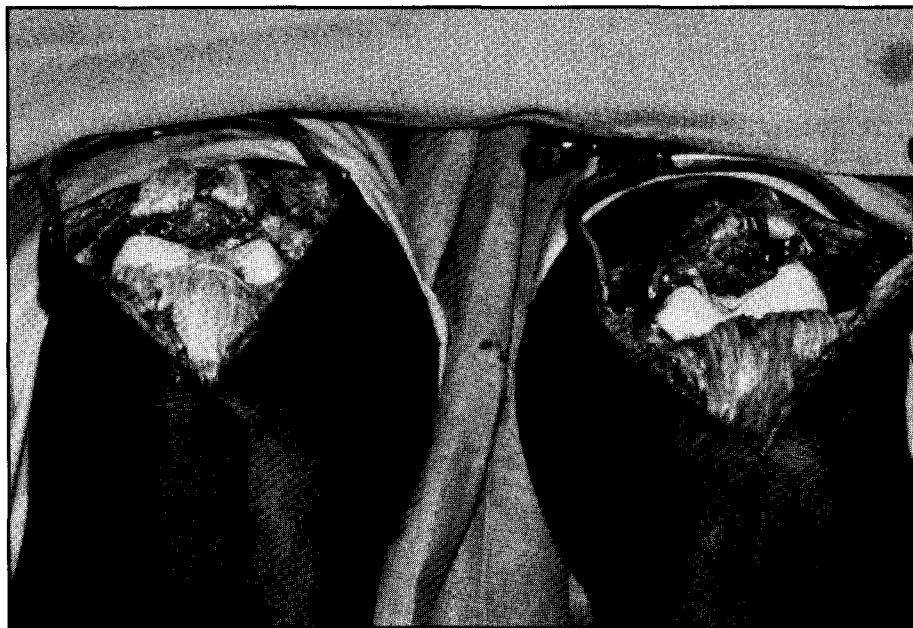
Two years prior to this injury, I had been diagnosed with Osgood-Schlatter disease or "jumper's knee." Treatment included ice and rest, which seemed to alleviate the problem. Partial rupture of the patellar ligament, known as jumper's knee, is a repetitive overload lesion at the bone-tendon junction at the lower patellar pole. Found mainly in athletes, it is caused either by microrupture or partial macrorupture of the proximal part of the tendon with degeneration and devitalized tissue at the insertion of the patellar tendon. Peripatellar tendinitis affecting either the quadriceps tendon or the patellar tendon insertion onto the patella is most commonly seen in athletes involved in jumping-related sports. Patellar and quadriceps ten-

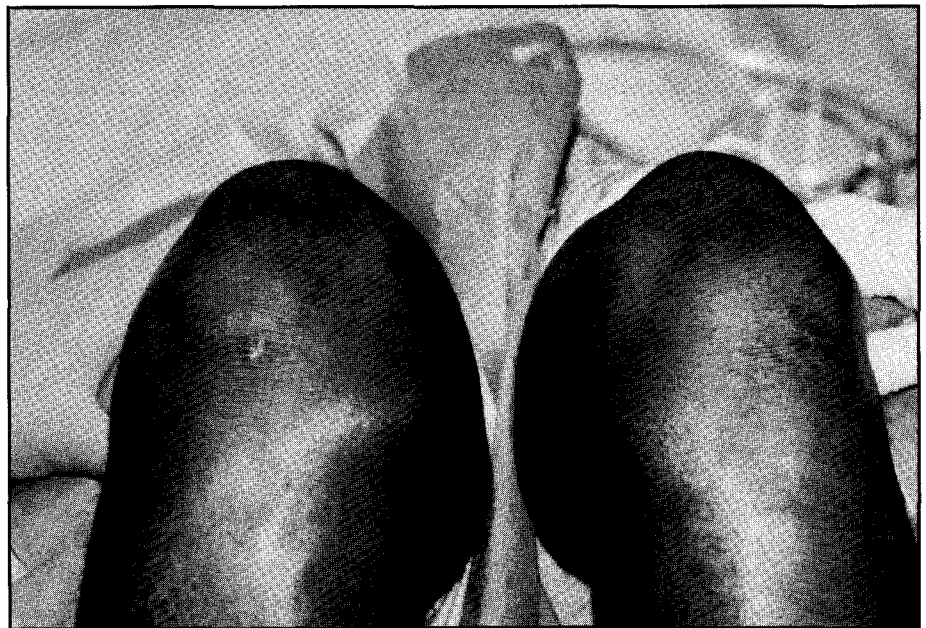

Figure 1. Anterior view of both knees showing defects inferior to both patellae.

don ruptures from indirect injury in athletes may represent the end stage of jumper's knee and result from repetitive microtrauma. Many athletes involved in sport activities place repetitive stress on the extensor mechanism of the knee, causing microtrauma concentrated at the superior or inferior pole of the patella. Volleyball seems to be the most common sport involved, as well as basketball, a sport in which I frequently participate. As a result of patellar trauma, a critical degree of tendon degeneration may have occurred prior to rupture. The overloading of the knees leads to degeneration of the patellar tendons, plus decreased elasticity, degenerative changes in collagen fibrils, and decreased vascular supply. In this case, the major factor leading to the tendon ruptures was degeneration from repetitive microtrauma that represents end stage jumper's knee. My age was also a factor since the tendons had undergone more wear and tear than would be found in a younger athlete.

Bilateral patellar tendon rupture is a very rare injury seen in approximately five patients a year in the United States with approximately 20 reported cases in English literature. Mine was only the second such procedure ever performed at the Mayo Clinic. The majority of these cases occurred in patients with systemic diseases such as systemic lupus erythematosus, rheumatoid arthritis, or renal failure. Rupture of the infrapatellar tendon in healthy athletes, as well as those diagnosed with jumper's knee, is extremely rare. In this case, the injury occurred as the tendons snapped at the lower pole of the patella by the strong force of jumping, thus causing the quadriceps to contract and fire with an extreme amount of force causing both patellae to retract superiorly into the region of the thigh. Bilateral patellar tendon rupture precludes the patient from ambulation or extension of either leg. Rupture of the patellar tendon requires immediate surgical attention. Excellent function usually follows repair of patellar tendon ruptures when surgery is performed early and care is taken to



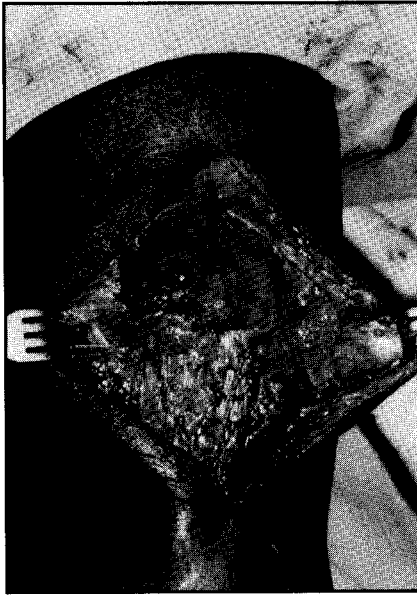**Figure 2.** Anterior view of both knees showing disruption of both patellae tendons.

restore normal patellar tendon length. Delayed surgery may cause technical problems in repair. If not repaired soon after injury, patellar tendon shortening may occur.

#### **Operative Procedure**

On September 17, 1993, I was brought to the orthopedic anesthesia block room and placed under epidural anesthesia. I was then taken to the operating room where my lower extremities were prepared and draped in the usual fashion. Tourniquets were applied to the thighs. The limbs were exsanguinated and the tourniquets were inflated to 300 mm of mercury. The repair of the patellar tendons was carried out simultaneously as follows. An incision was made centered over the patella from the superior pole to the medial aspect of the tibial tuberosity and approximately 1 cm distal to this point. This incision was carried down through the suprapatellar bursa and the tendon sheath was incised and the patellar tendon exposed. Immediately upon reaching the level of patellar tendon, it was noted that both patellar tendons were disrupted completely from the inferior pole of the patella with no

significant stump on the inferior pole (Figure 2). Both sides had complete disruption of the patellar retinacula, both medially and laterally. The joints were inspected and the cartilage was found to be free of damage. The medial and lateral menisci of both knees were intact as were the anterior cruciate ligaments. Attention was then turned to the repair, which was performed with a No. 1 polybutylate (Ethibond) suture in a Krakow stitch in each patellar tendon medially and laterally. A Krakow stitch is a weaving stitch that makes it easier to obtain better fixation of the tissue. Three drill holes were placed in the patella after the bed was prepared using a burr. The No. 1 polybutylate suture was then carried up through these drill holes. A drill hole was placed in each tibia just above the level of the tibial tuberosity through which a No. 5 uncoated polyester fiber (Mersilene) suture was passed. The sutures were then carried circumferentially through the retinaculum and quadriceps tendon and tied tightly with the knee in 30° flexion. Following this, the No. 1 polybutylate suture was carried through the patella and tied tightly (Figure 3). Good apposition of the patella to



**Figure 3.** Intraoperative repair of tendon showing sutures.

the patellar tendon was achieved and my knees were able to be flexed 90° without disruption of the repairs. The retinacula were closed using interrupted 0 polybutylate sutures and the remaining frayed edges of the patellar tendons were tacked down using 0 uncoated monofilament polyglactin 910 sutures. The tourniquets were released and hemostasis obtained with electrocautery. The wounds were irrigated and closed over a drain with interrupted 2-0 uncoated monofilament polyglactin 910 sutures subcutaneously and interrupted 2-0 polypropylene sutures in the skin. Sterile dressings were applied, followed by long-leg Robert Jones dressings with medial and lateral plaster splints. I was taken to the recovery room in good condition.

#### **Postoperative Care**

**9/20/93:** Three days after surgery, I was taken to the cast room. My dressings were removed, exposing intact wounds without erythema or drainage. Long-leg Robert Jones dressings with medial and lateral plaster splints were placed and I was returned to my room. On September 21, 1993, I was released from the hospital and was sent

home with pain medication.

**9/24/93:** I was brought back to the cast room for removal of the Robert Jones dressings. My wounds were intact even though I had been having some fever previously. The incisions were nontender and had absolutely no drainage or erythema, thus my sutures were removed and 1/2 in adhesive strips were placed over the wounds. I was then placed in Ortho-Tech Rehab III braces with the knees locked in full extension.

During the first 2 weeks after surgery, I went through both mental and physical changes despite the fact that I knew what was ahead. During my recovery period, the seriousness of my injury and extent of my surgery had not yet set in. Being as active as I had been and never experiencing any injury that had disabled me for a significant time period, losing the use of both lower extremities was devastating to say the least. The rupture of a single patellar tendon is rare and I felt it would never happen to me. The possibility of bilateral patellar tendon rupture is merely impossible, at least that is what I kept telling myself despite the fact that such surgery had been performed. Both legs were in braces and the only mobility I had was through the use of a wheelchair with the help of my wife. Depression really set in as I went from a very active, independent young man to a totally dependent one. The days during this healing process grew longer. I was unable to walk or play with my 3-month-old daughter and, for a short period of time, I stopped eating. Yet, I really didn't believe it was happening to me. Before my injury, I spent much of my free time in the gym lifting weights. I worked very hard at developing my body. But despite all my efforts, I saw my legs atrophying before my eyes.

Time helped me work through the pain though it was not always easy to keep a positive attitude. I dug deeply into myself and once my acceptance was put into perspective, the real healing began.

**10/22/93:** I returned to the cast room where my wounds were clean, dry, and intact. I began motion from 0° to 30° and was

scheduled for physical therapy (PT) to start October 22, 1993, in the Sports Medicine Department. I would be assessed in 3 weeks.

**10/29/93:** My knee motion was increased to 60°, but I still had to remain non-weight-bearing as I had been since I entered the hospital.

**11/15/93:** I was seen by my physician as an outpatient to check the motion as well as the strength of my repair. The ability to actively extend my legs was intact.

#### **Rehabilitation**

**10/22/93:** 45-minute therapeutic exercise (TE) and measured for a platform walker with height of 45 in. Increased the Ortho-Tech hinge brace from 0° to 30° to 0° to 60° bilaterally and then progress to 90° and crutches within 3 weeks.

**11/10/93:** 30 minutes TE. Doing well, easily achieved 60° range of motion (ROM). The brace was increased to 90° and crutches were added using a four-point gait for walking. Next session in 2 weeks and increase brace to 120°.

**11/19/93:** 30 minutes TE. Now have 0° to 70° ROM. Will proceed with daily PT to increase ROM and increase brace to 120°.

**11/22/93:** 45 minutes TE. Passive motion now at 0° to 80°. Will attempt to use Biodex machine, which is used to flex and manipulate the knee to increase available passive motion. Continue on a daily basis.

**11/23/93:** 45 minutes TE. Used hot packs. Biodex used for ROM passive mode using 12.5 in on leg extension and 4 in on the seat. Was able to achieve 73° flexion bilaterally using Biodex scale.

**11/24/93:** 45 minutes TE. Hot packs and Biodex machine for passive motion not at 80° bilateral passive motion parameters as above. Continue on a daily basis.

**11/26/93:** 45 minutes TE. Hot packs and Biodex machine for passive motion to 85°. Ice was applied following exercise.

**11/29/93:** 45 minutes TE. Hot packs, passive motion to 90°.

**11/30/93:** 45 minutes TE. Hot packs, PT as above. Ten minutes upper body ergometer (UBE) machine approved by physician to



begin strengthening.

12/1/93: 45 minutes TE. Hot packs and Biodex for passive motion. Continue daily.

12/2/93: 45 minutes TE. Hot packs and Biodex for passive motion to 92°. Continue daily.

12/6/93: 45 minutes TE. Hot packs and Biodex for passive motion. UBE for 10 minutes. The UBE is being used for cardiovascular work.

12/7/93: 45 minutes TE. Hot packs and Biodex for passive motion 0° to 93°.

12/9/93: Same as 12/7/93.

12/10/93: 30 minutes TE. Bilateral flexion 90° to 95°.

12/14/93: 45 minutes TE. Passive motion bilaterally to 100°.

12/15/93: Added leg press, three sets of 15 repetitions, level six to continue 3 to 4 times a week.

12/17/93: 45 minutes TE and Biodex and will proceed with leg press at the YMCA. Three sets of 10 to 15 repetitions.

12/21/93: Doing well. Biodex to 105° bilaterally. Will increase leg press to level 8 doing three sets, 2 to 3 times a week.

12/22/93: 45 minutes TE. Hot packs and Biodex up to 105° on the left and 107° on the right. Add hamstring curls and toe raises.

12/27/93: 45 minutes TE. 108° on the left and 105° on the right.

12/28/93: 45 minutes TE. Same as previous day.

12/29/93: 45 minutes TE. 110° bilaterally. Add leg press, hamstring curls, toe raises, added hamstring stretching due to discomfort in the medial distal hamstring. Continue as able.

1/5/94: 45 minutes TE. 110° on the left and 105° on the right. Ice post-exercise. Continue with Biodex until maxed out. Proceed with total gym.

1/6/94: 45 minutes TE. 110° on the left, 108° on the right. Continue with leg press, hamstring curls, toe raises on own time, as well as three times a week in Sports Medicine Department.

1/7/94: 45 minutes TE. 111° on the left, 110° on the right. Continue as able. Total gym trial next week.

Rehabilitation continues on a daily basis and will throughout the next 3 to 4 months. Expected ROM

bilaterally 130° to 135°. I should be able to resume all activities with no complications.

### Summary

As CSTs, we are integral members of the surgical team working with the surgeons, nurses, and anesthesia providers, as well as the patient. Our job duties require us to perform a number of tasks, the most important being to provide the best patient care possible. In order to perform these responsibilities, we attend accredited surgical technology programs. These programs assure us of the essentials needed to carry out these responsibilities. As a CST, I feel my training has been the best. We CSTs work hard to uphold our position. We sharpen our skills each day we work in the operating room. We are truly professionals. In the article, I shared a personal experience with you and, with this experience, I learned some things that we do not and can not see through the eyes of the patients to whom we provide surgical care each day. This lesson can not be taught in the classroom, during our clinicals, or in our everyday practice. This is the traumatic effect that major surgery has on our patients after they leave the operating room. Most are faced with days and weeks of pain, uncertainty, and unanswered questions.

My misfortune has given me an unwanted opportunity to experience the most difficult part of a patient's surgical experience. As a patient, I endured what I would consider the worst. Surgery was easy and painless—postoperatively is when the debt is finally paid. I have lost a lot as a result of my injury and my surgical experience as a patient resulted in inactivity, mental imbalance, and the uphill battle of fighting each day to feel normal again. My pain has endured through the course of my rehabilitation. Learning to walk again has not been easy. I thought that through rehabilitation it would become easier. I was wrong; it becomes harder and continues until you are whole again. Rehabilitation will continue for many months. Through it all, a valuable lesson has been learned; as a CST, the care I give to a patient

once they enter the operating room until the time they leave will never be enough. I have experienced their pain and frustration and from the time they leave the operating room, it is the start of a new beginning for most of them. Δ

### Acknowledgements

I would like to thank Robert Trousdale, MD, Department of Orthopedic Surgery, Mayo Clinic, for performing my surgery and for his assistance with this manuscript and Michael J. Stuart, MD, head of the Sports Medicine Center, Department of Orthopedic Surgery, Mayo Clinic, for his help during my recuperation. Special thanks to Peter Lohman, my physical therapist, for putting up with me during the tough times, and for his continued help and support on a regular basis, and to my wife, Jane, for her support and care during this difficult time.

### Bibliography

- Delee JC, Cravittto DF. Rupture of the quadriceps tendon after a central third patellar tendon anterior cruciate ligament reconstruction. *Am J Sports Med.* August 1991;19:4:415.
- Karlsson J, Lundin O, Wigerstad-Lossing I, Peterson L. Partial rupture of the patella. *Am J Sports Med.* August 1991;19:4:402.
- Rupture of the patellar tendon. *South Med J.* March 1988;81:3:376.
- Webb LX, Toby EB. Bilateral rupture of the patella tendon in an otherwise healthy male patient following minor trauma. *J Trauma.* November 1986;26;11:1045.
- Kelly DW, Carter VS, Jobe FW, Kerlan RK. Patellar and quadriceps tendon ruptures: Jumper's knee. *Am J Sports Med.* Sept-Oct 1984;12;5:375.