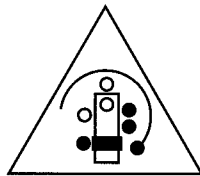
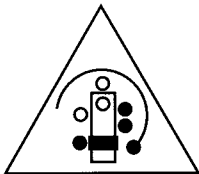

**Surgical Specialties
Collected Editions Series**

LARYNGOTRACHEAL SURGERY



**ASSOCIATION
OF SURGICAL
TECHNOLOGISTS**

*AEGER PRIMO -
THE PATIENT FIRST*



**ASSOCIATION
OF SURGICAL
TECHNOLOGISTS**

*AEGER PRIMO -
THE PATIENT FIRST*

Association of Surgical Technologists
7108-C S. Alton Way
Englewood, CO 80112-2106
303-694-9130

ISBN 0-926805-08-8

Copyright © 1995 by the Association of Surgical Technologists, Inc. All rights reserved. Printed in the United States of America. No part of this publication may be reproduced, stored in a retrieval system, or transmitted, in any form of by any means, electronic, mechanical, photocopying, recording, or otherwise, without the prior written permission of the publisher.

INTRODUCTION

Purpose

The purpose of this module is to provide the learner with information concerning specific surgical procedures performed on the larynx. The articles that follow originally appeared in *The Surgical Technologist* and have been reprinted in this series. Upon completing this module, the learner will receive 3 continuing education (CE) credits in category 3G.

Using the Module

1. Read the information provided, referring to the appropriate figures.
2. Complete the enclosed exam without referring back to the text. The questions are in a multiple-choice format and are taken directly from the corresponding article. Choose your answer based on the information presented in the article itself. Do not choose a response based on your personal experience, but instead select the best answer from the alternatives given.
3. Mail the completed exam answer sheet to AST, SSCE Series, 7108-C S. Alton Way, Englewood, CO 80112-2106. Please keep a copy of your answers before mailing the answer sheet.
4. Your exam will be graded, and you will be awarded CE credit upon achieving a minimum passing score of 70%. If you are an AST member, your credits will be recorded automatically and you do not need to submit the credits with your yearly CE reporting form.
5. You will be sent the correct answers to the exam. Compare your answers with the correct answers to evaluate your level of knowledge and determine what areas you need to review.

Laser Removal of Warts in the Throat

ARTICLE BY FRED CARLILE, CST



Although lasers have been used in head and neck surgery for more than 30 years, their use has not been a prominent form of treatment until the 1990s. With new instruments and improved techniques, lasers are now used more than ever before. Above all other types of lasers, the CO₂ laser has proven to be the most effective for use in the larynx. Laser treatments are not only used for warts in the throat, or laryngeal papillomas, but are very widespread in many other areas of head and neck surgery as well. They have proven themselves in the operating rooms of the 1990s and are sure to be around for many years to come.

Historical Perspective

As early as the 17th century, physicians were using the term, "warts in the throat," to describe benign tumors most often found in the larynx of children.¹ Since that time, many different treatments have been tried, several of which are still used today. Of these treatments, the CO₂ laser seems to be one of the best ways to control the spread of these warts, or papillomas, as they are known today.

Juvenile laryngeal papillomatosis was the term used for many years, and as recently as the 1960s, to describe benign tumors most often found in patients 15 years of age and under. These tumors are caused by the human papilloma virus (HPV). Two thirds of all patients affected are under the age of five. However, patients should be treated regardless of age, since no relationship has been

shown between puberty and a regression of the disease. Although these papillomas are most common in the larynx, they may also be found in the nasal mucosa and in the lung parenchyma and have been reported in the esophagus; however, they seldom invade submucosal tissue. The papillomas usually occur in multiple clusters spread over a wide area and may be localized as well.¹

Over time, many different treatments have been used for laryngeal papillomas. Some of the more common treatments have included injections of hormones and steroids, the use of ultrasound and radiotherapy, a vaccine made from the papillomas themselves, and tracheotomy. Radiotherapy is contraindicated since it may encourage malignancy, and tracheotomy should be avoided, as papillomas may grow at the tracheostoma. Some treatments still used today are removal by microsurgery, cryosurgery, electro-surgery, ultrasound, direct removal by laryngofissure, and naked-eye endoscopic removal.¹ Though these treatments are still in use today, removal of the papillomas by laser causes less trauma to the larynx and airway.

Anatomy of the Larynx

An examination of the anatomy of the larynx, sometimes called the voice box, shows it to be composed mostly of cartilage connected by ligaments. Its movement is controlled by numerous muscles. The larynx is located between the base or root of the tongue and the top of the trachea, with the thyroid gland located on either side. The lining consists of a mucous membrane

continuous with that of the trachea and pharynx. In adult males, the larynx is considerably larger than that of the female and may be seen moving when talking or swallowing; it is sometimes referred to as the "Adam's apple." The larynx of an adult male is approximately 45 mm in length compared with the larynx of a female, which is approximately 35 mm. In children, the size varies very little between the male and female until puberty.

The upper portion or vestibule of the larynx is triangular and slopes downward and backward. The epiglottis, ventricular fold (*false vocal cords*), and vocal fold (*true vocal cords*) are just part of its contents (Figure 1). The upper and lower portions are divided by the vocal folds. The lower portion is at first an elliptical form that widens and assumes a circular form at the bottom. This circular form connects with and is continuous with the trachea (Figure 2).²

Lasers in Treatment

The use of the laser in otolaryngology had its beginning in the 1960s with the use of argon laser therapy. Since then, the Nd:YAG, copper vapor, gold vapor, and other types have been tried, but the CO₂ laser has achieved the best results. Today it is the most common type of laser used for various otolaryngologic applications. After the laser's introduction, its use rapidly increased until it plateaued in the mid 1980s. By the late 1980s there was a sharp decrease in laser use, but since 1990 lasers have once again become popular. This is largely due to the many advances in the field of laser technology. For example, the first CO₂ laser

for the operating room was approximately the size of a telephone booth. While this laser did have an articulating arm, there was no way to direct the laser energy precisely through a laryngoscope. Advances in modern-day lasers include the development of the micromanipulator that attaches the articulating arm to the operating microscope, a drastic reduction in the size of lasers, and the availability of hand-held fibers and instruments. The existence of organizations that publish user guidelines and safety standards for laser use have also helped to increase the popularity of lasers.

Preoperative Considerations

Several things must be considered before beginning a laser laryngoscopy. Not only must the surgeon be familiar with the use of the laser and the procedure itself, but the anesthetist must be aware of the adverse effects that may appear unexpectedly and be prepared to deal with them if necessary.

Intraoperative Concerns and Safety Precautions

Many of the intraoperative concerns present with a traditional laryngoscopic procedure still exist in laryngoscopy with lasers. In addition to these concerns, the safe use of the laser is essential. Nitrous oxide should not be used for several reasons.³ First, it causes decreased cardiac output in patients with heart damage.¹ Second, and most important in laser use, nitrous oxide is as combustible as oxygen.

Another concern is the possibility of cardiac arrhythmias during laryngoscopy. These may occur from the pressure of the laryngoscope blade on the supraglottis thus stimulating deep laryngeal receptors. Arrhythmias must not be ignored, since they increase both intraoperative and postoperative myocardial infarction risks. Cardiac arrhythmias usually clear once the laryngoscope is removed. If the arrhythmias reappear upon reinsertion of the laryngoscope, the procedure should be terminated and rescheduled. When it is necessary to return a second time, 50 to 100 mg of lidocaine should be given intravenously after induction,

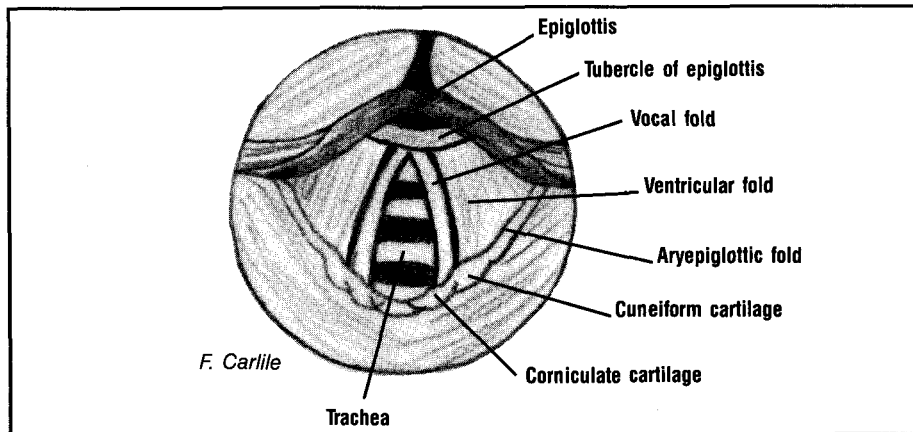


Figure 1. Laryngoscopic view of larynx.

or the superior laryngeal nerve should be blocked prior to the start of general anesthesia.

Laryngeal spasms are quite common upon removal of the laryngoscope and with the reversal of any muscle relaxant that has been used. The use of lidocaine on the vocal cords helps to prevent laryngospasms. Postoperative edema may also compromise the airway. Intravenous steroids may reduce edema but should be used only if excessive mucosa trauma has occurred.¹

The most dangerous risk is the

possibility of an endotracheal tube fire or explosion. To reduce this risk, a laser-safe tube must be used.¹⁴ There are currently many different tubes available that are approved for laser use. Some of these are manufactured with methylene blue in the cuff, while others are not. The cuff of a laser tube should be filled with normal saline, as opposed to air as are other tubes. If the tube does not have methylene blue in the cuff, the anesthesia personnel should plan to fill it with normal saline containing a dye. The dye will alert the surgeon

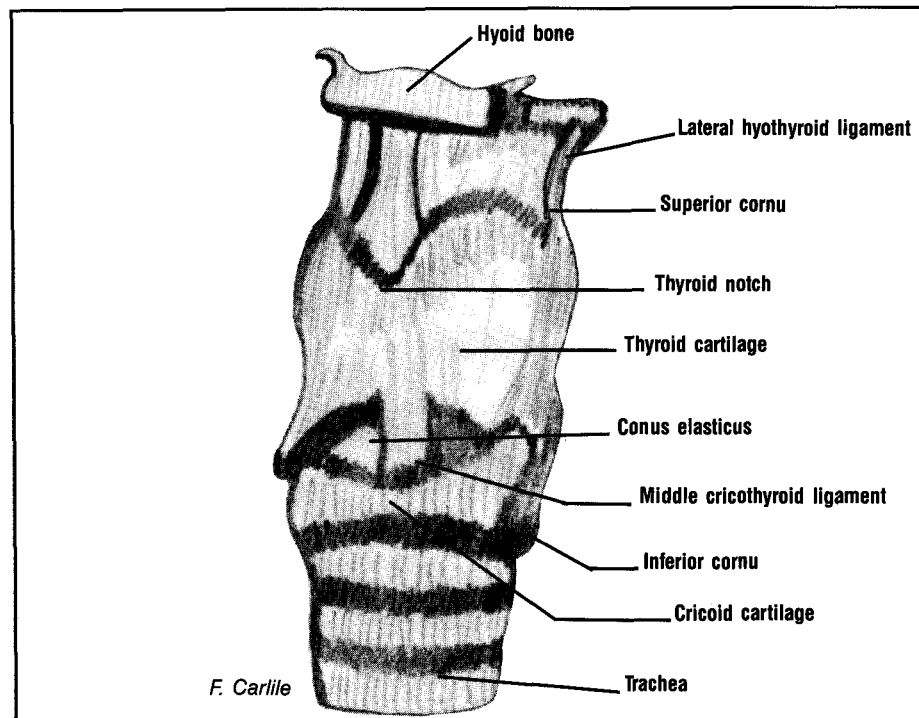


Figure 2. Ligaments of the larynx.

to a leak in the cuff should it be hit by the laser beam while the saline will absorb the laser energy and heat to help prevent injury. Anesthesia personnel may choose to use a jet technique or an apneic technique, which do not require a tube for patients who have a compromised airway; however, these techniques are not preferred in laser cases. Regardless of the technique chosen, combustible anesthetic gases must not be used for laser procedures. Again the use of nitrous oxide is discouraged since a mixture of nitrous oxide and oxygen can be ignited by CO₂ laser as readily as 100% oxygen. The preferred inhalation agents are halothane and forane.¹ When possible, a 24% solution O₂ mixture is preferred for delivery of these agents. This mixture can be achieved by using both O₂ and compressed air.

Laser safety is not only of concern to anesthesia personnel and the surgeon but is the responsibility of the entire operating room team as well. Each team member should be familiar with the laser equipment as well as knowledgeable of laser precautions. This is usually accomplished by attending a laser seminar or laser training course. The surgical technologist should visually check all ebonized finishes on instruments as well as the operation prior to the start of the procedure. Operating room staff must take all available precautions to prevent an accident or injury.

The first precaution that must be taken by operating room personnel

is to place a "laser in use" sign on the outside of all doors leading into the operating room suite.³ This sign should be clearly visible and should also state what type of laser is in use. The laser itself must be test fired before the patient enters the room, but only after each person in the room has donned protective eyewear and a mask designed specifically for laser use.³ To prevent burns to the patient and to the operating room personnel by reflected beams, all instruments selected must have either a nonglare or ebonized finish.³ The laryngoscope (a large-bore one is best) must also have a port for connection to the smoke evacuator and be approved for laser use. Only after all of the equipment is checked and found to be working properly is the patient taken into the operating room suite to begin the laser treatment.

Patient Preparation

Once in the operating room, the patient is placed on the operating table in the supine position and prepared for the surgical procedure. Following induction and establishment of the airway by the anesthesiologist, the patient is paralyzed to ensure complete immobility of the vocal cords. Paralysis is not always necessary in a standard laryngoscopy, but in a laser treatment, severe damage may be done to the cords if they move unexpectedly. The surgeon may place a mouth guard or tooth protector on the patient. This helps prevent damage to the patient's teeth and gums that may

otherwise be caused by the laryngoscope. The surgeon inserts a laser-safe laryngoscope and secures it in place with a suspension device. Moist cottonoid pledgets are placed around the cuff of the endotracheal tube for added protection from the laser beam. This is done using the microlaryngeal grasping forceps.

Once everything is in place, the laser arm is attached to the micromanipulator, which was previously placed on the microscope along with a 400-mm objective. At this time, wet eye pads are taped to the eyes and wet towels or drapes are used to cover the face and all exposed metal surfaces of the laryngoscope and suspension device to prevent burns to the patient.³ The laser is now ready to be turned on. The surgeon tells the laser operator the power settings he or she wishes to use and the laser operator keys the settings into the laser control panel. These settings are obtained based on certain laser principles involving the relationship of the watts of energy used and the area over which the energy is delivered. The pulse mode is usually preferred over the continuous mode to prevent heat damage within the larynx. A typical setting might be a spot size of 0.8 mm with 4 to 6 watts of power at 0.1 second.¹ With the settings entered, the laser is once again test fired on a wet tongue blade to ensure that the aiming beam and the laser beam are aligned and that the laser is working properly. It is important to note that, even at this point, if the laser misfires or gives the operator an error code, it must

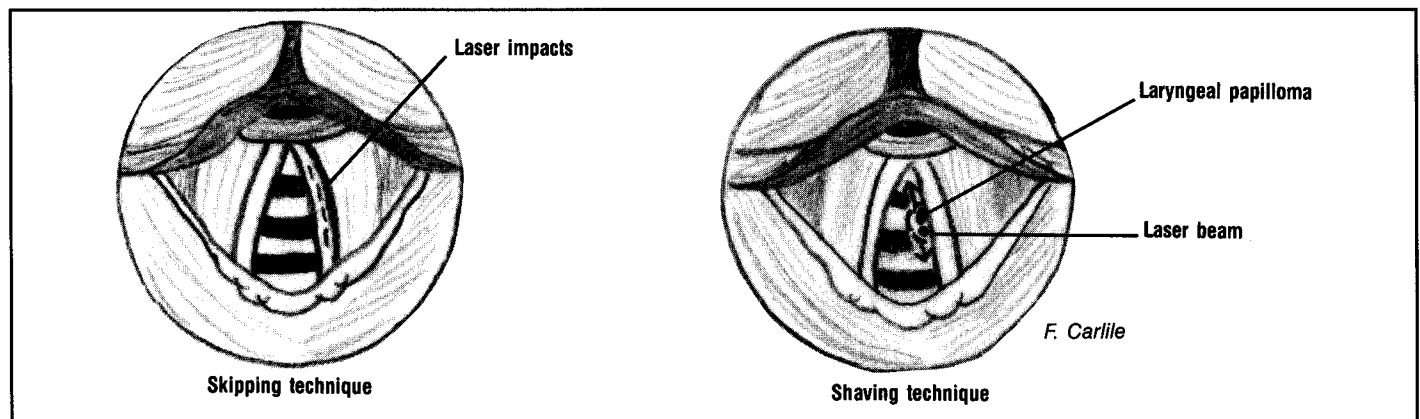


Figure 3. Techniques used in CO₂ laser laryngoscopy.

not be used in order to provide the patient with the safest possible treatment. As soon as all safety measures have been met, the surgeon proceeds with the laser treatment.

Operative Procedure

There are two methods that may be used in the larynx. The first is a skipping technique used to incise the squamous epithelium of the vocal cord. This technique produces a serrated cut and therefore lessens the chance of an uneven cutting depth by the laser beam. The second technique used in the larynx is shaving. Shaving is done with an operating platform, placed behind the lesion to protect the underlying tissue. By allowing half of the beam to impact the lesion and half of the beam to hit the platform, the lesion is shaved or vaporized a small amount with each firing of the laser beam (Figure 3).¹ Both techniques may require the use of some or all of the following: metal laser mirrors, forceps, operating platforms, suction tips, probes, and other instruments approved for laser use (Figure 4). Laser safety must remain in the forefront of everyone's mind throughout the procedure. With the proper use of all laser-associated equipment, the results will be both safe and effective.

Upon completion of the laryngoscopy, the wet towels or drapes are removed, and the articulating arm is removed from the microscope. Before removal of the laryngoscope, cottonoid pledgets are removed and counted as a sponge count.

Postoperative Care

After removal of the laryngoscope, the patient is awakened according to standard procedure and taken to the postanesthesia care unit. As in other procedures, the patient remains in postanesthesia care until he or she is stable and able to return to the floor. Most laryngoscopic procedures are done as a same-day surgery outpatient basis. However, patients must be observed for bleeding or edema, which could block the airway. This is the most common postoperative concern in any surgical procedure involving the airway.




Figure 4. Items needed to perform laser laryngoscopy. 1, Laser mask; 2, Protective eyewear; 3, 400-mm objective; 4, Micromanipulator; 5, Straight and 90° angled probe; 6, Fiber optic light cables; 7, Non-glare laryngoscope (pediatric and adult); 8, Suction tip; 9, Operating platform (4 & 6 mm); 10, Metal mirrors; 11, Straight, left, and right grasping forceps; 12, Suspension device; 13, Endotracheal tube; 14, Cottonoid pledgets.

Promising Results

The knowledge and safe use of the CO₂ laser have given many patients better results than any other procedure currently used. Although a prolonged remission (many years for some patients) has been reported, the disease may not be permanently eradicated. A reported 65% control rate for pediatric-onset patients and a 45% control rate for adult-onset patients may be achieved. However, the pediatric patient may require treatments much more frequently, possibly as often as every 3 to 6 months.¹ The treatment rate varies greatly from patient to patient.

Not only may papillomas be treated with better results, but accessory instruments for the laser have made it possible to treat lesions previously considered inoperable and still achieve a good result. These benefits, along with improved intraoperative bleeding control, less postoperative pain and edema, less chance of scarring and web formation postoperatively, and a greatly reduced chance of seeding, all work together to make the CO₂ laser beneficial as a means of treatment.¹

Otolaryngologists have reported positive results in the laser treatment of many other laryngeal diseases as well. These include capillary hemangiomas, the reduction of scar tissue, webs, other lesions involving the vocal cords and epiglottis, and the debulking of large malignant lesions to improve the patient's airway. Combining these with the hundreds of other possible uses in head and

neck surgery, the CO₂ laser, along with other laser types, is sure to remain one of the most promising treatments available to the otolaryngologists of today and tomorrow. Δ

Acknowledgements

The author would like to thank T. Lawrence, MD; C. Jordan, MD; B. Rayne, MD; HK Bralley, CRNA; and J. Wall for their assistance with this manuscript.

References

1. Dixon JA, Hunter JG, Parsons DS, Duncavage JA, Ossoff RH, Benjamin B. *Lasers in Otolaryngology - Head and Neck Surgery*. 1st ed. Philadelphia, Pa: WB Saunders Co. 1990; 1-43.
2. Goss CM. *Gray's Anatomy 100th Year*. 26th ed. Philadelphia, Pa: Lea & Febiger. 1963; 1176-1187.
3. Atkinson LJ. *Berry & Kohn's Operating Room Technique*. 7th ed. St Louis, Mo: Mosby-Year Book. 1992; 176-178.
4. Lore JM. *An Atlas of Head and Neck Surgery*. 3rd ed. Philadelphia, Pa: WB Saunders Co. 1988; 874-875.

Type I Thyroplasty for Voice Improvement

ARTICLE BY MARY KENNEDY, CST

S

ince the early 1900s, doctors have researched possible treatments to correct dysphonia (impairment of voice)

caused by unilateral vocal cord paralysis. In 1912, Brunings used paraffin to inject the vocal cord, which had successful results, but was not well received by other physicians, due to the formation of a paraffinoma. In 1915, Payr used a transverse U-shaped incision on the thyroid cartilage to make an anteriorly-based pedicle flap, which was depressed in an inward direction to displace the vocal cord medially. The effect was limited; in most patients, the flap did not survive. Therefore, most surgeons did not accept this procedure. Many other surgeons varied Payr's surgery, using different cartilage grafts and placing them usually between the thyroid cartilage and the inner perichondrium of the vocal cord. These procedures had varying degrees of success, but no one treatment was widely used. In the 1960s, Arnold popularized the use of polytetrafluoroethylene (PTFE) injected into the paralyzed vocal cord. PTFE injection was the treatment of choice until the development of type I thyroplasty in recent years.¹

In 1974, Isshiki developed a series of thyroplasties, which are surgeries to correct the vocal cords through an external approach by way of the thyroid cartilage.¹² There are four types of thyroplasties:

Type I: Medialization of the vocal cord.

Type II: Lateralization of the vocal cord.

Type III: Relaxation (shortening) of the vocal cord.

Type IV: Tensing (lengthening) of the vocal cord.¹

Type I thyroplasty has several distinct advantages over PTFE injection making it the treatment of choice for unilateral vocal cord paralysis since the mid-1980s.

Disadvantages of PTFE Approach

Although PTFE injection was successful in many patients, it has

Type I thyroplasty is indicated for patients with dysphonia caused by unilateral vocal cord paralysis, vocal cord atrophy, or vocal cord sulcus.

many disadvantages and limitations. PTFE is not highly predictable when injected; in some cases, it spreads uniformly while in other cases it may not spread at all. PTFE can not be removed easily without significant damage to the vocal cord, which may result in airway obstruction. Macrophages may engulf the PTFE within the cord, producing a hard granuloma. Once injected, the position and quantity of the PTFE is difficult to revise or reverse. In addition, the PTFE has migrated in many patients. PTFE injection is usually performed on an awake patient, often making it difficult to position the rigid laryngo-

scope and lewey arm without causing patient discomfort. In these circumstances, the inadequate surgical exposure is a contraindication for PTFE injection. If there is a possibility that the motor function will return to the vocal cord, PTFE injection is not indicated as part of the therapy. PTFE injection will partially medialize the vocal cord, but will never provide complete relief from the aspiration common in patients with vocal cord paralysis. Type I thyroplasty overcomes these issues with better patient outcomes in most cases.

Type I Thyroplasty

Type I thyroplasty medially displaces the paralyzed vocal cord by depressing a rectangle of thyroid cartilage and creating a window, which is secured by a piece of autologous cartilage or by a polymeric silicone wedge or block. By adjusting the thickness and position of the block, vocal cord position can be fine-tuned intraoperatively by having the patient speak while the surgeon watches the movement of the vocal cord with a flexible laryngoscope.

Preoperative Considerations

Type I thyroplasty is indicated for patients with dysphonia caused by unilateral vocal cord paralysis, vocal cord atrophy, or vocal cord sulcus (groove). Patients undergo many preoperative tests to determine if type I thyroplasty is indicated. The manual compression test is important in determining if the surgery will be successful. This test is done by placing fingers on the affected side, pushing the thyroid ala medi-

ally, and having the patient speak. If the patient's voice sound has improved, type I thyroplasty is usually successful. During the preoperative evaluation, the patient's voice is recorded and his or her vocal cord movement is videotaped with a flexible laryngoscope. This test determines if the cord moves at all and the size of the opening between the cords. Some doctors may also use computed tomography, but this evaluation is optional.

The surgeon must consider the duration and cause of paralysis in determining whether there may be a return of function. If a nerve has been cut, the surgeon will also need to ascertain at what level the neural interruption occurred. During thoracic surgery, the vagus nerve may be cut, whereas during neck surgery, the recurrent laryngeal nerve or the vagus nerve may be cut. By looking at the videotape of the vocal cords, the surgeon can determine the position of the vocal cord and whether there is any atrophy of the affected cord, which helps determine the size and shape of the implant. The normal vocal cord position and function is also documented to help determine the placement of the implant. Patients with a large larynx and large gaps between their vocal cords to be closed may have results as good as those patients with a small larynx and small gaps.³ If the patient has had previous radiation therapy to the area or has had neck surgery, trauma, or high vagal lesions, the chance of returning the voice to normal is diminished.

Finally, and most importantly, the patient's wishes are considered. All patients receive a complete head, neck, and chest examination. Patients who undergo type I thyroplasty are often asked not to be intubated for elective cases within 3 months postoperatively. Therefore, a patient may be asked to have the elective surgery done before type I thyroplasty if the surgery can not wait 3 months or if the patient desires to have the elective surgery done before the thyroplasty. The 3 months allows for better results in the healing process of the vocal cord. The patient will also undergo the

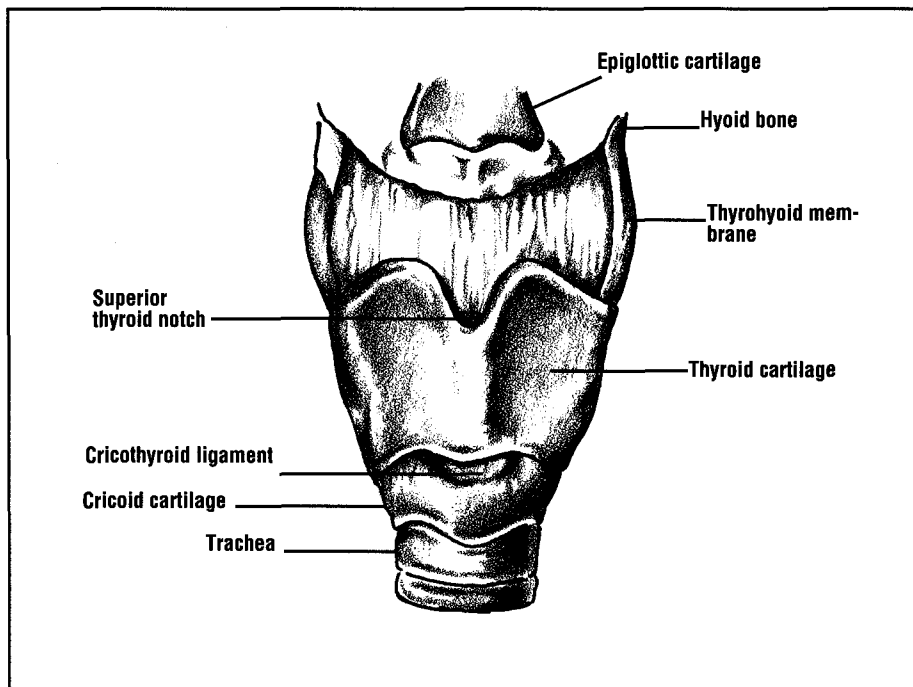


Figure 1. Anterior view of the larynx.

standard preoperative tests required by the hospital and anesthesia department for a local intravenous sedation case.

Patient Preparation

The patient is placed on the operat-

ing table in a supine position with the neck extended, usually with a shoulder roll placed behind the neck. If the flexible laryngoscope is used, topical nasal anesthetic will be used. Intraoperative video laryngoscopy is not necessary for

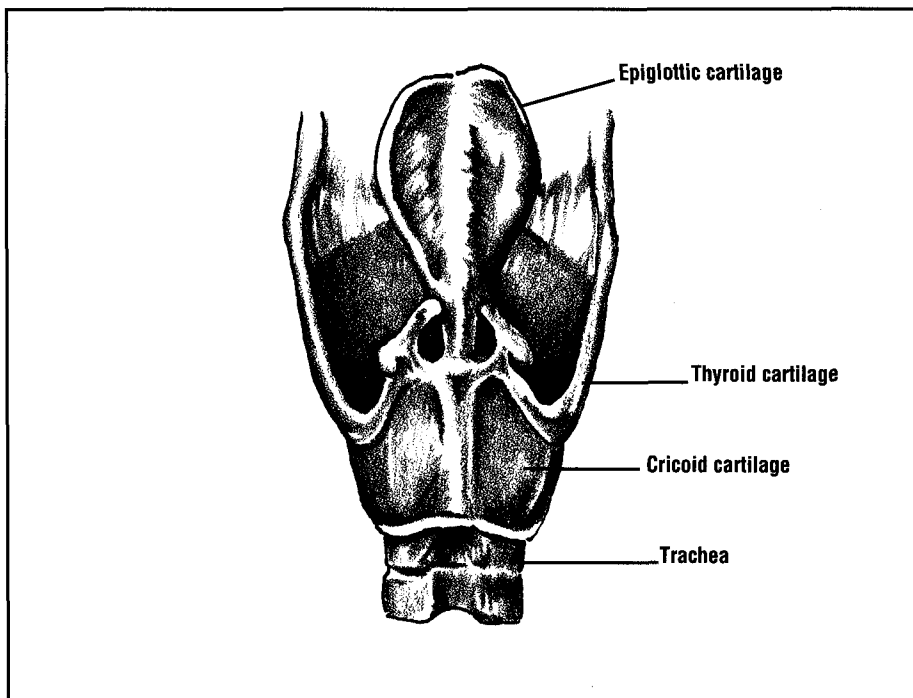


Figure 2. Posterior view of the larynx.

the success of the procedure, but most surgeons choose to use it.⁴ Lidocaine with epinephrine is usually used for local injection. The patient is mildly sedated so that he or she is alert enough to speak.

Operative Procedure

A small incision is made over the thyroid cartilage and the strap muscles are dissected and retracted

The surgeon must consider the duration and cause of paralysis in determining whether there may be a return of function.

away. The thyroid notch and lower margin of the thyroid cartilage are identified and the midpoint is marked as the supposed location of the anterior commissure (Figures 1, 2, and 3). A line is drawn horizontally to indicate the upper surface of the vocal cord. The vocal cord line is the upper line of the rectangular window made in the thyroid carti-

lage. The anterior vertical line should be 5 to 7 mm from the median line of the thyroid cartilage. The window should be 4 to 6 mm high and 8 to 14 mm wide; the larger the thyroid ala, the larger the window used (Figure 4). The average windows are 6 x 12 mm for men and 4 x 10 mm for women. If the cartilage is not calcified or too hard, a knife may be used to create the window. If there is calcification present, a small cutting or diamond burr on an ototome may be used. If the window is too high, there will be bulging of the false cord. If there is too much extension of the window, the cricoid cartilage will block medial displacement.

After opening the window, the flexible laryngoscope is inserted through the patient's nose. An ear periosteal elevator is used to dissect the mucosa from the cartilage. The elevator is also used to probe through the window to determine vocal cord changes to better position the implant. Many shapes of implants are used, but the most common are the wedge and the T-shaped block. The implant must have a projection that fits in the window for better stabilization. The block is placed as the patient phonates to achieve the maximum

effect. For better precision, the inner perichondrium should be sufficiently elevated from the cartilage around the window.¹ Once a better voice is attained and improved closing of the vocal cords occurs, the block may be sutured to the thyroid cartilage for greater stabilization. At that time the neck incision is closed and dressed appropriately with antibiotic ointment and sterile tape strips.

Complications

Among the possible complications of type I thyroplasty is the perforation of the vocal cord. If a perforation occurs, antibiotics are recommended for 48 to 72 hours. Perforation creates a greater chance of infection with extrusion of the implant. However, infection may still occur without perforation. Two rare complications are airway obstruction and laryngocutaneous fistula. Laryngocutaneous fistula normally occurs if the perichondrium over the thyroid cartilage is not closed properly, but may also occur with an infection. The most common complication is undercorrection.

There are several options for a patient with poor results. A larger implant could be placed, a different shaped implant may be indicated, the contralateral vocal cord can be implanted, anterior laryngoplasty or laryngopexy can be performed, or PTFE or collagen injection may be indicated.³ Many patients receive ranitidine (a histamine inhibitor that reduces acid secretion) for 2 weeks postoperatively to prevent reflux, which may cause poor results. Most complications usually occur at 1 week postoperatively and are almost always revealed by the first month postoperatively. The patient's voice is checked 1 day, 1 week, 1 month, and 3 months postoperatively. Some surgeons may prefer to have the voice checked at 6 months and 1 year postoperatively as well. While the patient is not placed on voice rest, voice conservation and vocal hygiene are essential. Studies have shown that it takes 1 month for the implant to fibrose within the vocal cord; therefore, the patient is excluded from heavy lift-

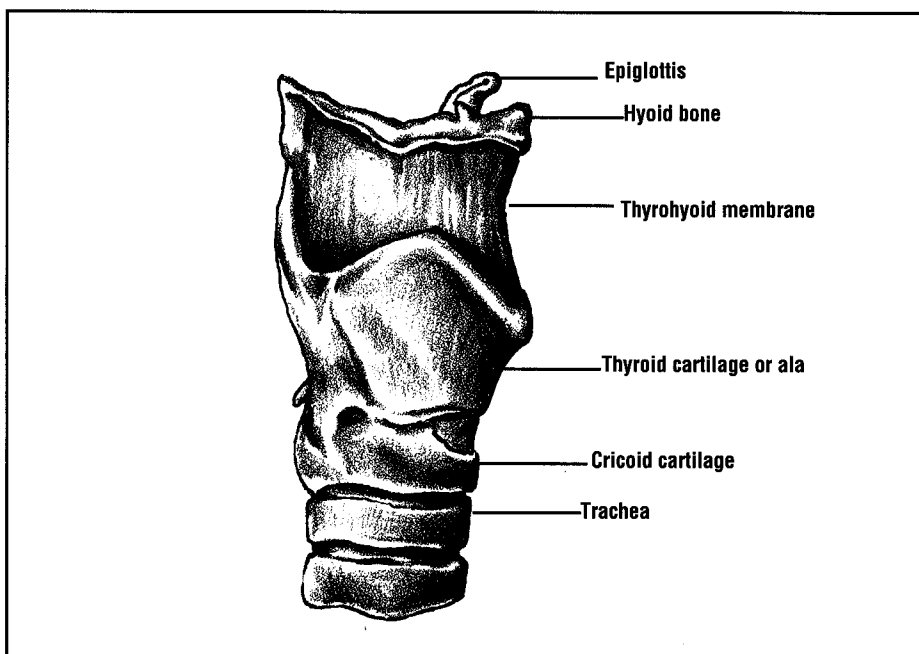


Figure 3. Side view of the larynx.

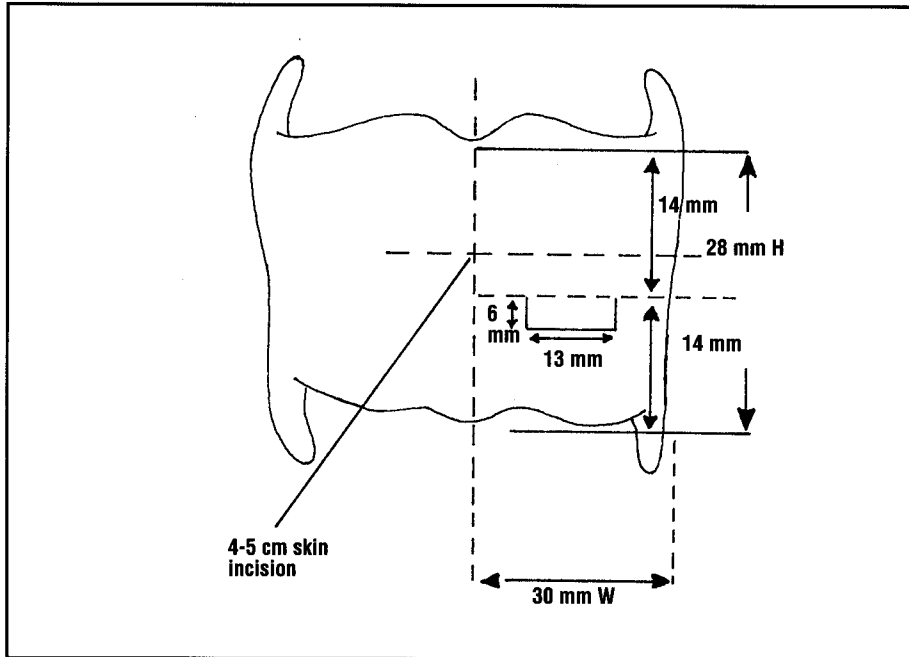


Figure 4. Placement of skin incision as compared to the calculation of the window on the thyroid cartilage.³

ing, yelling, aerobics, trumpet playing, singing, or anything that could strain the vocal cords excessively for that month.

There has been no evidence of granuloma formation in any patient receiving type I thyroplasty thus far. The major disadvantage of type I thyroplasty is the neck incision.

Advantages of Type I Thyroplasty
The most important advantage of type I thyroplasty is its reversibility, which is dependent on the configuration and position of the implant, the occurrence of infection, and the extent of fibrosis around the implant.³ This procedure can be used in the treatment of longstanding vocal cord paralysis due to atrophy or can fill in defects in a mobile cord. Another distinct advantage is that the surgeon can adjust the degree of lateral compression in accordance with the patient's vocalization intraoperatively.³ The patient can better tolerate the procedure under local anesthesia as only a flexible laryngoscope is used.

Conclusion

Studies have shown that type I thyroplasty successfully normalizes voice quality impaired by unilateral

vocal cord paralysis. Postoperatively, breathlessness and hoarseness are decreased due to better approximation of the vocal cords. Patients continue to have long-term improvement. Due to the relative success of type I thyroplasty, surgeons have started to do primary

Type I thyroplasty successfully normalizes voice quality impaired by unilateral vocal cord paralysis.

thyroplasty after nerves have been cut in skull base, neck, or chest surgery without hearing the postoperative voice changes, if any. Type I thyroplasty is beginning to be used for patients with abductor spasmodic dysphonia, bowed vocal cord, and unilateral cordectomy. Due to its reversibility, there are a variety of areas in which type I thyroplasty may be indicated in the future. Δ

Acknowledgements

The author would like to thank Kate Hetzel, RN, for her illustrations;

P.D. Spies, RN, for her guidance and proofreading; Mike Crary, PhD, for his guidance and reference materials; and Nicholas Cassisi, MD, for his guidance.

References

1. Isshiki N. *Phonosurgery: Theory and Practice*. Tokyo, Japan: Springer-Verlag; 1989.
2. Isshiki N, et al. Thyroplasty as a new phonosurgical technique. *Acta Otolaryngologica*. 1974; 78:451-57.
3. Koufmann JA. Laryngoplastic phonosurgery. In: Johnson JT, ed. *Instructional Courses*. American Academy of Otolaryngology: Head and Neck Surgery. St Louis, Mo: CV Mosby; 1988:339-350.
4. Netterville JL, et al. Silastic medialization and arytenoid adduction: The Vanderbilt experience. *Ann Otol, Rhinol, Laryngol*. 1993; 102:413-424.

Additional Sources

- Issacson G, et al. Histology of Isshiki thyroplasty type I. *Ann Otol, Rhinol, Laryngol*. 1990; 99:42-45.
- Maves MD, McCabe BF, Gray S. Phonosurgery: Indications and pitfalls. *Ann Otol, Rhinol, Laryngol*. 1989; 98:577-580.

Laryngotracheal Reconstruction with Rib Graft

ARTICLE BY JANET K. REISSER, CST

Laryngotracheal reconstruction is indicated for severe subglottic stenosis in infants with a tracheostomy. Infants requiring this type of surgery have typically been intubated during the neonatal period secondary to respiratory distress syndrome. Multiple or prolonged intubations often necessitate tracheostomy. Upper airway obstruction may present secondary to prolonged intubation or multiple intubations. Immediate treatment for this upper airway obstruction is attempted reintubation or tracheostomy. These infants may need to have a tracheostomy for years. Long-term corrective measures include progressive dilatation of the airway or reconstructive surgery. Usually reconstructive surgery is delayed until the infant's respiratory condition can tolerate decannulation (removal of tracheostomy tube).

The occurrence of laryngotracheal stenosis has increased since the 1960s with the use of prolonged intubation in infants. This method of ventilatory support remains accepted as treatment for premature infants.¹ However, this technique can lead to laryngotracheal injury, especially subglottic or tracheal stenosis.² In 1974, Fearson and Cotton promoted the use of an autogenous cartilage graft to the larynx in order to create a safe, stable airway in the shortest time possible with the fewest complications.³

Anatomic Overview

To understand laryngotracheal

reconstruction, a review of the anatomy of the larynx, trachea, and costal cartilages is necessary. The larynx, located in the front and middle of the neck, extends from the base of the tongue to the trachea.⁴ Lined with mucous membranes, the larynx is a musculocartilaginous structure that acts primarily as a sphincter guarding the entrance to the trachea and functions secondarily as the organ of voice. It is composed of nine cartilages: thyroid, cricoid, epiglottis, two arytenoid, two corniculate, and two cuneiform cartilages, all of which are connected by ligaments.⁵

Upper airway obstruction may present secondary to prolonged intubation or multiple intubations.

The trachea, beginning at the lower end of the larynx, branches into the right and left main bronchi. It is composed of transverse horseshoe-shaped cartilages in a fibro-elastic wall.⁵ Costal cartilages are flat structures of hyaline cartilage. They extend from the anterior end of the ribs and contribute to chest mobility and elasticity.⁶

Preoperative Considerations

To determine the extent of the subglottic stenosis, the surgeon will perform a laryngoscopy and bronchoscopy. If a tracheostomy is not already in place, the surgical technologist should have a varying selection of endotracheal and tra-

cheostomy tubes available in case a tracheostomy is needed. The pediatric endoscopic cart is brought into the operating room with several sizes of laryngoscopes and bronchoscopes. The surgeon will select the sizes of the individual pieces of equipment that he or she will use. The light source and suction should be checked by the surgical technologist prior to use. The surgeon may require a flexible laryngoscope to visualize the movement of the infant's vocal cords. The endoscopy can be performed as a separate procedure; however, it will also be repeated immediately prior to the laryngotracheal reconstruction. Following the procedure, the endoscopic equipment should be cleaned according to manufacturer's recommendations and hospital policy.

Operating Room Setup and Patient Preparation

Prior to the start of the laryngotracheal reconstruction, the operating room temperature must be elevated in order to maintain the infant's temperature. In addition, a warming pad and/or heat lamps may be required. The room must have available suction and cautery. The infant is brought into the operating

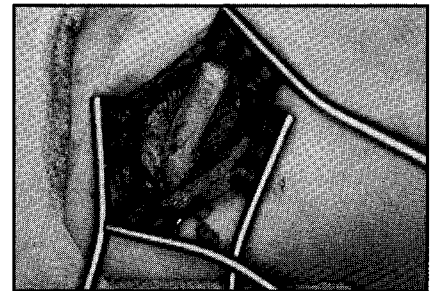


Figure 1. Harvesting rib graft.

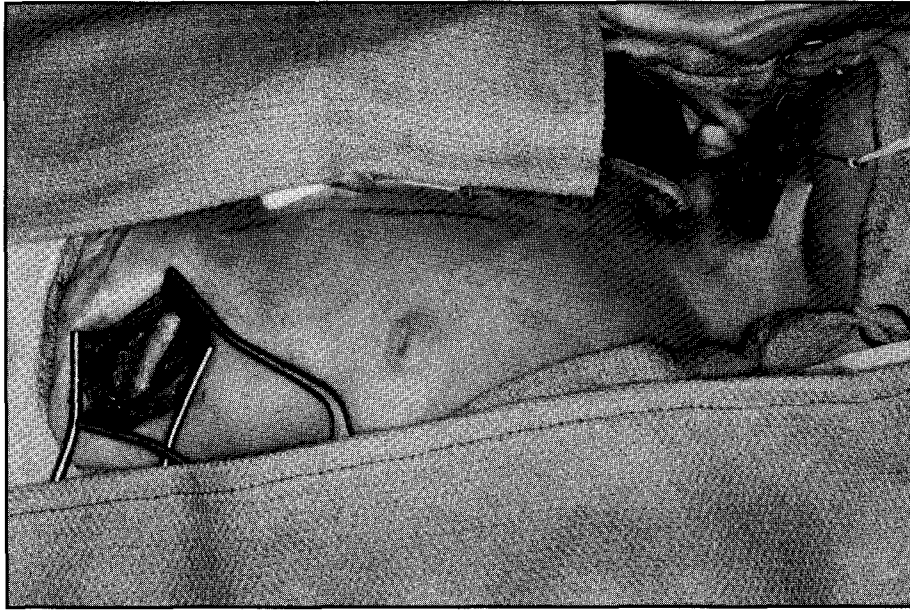


Figure 2. Surgical field with rib graft and larynx exposed.

room and routine monitoring is performed by anesthesia. After general anesthesia is induced, the infant is positioned with the neck extended and the trachea exposed. A foam donut and shoulder roll may be used to achieve enhanced visualization. A 0.5% lidocaine with epinephrine 1:200,000 will be injected horizontally to the proposed incision site immediately above the tracheostomy stoma. Sterile drapes (Steri-drapes) are used to cover the anesthesia circuit and outline the operative field. The anterior neck and mid-chest are surgically prepped and draped. The surgical technologist should be prepared for a laryngoscopy in case the surgeon needs to ensure the precise location and extent of the stenosis prior to the surgical incision. The following surgical equipment should be available:

1. Pediatric minor instruments
2. No. 15 blade
3. 3 x 3 sponges
4. Crile retractors
5. Bipolar and pencil cautery
6. Marking pen
7. Pediatric Doyen costal elevators (right and left blades)
8. Small rib cutter
9. Heavy curved Mayo scissors

10. Freer double-ended elevator
11. 6700 Beaver blade and handle
12. 1/2 inch cottonoids
13. Rubber band drains
14. Steri-drape (2-1000)
15. Small transparent adhesive film (Op-site)
16. Split sheet and towels
17. 1/2 inch sterile tape strips (Steri-strips)
18. Double-ended costal periosteotome
19. Surgical prep (iodophor)
20. Surgeon's headlight and light source
21. Foam donut and/or shoulder roll

Operative Procedure

The surgeon makes the initial incision into the right chest in order to

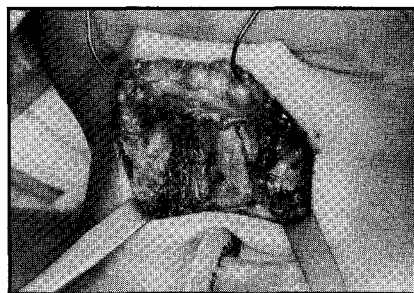


Figure 3. Laryngeal exposure.

obtain a 4-cm length of costal cartilage (Figure 1). The cartilage is wrapped in saline soaked gauze until needed. A small amount of saline is placed in the chest wound to ensure that the parietal pleura is intact and no pneumothorax exists. When the surgeon is certain that the chest cavity has not been entered, the wound is closed with 4-0 chromic and 3-0 nylon sutures. At this time, sterile tape strips are applied and the chest site is covered with a towel.

For the actual reconstruction, the surgeon makes a horizontal incision superior to the stoma (Figure 2). The underlying neck muscles are separated in the midline to expose the larynx and trachea (Figure 3). In addition, the cricoid cartilage must be split in the middle anteriorly and occasionally posteriorly with a 6700 Beaver blade (Figure 4). Careful inspection of the larynx and trachea must be done to determine the

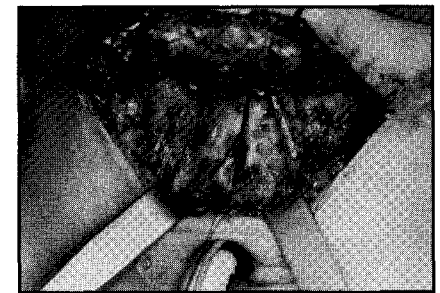


Figure 4. Stenosis divided.

extent of the stenosis. If necessary, the initial neck incision may be lengthened at this time. After the inspection, these structures are divided precisely in the midline. A cottonoid sponge with long-acting nasal spray solution may be used in the lumen for vasoconstriction purposes. Another cottonoid may be used in the tracheal lumen, around the endotracheal tube, to prevent escape of anesthetic gases and aspiration of blood and secretions into the lower airway. The surgeon trims the costal cartilage graft to match the needed expansion using a No. 15 blade and scalpel. The perichondrium side of the graft is placed toward the lumen (Figure 5). Choices of suture include 5-0 polyglyconate (Maxon) or polybutester

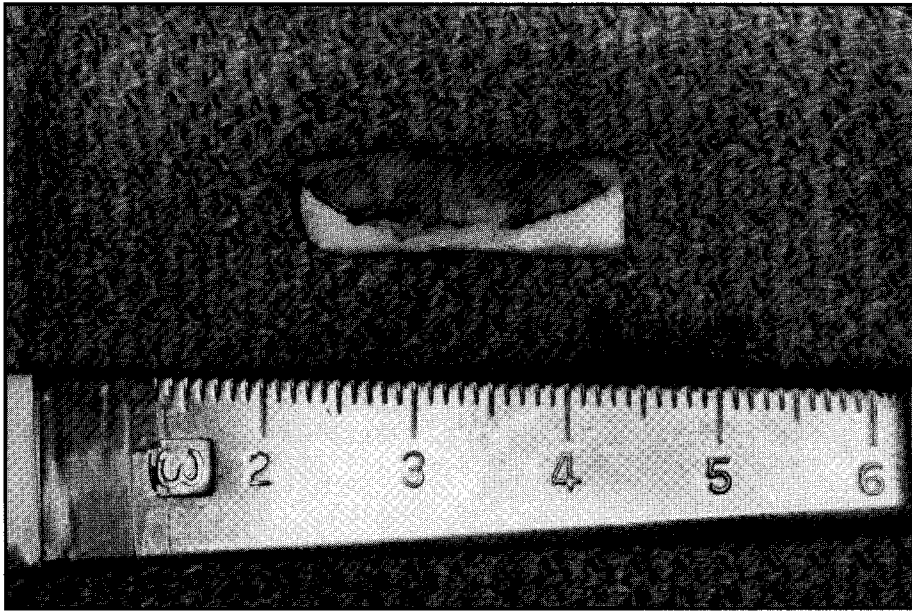


Figure 5. Shaped rib graft.

(Novafil).⁷ The sutures are tagged with rubber-shod hemostats prior to locating the graft into position (Figure 6). The graft is positioned in the laryngotomy and the sutures are secured (Figure 7). The neck incision is then closed with 4-0 chromic. A rubber band is secured for a drain, after which the skin is closed with 5-0 plain. No dressing is necessary.

The chest is inspected and dressed with a small gauze sponge and transparent adhesive film. A tracheostomy tube is positioned over the stoma. Upon decision of the anesthesia team, the endotracheal tube is replaced with the tracheostomy tube.

Postoperative Care and Complications

The infant is transported to the postanesthesia care unit (PACU) with oxygen. The infant's length of

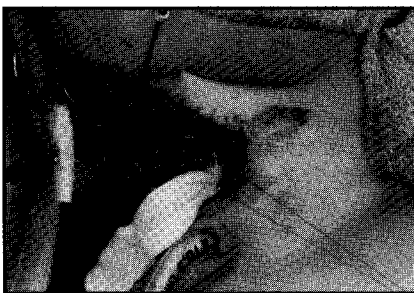

Figure 6. Rib graft with sutures in place.

stay in the intensive care unit is approximately 2 to 7 days. The patient may then be moved to the general floor for 4 days. The patient is released home with weekly office follow up visits.

More extensive surgery must be performed if stenosis is present anteriorly and posteriorly. In these

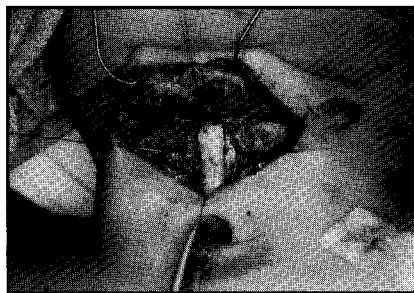


Figure 7. Rib graft positioned and secured in laryngotomy.

cases, a stent is needed. Other possible complications include postoperative infections, aspiration, puncture of the pleural cavity, and occlusion of the tracheostomy tube. With home care, parents are instructed to meticulously suction and clean the inner cannula, to use humidification regularly, and to maintain the infant's hydration. Occasionally, an altered diet may be indicated if aspiration is a persistent problem. The need for speech therapy should be evaluated according to the infant's age and mental develop-

ment.⁸

Laryngotracheal stenosis may be a surgical challenge for the surgical technologist due to the potential airway complications and the infrequency of the procedure. However, the procedure offers the promise of an improved lifestyle and health for patients and their families. Δ

Acknowledgements

The author wishes to acknowledge Lewis R. Hutchinson, MD, staff physician at Scott & White Department of Otolaryngology and professor at Texas A & M University Health Science Center College of Medicine, for his technical assistance in writing this article. The author graciously thanks her colleague Athena Stinson, RN, CNOR, for her kind advice and continual encouragement.

References

1. McDonald IH, Stocks J. Prolonged Nasotracheal Intubation. *Br J Anaesth.* 1965;37:161-167.
2. Wiatrak BJ, Cotton RT. Anastomosis of the Cervical Trachea in Children. *Arch Otolaryngol Head Neck Surg.* 1992;118:58-62.
3. Fearson B, Cotton RT. Surgical Correction of Subglottic Stenosis of the Larynx in Infants and Children: Progress Report. *Ann Otol Rhinol Laryngol.* 1974;83:428-431.
4. Benton HH. *The Transvision Book of Health.* Chicago, Ill: Encyclopedia Britannica, Inc.; 1974:63-65.
5. *Dorland's Illustrated Medical Dictionary.* 27th ed. Philadelphia, Pa: W. B. Saunders Co.; 1988:898,1738.
6. Williams PL, Warwick R, Dyson M, Bannister LH. *Gray's Anatomy.* 37th ed. Edinburgh, England: Churchill Livingstone; 1989:335.
7. Raffensperger JG. *Swenson Pediatric Surgery.* Norwalk, Conn: Appleton Lange Publishers; 1990:678-680.
8. Healy GB. *Common Problems in Pediatric Otolaryngology.* Chicago, Ill: Yearbook Medical Publishers, Inc.; 1990:415-421.