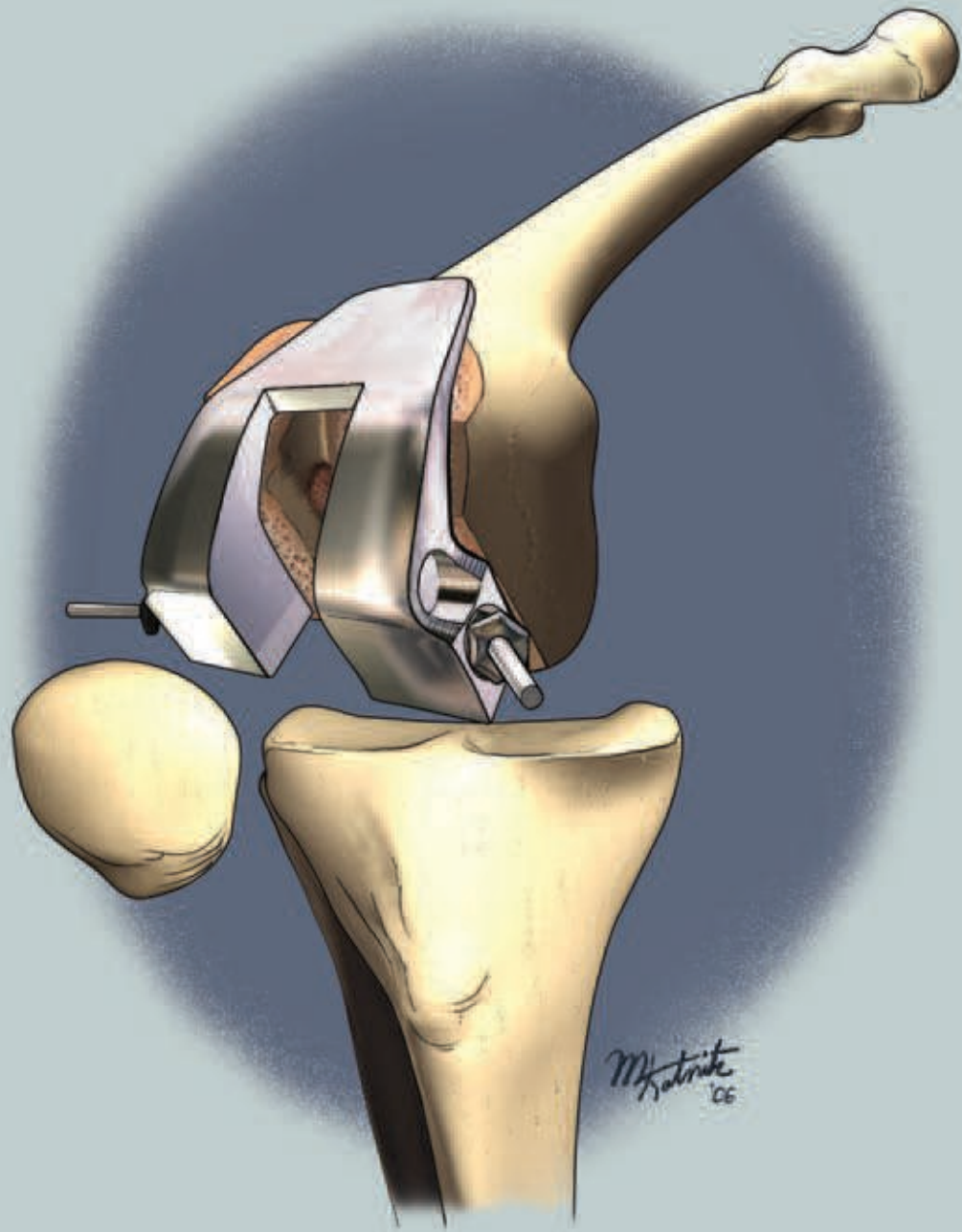

Total Knee Arthroplasty

Jeffrey Bidwell, CST, CSA, MA

Introduction

The purpose of this article is to present a brief overview of the various aspects of a total knee arthroplasty. For surgical technology students and CSTs with limited orthopedic experience, this article provides an insight into the complexity of the procedure from the surgeon's perspective.

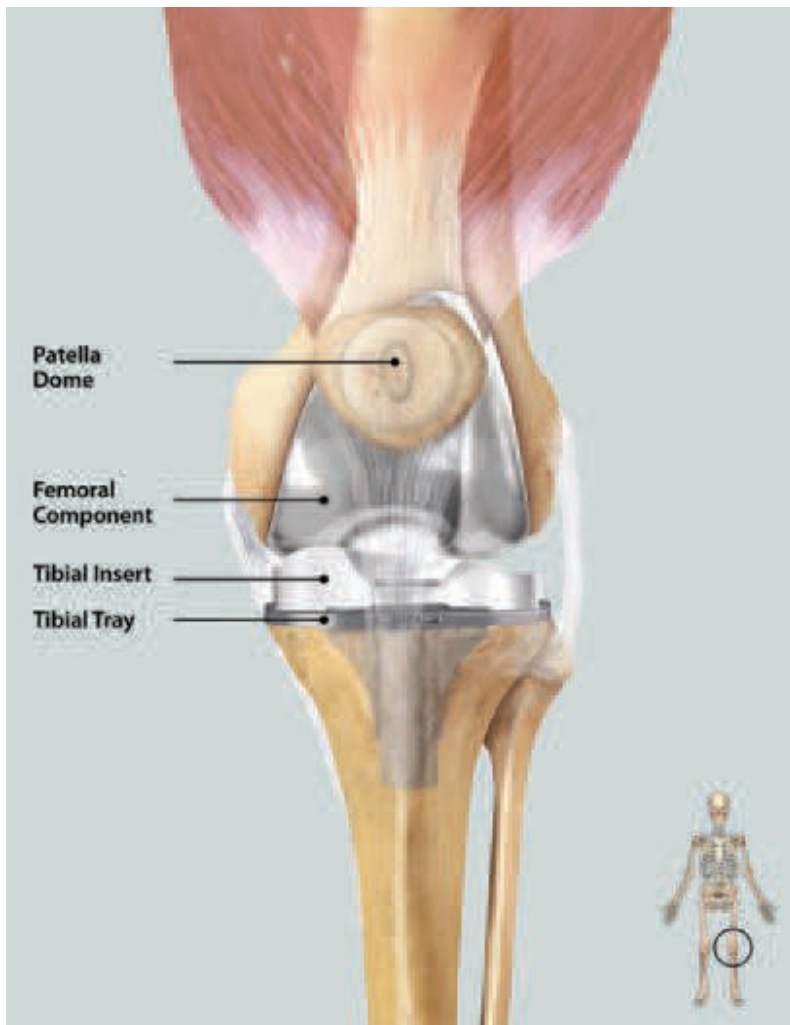
Arthroplasty is an operation to restore motion to a joint and function to the muscles, ligaments and other soft tissue structures that control the joint.² Total knee arthroplasty is indicated for patients who demonstrate radiographic intra-articular disease and severe knee pain or other symptoms that cannot be controlled with non-operative methods. For individuals with mild pain, over-the-counter medications such as acetaminophen (eg, Tylenol®) and topical pain relievers (eg, Aspercreme®, Icy Hot®) might be sufficient to provide relief. Nonsteroidal anti-inflammatory drugs (NSAIDs), such as ibuprofen, are used to relieve pain and inflammation, but

are known to have side effects. More moderate pain is treated with stronger NSAIDs and COX-2 inhibitors. Cortisone injections are also given to the joint to relieve inflammation, but this type of relief is usually only short-term.

When pain, limping, and joint dysfunction become so severe that none of these treatments provide adequate relief, surgery may be the next option. There are several surgical alternatives to knee replacement, such as arthroscopy, osteotomy, and synovectomy. These may be able to delay the necessity of a replacement, but when pain reaches the point that it becomes controlling, a knee replacement is usually recommended.¹¹

History

Early arthroplasty techniques initially utilized the patient's own tissues (skin, muscle, fascia) in the joint, which improved ankylosed joints but did little to help arthritic joints. Surgeons also experimented with glass, Bakelite and cellulose



Courtesy: Wright Medical Technology, Inc.

FIGURE 1:
Artificial knee

as interpositional material, but they also produced poor results for the arthritic knee.²

Modern approaches to today's total joints began in the 1960s when Sir John Charnley designed a stainless steel femoral head to articulate with a polyethylene acetabular implant. Both were secured by polymethylmethacrylate to the surrounding bone. Guston developed a similar system for the knee following Charnley's design. Other applications including arthroplasty of the elbow, ankle and wrist were attempted, but poor results have limited their use. However, arthroplasties of the knee and hip continue to improve and increase based on Charnley's design of metal on polyethylene and improved technology (Figure 1). In most cases, stainless steel implants have been replaced with stronger metals, such as cobalt and titanium, but research has yet to find a better alternative for polyethylene.²

Total knee implants

Knee implants can be divided into three different categories, based on the section of the knee to be replaced: unicompartmental, bicompartmental and tricompartmental. Unicompartmental implants are used to replace either the medial or lateral side of the corresponding articular surface of the femur and tibia. Bicompartmental implants replace medial and lateral surfaces of the femur and tibia. Tricompartmental implants replace the medial and lateral surfaces of the femur and tibia, plus the patella.

Tricompartmental implants are further subdivided into categories, depending on the stability of the patient's knee. Unconstrained implants require minimal resurfacing of the tibia and femur, and good collateral and posterior cruciate ligaments. Semiconstrained implants are used when there is a problem with ligament balancing. Fully constrained implants, which are joined together by hinges and only allow motion in a sagittal plane, are used when there is a severe deformity with the ligaments, or during revisions.²

Basic biomechanics

Motion occurs during the normal movement (gait cycle) of the knee in three planes: flexion and extension, abduction and adduction, and rotation.

Longitudinal and rotational alignment

Studies have demonstrated a direct correlation between long-term success of a total knee procedure to the restoration of normal limb alignment. Malalignment of the prostheses can lead to long-term problems such as: patellofemoral and femorotibial instability, accelerated polyethylene wear and implant loosening. The mechanical axis line should project through the center of the knee joint. During a normal gait, the mechanical axis is inclined three degrees from the vertical axis. If the mechanical axis is nearer to the lateral side of the knee center, the knee is in valgus alignment. In varus alignment, the opposite is true. Valgus or varus deformity can be determined by an anteroposterior roentgenogram.²

Patellofemoral joint

The patella increases the lever-arm action of the extensor mechanism of the knee. The quadriceps and patellar tendons insert on the patella anteriorly. In this way, the patella lengthens the extensor lever by displacing the forces of the quadriceps and patella tendons away from the center of rotation. The length of the extensor lever arm varies during knee flexion.⁴ The Q-angle, as described by Hvid, is the angle between the extended anatomical axis of the femur and the line between the center of the patella and the tibial tubercle. The quadriceps acts primarily in line with the anatomical axis of the femur, with the exception of the vastus medialis obliquus, which acts to medialize the patella in terminal extension. In other words the Q-angle at the top of the thigh is shaped like the letter V. It starts at the anterosuperior iliac spine, continues to the middle of the femur, and it then follows a straight line down the center of the patella to the tibial tuberosity. If the tibial component is internally rotated, it will increase the Q-angle and lead to lateral subluxation of the patella. Tibial components should be centered on the medial border of the tibial tubercle, slight external rotation. Similarly, internal rotation of the femoral component can increase lateral patellar subluxation.² A lateral retinacular release can help correct lateral patellar subluxation. This is performed by cutting the synovium and retinaculum longitudinally to the muscle fibers of the vastus lateralis. If a full release is performed, the superior lateral geniculate artery should be identified to avoid possible devascularization of the patella.²

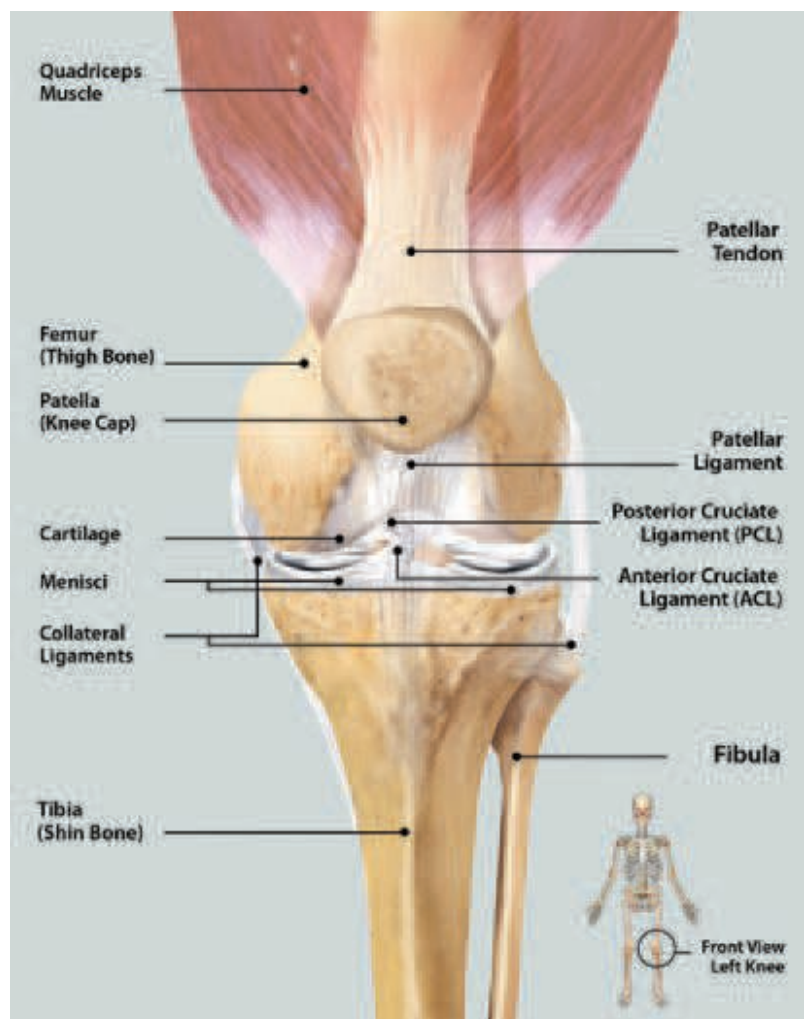
Anatomy

The knee joint is formed by the tibiofemoral and patellofemoral articulations. There is not a single unified capsule in the knee (Figure 2). The cruciate and collateral ligaments are the two main sets of ligaments for the knee joint. The cruciates are located within the joint capsule “intra-capsular ligaments.” The anterior cruciate ligament (ACL) attaches to the anterior surface of the tibia in the intercondylar area, just medial to the medial meniscus. The posterior cruciate liga-

ment (PCL) attaches to the posterior tibia in the intercondylar area and runs in a superior and anterior direction on the medial side of the anterior cruciate ligament. It attaches to the anterior femur on the medial condyle. The ACL tightens during extension, preventing hyperextension of the knee. When the knee is flexed, the ACL keeps the tibia from being moved anteriorly. The posterior cruciate ligament keeps the femur from being displaced anteriorly on the tibia or the tibia from being displaced posteriorly on the femur.⁷

The medial collateral, or tibial collateral, ligament is a flat, broad ligament, attaching to the medial condyles of the femur and tibia. Fibers of the medial meniscus are attached to this ligament. On the lateral side is the lateral collateral, or fibular collateral, ligament. It is a round, cord-like ligament that attaches to the lateral condyle of the femur and runs down to the head of the

FIGURE 2:
Normal knee



fibula. It does not attach to the lateral meniscus. The collateral ligaments provide stability in the frontal plane. The medial and lateral menisci are two wedge-shaped fibrocartilage disks, located on the superior surface of the tibia and are designed to absorb shock. The medial meniscus, due to its attachment to the medial collateral ligament, is more frequently torn.⁷

Muscles of the knee

The pes anserine muscle group is made up of the sartorius, gracilis, and the semitendinosus. Each proximal attachment has a different source; the sartorius muscle from the iliac spine, the gracilis from the pubis, and the semitendinosus muscle from the ischial tuberosity. They all join together to have a common distal attachment on the anteromedial surface of the proximal tibia.⁴ The quadriceps muscles are comprised of four muscles: rectus femoris muscle, vastus lateralis, vastus medialis and vastus inter medialis. All four attach to the base of the patella and to the tibial tuberosity through the patellar tendon. The popliteus muscle originates on the lateral condyle of the femur and crosses the joint posteriorly to insert medially on the posterior proximal tibia. The gastrocnemius muscle attaches by two heads to the posterior surface of the medial and lateral condyles of the femur. After descending the posterior calf superficially, it forms a common tendon with the soleus muscle and attaches to the posterior surface of the calcaneus. The gracilis, sartorius, and tensor fascia latae muscles span the knee joint posteriorly and provide stability to the joint.⁶

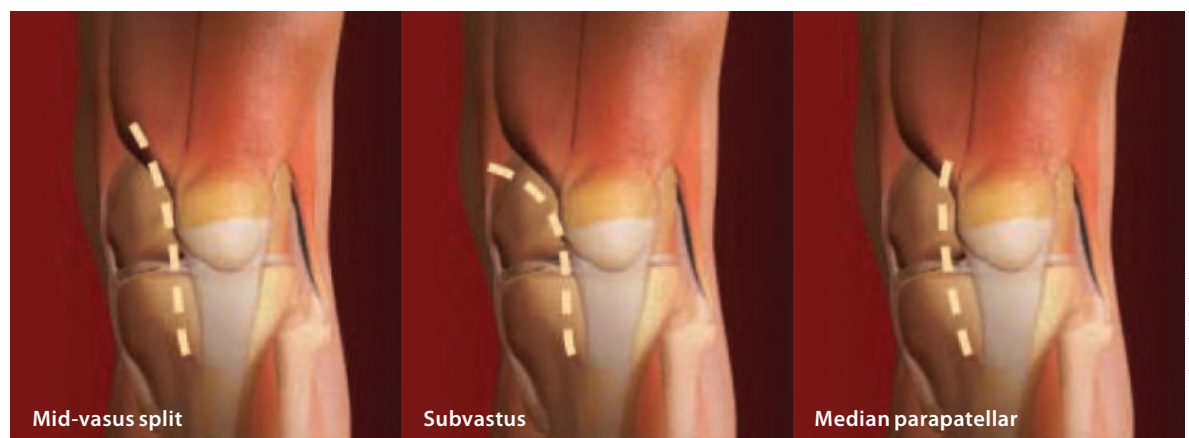
MIS surgical approach

Many surgeons today are using the mini-incision (MIS) approach. Ideally, this approach does not evert the patella or resect the quadriceps muscle or tendon. It does not necessarily involve a smaller four- to six-inch skin incision. The idea behind the MIS is that if the knee's extensor mechanism is not disturbed, the patient should experience a faster recovery and less postoperative pain.¹¹

The surgeon can choose from three different approaches (Figure 3):

The subvastus approach provides exposure, while preserving the quadriceps attachments to the patella. This approach will not require the patella to be everted. The subcutaneous tissue is divided down to the fascia of the vastus medialis. The inferior border of the muscle is identified and cut usually 4 to 9 cm medial to the edge of the patella in order for the surgeon to slide a finger under the muscle obliquus, while staying on top of the synovial lining of the joint. The vastus medialis is pulled superiorly. The vastus medialis is then released from the medial retinaculum, while leaving a portion attached to the inferior border of the vastus medialis. The incision is then made through medial retinaculum and synovium along the medial border of the patella, then inferiorly following the medial border of the patellar tendon to the proximal portion of the tibia. The medial soft tissue sleeve is elevated along the tibia. The patella and extensor mechanism are retracted into the lateral gutter. The knee is flexed, and the patella should stay

FIGURE 3:
Types of incisions



Courtesy: Wright Medical Technology, Inc.

retracted in the lateral gutter behind the Hohmann retractor. The quadriceps tendon and vastus medialis will lie over the distal anterior portion of the femur. The knee is flexed in various degrees of extension during the different procedural steps to improve visualization along with retracting the extensor mechanism. The medial and lateral menisci and any osteophytes are removed, along with soft tissue releases.¹²

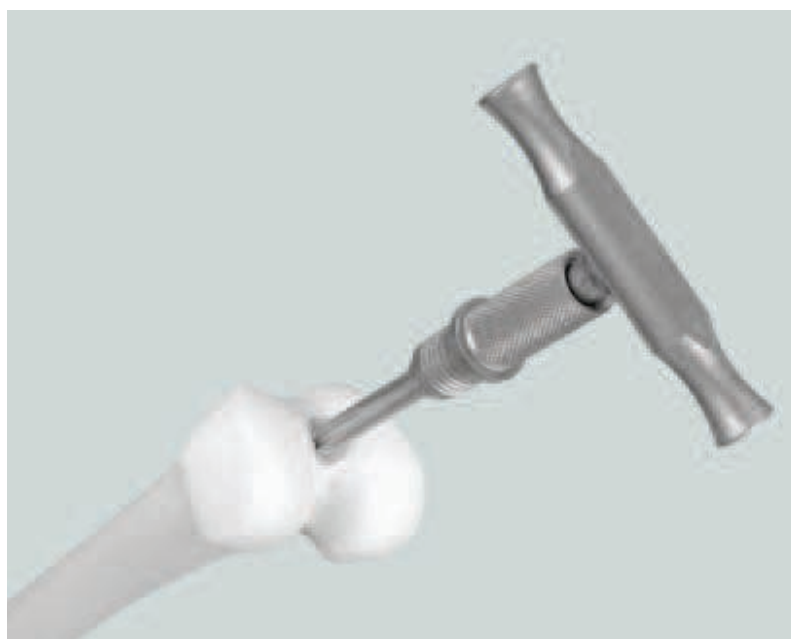Standard total knee incision

Anterior midline is the most common skin incision; it is made with the knee in flexion, which allows for better exposure. The skin incision should be long enough to avoid excessive tension during retraction. The standard retinacular incision is a medial parapatellar approach. It is extended proximally the length of the quadriceps tendon, leaving a 3 to 4 mm cuff of tendon on the vastus medialis for later closure.² The incision is continued around the medial aspect of the patella, extending 3 to 4 cm onto the anteromedial surface of the tibia, along the border of the patellar tendon. The medial side of the knee is exposed by subperiosteally stripping the anteromedial capsule and deep medial collateral ligaments off the tibia. Special attention must be paid to the patellar tendon attachment to the tibial tubercle; avulsion is very difficult to repair. The knee is extended and the patella is everted along with the release of lateral patellofemoral plicae and adhesions. In obese patients, a lateral release may be necessary to allow eversion of the patella. The knee is again flexed, and the remaining meniscus and ACL are removed. If a PCL-substituting technique is being used, the PCL will also be removed at this time.²

Wright Advance Knee System

Femoral preparation

An opening in the femoral canal is initiated with a $\frac{3}{8}$ " drill bit. The opening is placed medial and anterior to the anteromedial corner of the intercondylar notch. The fluted intramedullary (IM) reamer/rod is inserted into the femoral canal, while irrigating and aspirating several times to reduce the risk of fat embolism.



Courtesy: Wright Medical Technology, Inc.

Femoral alignment

The valgus angle is set prior to attaching the valgus angle alignment guide to the IM reamer/rod. A small screw is tightened to lock the valgus angle. The femoral valgus alignment guide slides over the IM reamer/rod, until the paddle rests against the distal condyle. The guide is locked in place by tightening the large screw. The distal resection crosshead may be locked onto the valgus alignment guide by tightening the locking screw with a hexagonal head screwdriver. The alignment is checked by referencing the femoral head with the external alignment guide and rod. The crosshead is fixed to the anterior femur by placing $\frac{1}{8}$ " headless pins or drill bits into the zero-holes (Figure 4).

Femoral resection

The distal femoral resection is performed with or without the IM rod and alignment guide in place. The valgus angle alignment guide and IM reamer/rod are removed with the T-handle. It is removed as one unit, therefore the large screw need not be loosened. The distal femur is resected using a 0.050 thickness saw blade. Either the standard resection slot or the +4 mm resection slot may be used, as necessary. The crosshead may be adjusted proximally or distally as needed and stabilized with an additional headless pin through the divergent pin hole to provide additional stability.

FIGURE 4:

Alignment rod insertion

FIGURE 5:

Graduated markings on the stylus correspond to the length of the anterior flange

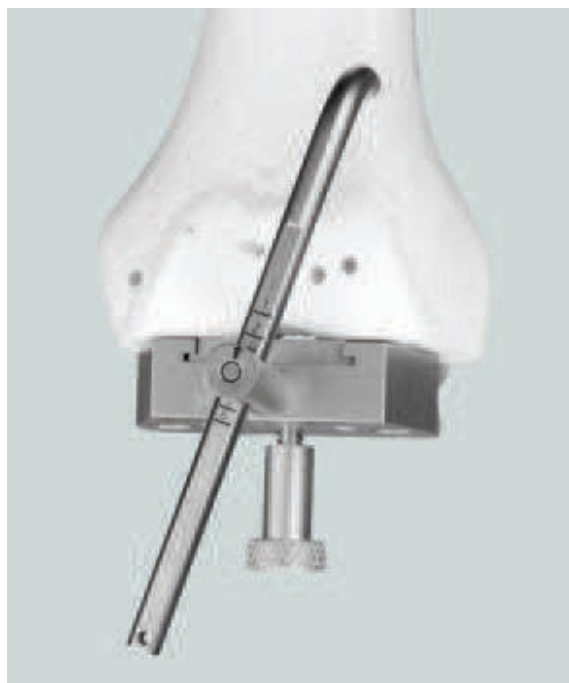


FIGURE 6:

The 0° guide can be used with a tommy pin to set rotation manually, using the A-P photo axis.

Femoral sizing

The anterior-posterior (A-P) femoral sizer is placed flush against the resected distal femur and adjusted so that the feet rest against the posterior condyles, and the stylus touches the most prominent aspect of the anterior cortex just proximal to the anterior condyles. The estimated size is indicated on the distal surface of the sizing caliper (Figure 5). The markings on the stylus correspond to the length of the anterior flange of the femoral component and can be used to locate the exit point of the sawblade. The sizer is pinned to

the distal femur using 1/8" diameter-headed pins. After determining the appropriate size, the holes in the distal femur for the fixation pegs on the femoral resection block are prepared with a 3/16" drill bit and the 0° or 3° drill guide (Figure 6). The position of the holes determines external rotation relative to the posterior condyles. The surface marked "left" should face the surgeon for a left knee and "right" should be facing the surgeon for a right knee.

Anterior and posterior resections

The femoral resection block corresponding to the size indicated by the caliper is selected. The femoral resection block is placed into the prepared holes and flush to the distal femur. The block is stabilized medially and laterally using 1/8" diameter-headed pins. The posterior cut is carried out first using a 0.050 thickness saw blade, followed by the anterior (Figure 7).

Trochlear groove resection

The final femoral resection of the trochlear groove is performed. The guide is attached to the femur using fixation pins and the resection is carried out.

Tibial preparation

The ankle yoke is positioned against the lower leg proximal to the malleoli, and the spring is wrapped around the leg. The bar holding the appropriate resection crosshead is raised, and the bar is pinned to the upper tibia once the crosshead is centered on the proximal tibia (Figure 8).

Extramedullary tibial resection

The resection slot is located a few millimeters below the lowest articular surface. The medial/lateral adjustment screw at the ankle is used to align the resection guide parallel to the tibia. The stylus is attached to the crosshead, and the crosshead adjustment knob is turned to raise or lower the crosshead until the level of the resection is indicated by the stylus. The crosshead is pinned to the proximal tibia using headless pins to allow detachment of the crosshead from the guide to allow proximal or distal movement. An align-

ment guide and rod may be used to check alignment to the ankle. The crosshead may be pinned to the tibia through the divergent pin holes for added stability. The resection is carried out using a 0.050 thickness saw blade. If necessary, the 3° varus/valgus resection block is used to re-cut the tibia in correct alignment.

Tibial sizing


The tibial trial base equal in size to the femoral implant is assembled with the trial base handle and placed against the proximal tibial surface. Alignment may be checked by inserting an alignment rod through the handle to check alignment to the ankle. The keel punch guide is attached to the keel punch handle and is secured to the trial base by turning the knurled handle. The entry hole for the tibial stem is prepared using the ½" drill guide and reamer. The hole is reamed to the necessary depth. The appropriate keel punch on the threaded punch handle is slid through the guide until the punch is fully seated. Once the punch is seated, the handle is removed by turning counter-clock-wise until it is disengaged from the punch leaving the tibial trial base and stem in place for trial reduction.

Patellar preparation

The patellar reamer guide is attached to the parallel patellar clamp and is centered over the apex of the patellar articular surface and clamped (Figure 9). The thumbscrews are loosened on the depth regulator until it rests at the bottom of the patellar reamer guide. The appropriate patellar reamer is inserted into the guide until it rests on the apex of the patellar articular surface. Reference the scale on the side of the reamer guide to note the depth of the reamer. The top edge of the depth regulator is set to 14 mm below the reamer collar. The depth regulator stops the reamer at the appropriate level. The appropriate drill guide is used to size the patella and prepare holes in the bone for the implant peg(s).

Trial reduction

The knee is flexed, and the appropriate size femoral trial is placed on the distal femur using the femoral impactor or holder/driver. The appropri-



Courtesy: Wright Medical Technology, Inc.

FIGURE 7:

(A) The width of the resection block is equal to the femoral width. (B) The anterior face has the same profile as the anterior surface of the femoral implant.



Courtesy: Wright Medical Technology, Inc.

FIGURE 8:

The medial/lateral adjustment screw at the ankle is used to align the resection guide. The stylus is attached to the crosshead until the stylus indicates the desired level of resection.


ate tibial trial insert is placed onto the trial base, and the trial reduction is completed. When satisfied with the fit, the trials are extracted using the appropriate tools.

Implant insertion

The femoral implant is inserted with the femoral impactor or folder/driver. The metal tibial base is inserted with the tibial base impactor. The trial tibial insert may be reinserted to check ligament and soft tissue balancing for stability. The trial

FIGURE 9:

During patellar preparation, the appropriate tri-peg or central peg reamer is used to prepare the peg hole(s).



Courtesy: Wright Medical Technology, Inc.

tibial insert is removed. The patellar implant is secured with bone cement and held in place with the parallel patellar recessing clamp. Once the cement has cured, the appropriate tibial insert is seated and locked into place.

Ligament balancing

Soft tissue and ligament releases are performed during exposure and bone resurfacing. Three common problems may occur during total joint reconstruction: varus deformity, osteophytes and valgus deformity.

Varus deformity is a common problem in the osteoarthritic knee. The surgeon will usually release the deep medial collateral ligament off the tibia and the attachment of the semimembranosus aponeurosis.²

Osteophytes, on both tibia and femur should be removed because they can raise the medial soft tissue sleeve which will shorten the MCL. For severe deformities, the PCL and posterior medial capsule can also be released. Too much of a release can lead to valgus instability.²

Valgus deformities often occur in patients with rheumatoid arthritis and osteoarthritis, usually associated with hypoplasia of the lateral femoral condyle and flexion contracture of the knee. For correction, the lateral capsule is released from the tibia. In lesser degrees of deformity, balance can be obtained by release of the iliotibial band at the level of the joint line. For severe deformities, the LCL can be stripped off the lateral condyle and the popliteus tendon can be incised.²

In a fixed flexion contracture, posterior soft tissues block full extension of the knee. The first step is to strip the adherent posterior capsule proximally off the femur, a short distance above the femoral condyles posteriorly. Additional bone from the distal femur will also help correct the contracture by enlarging the narrowed extension gap.²

Wound closure

The wound is irrigated, hemostasis is achieved, and a drain is placed, if necessary. Closure occurs with the knee in approximately 35° of flexion in layers with suture according to the surgeon's preference. A bulky dressing is applied.

Key Terms^{2,7,9}

Pes anserinus is the combined insertion of sartorius, gracilis and semitendinosus.
Ligament of Wrisberg is a band that leaves the posterior horn of the menisci, passes along side of the PCL and attaches to the medial condyle of the femur.
Transverse ligament stretches across the anterior part of the knee and connects one meniscus to the other.
Coronary ligaments are the deeper portions of the capsule that unites the menisci to the tibia and femur.
Ligamentum mucosum is often the first structure seen when entering the joint through a scope; it is a triangular fold of synovial membrane.
Genicular arteries: superior, middle, inferior = collateral circulation around the knee. The greatest risk in a lateral retinacular release is devascularization of the patella caused by interruption of the superior lateral geniculate artery. This artery is located at the musculotendinous junction of the vastus lateralis.
Popliteus bursa lies between the popliteus tendon and the lateral condyle of the femur. It separates the popliteus tendon from the lateral menisci.
"The unhappy triad of O' Donoghue," or called (terrible triad) includes the tibial collateral ligaments, ACL and medial meniscus when torn.
Chondromalacia consists of softening, discoloration, fraying and degeneration of the articular surface of the kneecap. This is seen in women ages 14–28 usually.
Osteochondritis dissecans; distal femur, portion of it loses blood supply, usually lateral surface medial condyle.
Baker's cyst occurs at the back of the knee, (popliteal cyst) and can result from an enlargement of the semi-membranous bursa or bursa beneath the medial head of the gastrocnemius. It seems to be associated with a meniscal tear.
Joint mice is any loose body in the knee joint.

Postoperative care, complications and prognosis

Continuous passive motion may be implemented to maintain range of motion. The patient typically remains hospitalized for three to four days postoperatively. A rigorous physical therapy program may be ordered to assist the patient in gaining strength and maintaining balance. Assistive devices, such as a walker or cane, may be needed initially.

Potential postoperative complications may include infection. Infection in a total joint is catastrophic for the patient. Infection control begins with the operating room team that must observe and practice strict aseptic technique. The following recommended methods are just some of the ways to reduce the risk of surgical site infection:

- Minimize the number of personnel in the room
- Eliminate unnecessary conversation in the room
- Use ultra-clean air operating rooms (laminar flow-vertical and horizontal)
- Use ultraviolet light
- Use body exhaust systems (low levels of bacterial shedding)
- Use prophylactic antibiotics
- Use double gloving

Other complications may include:

- Hemorrhage
- DVT- deep venous thrombosis
- Restricted range of motion
- Neurovascular complications related to tourniquet inflation
- Uneven leg length

The patient is expected to return to normal activities within four to six weeks postoperatively.

About the author

Jeff Bidwell, CST, CSA, MA, graduated from the Madisonville Community College Surgical Technology Program in 1991, earned his Bachelor's degree from the University of Southern Indiana in 1997, and a Master's degree from Murray State University in 1999. Over the past 15 years, he has worked in all surgical areas with a specialty in orthopedics.

Currently, he is the director of the Surgical First Assisting and Surgical Technology Programs at Madisonville Community College, instructor of European and American history and part-time CSA with the Trover Clinic orthopedic department. He also serves as chair of the Subcommittee on Accreditation for Surgical Assisting (SASA) and also as chair of the AST Education and Professional Standards Committee. Jeff serves on the Board of the Kentucky State Assembly and as an advisor for the Kentucky Medical Boards Surgical Assisting Committee. He is also working on the second edition of the *Surgical Assisting Core Curriculum*.

References

1. Becker, J. Stucchi A, ed. *Essentials of Surgery*. Philadelphia: WB Saunders; 2005.
2. Canale T. *Campbell's Operative Orthopaedics*. St Louis: Mosby; 1998.
3. Price P, ed. *Surgical Technology for the Surgical Technologist: A Positive Care Approach*. 2nd ed. Albany, NY: Thomson Delmar Learning; 2004.
4. Wheelless' Textbook of Orthopaedics, <http://www.wheellessonline.com/ortho/2136>. Accessed 3/9/2006.
5. Gray, H et al. *Anatomy of the Human Body*. Philadelphia: Lea & Febiger; 1985.
6. Moore K, Dalley A. *Clinically Oriented Anatomy*. 4th ed. Philadelphia: JB Lippincott; 1999.
7. Martini, F. *Human Anatomy*. 3rd ed. Upper Saddle River, NJ: Prentice Hall; 2000.
8. Niederhuber J. *Fundamentals of Surgery*. New York: Appleton & Lange; 1998.
9. Thorek, P. *Anatomy in Surgery*. Philadelphia: JB Lippincott; 1951.
10. Townsend C. *Sabiston Textbook of Surgery*. 17th ed. Philadelphia: JB Lippincott; 2004.
11. Wright Medical Technology. www.wmt.com. Accessed 3/8.2006.
12. Zimmer Orthopedic Products.