

# AST

**Association of Surgical Technologists**



## *CE Credit Package 8*

*8 Credits for \$13<sup>00</sup>*



*Please submit your completed Master Answer Sheet along with payment to*

*AST Member Services*

*6 W. Dry Creek Circle, Suite 200 Littleton, CO 80120*

*Or fax with credit card information to (303) 694-9169.*

*Or scan and e-mail with credit card information to [memserv@ast.org](mailto:memserv@ast.org).*

*Table of Contents*  
*CE Credit Package 8*



**Total Knee Arthroplasty**

**Surgical Correction of Acquired Adult Flatfoot Deformity**

**Hip Arthroscopy: Treating Femoroacetabular Impingement**

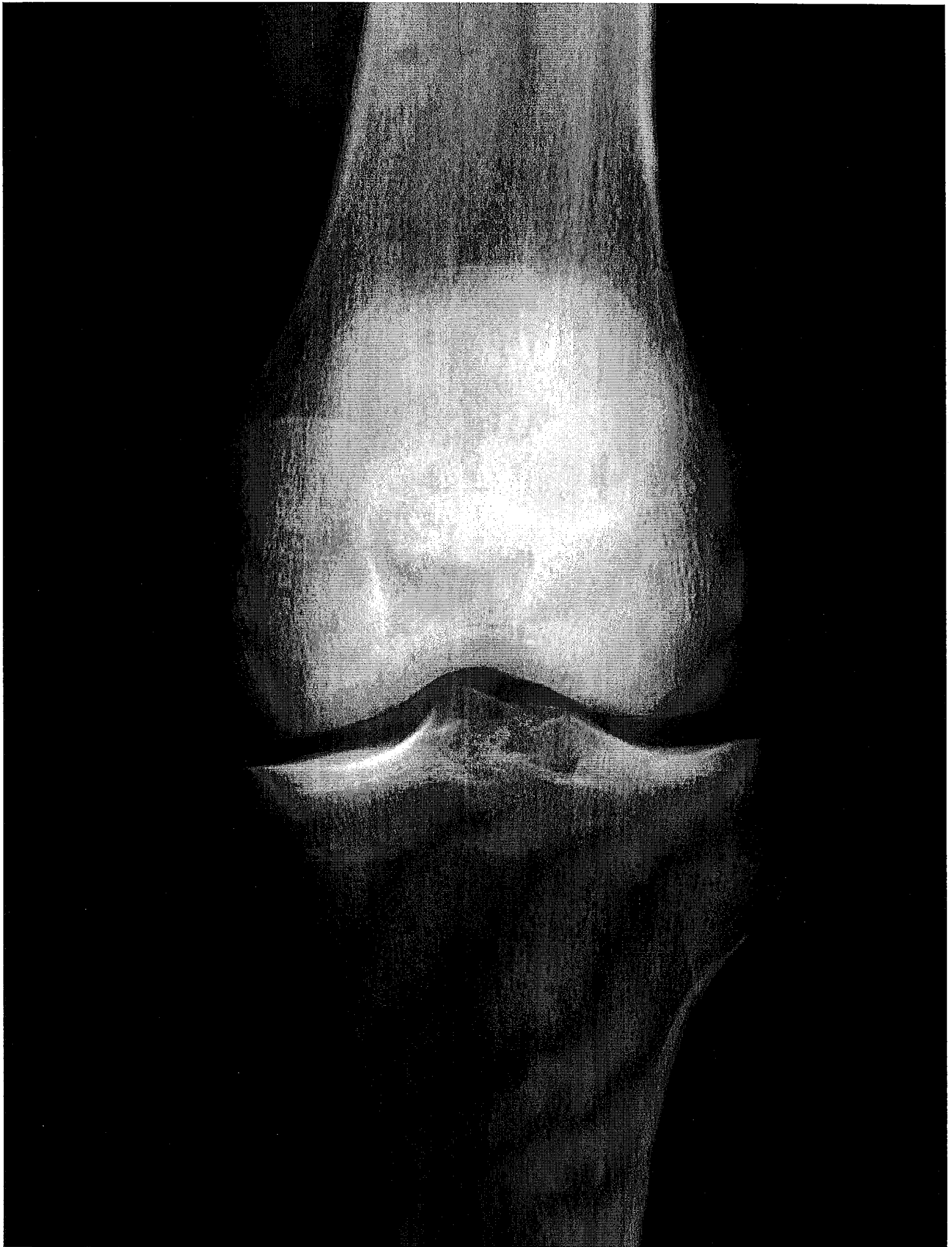
**Platysmaplasty A Surgical Resolution for the “Turkey Neck”**

**Emergency Cesarean Delivery in the Labor and Delivery Room**

**Radical Neck Dissection**

**Pectus Carinatum: Pigeon Chest**





# Total Knee Arthroplasty

by Linda Bauer, CST

Total knee arthroplasty is one of the most extensive and technically difficult elective surgeries performed today. From the patient's point of view, the decision to have an important joint deliberately obliterated and replaced with manufactured components cannot be an easy one, and is further complicated by considering the potentially-devastating effects of a failed procedure.

**F**or the surgeon, knee replacement presents formidable technical challenges, as careful planning and precise execution are critical in providing the patient with full postoperative function. Planning and precision are central in the surgical technologist's role as well, as instrumentation for this procedure is extensive and highly specialized. The introduction of navigation systems to aid in knee replacement adds another level of complexity for the surgical team, a prospect that can be quite daunting for a new or inexperienced surgical technologist. This article will discuss computer-assisted total knee arthroplasty and present information to help surgical technologists participate effectively in this surgery.

The basic principles of total knee replacement are fairly straight forward. The knee is a hinge joint, in which the distal condylar surface of the femur articulates with the proximal surface of the tibia. This articulation is maintained by a system of strong ligaments, and the joint is protected by the patella bone, which is held in place by thick tendons. Injury, age and arthritic changes can contribute to deterioration of the joint surfaces, resulting in significant pain and loss of function. The surgery

## LEARNING OBJECTIVES

- ▲ Compare and Contrast the standard and navigation knee replacement systems
- ▲ Evaluate the benefits of the imageless navigation system
- ▲ Analyze the step-by-step process of the total knee procedure using an imageless navigation system
- ▲ Explore the history and development of the total knee procedure

involves the removal of the ends of the femur and tibia by means of a series of chamfered saw cuts, and the addition of artificial joint components to both bones, as well as to the inner surface of the patella.

The success of the total knee procedure depends on many factors, including patient selection, prosthesis design, the preoperative condition of the joint, surgical technique (including soft tissue balancing and limb alignment) and postoperative rehabilitation.

The success of the total knee procedure depends on many factors, including patient selection, prosthesis design, the preoperative condition of the joint, surgical technique (including soft tissue balancing and limb alignment) and postoperative rehabilitation.

#### HISTORY AND DEVELOPMENT

Total knee replacement has advanced considerably since the first attempts more than a century ago, when Theophilus Gluck designed and implanted a total knee made of ivory, stabilizing the implants with plaster of paris and colophony (a translucent, brittle substance produced from pine oleo resin, which is used in varnishes and inks).<sup>1</sup> Gluck's total knee failed for a variety of reasons, including poor bearing surface, improper fixation, and frequent infections. With many improvements, the Walldius hinge was introduced in 1951. Made of acrylic, and later upgraded to cobalt chromium (CO-CR) in 1958, this implant was used until the early 1970s. In 1968, Frank H Gunston, MD, a Canadian surgeon, designed the first polycentric knee.<sup>1</sup> Two basic flaws in his design limited its success: it did not replace all the condylar surfaces, and it had a small contact area. This polycentric knee was made of stainless steel and only replaced the weight-bearing part of the knee, which is not a true condylar knee. A narrow, polycentric metal replaced the weight-bearing part of the condyles, and the tibia was replaced with narrow, plastic runners. This allowed for minimal rota-

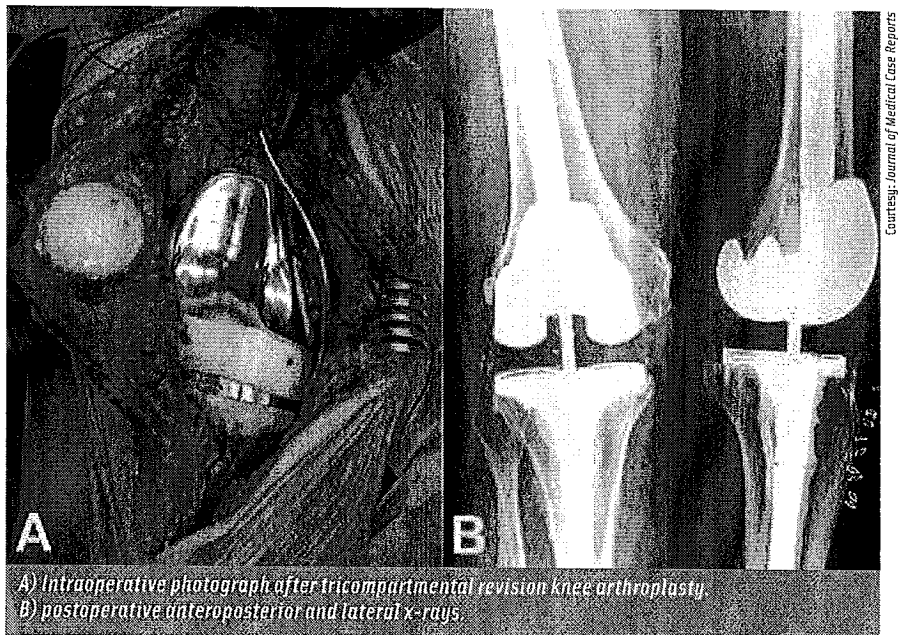
tion. Consequently, these components loosened after a while, which resulted in failure of this polycentric knee.

By the 1970s, the race was on to create the perfect condylar knee. Between 1970-73, three implants were developed independently.<sup>1</sup> In New York, Walker, Ranawet and Insall came up with their version. At the same time, Coventry and Turner introduced the geometric prosthesis, and Towley, from Huron, Mich, came up with the anatomic knee. There were two common threads that each of these

protheses had. One was preserving the cruciates to ensure stability, and the other was using polymethylmethacrylate cement for fixation. The geometric knee had rotational constraint resulting in a high failure rate and was later discontinued. The anatomic knee replaced the troclear surfaces. This requires minimal removal of tibia and femur bone and allows the preserva-

tion of both cruciates. Failure occurred because of a thin tibia component and lack of fixation. As a result, the anatomic knee was also discontinued.

In 1971, Freeman and Swanson began using the Imperial College London Hospital (ICLH) knee.<sup>2</sup> It relied completely upon component geometry and soft-tissue balance to provide stability with both cruciate ligaments being sacrificed. This procedure was practiced until 1975. A study of complications and failures showed that an acceptable outcome



could not be achieved reliably. The tibial components tended to sink and loosen and patella pain was persistent and sometimes resulted in a patellectomy (removal of the patella bone).<sup>2</sup> In addition, the poly surface of the tibia showed surface damage, which was attributed to the cement being left in the posterior compartment of the knee. Last but not least, alignment of the knee and the control of instability could not be achieved accurately and reliably by the eye.<sup>2</sup>

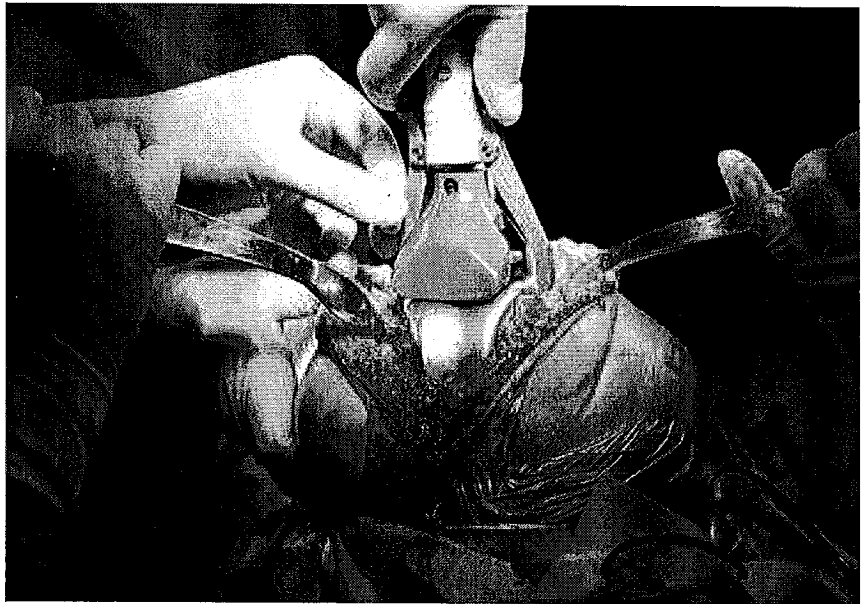
Over the next several years, many designs were attempted without success. Optimal material for the prosthesis had not been found, and stability could not be reliably maintained. In 1978, Johns Hopkins introduced the concept of universal instrumentation,<sup>1</sup> regardless of manufacturer. By the 1980s and 90s, most of the condylar designs incorporated universal instrumentation. Additional improvements in condylar design allowed better fixation with and without cement, reducing wear, enhanced kinematics and increased range of motion.<sup>1</sup>

### **SURGICAL NAVIGATION SYSTEMS**

Surgical navigation was developed to help reduce errors in component alignment during total knee arthroplasty<sup>3</sup> and to help surgeons install implants more accurately and reproducibly. Navigation systems also record quantitative information, such as joint range-of-motion, laxity, and kinematics, intraoperatively.<sup>3</sup>

Computer-assisted surgical systems have been developed for procedures such as total hip replacement, anterior cruciate ligament reconstruction, high tibial osteotomy, revision total knee arthroplasty, and many others. The earliest and most complex were active robotic systems, in which the robot performed surgical tasks, such as drilling, without the direct intervention of the surgeon.<sup>3</sup> This robotic system was not widely used because of the cost and complexity.

Semi-active systems do not perform surgical tasks, but may limit placement of surgical tools. With this system, the surgeon first indicates the desired position and orientation of the femoral prosthetic component on a three-dimensional digitizing template. The robot then positions the saw and drill guides so that the surgeon can make the necessary cuts and holes.<sup>3</sup>



The passive system receives information such as cut plane orientation and limb alignment that is displayed on a computer monitor in the operating room. Preoperative image systems rely on models derived from CT images, or by morphing a generic model to match the bony geometry of a particular patient.

This article focuses on the imageless navigation system by Stryker.

### **IMAGELESS NAVIGATION SYSTEMS**

Imageless systems collect information needed for navigation through direct measurement of bony landmarks, or through kinematic algorithms to determine joint centers.<sup>3</sup> Stryker entered the surgical navigation market in 2000, and introduced imageless navigation to orthopedics in 2001. The imageless system does not require preoperative CT or MRI scans. This navigation system is an interactive operative monitoring system designed to improve the surgical performance and clinical outcome of knee replacement surgery. As a PC-based imageless guidance system, the knee navigation system helps to facilitate improved decision-making for alignment and orientation of instruments, trials and implants as well as for balancing soft tissue.<sup>4</sup> It has an open platform, which means that it has dedicated instruments that are compatible with different implant systems. With the imageless system, the medical team can use either Articular Mounted Surface (ASM) or Precision 4.0. Precision 4.0 can be used in the manual implant sizing mode or the automatic implant sizing mode, according to surgeon preferences.

To implement the Stryker navigation system, the surgical team will need: a camera, trackers, pointer, cutting jigs and fixation pins.

Navigation systems have a few basic components. An optical tracking system measures the position and orientation of the trackers that are attached to the femur and tibia with bicortical screws or drill points. The pointer digitizes

Surgical navigation was developed to help reduce errors in component alignment during total knee arthroplasty<sup>3</sup> and to help surgeons install implants more accurately and reproducibly.

bony landmarks, monitored by a camera that is attached to the computer. The influence of navigation on the alignment is unclear. Surgical complications associated with navigation are very minimal. There is a chance of stress fractures from the tibial and femoral pin sites. Operating time increases slightly using navigation—usually by approximately 10-20 minutes. No long-term studies have proven that navigation improves postoperative functions, kinematics, allows for more rapid recovery or decreases complication rates. Debate exists on the utility of navigation,<sup>3</sup> but it can provide valuable feed back during surgery.

Instrumentation and equipment used in navigation is not very different from setting up a regular total knee. The surgical technologist will need all of the regular total knee instruments, omitting a few of the standard jigs and replacing them with the navigation jigs. Whether the surgeon uses ASM or Precision 4.0, determines when and where he or she will put in the fixation pins. This article focuses on Precision 4.0.

The first step is to register the trackers. Lithium batteries are placed into each of the trackers and the pointer. The trackers and pointer are then registered with the computer. This is accomplished by holding the tracker up to the computer and pressing the register button. Then, two Ortholock anchoring devices are placed on the femur and tibia. On the femur, the pins are positioned close to the knee joint. To minimize muscle load, pins are placed with the knee in flexion. On the tibia, the pins can be positioned distal to the tibial tubercle to avoid the patella tendon and collisions with the tibial implant. The Ortholocks will hold the femoral and tibial trackers.

Establishing a patient's mechanical axis is critical to a successful procedure. The mechanical axis runs from the center of the femoral head through the center of the knee, then through the center of the ankle. The mechanical axis is used to determine a patient's correct standing anatomy.

The position of the camera is very important. The camera is brought into alignment with the knee joint so that all instruments are centered in the working volume, signified by the grey circles on the monitor. The femur is registered next. By digitizing femoral landmarks, the following axes and references are defined: mechanical femur axis, femoral rotation axis, reference for resection level and reference for notching. It is very important to find the hip center, because this is the gene-

sis of all subsequent points. Hip center is the first point that is mapped after determining a patient's mechanical axis, and is accomplished by slowly and smoothly rotating the hip.

Next, the pointer's tip is placed into the sulcus of the medial epicondyle and the pointer's select button is pressed, which registers those points. The pointer is then placed on the most prominent point of the lateral epicondyle and registered. Next, the pointer is placed at the center of the troclear sulcus, anterior toward the distal end of the femoral shaft to determine the femur center. This is essentially where one would place the intramedullary rod when using conventional instrumentation. Next, the pointer is aligned with the most posterior point of the trochlea and the most anterior point of the intercondylar fossa, also referred to as Whiteside's line, and the point is registered. The medial distal condyle is then digitized, along with the lateral distal condyle and anterior cortex. This completes registration of the femur. The next step is to register the tibia.

By digitizing tibial landmarks, the following axes and references are defined: mechanical tibia axis, tibial rotation axis and reference for resection level. The leg is flexed with a retractor being placed behind the tibia, to bring it into view. First, the tibia is registered center, followed by the tibial A/P axis. The pointer is placed midpoint, at the posterior cruciate ligament and the medial third of the tibial tuberosity. Then the medial and lateral compartments are digitized. It is important to determine the most prominent aspect of the medial malleolus and the most prominent aspect of the lateral malleolus and register these points. Upon completion of femur and tibia registration, the surgeon has established

a defined reference system. The digitized reference landmarks and axes are now used to assess the kinematics and calculate the alignment of instruments and bone cuts.

When the surgical procedure is finished, all of the procedure-related information can be saved in the computer. At the surgeon's request, the information can be transferred to a CD and printed on paper. Care of the navigation trackers is very important. They can only be wiped off with an enzymatic cleaner. They cannot be immersed in water. The navigation instruments can be cleaned in the usual manner. The trackers and the navigation instruments can be autoclaved so that they can be ready for the next procedure. The monitor should be wiped down with water and a sponge, as well as a disinfectant, after every case to remove any debris.

## CASE STUDY

### History

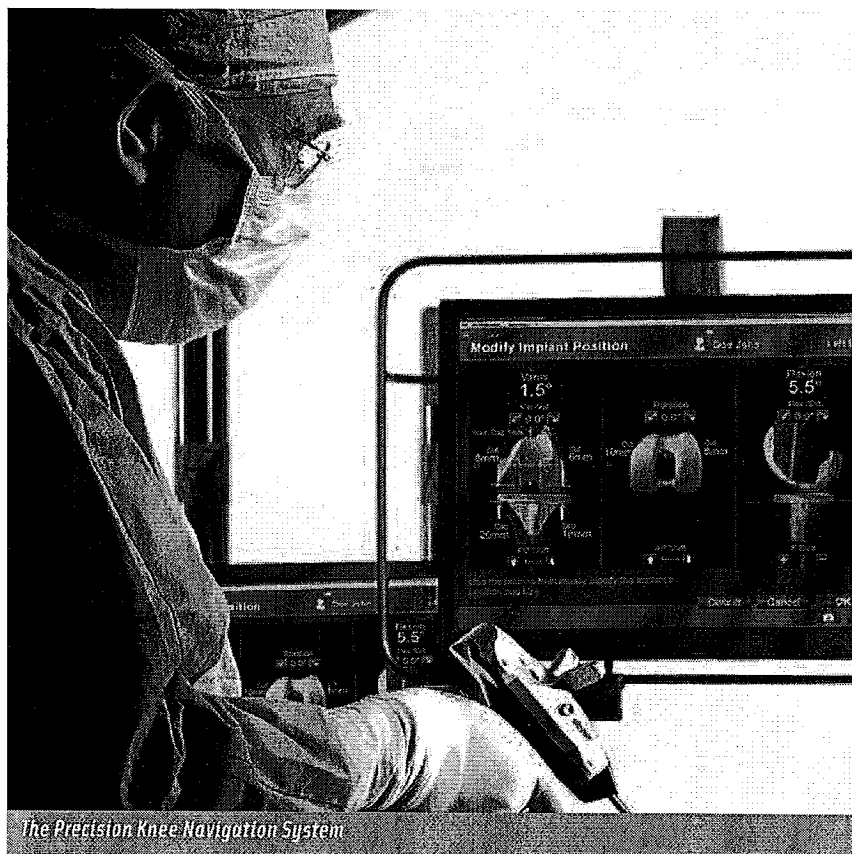
The patient is a 53-year old female, who first went to her doctor in 2004, at the age of 46, due to an injury caused by a fall at her work place. She is a runner and very active. After examination, it is concluded that the patient does not have any mechanical symptoms of locking. She has a negative Lachman test and negative pivot shift. She was sent for an MRI, which showed a medial meniscal tear. X-rays show narrowing of the medial joint space, and probable chondromalacia with infusion. At the time of her initial appointment, the patient chose not to treat the tear, she was stable.

Over the next five years, she was treated with numerous steroid shots, due to pain in her knee. Then she was treated with a hyaluronate injection, which involved a series of three injections, two weeks apart. Subsequently, she experienced some relief. After six months, she repeated the hyaluronate injection protocol. In June 2009, she opted for a total knee replacement with 4.0 navigation.

### Procedure

After anesthesia is administered, a well-padded tourniquet is placed about the left upper extremity. The patient is prepped with an antimicrobial, antiseptic skin cleanser,

then painted with chlorhexidine gluconate solution and draped in the usual sterile fashion. The extremity is exsanguinated and the tourniquet is inflated to 300 psi, and deflated prior to wound closure. Pins are placed from lateral to medial in the femur and the tibia for navigation. The midline incision is made. Parapatellar arthrotomy is carried out, and in this case, a large amount of clear joint fluid emerged. The joint is exposed and registered with Stryker 4.0. This patient has a very thick, plain white synovial tissue throughout the knee. It is not in fronds, and is more membranous in nature. A synovectomy will be performed at the conclusion of the case.<sup>5</sup>



Having registered the knee, the distal femur is resected 9mm from the high side. Rotation is centered on the average of the transverse epicondylar and A/P axis, which correlates with about three degrees external rotation relative to the posterior transcondylar axis. The patient is then shifted 1.5mm anterior so as not to notch her. Anterior and posterior beveled cuts thus created for a size four Triathlon knee. The tibia is sublaxated, meniscal remnants are taken, and the posterior cruciate ligament is preserved. The tibia



is cut zero degrees mechanical axis rotation centered on the juncture of the medial middle third of the tibial tubercle with a four-degree posterior slope. The surgeon resects 1mm below the low point of the low side. Posterior osteophytes are removed. After a medial release, it is determined that the patient balances well with a 13mm insert. With full extension and flexion to 144, the knee is stable throughout a range of motion. The patella is then measured with a caliper. Osteotomy is created at the appropriate level, and resurfaced

Instrumentation and equipment used in navigation is not very different from setting up a regular total knee. The surgical technologist will need the regular total knee instruments, omitting a few of the standard jigs and replacing them with the navigation jigs.

with an asymmetric 9x29 patella. The trial components are removed and copious irrigation is carried out. Cement is packed into dried interstices of the bone and the components are placed. The Stryker Triathlon system is used: a size four femur CR (cruciate retaining), size four tibia, 13mm CR insert and an asymmetric 9x29 patella. Final kinematics are excellent—within one degree of the mechanical axis throughout the full range of motion—and the knee is stable. The tourniquet is deflated.<sup>5</sup>

In this case, the patella tracks well, and does not require lateral release. Copious irrigation is carried out. The wound is injected with a ropivacaine cocktail. A drain is placed in the depths of the wound. The arthrotomy is closed with #1 polyglactin 910, subcutaneous: #2-0 Polyglactin 910, skin running subcuticular poliglecaprone 25, followed by a topical skin adhesive. The patient is placed in a soft-tissue dressing and a cold-therapy unit, and returned to the recovery room in good condition.<sup>5</sup>

The patient spent three days in the hospital. After returning home, she underwent six-eight weeks of physical therapy, consisting of formal physical therapy two times a week, and continued the exercises on the off days. Seven weeks after surgery, the patient returned to work on light duty for two weeks, followed by two weeks of restricted light duty, meaning she could not lift more than 20 pounds. After that, she returned to full duty. After 11 weeks, the patient was doing well, continuing her exercises. The patient reported that after three months, it was the best thing she ever did.

One piece of advice that the patient strongly encourages others to follow is to take the full time off and follow the prescribed protocol exactly. The patient is a surgical technologist, working full time at a hospital in Austin, Texas.

## CONCLUSION

Future research and development of navigation systems should address three major challenges in total knee arthroplasty: ensuring consistent postoperative outcomes, treating younger and more active patients, and enabling less invasive surgery.<sup>3</sup> Over the years, the medical field has seen the evolution of joint replacements. The procedures have improved from ivory implants being held in place with plaster of paris, to cobalt chromium (CO-CR) implants and a computer aiding the surgeon in getting just the right fit. The success of the total knee

still depends on many factors, including patient selection, preoperative conditions of the joint, and surgical technique. At the same time, it is such an exciting time for surgical technologists. There are so many exciting opportunities for learning new and more advanced procedures.

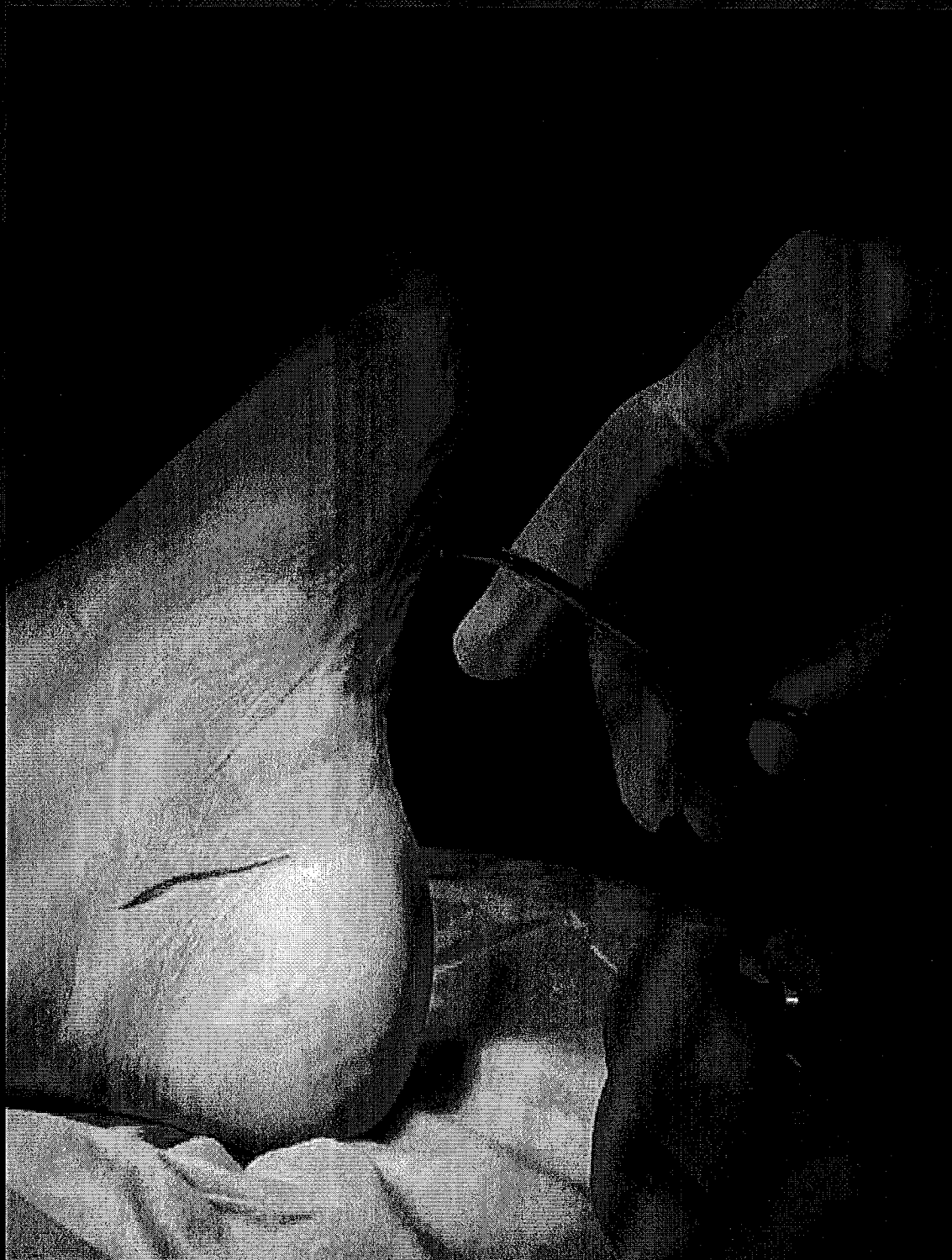## ABOUT THE AUTHOR

Linda J Bauer has been a surgical technologist for 32 years, and has been a CST since 1992. She currently works at Seton Medical Center in Austin, Texas, where she is a lead tech and specializes in orthopedics.



## References

1. Ranawat C. *SOA Textbook*. "History of Total Knee Replacement." The Southern Orthopaedic Association and Data Trace Publishing Company. 2006.
2. Freeman MAR; Todd RC; Bamert P; Day WH. "ICLH Arthroplasty of the knee: 1968-1977" *The Journal of Bone and Joint Surgery*. 1978;60-B,3:339-344. Also available at: <http://www.jbjs.org.uk/cgi/reprint/60-B/3/339.pdf>.
3. Siston, Robert; Giori, Nicholas; Goodman, Stuart; Delp, Scott. "Surgical navigation for total knee arthroplasty: a perspective." *Journal of Biomechanics*. 2007;40:728-735. Also available at: [http://www.mecheng.osu.edu/nmbi/files/nmbi/JoB\\_2007\\_ASB\\_Award\\_Navigation\\_Perspective.pdf](http://www.mecheng.osu.edu/nmbi/files/nmbi/JoB_2007_ASB_Award_Navigation_Perspective.pdf).
4. Stryker Precision Knee Navigation. Stryker Leibinger GmbH. Available at: [http://www.stryker.com/stellent/groups/public/documents/web\\_prod/056838.pdf](http://www.stryker.com/stellent/groups/public/documents/web_prod/056838.pdf)
5. Carter, Shelby MD. Surgical notes. [www.shelbycartermd.com](http://www.shelbycartermd.com)



## SURGICAL CORRECTION OF

# Acquired Adult *Flatfoot Deformity*

by Angel Webb, CST

*Pes Planus*, or flat foot, refers to the postural appearance of the foot. This condition can be acquired or congenital. This article discusses acquired cases in which there is a change in shape and position of the back and mid portions of the foot.

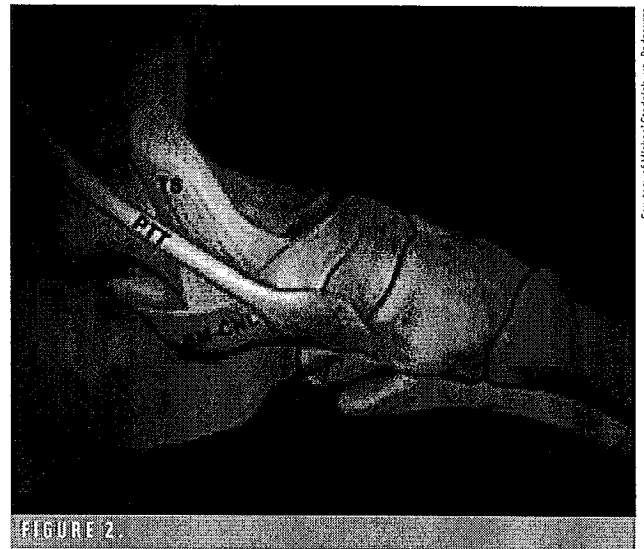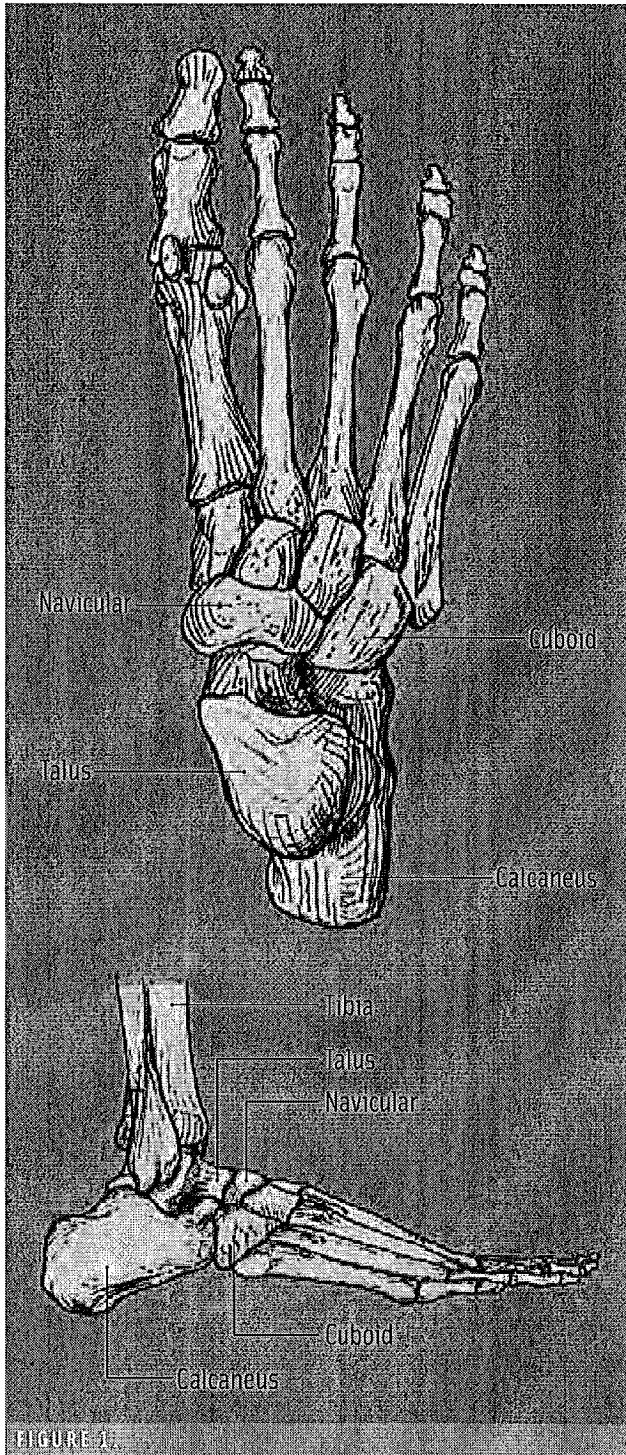
**A**lthough, 10-25 percent of the population have varying degrees of flatfoot, very few are symptomatic. Those that are symptomatic may complain of painful swelling posterior to the medial malleolus that may extend into the medial arch. They may also, variably, complain of foot, ankle or lateral hindfoot pain.

### ANATOMY

A review of relevant anatomy will help in understanding this topic. The subtalar joint is the articulation of the calcaneus and the talus, with the talus superior to the calcaneus. The talonavicular joint is between the talus and the navicular, and is located on the dorsal foot, just below the ankle. The calcaneocuboid joint consists of the calcaneus and the cuboid. It is located on the anterolateral midfoot (Figure 1). The medial longitudinal arch consists of the calcaneus, talus and navicular, as well as the middle, medial and lateral cuneiforms and the first through third metatarsals. The posterior tibial tendon passes behind the medial malleolus and attaches on the navicular tuberosity (bump on the inside of the instep). The flexor digitorum longus tendon is

### LEARNING OBJECTIVES

- ▲ Review the relevant anatomy for this procedure.
- ▲ Examine the step-by-step process of FDL transfer.
- ▲ Compare and contrast the benefits and risks of motion-sparing procedures to arthrodesis.
- ▲ Assess the surgical alternatives and additions to FDL transfer.
- ▲ Evaluate the rehabilitation process after flatfoot surgery.



just behind and adjacent to the posterior tibial tendon. The spring ligament helps to hold up the arch by forming a supportive sling under the head of the talus (Figure 2).

The most common cause of adult-acquired flatfoot is posterior tibial tendon dysfunction (PTTD). The abnormalities of the posterior tibial tendon are divided into stages. In stage one, there is tendonitis or inflammation, but the tendon is of normal length and not torn. In stage two, the tendon is elongated, but the hindfoot remains flexible. The arch of the foot may appear normal in non-weight-bearing position. In weight-bearing positions, however, the arch appears flattened and the heel moves to the outside (valgus deformity). In stage three, the hindfoot deformity of stage two becomes rigid or “fixed.” The hindfoot is everted (valgus) and the forefoot is abducted (pointing to the outside).

### SURGICAL CONSIDERATIONS

Surgical procedures for correction of the flatfoot vary, but can include: medial displacement osteotomy of the calcaneus and transfer of the flexor digitorum longus (FDL) tendon to replace the posterior tibial tendon; spring ligament reconstruction; subtalar arthrodesis; and triple arthrodesis (fusion).

Indications for medial displacement osteotomy of the calcaneus, and substitution of the posterior tibial tendon using the flexor digitorum longus (FDL), are painful PTTD stage two and a flexible flatfoot deformity. Combining the osteotomy with the transfer of the FDL is useful in improving the posture of the foot and gives some mechanical protection to the tendon transfer.

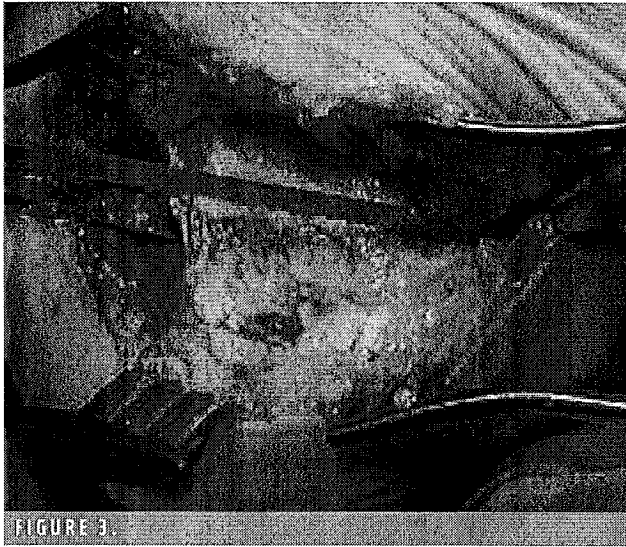


FIGURE 3.

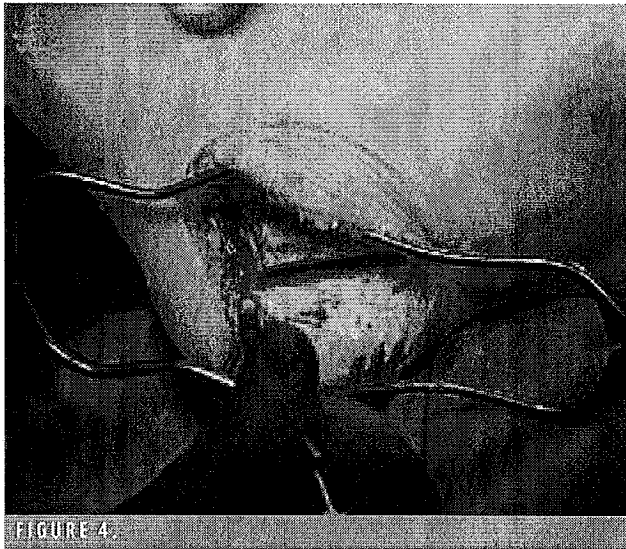


FIGURE 4.

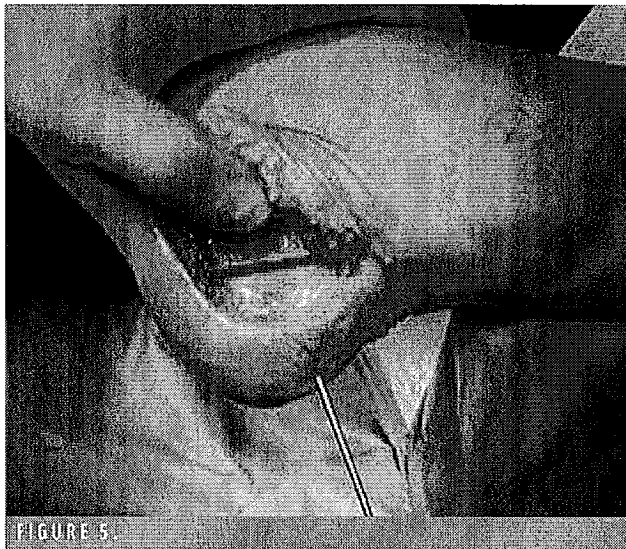

FIGURE 5.

Preoperative preparation includes weight-bearing radiographs consisting of anteroposterior, lateral, and oblique views of the foot. On the lateral view, a sagging of the talonavicular joint may be seen. On the anteroposterior view, an abduction of the foot with increased exposure of the talar head can be seen. It looks like a hat (navicular) is falling off of someone's head (talar head).

#### PROCEDURE

For the procedure, the patient is placed in the supine position on the operating table with two or three rolled sheets (a "bump") under the ipsilateral hip so that the affected side is internally rotated. A thigh tourniquet is applied.

The skin prep is performed and the operative leg is draped to just below the knee. The operative limb is exsanguinated and the tourniquet is inflated. The skin over the lateral heel is incised obliquely parallel and inferior to the peroneal tendons. Dissection is carried down to the bony surface of the calcaneus. The sural nerve is identified and retracted. A sagittal saw is used to create the osteotomy using care not to over-penetrate to the medial side to avoid injury to the neurovascular bundle. The calcaneal tubercle (back of heel bone) is displaced medially about one cm (Figures 3 & 4). The position can be temporarily held with a 0.062 Kirschner wire. A posterior longitudinal incision is made over the heel. A hemostat is used to enlarge the opening to accommodate the fixation screws, which may be solid or cannulated. If cannulated, the guide pin for the screw is advanced across the osteotomy site toward the lateral portion of the calcaneus (Figure 5). A cannulated screw

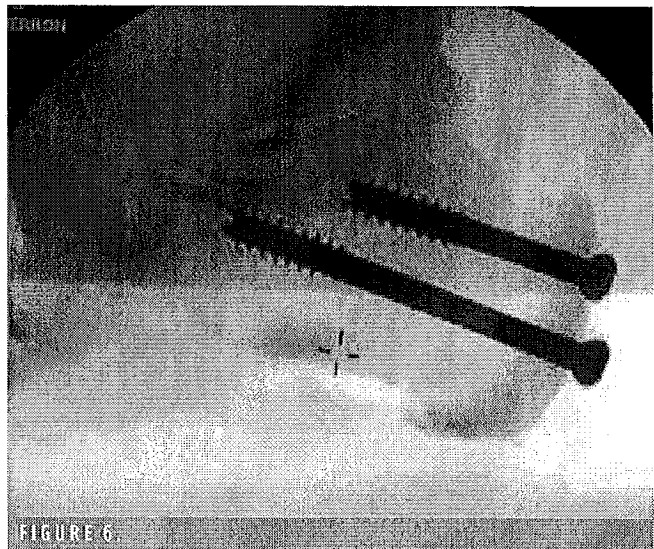
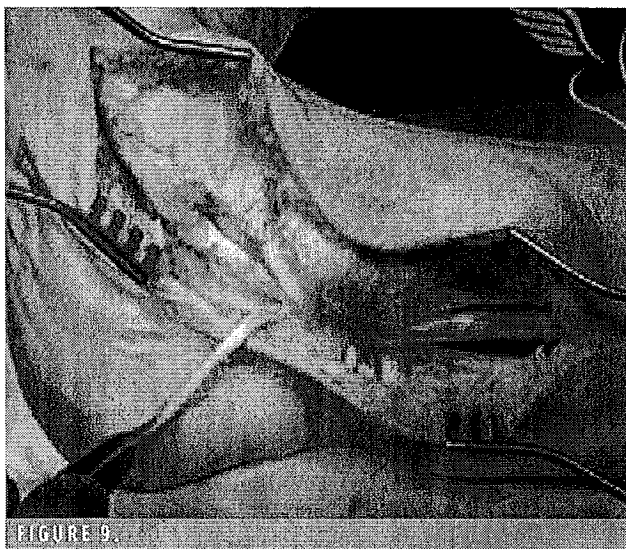
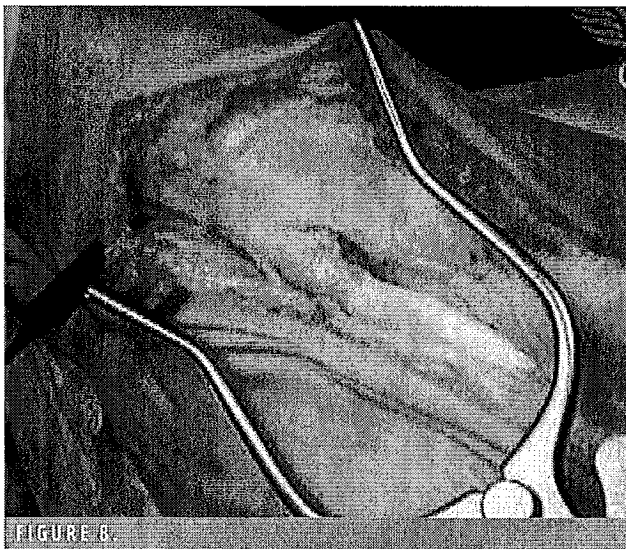
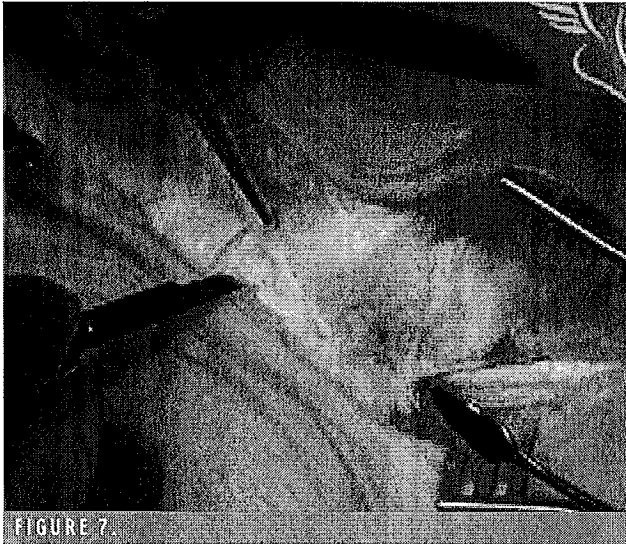


FIGURE 6.

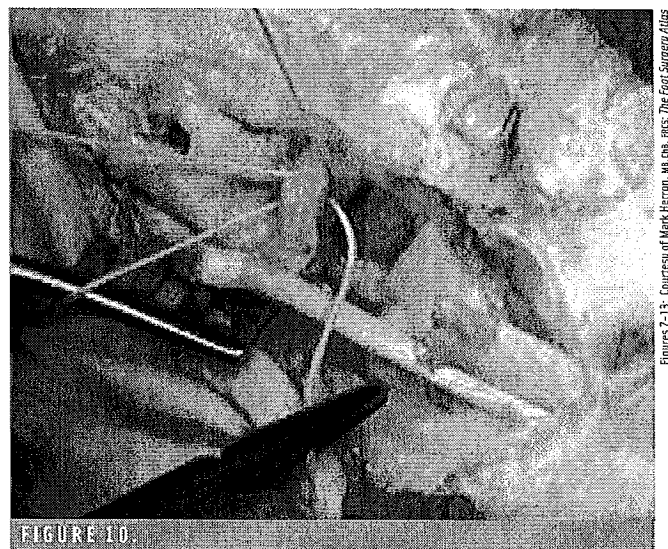
Figures 3-6: Courtesy of Mark Harron, MD, PhD, FRCR, The Foot Surgery Atlas



is inserted across the osteotomy site. The screw placement and osteotomy position is radiographically checked (Figure 6). The wound is irrigated and closed in layers using either a 2-0 or 3-0 absorbable suture for the subcutaneous tissues and 3-0 nylon on the skin.

Attention is then turned to the FDL transfer and the medial side of the foot. At this point, it is helpful to have the “bump” removed from the ipsilateral hip, allowing the foot to externally rotate. An incision is made from a point superior to the tip of the medial malleolus to the navicular along the course of the posterior tibial tendon. The tendon sheath is opened and inspected (Figures 7-8). Increased fluid, fissures, change in color and texture of the tendon can be seen. The FDL tendon is identified and dissected into the midfoot (Figure 9). After the tendon is detached, it will serve to replace the damaged posterior tibial tendon. The posterior tibial tendon is usually debrided. If severe, it is largely excised, but may be saved to attach to the newly-transferred FDL to add to its power. This is called a tenodesis. The surgeon may repair the spring ligament. One method by which this is accomplished is to plicate the ligament using 2-0 fiberwire (Figure 10).

The navicular is exposed dorsally. A drill hole is made going from plantar to dorsal. A 3.2 mm drill can be used first to make a pilot hole. The hole can then be enlarged using a 4.5 mm drill to accommodate the thickness of the FDL. Figure 11 shows the hole in the navicular, which can be seen below the Senn retractor, and the FDL tendon stretched across the navicular. The FDL tendon is passed through the hole from plantar to dorsal. The foot is then



Figures 7-13: Courtesy of Mark Herron, M.D., MCh, The Foot Surgery Atlas

positioned into maximum inversion. The tendon is sutured into the periosteum of the navicular, the surrounding tissues, and to itself using #2 nonabsorbable suture.

Another technique of fixating the FDL tendon is the use of an absorbable biotenesis screw. A 2-0 absorbable suture is stitched to the free end of the FDL starting about 2cm from the end of the tendon so that the ends of the suture (left long) are parallel to the length of the tendon. A long 2.0 drill bit having an eyelet on the opposite end of the flutes of the bit is passed through the navicular from

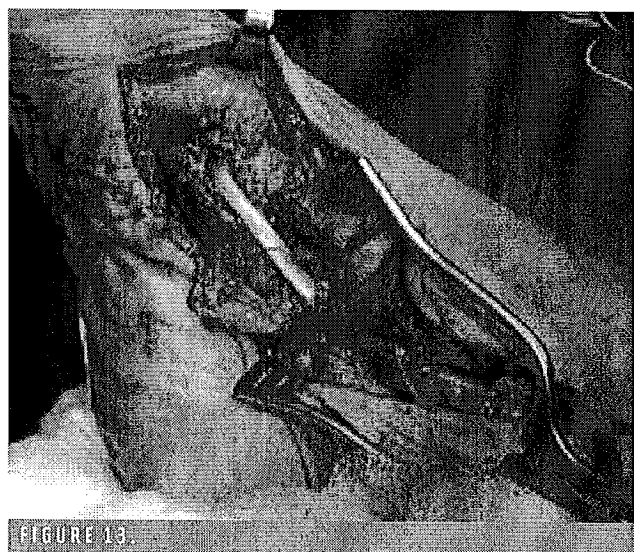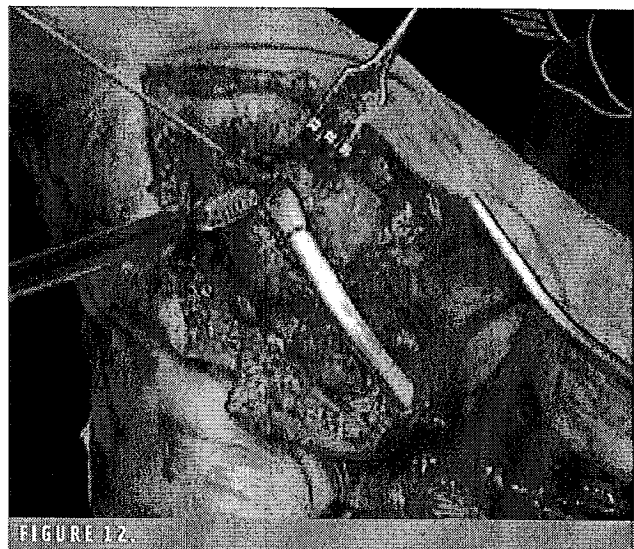
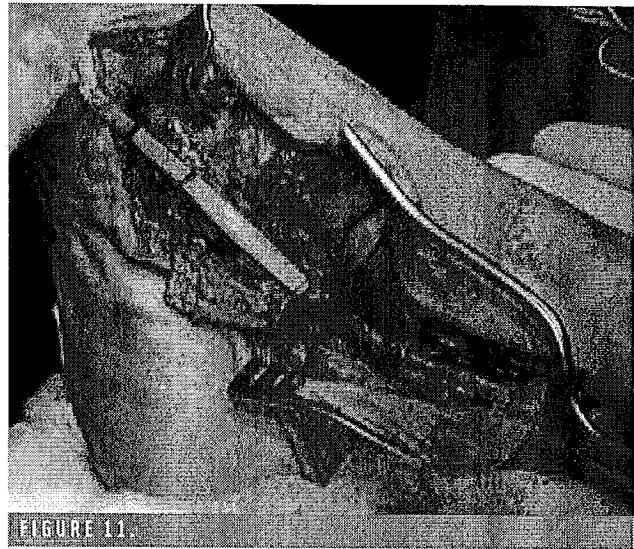
Surgical procedures for correction of the flatfoot vary, but can include: medial displacement osteotomy of the calcaneus and transfer of the flexor digitorum longus tendon to replace the posterior tibial tendon; spring ligament reconstruction; subtalar arthrodesis; and triple arthrodesis.

plantar to dorsal. A cannulated 5.0mm drill bit is passed over the first drill and removed. The long ends of the suture are threaded through the eye of the first bit. The bit is then pulled through the hole in the navicular, feeding the FDL through. A 5.0 bioabsorbable screw is placed in the hole from the plantar side while tension is applied to the sutures and the foot is held in maximum inversion (Figure 12). The suture is cut and the wound is irrigated (Figure 13). A suction drain may be placed. The wound is closed in layers, starting with a 2-0 absorbable suture for subcutaneous tissue and 3-0 nylon for skin.

After closure, the patient is held in a short-let compressive dressing consisting of a wound dressing, a bulky cotton roll, plaster or fiberglass splints, and an over wrap of an elastic bandage. This is done with the foot in inversion to protect the tendon transfer.

#### POSTOPERATIVE

Sutures are removed at two to four weeks and a short-leg, non-weight-bearing cast is applied with the foot still in inversion. The cast is changed intermittently every few weeks after surgery and radiographs are taken to confirm union of the osteotomy site. The patient is eventually allowed to bear weight in a walking cast and then in a



walking boot. After three months, the patient is allowed to gradually discontinue the walking boot and begin unprotected ambulation. Patients are encouraged to begin range-of-motion exercises and are started on physical therapy for strengthening and balance.

Usually, 10-18 months are needed for maximum rehabilitation after the surgery. It is rare to have late failures of the FDL transfer and the functional results of the surgery appear to be durable.

## **SURGICAL ALTERNATIVES**

### *Lateral Column Lengthening*

Another option for patients presenting with stage two PTTD, peritalar subluxation, hindfoot valgus and pain at the distal fibula and lateral calcaneus, is a lateral column lengthening. This is often done through the calcaneocuboid joint with arthrodesis in conjunction with the FDL transfer and a spring ligament repair as described earlier. Iliac

Another option for patients presenting with stage two PTTD, peritalar subluxation, hindfoot valgus and pain at the distal fibula and lateral calcaneus, is a lateral column lengthening.

crest block autograft or structural allograft can be used to lengthen the lateral column.

Anteroposterior and lateral radiographs should be taken. These can show a loss of medial arch height, forefoot abduction, hindfoot valgus, and impingement of the fibula on the calcaneus.

The patient is positioned in supine with a "bump" under the ipsilateral hip to have better access to the lateral side of the foot. A thigh tourniquet is applied. A surgical prep is performed and the leg is draped up to the knee. Consideration must be taken to include concurrent draping of the ipsilateral iliac crest.

A skin incision is made over the calcaneocuboid joint. Care is taken to identify and preserve branches of the sural nerve. The extensor digitorum brevis muscle is reflected dorsally from its inferior margin. The peroneal tendons are retracted dorsally. A lamina spreader is inserted into the calcaneocuboid joint and the cartilage is removed from the joint using an osteotome, curettes, and ronguer. An osteotome may be used to shingle the subchondral bone. This is

when the subchondral bone is slightly raised up in multiple places in such a manner that it looks like shingles on a roof. This is thought to aid in the fusing of bone. Likewise, subchondral bone can also be prepared for fusion by using a 2.5-3.5 drill bit and drilling multiple holes.

A lamina spreader is placed in the joint and distraction is applied. Adduction of the forefoot and restoration of the medial longitudinal arch can be observed with this maneuver. Intraoperatively, an anteroposterior image using fluoroscopy is used to assess the coverage of the talar head by the navicular. When the desired coverage is reached then a measurement of the distraction of the calcaneocuboid joint is taken. It usually ranges eight to 12mm.

From the ipsilateral hip, a tricortical graft is taken and contoured into a trapezoidal shape in order to create a wedge. This graft is impacted into place using a bone tamp. Further stabilization is achieved with the use of a small plate.

The iliac crest wound is irrigated and closed in layers with 0 polyglactin 910, 2-0 polyglactin 910 and 3-0 nylon. The calcaneocuboid wound is irrigated and closed in layers with 2-0 polyglactin 910 and 3-0 nylon.

### **POSTOPERATIVE**

The bump is removed. The spring ligament repair and FDL transfer are

completed in the manner previously described with the foot held in supination by the assistant.

After the wounds are closed, a splint is applied maintaining supination of the foot. The postoperative care is followed as described in the previous procedure.

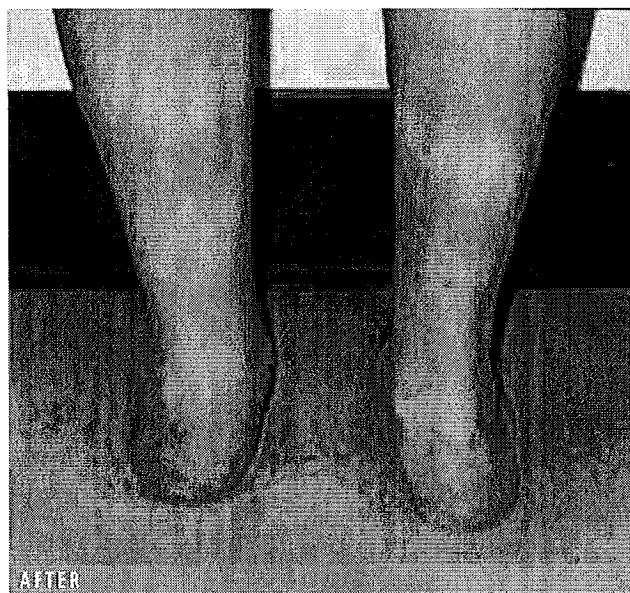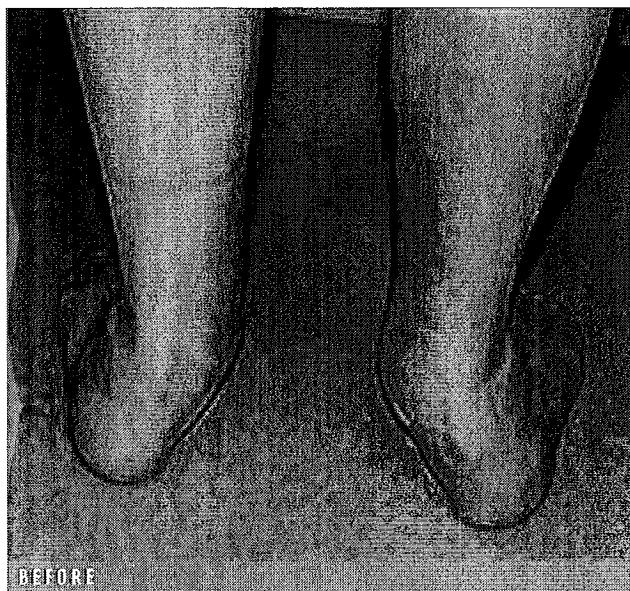### *Subtalar Arthrodesis*

There are some patients for whom the previously-described procedures are not an option due to the presence of arthritis in the subtalar joint or because the subtalar joint is fixed with the hindfoot in valgus. In such cases, a subtalar arthrodesis may be appropriate. It can be an applicable procedure when other hindfoot reconstruction operations have failed such as medial calcaneal osteotomy, posterior tibial tendon reconstruction with FDL transfer, or spring ligament repair.

Preoperative preparation includes radiographs like those outlined for the above-mentioned procedures.

For surgery, the patient is positioned supine with a "bump" under the ipsilateral hip in order to internally rotate the extremity. A thigh tourniquet is applied.





After prepping and draping is complete and the tourniquet has been inflated, the incision is made starting at the tip of the lateral malleolus and continuing toward the base of the 4th metatarsal. The calcaneal attachment of the extensor digitorum brevis muscle is dissected to create a distally-based flap, allowing exposure to the calcaneocuboid joint. The peroneal tendons and sheath are retracted inferiorly. A lamina spreader is inserted into the sinus tarsi to aid exposure of the articular surfaces. Cartilage is removed using osteotomes, curettes, and ronguer until the subchondral bone is exposed. The subchondral bone is prepared for fusion using a 3.2 drill bit to drill multiple holes. A guide

wire from a 7.0 cannulated set is passed through a longitudinal incision in the heel through the posterior facet of the calcaneus into the talus, allowing for five to seven degrees of valgus. Using a depth gauge, a measurement is taken to determine the length of the screw to be placed. A cannulated drill bit is passed over the guide wire. A partially-threaded screw with a diameter of 7.0 mm having the length somewhat shorter to that shown on the depth gauge is inserted. The reason for using a shorter screw than what is shown on the depth gauge is to allow for compression of the fusion site without having the undesirable effect of the screw protruding.

When a screw is placed through the posterior facet into the talus, it is likely to have a thread length of 16mm due to the height of the talus. Conversely, a 32mm thread length can be used when the screw is placed dorsal to plantar through an incision over the talar neck due to the height of the calcaneus and the angle at which the screw is placed.

The stability is tested and fluoroscopy is used to do a final check on screw and hindfoot placement.

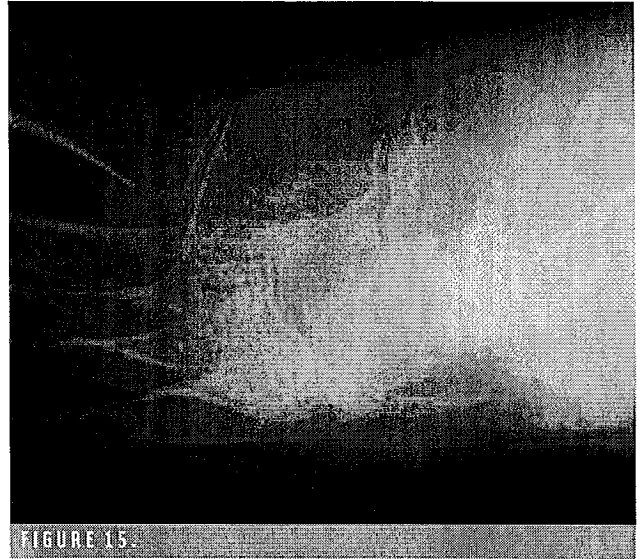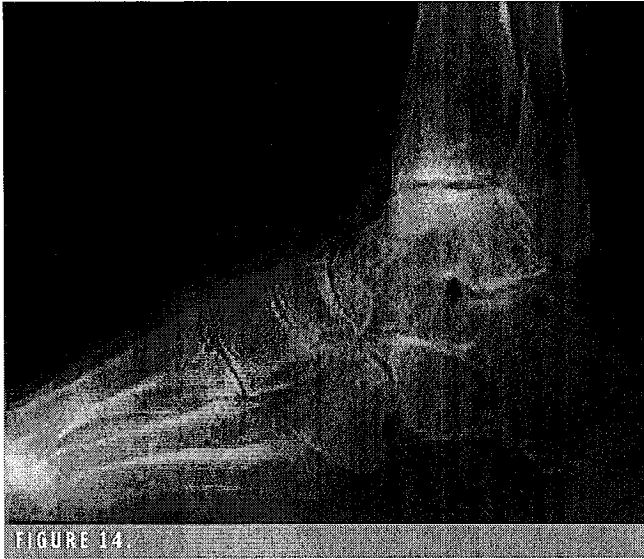Bone graft may be taken from the proximal tibia using curettes and small osteotomes. If so, it is placed into the fusion site before insertion of the screws. The extensor digitorum brevis muscle is reapproximated over the bone graft and the wound is irrigated and closed in layers using 2-0 polyglactin 910 and 3-0 nylon.

#### POSTOPERATIVE

A splint is applied and the patient is made non-weight-bearing. After three weeks, the sutures are removed and a short-leg, non-weight-bearing cast is applied. A walking cast is applied at six to eight weeks postoperatively, and for an additional four to six weeks until evidence of arthrodesis union can be seen radiographically.

Foot and ankle rehabilitation starts after bone healing is complete and the final cast is removed. Patients can expect to have some swelling and aching for many months.

The success rate of this procedure is high for patients having PTTD and flatfoot; however, there are some patients who have more severe deformity and/or arthritis requiring a more extensive procedure such as a triple arthrodesis. Patients having a fixed hindfoot deformity, such as that resulting from posterior tibial tendon rupture with an acquired flat foot, as well as painful arthritis in the hindfoot and the tarsal joints, may need this procedure.



**Triple Arthrodesis**

A routine foot and ankle examination and radiographs should be done. These include weight-bearing anteroposterior foot, lateral foot and anteroposterior ankle views (Figures 14 & 15). Also useful are views of oblique foot and mortise of the ankle.

As GEA opened the door for better treatments in women's health, it also opened a door to more career choices for surgical technologists. The office-based procedure provides a different route of employment for surgically-trained personnel.

For surgery, the patient is positioned, prepped and draped in the same manner as with a subtalar arthrodesis.

The incision starts from the distal fibula and runs to the base of the 4th metatarsal. The subtalar joint is prepared as described previously. The calcaneocuboid joint is prepared next using osteotomes, curettes, and ronguer while it is held open with a lamina spreader. The next to be prepared is the talonavicular joint through an anteromedial incision at the level of the talar neck. It is prepared in the same fashion as the subtalar and the calcaneocuboid joints except that a toothless lamina spreader may be used to hold the joint open. With all three joints, the subchondral bone is drilled multiple times. Bone graft is placed in all the fusion sites prior to and following insertion of hardware. Can-

nulated screws are placed across the subtalar joint in the manner previously described. The talonavicular joint can be stabilized using cannulated or solid screws. The screw is placed at a shallow angle in the medial-lateral plane in a retrograde direction. It is important to countersink the entrance hole in the navicular in order to not break the

bridge of bone as the screw is tightened. It is important to be sure to hold the talonavicular joint in a reduced position so as to restore the medial longitudinal arch and obtain the correct balance of adduction-abduction and varus-valgus.

The calcaneocuboid joint is stabilized similarly. The screw is placed from the anterior process of the calca-

neus into the cuboid (Figures 16 & 17).

Another approach that is used in fusing the talonavicular and calcaneocuboid joints is the use of compression plates. This technique is accomplished with plates that allow one to two screws being placed through the plate that spans the joint. Once the screws are placed, the plate is spread open

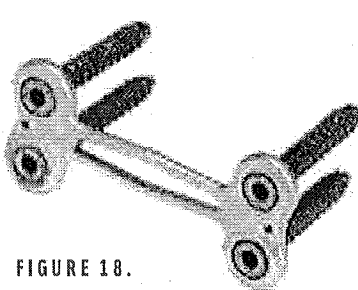
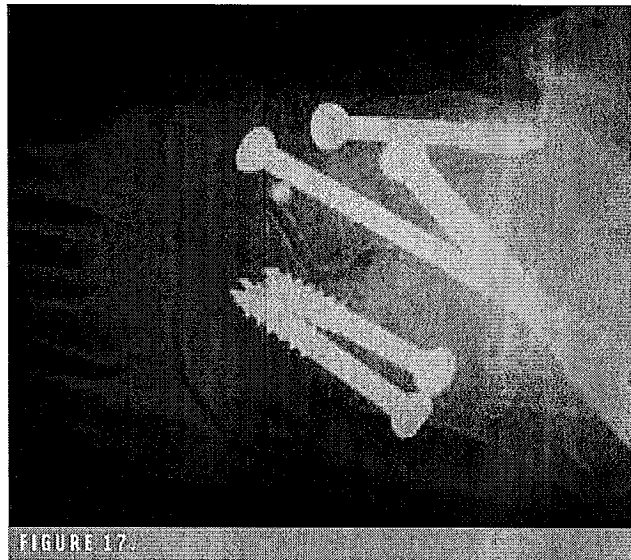
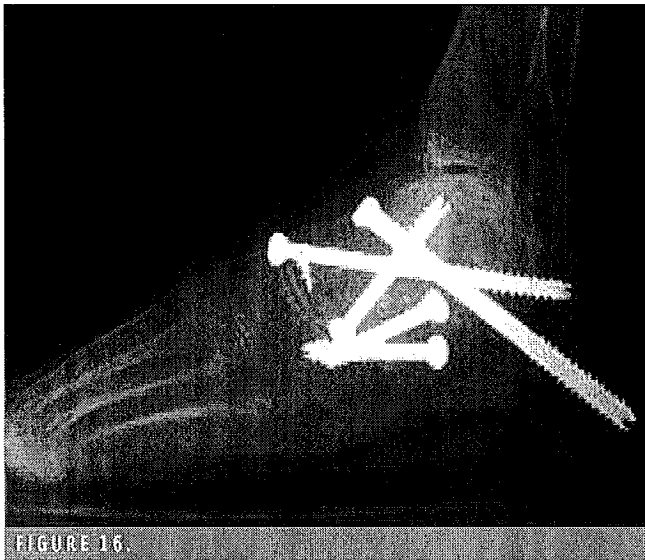


FIGURE 18.

causing compression of the joint (Figure 18). Even though this is not as common a technique as the one previously described, it's known to be used with a good post-operative result.

Figures 16, ©Integra LifeSciences Corporation 2009. Reprinted with permission.



Figures 14-17. Courtesy of James Bradsig, MD

Fluoroscopy is used to check fixation placement and alignment. The extensor digitorum brevis muscle is reapproximated using 0 polyglactin 910 . The wound is irrigated and closed in layers using 2-0 polyglactin 910 and 3-0 nylon. A bulky splint is applied to allow for swelling.

#### POSTOPERATIVE

At the first follow-up visit, the splint and sutures are removed. A short leg cast is applied. The patient is to remain non-weight-bearing for six weeks following surgery. At six weeks, if the fusion sites have healed and there is no tenderness in those areas, the patient is allowed to wear shoes and increase activities as tolerated.

There are some possible complications of attempted arthrodesis, including nonunion of the talonavicular joint, occurring in 5-10 percent in most of the reported series in literature. This can be decreased with care in meticulous removal of cartilage and fibrotic bone. Also, the use of cancellous autograft can improve fusion rates. There is a risk for malalignment, usually occurring at the time of surgery. Careful alignment of the joints at the time of surgery helps to avoid malalignment.

#### CONCLUSION

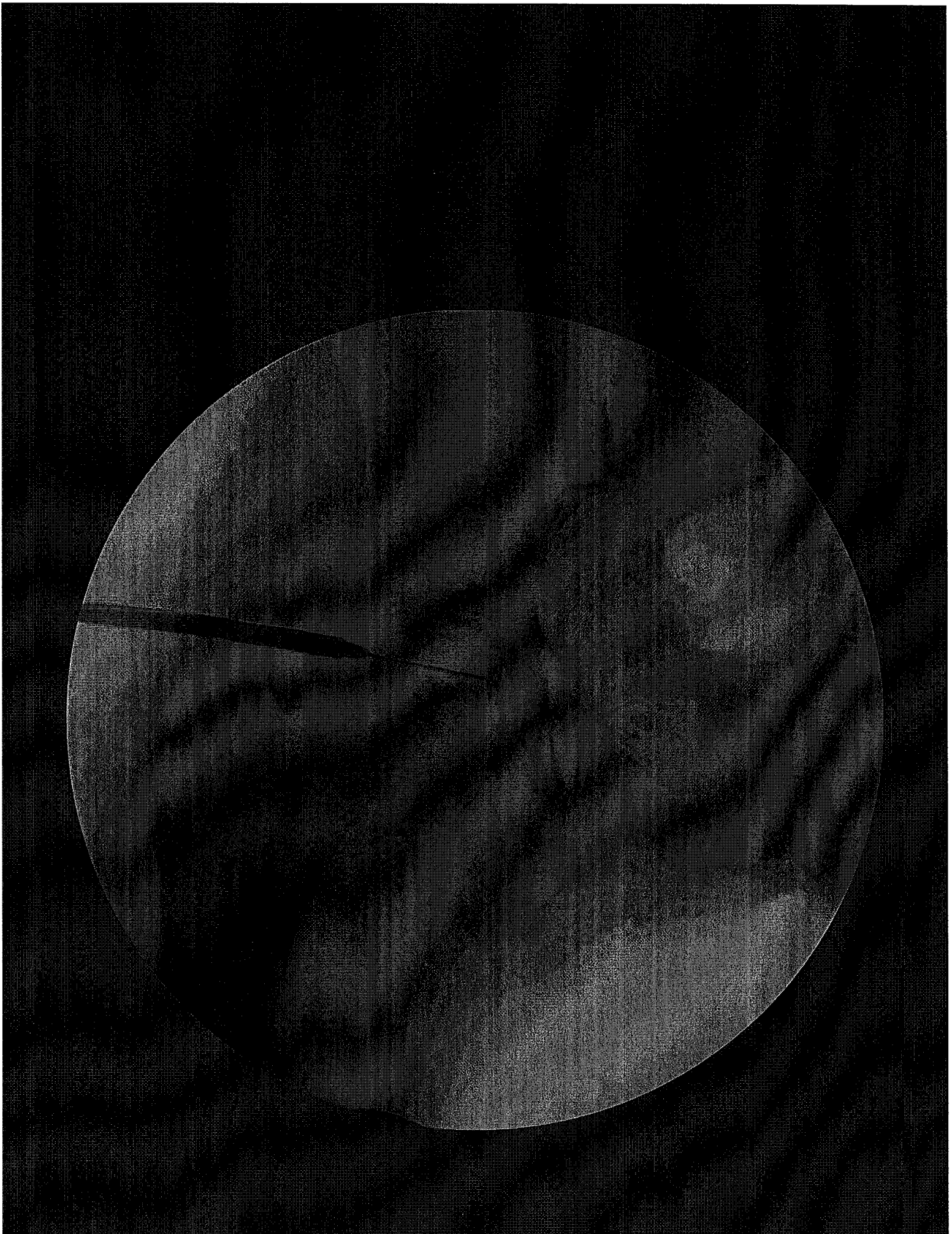Whenever possible, it is best to do motion-sparing procedures, as described earlier in this article as a first option. As long as there is no painful arthritis or lack of mobility in the hindfoot or tarsals, procedures such as medial displacement calcaneal osteotomy with FDL transfer or lateral column lengthening are motion-sparing and more

often preferred. Subtalar arthrodesis and triple arthrodesis should be reserved for patients having painful arthritis or fixed flatfoot with PTTD. It is also useful to reserve them as a secondary option for salvage procedures when the above-mentioned fail.

#### ABOUT THE AUTHOR

Angela Webb, CST, attended Career West Academy in California, where she majored in surgical technology. After completing her clinical training in Texas, in 1995, she worked at Baylor University Medical Center as a Certified Surgical Technologist. Ms Webb has specialized in orthopaedics for 12 years, focusing primarily on foot and ankle procedures, as well as shoulders. She currently works full-time at Mary Shiels Hospital in Dallas.





# Hip Arthroscopy:

## TREATING FEMOROACETABULAR IMPINGEMENT

by Margaret M Armand, CST  
with contributions by  
Benjamin G Domb, MD and Rima Nasser, MD

**HISTORY** Hip arthroscopy is a rapidly-evolving field in orthopedic surgery.<sup>1</sup> Similar to arthroscopic knee and shoulder surgery, hip arthroscopy involves an arthroscope inserted into the hip joint space. Its history is brief. Minimally used in the late 1980s, due to limitations in the understanding of the joint pathology and techniques, hip arthroscopy has seen a surge in technical developments since the mid 1990s and has enabled surgeons to begin treating a variety of painful hip conditions.<sup>2,3</sup>

**A**s the understanding of arthroscopic anatomy, indications, potential complications and techniques has evolved, hip arthroscopy has become a successful treatment method for a variety of hip pathologies.<sup>2,3</sup>

Arthroscopic hip surgery can address a variety of painful hip conditions, including labral tears, loose bodies, ligamentum teres femoris injuries, capsular laxity, chondral deformities, coxa saltans (clicking hip), and femoroacetabular impingement.<sup>2,4,5,6</sup> While it does not allow for a 360-degree view of the joint, like the more commonly-used open procedure, most pathological structures can be visualized and repaired using the arthroscopic approach. This procedure is preferable for repair because, if performed correctly, it is less invasive, less traumatic, and has a shorter recovery time than open surgery.<sup>7,8</sup> Patients of all ages and activity levels tend to prefer an arthroscopic operation because of this. Hip arthroscopy is especially popular with athletes because it may allow for a quicker return to competition.

### LEARNING OBJECTIVES

- ▲ Review the relevant anatomy for this procedure
- ▲ Examine the set-up and surgical positioning for this procedure
- ▲ Compare and contrast the osteoplasty-cam procedure and the acetabuloplasty-pincer procedure.
- ▲ Assess the indications for femoroacetabular impingement
- ▲ Evaluate the recovery and rehabilitation process following FAI

## ANATOMY OF THE HIP

The hip is a ball and socket joint. The arrangement of bones, ligaments and muscles allow for a variety of movements and a large range of motion. The hip joint consists of the bones of the pelvis and the femur, ligaments and tendons, muscles, nerves and blood vessels. Three fused bones; the ischium, ilium, and pubis provide the frame of the pelvis. The head of the femur fits into the acetabulum formed where the three parts of the hip bone converge. The bony surfaces are lined with articular cartilage which allows for smooth movement of the bones in the joint.

Covering the rim of the acetabulum is a fibro-cartilaginous structure called the labrum. The labrum helps to create a suction seal for the joint surfaces. This labrum has several purposes, including aiding joint stability and helping to control the ingress and egress of synovial fluid. If the socket or acetabular contour is too deep, or the head/neck junction of the femoral head is irregular, this excessive bone growth can cause impingement of the labrum.<sup>6</sup>

Three large ligaments support the hip capsule and keep the hip in place. Anteriorly, the iliofemoral ligament is attached at the iliac spine of the hip bone to the inter-

hamstrings: biceps femoris, semitendinosus and semimembranosus, and the gluteus maximus. The piriformis, obturator internus, obturator externus, the superior and inferior gemellus muscles and the quadratus femoris muscle function as lateral rotators of the hip. The adductor muscles include the adductor longus, adductor brevis and the adductor magnus with the pectineus and gracilis muscles.<sup>9</sup>

Innervation is primarily provided by the femoral nerve anteriorly and the sciatic nerve posteriorly.<sup>10</sup> The obturator nerve also passes through the hip. The femoral nerve innervates the flexor muscles of the thigh, the extensor muscles of the leg and the skin of the medial and anterior aspect of the thigh. The sciatic nerve supplies the posterior and lateral aspects of the thigh. The lateral cutaneous nerve affects the skin of the lateral, anterior and posterior aspects of the thigh.<sup>9</sup>

The blood supply to the hip is from the femoral arteries that run anteromedial in the thigh. The femoral artery has a deep branch called the profunda femoris, which supplies blood to the hip joint capsule.<sup>10</sup> Within the ligamentum teres is a smaller vessel that supplies blood to the femoral head. The blood return is through the great saphenous and femoral veins.<sup>9</sup>

Twenty-seven muscles cross the hip that control movement and help propel the human body.<sup>6</sup> The majority of these muscles originate on the pelvic girdle and insert along the femur.

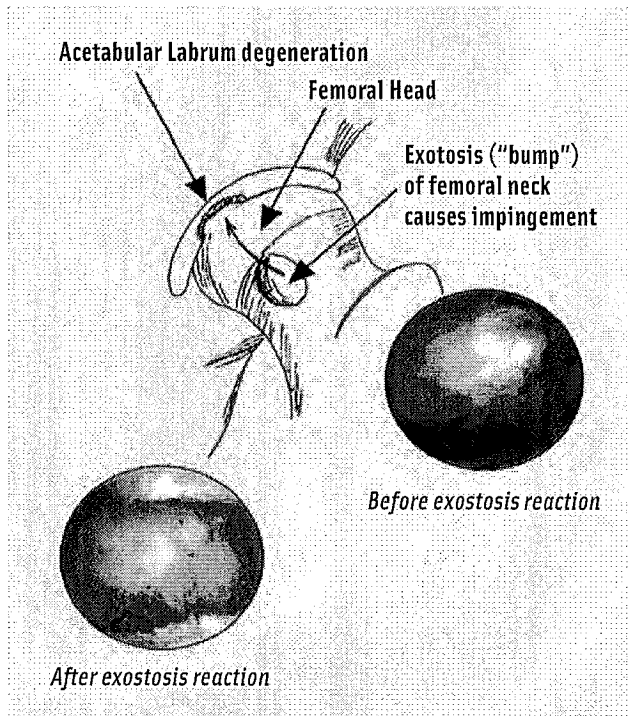
## FEMOROACETABULAR IMPINGEMENT (FAI)

Many times, it is abnormal anatomy that causes impingement. In cases where there is a wide lip of bone on the socket, or over-coverage in one area, this bone pinches against the labrum and the femoral head-neck

trochanteric line of the femur, the pubofemoral ligament is attached at the pubic part of the acetabular rim to the neck of the femur, and posteriorly, the ischiofemoral ligament is attached at the ischial wall of the acetabulum to the neck of the femur. These ligaments form the hip joint capsule, which is filled with synovial fluid that lubricates the articulating bones of the joint and allows the hip to move freely. A smaller ligament, the ligamentum teres, attaches from the fossa of the acetabulum to the head of the femur.<sup>9</sup>

Twenty-seven muscles cross the hip that control movement and help propel the human body.<sup>6</sup> The majority of these muscles originate on the pelvic girdle and insert along the femur. Major flexors include the four muscles of the quadriceps muscle: the rectus femoris, vastus lateralis, vastus medialis, and vastus intermedius along with the sartorius muscle. Extensors include the three muscles that form the

junction. An extra bony growth on the femoral neck causes a deviation from the normal sphericity of the femoral head. This also leads to increased pinching and damage to the labrum and acetabular rim cartilage.<sup>6</sup> Femoroacetabular impingement (FAI) is a painful hip condition where the labrum of the acetabulum becomes impinged between an abnormally-shaped femoral head-neck junction and/or a deep or overhanging rim of the acetabulum during flexion, adduction and internal rotation.<sup>4,9</sup> The pain may be caused by the repetitive tearing or crushing of the labrum, or through bone-on-bone contact of the femoral head-neck junction and the acetabulum.<sup>9</sup> There are two types of FAIs: cam impingement from the femur and pincer impingement from the acetabulum.<sup>3,8,9,10</sup> While these may occur independent of each other, it has been shown that combined impingement occurs in 86 percent of the cases.<sup>4</sup>



An extra bump on the femoral head can cause a deviation from the normal sphericity of the femoral head, leading to increased friction and damage of the acetabular rim cartilage. The condition that results has been termed femoroacetabular impingement (FAI).

## DIAGNOSIS

Preoperative planning is important for identifying patients who will benefit from arthroscopic hip surgery. While some patients with hip pain respond to more conservative treatments, such as therapy, rest and non-steroidal anti-inflammatory drugs (NSAIDs), some have pain that can only be treated by surgery.<sup>2,6</sup> In patients with persistent symptoms, a carefully-elicited history and physical examination may suggest various anatomical and pathological processes.<sup>2</sup> A challenging goal of the physical examination is to determine if the pain is of intra-articular or extra-articular origin.<sup>4,2</sup> In order to discover this, "[t]he history should include the qualitative nature of the discomfort (clicking, catching, stiffness, instability, decreased performance, and weakness), the location of the discomfort, onset of symptoms, and any history of trauma or developmental abnormality."<sup>4</sup>

Extra-articular causes of hip pain, including sacroiliac joint pathology, stress fractures, trochanteric bursitis,

occult hernias and tendon injuries (iliopsoas, piriformis, rectus hamstring or adductor) occur more frequently than intra-articular causes of hip pain.<sup>2,11</sup> Lateral thigh pain is typically due to trochanteric bursitis, and posterior buttock and sacroiliac pain is usually due to spinal or sacroiliac conditions.<sup>2,6</sup>

Since most hip joint pathology is found within the intra-articular region, distraction is necessary to achieve arthroscopic access.<sup>1</sup> Determining the signs and symptoms that suggest intra-articular pathology are essential in differentiating patients who may benefit from hip arthroscopy.<sup>2</sup> The presence of groin pain and /or anterior thigh pain extending to the knee is a significant indicator, especially if the pain is activity related.<sup>2,8,9,10</sup> In the case of FAI, presenting pain is commonly felt when the hip is flexed, adducted and internally rotated (the FADDIR test.)<sup>1,4</sup> During these movements, the labrum becomes impinged between the bony structures. Repetitive movements cause tearing or crushing of the labrum which can be quite painful.

Radiographic imaging, three dimensional imaging from computed tomography (CT) scans, and magnetic resonance imaging (MRI) are useful in determining the pathology of the hip. Many times, bone irregularities of the acetabular rim are noted on a radiographic image. The three dimensional imaging from a CT scan can give detail on bone growths and calcified loose bodies in the joint and show abnormalities to the head neck junction of the femur.<sup>2,6</sup> MRI studies are best for soft tissue problems.<sup>6</sup> Therefore most tendon and labral tears can be viewed with an MRI scan or with an MR arthrogram.<sup>6</sup>

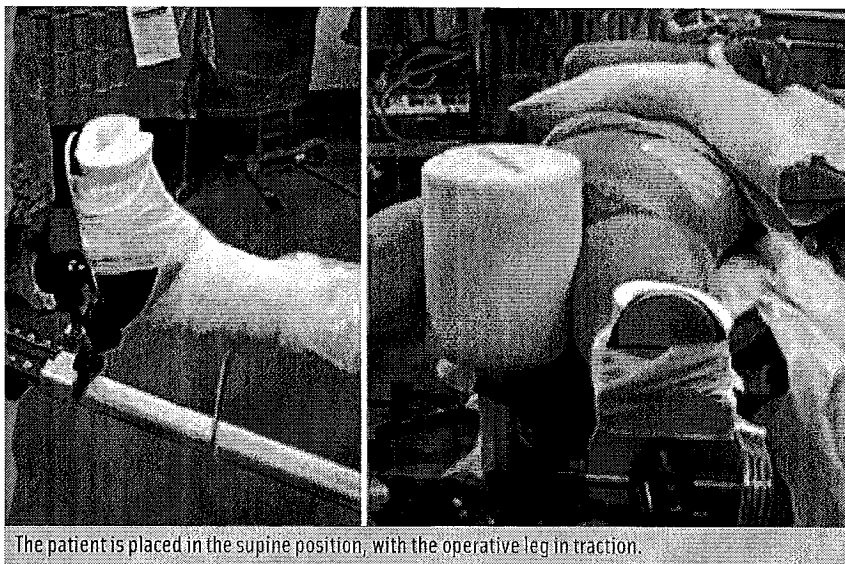
Since most hip joint pathology is found within the intra-articular region, distraction is necessary to achieve arthroscopic access.<sup>1</sup> Determining the signs and symptoms that suggest intra-articular pathology are essential.

## SURGICAL POSITIONING

Patients undergoing arthroscopic hip procedures are placed in the supine or lateral position.<sup>1,2,3,7</sup> Both positions are equally effective. The choice is made by surgeon preference. For some surgeons, the supine position may be advantageous for ease of positioning, while lateral position may be preferable for obese patients.<sup>1,2,3</sup> When patients are placed

in a supine position, a custom leg distraction device is attached to the operating table. The patient is positioned against a wide peroneal post with feet in distraction boots securely taped in place with three-inch silk tape. The ipsilateral arm is placed across the chest and the contralateral arm is placed on an arm board. Complete relaxation is necessary to achieve distraction and the patient is completely paralyzed to prevent any movement during the procedure so that when sharp objects are placed within the joint harm is not caused by sudden movements.<sup>7</sup>

The patient's operative leg is placed under traction to open up the joint, providing space to work.<sup>1,3,6</sup> This is visualized under fluoroscopy.<sup>1,6</sup> The lower limb is placed in slight flexion (approximately 10-20 degrees) with the foot maintained in neutral to slight internal rotation.



The patient is placed in the supine position, with the operative leg in traction.

The peroneal post is pushed against the medial portion of the thigh of the involved leg, keeping the post away from the branch of the pudendal nerve that crosses over the pubic ramus.<sup>1,2,3,7,8</sup> Distraction is achieved carefully until the "vacuum phenomenon" is seen on the X-ray.<sup>3,8</sup> Adequate visualization requires the femoral head to be distracted from the acetabulum with a goal of seven-10 mm between their articular surfaces.<sup>2,7,8</sup>

The patient is prepped from waist to knee on the affected leg and from the midline of the abdomen to as posterior as possible using alcohol first, then with a Chloraprep<sup>®</sup> solution. Draping involves four adhesive drapes placed first at the iliac crest, mid-thigh, as anterior and as close to the peroneal post as possible and, finally, as posterior as pos-

sible followed by an isolation drape. The adhesive portion of this drape is placed over the incision site and the remainder is placed over the patient.

#### SCRUB NOTES

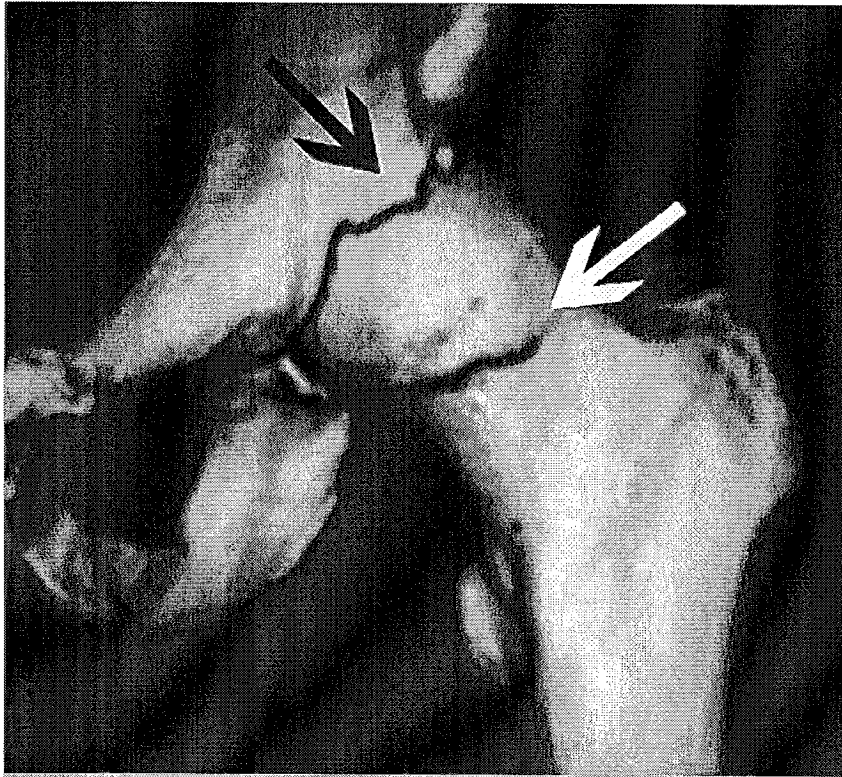
The surgical technologist stands toward the patient's head, and the first of two Mayo stands is placed over the patient's chest. This Mayo stand holds the cords necessary for the procedure: a long, 70-degree arthroscope with camera, light cord, and fluid inflow, as well as an arthroscopic shaver with suction and a radio frequency Ablator wand. The second Mayo stand abuts the first and holds the necessary instrumentation: a #11 blade for the initial incisions, a long, narrow-handled, curved beaver blade; two specially-designed, long spinal needles; a flexible guide wire; two hip trocars, 4.5 mm and 5.0 mm; two cannulated switching sticks; two slotted cannulas for exchanging instrumentation; and an arthroscopic probe.

#### SURGICAL PROCEDURE

The first step in the procedure includes placing portals using spinal needles and a flexible guide wire. Two portals are typically used: an anterior and an anterolateral.<sup>4</sup> The anterolateral portal is placed laterally over the superior margin of the greater trochanter at its anterior border.<sup>1</sup> This portal is established first, as it lies most centrally within the safe zone for arthroscopic hip surgery and penetrates the gluteus medius.<sup>1,2</sup> "The anterior portal is placed at the site of intersection of a sagittal line drawn distally from the anterior superior iliac spine and a transverse line across the tip of the greater trochanter."<sup>1,2</sup> This portal penetrates the sartorius and the rectus femoris.<sup>2</sup> Other portals may be used as necessary, including posterolateral or distal lateral accessory ports. When placing the anterolateral portal, one must be extremely careful of the lateral cutaneous nerve, and when establishing the posterolateral portal, one must consider the posterior neurovascular bundle.<sup>3,7</sup> The femoral artery and nerve lie well medial to the anterior portal and the sciatic nerve lies posterior to the posterolateral portal.<sup>1</sup>

Specially-designed instruments are used to reach the depth of the hip joint, including a long spinal needle and a flexible guide wire.<sup>3</sup> Special care must be taken to avoid





**FIGURE 1.** Three-dimensional computed tomography reconstruction of the hip revealing extensive anterolateral cam impingement (white arrow) and pincer impingement (black arrow).

penetration of the acetabular labrum or causing damage to the femoral head.<sup>1,3</sup> As the surgeon uses the spinal needle to penetrate through the capsule into the joint space, there is a palpable decrease in resistance.<sup>3</sup> However, if the needle is directed into the labrum the resistance felt is greater.<sup>3</sup> Once the surgeon positions the spinal needle, air is introduced into the joint space by removing the stylet. The needle is removed and then redirected to the correct location in the joint space.

Next, the surgeon feeds a guide wire through the spinal needle, and the spinal needle is removed.<sup>11</sup> After the surgeon positions the guide wire in the joint, a cannulated trocar is used to penetrate the joint capsule.<sup>1</sup> Either a 30-degree or a 70-degree long arthroscope can be used.<sup>1,3,4,7</sup> Use of a 70-degree scope allows for a nearly-complete visualization of the joint. Once the scope has been introduced into the joint capsule, it will aid the placement of the other portals. To improve visualization and increase access within the joint, the surgeon may perform

a capsulotomy using a curved beaver blade on a long, narrow handle.<sup>14</sup>

During the procedure, an initial diagnostic arthroscopy is performed and the structures of the hip joint are examined.<sup>1</sup> The femoral head is observed for chondral deformities or damage, as well as the surface of the acetabulum, the condition of the labrum and the ligamentum teres. An arthroscopic probe is used to examine the condition of the chondral-labral junction of the acetabulum.

#### LABRAL PATHOLOGY

The labrum is a fibrocartilaginous structure attached to the rim of the acetabulum.<sup>4,10</sup> The rim consists of a triangular shaped “tongue” of bone to which the labrum is attached.<sup>9</sup> The labrum creates a type of suction seal, limiting fluid expression from the joint space, protecting the cartilage layers of the hip and acting as a joint stabilizer.<sup>4</sup> Proprioceptive and nociceptive nerve fibers run through the labrum, so pain is felt when it is impinged by the bony structures of the acetabular rim or the femoral neck.<sup>8,9</sup> The articular surface of the labrum has decreased vascularity.<sup>4,7</sup>

During the procedure, an initial diagnostic arthroscopy is performed and the structures of the hip joint are examined.<sup>1</sup> The femoral head is observed for chondral deformities or damage, as well as the surface of the acetabulum, the condition of the labrum and the ligamentum teres.

Two types of labral tears have been identified.<sup>12</sup> A primary tear, or type 1 tear, is a detachment of the labrum from the rim of the acetabulum, commonly caused by a cam impingement. A type 2 tear is an intrasubstance tear of the labrum, typically caused by a crushing of the labrum against the neck of the femur by an overhanging rim of the acetabulum, also called a pincer lesion.<sup>4</sup>

Debridement, or repair of the labral defect, is dependent on the causes of impingement and the severity of the tear. "The goal of surgical treatment of labral tears is to eliminate any unstable tissue by debridement or repair, while preserving as much healthy tissue as possible to allow the labrum to maintain its role as a suction seal and secondary joint stabilizer."<sup>4</sup> If the labrum is detached from the rim, a repair may be necessary and a suture anchor repair is used. If the labrum remains attached and the majority of the substance is intact, there is a possibility that a debridement with a shaver is adequate.

In order to prevent a possible fracture, a resection of less than 30 percent of the head-neck junction is recommended because this has been shown not to alter the load-bearing capacity of the femoral neck.<sup>4,8</sup>

#### ACETABULOPLASTY-PINCER PROCEDURE

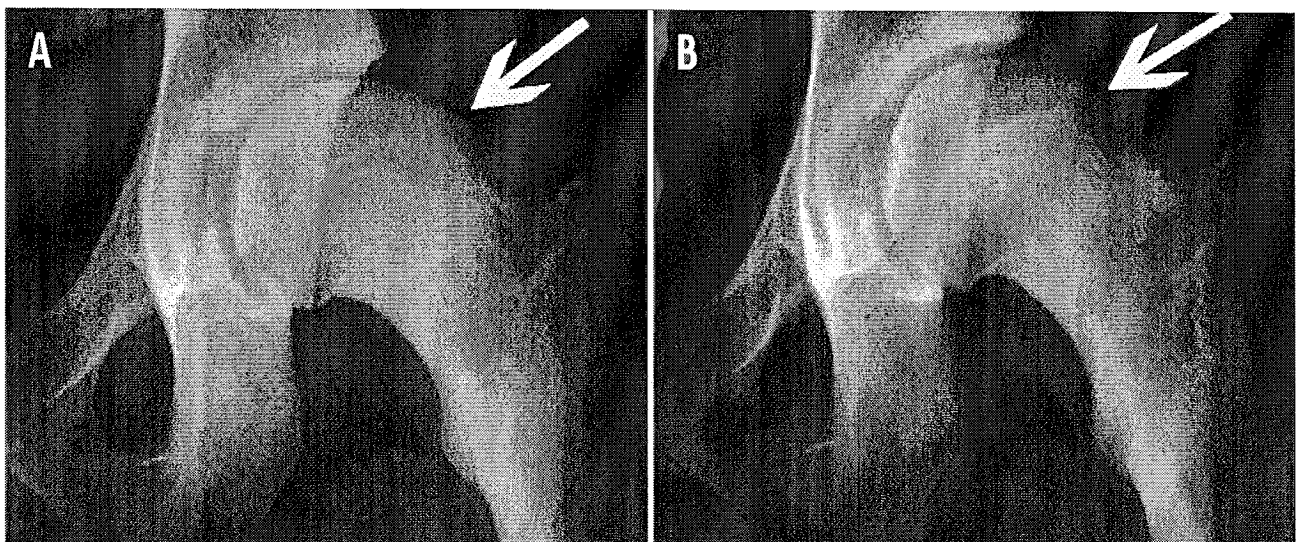
In cases where there is over-coverage of the acetabular rim, or a "deep" acetabular fossa, damage may occur to the labrum caused by its impingement between the rim and the femoral neck during flexion.<sup>1,3,8,9,10</sup> Larger pincer lesions usually result in an intrasubstance tearing of the labrum, necessitating an acetabuloplasty.<sup>4</sup> Depending on the size of the pincer lesion, the labrum may or may not need to be detached from the

rim.<sup>4,9</sup> If detachment is necessary, the labrum is detached using a curved beaver blade on a long handle. The acetabuloplasty is performed using a motorized burr.<sup>8</sup> Progress is monitored with radiographic imaging. It is not recommended to resect greater than 5 mm of acetabular rim as it may cause instability.<sup>4,8</sup> A suture repair is performed if detachment is necessary.<sup>4,8</sup>

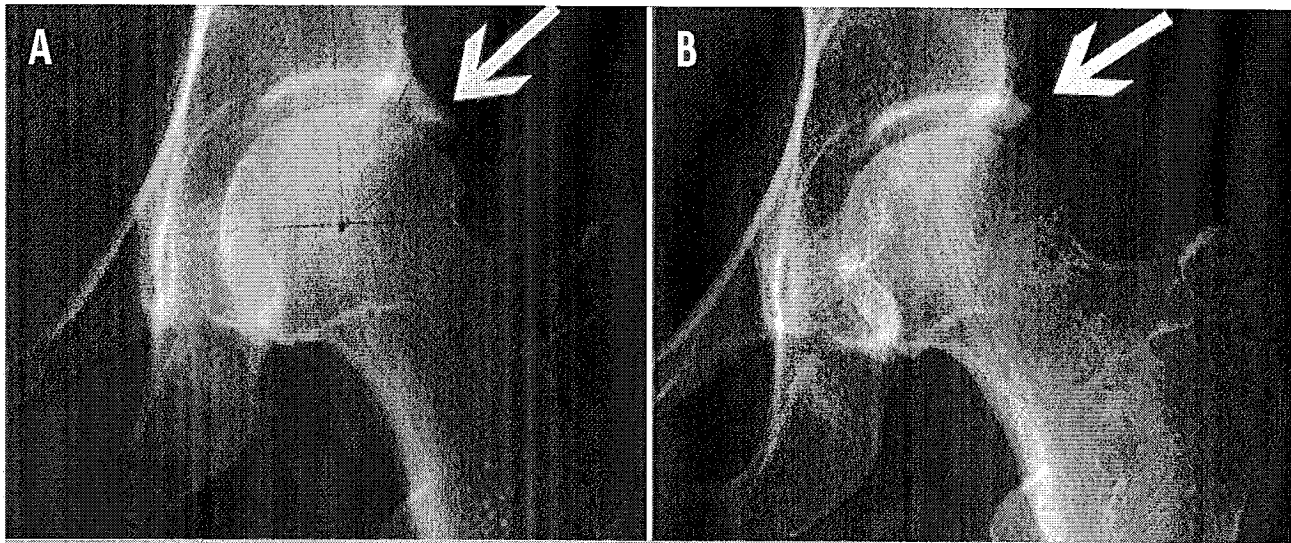
#### OSTEOPLASTY- CAM PROCEDURE

Labral tears, which are associated with cam impingement, are more commonly type 1 tears and affect the transition zone cartilage and articular surface of the labrum.<sup>4</sup> A cam-type impingement is caused by a nonspherical head-neck junction of the femur.<sup>1</sup> Most commonly manifested during hip flexion and internal rotation, this causes an impingement of the labrum between the anterior acetabulum and the femoral neck.<sup>3,8,9,10</sup> "When the aspherical head-neck junction of the femur enters the acetabulum, it displaces the labrum toward the capsule and applies disproportionate load to the adjacent articular cartilage of the acetabulum. This leads to chondral delamination and detachment of the labrum from the acetabular rim."<sup>4</sup>

Femoral osteoplasty involves recontouring the cam lesion using a motorized burr and fluoroscopy. Traction is removed and a dynamic impingement exam is performed.<sup>6</sup> The hip



**FIGURE 2.** (A) An AP pelvis radiograph reveals a superior area of cam impingement (arrow) in a 21-year-old college wrestler. An aspherical head-neck junction evident on the AP radiograph in addition to the lateral radiograph indicates a more extensive cam lesion. (B) A burr was used to recontour the head-neck junction arthroscopically, and improved offset is evident on the postoperative AP radiograph (arrow).



**FIGURE 3.** (A) An AP pelvis radiograph reveals pincer impingement with a deep acetabulum and secondary ossification of the labrum (arrow) in a 38-year-old equestrian rider with increasing pain with hip abduction. (B) Arthroscopic rim trimming was used to remove this ossified labrum and area of overcoverage (arrow), as seen on the postoperative AP radiograph. The patient's abduction range of motion normalized, and she no longer had pain during horseback riding.

will be flexed, extended, abducted, adducted, internally and externally rotated in order to determine the appropriate positioning.<sup>4,8</sup> Often the area of the cam lesion can be identified by areas of damaged articular cartilage at its location. The surface cartilage is removed using a curette and a motorized shaver. Then a motorized burr is used to reduce the bony prominence. After osteoplasty, joint clearance is assessed by flexing the hip beyond 90 degrees and internally rotating under direct visualization.<sup>4,8</sup> In order to prevent a possible fracture, a resection of less than 30 percent of the head-neck junction is recommended because this has been shown not to alter the load-bearing capacity of the femoral neck.<sup>4,8</sup> Care must be taken not to remove too much bone and compromise the strength and integrity of the femoral neck.

#### DYNAMIC EXAM

A dynamic exam concludes the procedure. Traction has been removed and the hip joint is run through a complete range of motion: flexion, extension, internal and external rotation. The repair and the movement of the femoral head within the acetabulum as well as contact of the labrum are observed arthroscopically. If any signs of impingement remain, the osteoplasty can be refined at this time.

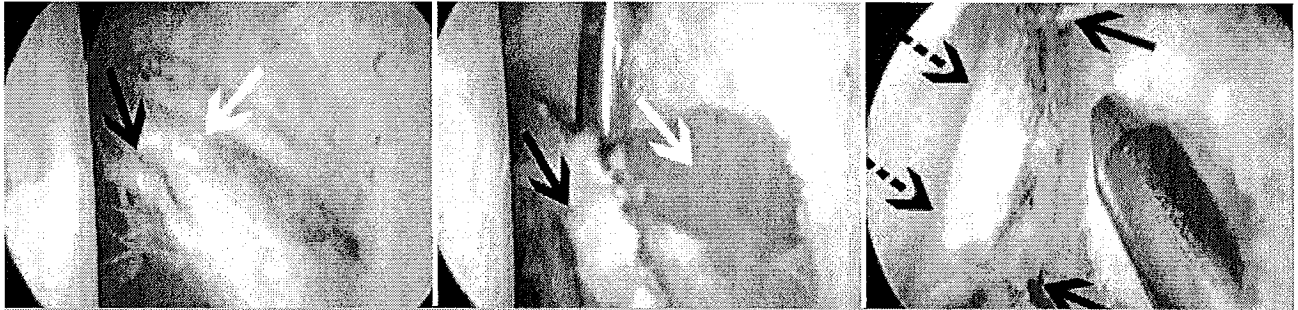
At the conclusion of the procedure, the suction is connected to the trocar and excess fluid is removed from the joint space. A local anesthetic of 20ml 0.5% bupivacaine and 2ml morphine sulfate is injected into the joint to ease postoperative pain. The portals are closed with a 3-0 nylon

suture. Bacitracin ointment is applied, followed by a non-adherent dressing, gauze pads and finally ABD pads are secured with perforated tape. A polar care hip dressing is applied and the patient's hip brace, which has been previously fitted for him or her, is secured.

#### RECOVERY AND REHABILITATION

Postoperative rehabilitation helps to determine and complete the success of the hip arthroscopy. In the early phase of rehabilitation, restrictions include limits on the amount of weight borne by the hip and its range of motion. In uncomplicated cases, crutches are used for approximately seven-10 days.<sup>2,6</sup> In patients requiring repairs or who have extensive problems, the patient may be non-weight bearing for six-eight weeks.

Postoperative rehabilitation also includes continuous passive motion for the first four weeks for two-four hours per day.<sup>2,8</sup> Starting immediately, patients are encouraged to ride a stationary bike with a high seat to avoid pinching. A slow progression to activity avoids over-activation or aggressive loading of the hip flexors, abductors and adductors, as these muscle groups are highly susceptible to fatigue and tendonitis postoperatively.<sup>4</sup> Some patients will begin physical therapy as early as the next day, and some may begin two weeks postoperatively and may continue for four-eight weeks.<sup>6</sup> This recovery usually covers three to four months, though patients may continue to see improvement in their symptoms for up to one year postoperatively.



**FIGURE 3.** (A) Arthroscopic view of left hip with arthroscope in anterior paratrochanteric portal. The femoral head is to the left, and the acetabulum is to the right. This image from a 17-year-old soccer player who had peripheral labral ecchymosis consistent with pincer impingement (white arrow) and a disruption of the labral-chondral junction with early chondral delamination consistent with cam impingement (black arrow). (B) The labrum (black arrow) was detached from the acetabular rim through the area of undersurface tearing with a beaver blade. Rim trimming was performed to the acetabular rim (white arrow) with an arthroscopic bur. (C) The labrum has been repaired/refixed to the acetabulum with 2 suture anchors (solid arrows), and traction has been released, which shows restoration of the normal sealing function of the labrum against the femoral head (dashed arrows).

## CONCLUSION

Hip arthroscopy has evolved greatly in the last decade. Through improvements in equipment and techniques and a clearer understanding of indications and pathology, hip arthroscopy has become an effective means of treating a variety of intra-articular hip conditions. Though it is presently an uncommon procedure for surgical technologists, as this procedure requires highly-specialized training for the surgeons who perform hip arthroscopy, this is a procedure that will become more prevalent in the future.

## ABOUT THE AUTHOR

Margaret Armand, CST, is currently working at Advocate Good Samaritan Hospital in Downers Grove, Ill. After 14 years in early childhood education she made the career change to surgical technology in 2004. She primarily works with the orthopedic surgery team.



## Acknowledgements

Ms Armand wishes to recognize and thank Dr Benjamin G Domb for sharing his expertise, for his support, and encouragement with the writing of this article, Dr Rima Nasser for her editorial contributions, and most importantly her husband and family for their support.

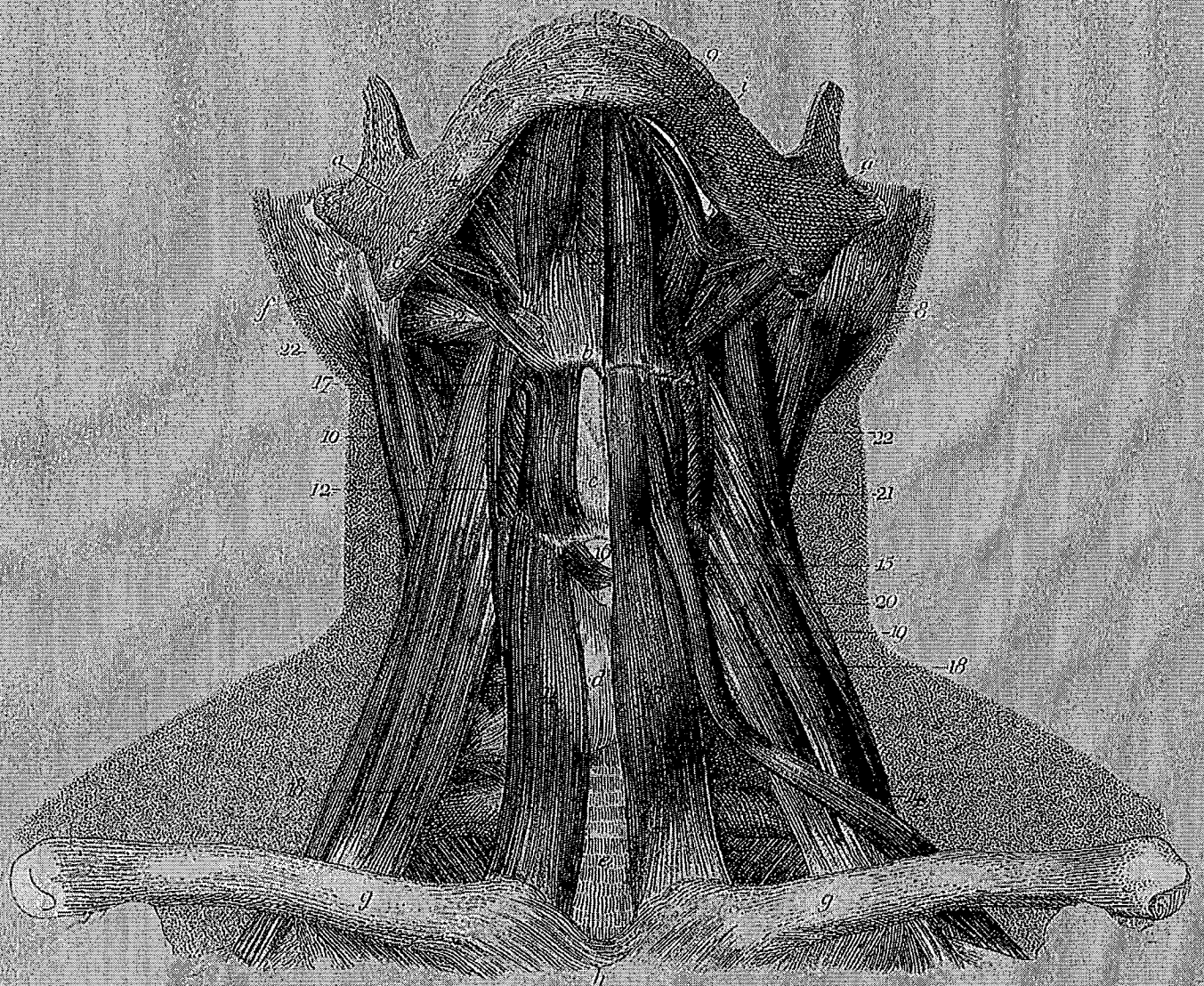
## References

1. Byrd, Thomas. 2006. "The Role of Hip Arthroscopy in the Athletic Hip." *Clinics in Sports Medicine*, 25. Accessed: May 9, 2009. Available at: <http://www.mdconsult.com/das/article/body/147272413-2/jorg=journal&source=&sp=16167525&sid=0/N/532245/1.html?issn=02785919>.
2. Carreira, D; Bush-Joseph, C. 2006. "Hip Arthroscopy." *Orthopedics*, 29. Accessed: April 1, 2009. Available at: <http://www.orthosupersite.com/print.asp?rID=17203>.
3. Shetty, V; Villar, R. 2007. "Hip arthroscopy: current concepts and review of literature." *British Journal of Sports Medicine*, 41. Accessed: July 1, 2009. Available at: <http://www.bjsportmed.com>.

4. Shindle, M; Domb, B; Kelly B. 2007. "Hip and pelvic problems in athletes." *Operative Techniques in Sports Medicine*, 15. 195-203.
5. Kelly B; Williams, R. 2003. "Hip arthroscopy: current indications, treatment options, and management issues." *American Journal of Sports Medicine*, 31. 1020-1037.
6. Tanner M. 2007. Central States Orthopedic Specialists. Accessed: April 1, 2009. Available at: [http://www.csosortho.com/hip\\_arthroscopy.cfm](http://www.csosortho.com/hip_arthroscopy.cfm).
7. McCarthy J; Lee, J. 2005. "Hip Arthroscopy: Indications, Outcomes, and Complications." *The Journal of Bone and Joint Surgery*, 87. Accessed: May 9, 2009. Available at: <http://www.ejbs.org/cgi/content/full/87/5/1137>.
8. Philippon, M; Schenker, M. 2006. "Arthroscopy for the Treatment of Femoroacetabular Impingement in the Athlete." *Clinics in Sports Medicine*, 25. Accessed: May 6, 2009. Available at: <http://www.mdconsult.com/das/article/body/147272413-2/jorg=journal&source=&sp=16167524&sid=0/N/532244/1.html?issn=02785919>.
9. Manaster, B; Zakei, S. 2006. "Imaging of Femoral Acetabular Impingement Syndrome." *Clinics in Sports Medicine*, 25. Accessed: June 13, 2009. Available at: <http://www.mdconsult.com/das/article/body/147272413-2/jorg=journal&source=&sp=16447420&sid=0/N/547983/1.html?issn=02785919>.
10. Newman, J; Newberg, A. 2006. "MRI of the Painful Hip in Athletes." *Clinics in Sports Medicine*, 25. Accessed: June 26, 2009. Available at: <http://www.mdconsult.com/das/article/body/147283531-2/jorg=journal&source=&sp=16447409&sid=0/N/547972/1.html?issn=02785919>.
11. Ruane, J; Rossi, T. 1998. "When Groin pain is more than just a strain." *The Physician and Sports Medicine*, 26. 78-104.
12. Seldes, R; Tan, V; Hunt, J et al. *Anatomy, Histologic features, and Vascularity of the Adult Acetabular Labrum. Clinical Orthopaedics and Related Research*. 382:232-240, 2001.

## For Further Reading

1. Byrd, J; Thomas. 2007. Arthroscopy Association of North America. Accessed: June 26, 2009. Available at: <http://www.aana.org/members/data/ElearningSystem/ReadContent.aspx?sid=536&videoname=State+of+the+Art+2007%3a+Indications+for+Hip+Arthroscopy&topicname=2007+Fall+Course&coursename=State+of+the+Art+2007%3a+Indications+for+Hip+Arthroscopy>.
2. Lubowitz, J; Poehling, G. 2009. "Who among us should perform arthroscopic surgery of the hip?" *Arthroscopy The Journal of Arthroscopic and Related Surgery*, 25. Accessed: April 1, 2009. Available at: [http://www.arthroscopyjournal.org/article/S0749-8063\(09\)00106-6/fulltext](http://www.arthroscopyjournal.org/article/S0749-8063(09)00106-6/fulltext).
3. Mohammed, R. 2007. "Riazuddin Mohammed: Initial Experiences of the Arthroscopy of the Hip." *Journal of Orthopaedics*, 4. Accessed: June 23, 2009. Available at: <http://www.jortho.org/2007/4/3/e9/index.html>.



# Platysmaplasty

*A surgical resolution for the "turkey neck"*

by Nydia I Morales, CST

The term "turkey neck" refers to the lateral ptosis of the frontal neck derma. This can occur when the platysma muscles separate, a result of natural weakening of the ligaments in the cervical region, as well as excessive lipid build-up. Other causes of this condition include genetics, bone loss and decline of skin elasticity—possibly from weight loss. It is most commonly regarded as a factor of aging, although sun exposure and smoking may also contribute.

**F**or patients who are interested in reducing the loose look of sagging skin in the neck area under the jaw line, a platysmaplasty, or neck lift, is an option. It can be performed in conjunction with a face lift, but it is often performed as a stand-alone procedure. This article examines the surgical options for resolving turkey neck, as well as alternatives to surgery.

## ETIOLOGY AND ANATOMY

The platysma muscle is one of a pair of plate-like, wide muscles at the side of the neck. It arises from the fascia covering the superior parts of the pectoralis major and the deltoideus. It crosses the clavicle and rises obliquely and medially along the side of the neck. The platysma covers the external jugular vein as the vein descends from the angle of the mandible to the clavicle. It is innervated by the cervical branch of the facial nerve and serves to draw down the lower lip and the corner of the mouth. When the platysma fully contracts, the skin over the clavicle is drawn toward the mandible, increasing the diameter of the neck.<sup>1</sup>

The muscle has several distinct points of reference. It is attached to the mentum and the inferior madibular edge and

## LEARNING OBJECTIVES

- ▲ Review the relevant anatomy for this procedure
- ▲ Examine the set-up and surgical positioning for this procedure
- ▲ Compare and contrast the differences between an in-office procedure and a typical OR procedure
- ▲ Assess the indications for platysmaplasty
- ▲ Evaluate the recovery process, as well as the potential postoperative complications for platysmaplasty


intersects the orbicularis oris laterally and the depressor anguli oris.<sup>2</sup> The skin of the cheek and the anterior neck is comprised of three interconnected layers: the superficial epidermal-dermal layer; the underlying subcutaneous fat; and a gliding membrane composed of fibro-elastic connective tissue and muscle. This gliding membrane is called the superficial musculo-aponeurotic system (SMAS).<sup>2</sup> The SMAS aids in reattaching the muscle, producing a younger, smoother facial appearance. The fat of this superficial layer consists of lobes that lie randomly on the face and intersect with the fibrous tissues of the SMAS. Thicker layers of fat are found in the neck and cheek area. The deep fat layer is thin and divided by fibrous bands. The ligaments hold the soft tissue and anchor it to the bone.<sup>3</sup>

#### PREOPERATIVE PREPARATION

The patient is required to cease smoking and consuming alcohol for two weeks prior to the procedure. This is to help ensure proper healing postoperatively. In addition, aspirin should not be taken preoperatively as it can cause bleeding. The patient should wear comfortable clothing during and after the procedure to facilitate nonrestrictive circulation. Baggy clothing or a sweat suit is encouraged.

Vital signs, including blood pressure and pulse oximeter readings are recorded and close attention is given to any irregularities, such as cardiac dysrhythmia.

The surgeon will review the procedure with the patient, as well as take a complete medical history. Photos of the patient are taken to provide a before-and-after comparison. The surgical technologist remains in the OR suite for the duration of the procedure to monitor the patient at all



*The platysma muscle is highlighted in bright red.*

times. There is no circulating nurse or anesthesiologist present. Prior to the procedure, the surgical technologist confirms that the consent form has been signed and countersigns it. He or she also reviews all medical entries at this time. Vital signs, including blood pressure and pulse oximeter readings are recorded and close attention is given to any irregularities, such as cardiac dysrhythmia.

The choice of anesthetic will vary depending on several factors, including the patient's overall health, medications the patient is currently taking and the number and length of time of the procedures being performed. Patient and surgeon preference are also considered. A platysmaplasty alone can be performed under general anesthesia, with IV sedation or local anesthesia. Most cases are done in-office and are performed under local anesthesia.

The local anesthetic for this procedure is a tumescent solution: a combination of 400 ml normal saline, 90 ml one percent lidocaine without epinephrine, 10 ml 8.4 percent sodium bicarbonate and one ml of epinephrine 1:1000.

Preoperative antibiotics are also administered to prevent bacterial infections. Cephalexin is the primary antibiotic of choice as it can be used in patients with certain heart problems as a means to prevent coronary infection (bacterial endocarditis). Cleocin may be used to fight bacterial infections in patients who are allergic to penicillin. Azithromycin—known as z-pack—may be used postoperatively. In most cases, a sedative is used. Five to 10 mg of diazepam is administered sublingually to treat anxiety in patients who request it. The sedative is used based on patient preference; however, the surgeon will dictate the dose to be administered.

The patient is placed in the seated position and the surgical technologist cleans the patient's neck with surgis-crub. The patient's thoracic region is draped in order to create and maintain the sterile field during the procedure. The surgeon then outlines the planned incisions with a sterile marking pen on the submental region. The local anesthetic is administered by injection into the surrounding area.

The surgical technologist sets up the Mayo stand with the following instrumentation:

- ▲ #15 knife blade and knife handle
- ▲ Army-Navy retractor
- ▲ Adson forceps with teeth
- ▲ DeBakey tissue forceps
- ▲ Needle holder
- ▲ Curved and straight Metzenbaum scissors
- ▲ Small mosquito (placed to the side in case it is needed)
- ▲ 4x4s
- ▲ 5.0 nylon suture
- ▲ 2.0 PDS

- ▲ Surgeon's magnified intense glasses
- ▲ Electrosurgical pencil with needle-tip electrode (ESU)
- ▲ 0.9 percent sodium chloride for irrigation and kidney basin
- ▲ Long tip cotton applicator
- ▲ Elastic bandage (wrap)
- ▲ Sutures and dressings of the surgeon's preference



In addition, the surgical technologist will lay out the sterile gloves, bouffant/cap and the head light source to be used during the procedure.



## OPERATIVE PROCEDURE

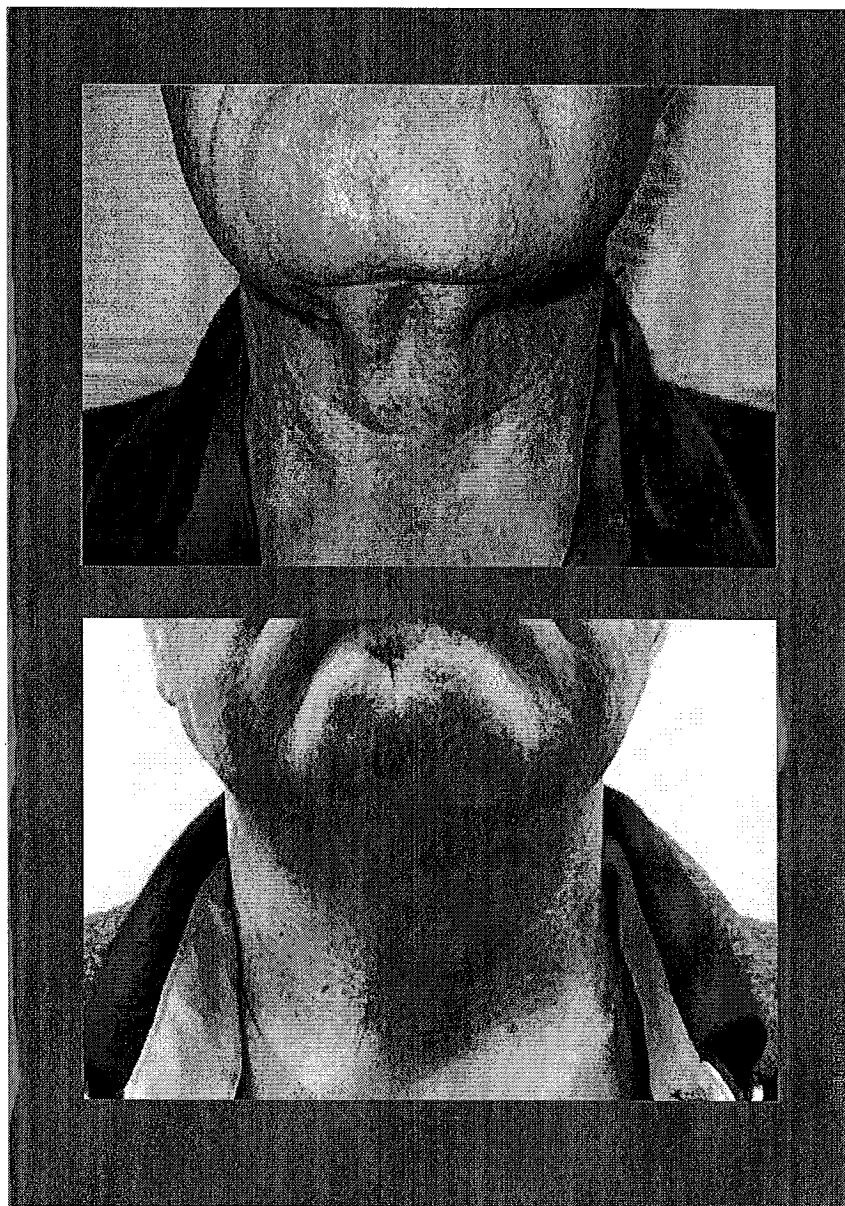
Using the #15 blade, the surgeon makes a one-inch submental incision. The ESU is then used to coagulate the blood vessels while the surgical technologist pats the area dry using the sterile 4x4s. Using a toothed Adson forceps to grasp the external derma, the dissection is continued subcutaneously, in a horizontal direction of the submental region. Using a straight Metzenbaum scissor, the surgeon separates the subcutaneous layer from the platysma muscle and exposes the fat pad.

The surgeon inserts an Army/Navy retractor approximately one inch into the incision, creating an open pocket, which is held in place by the surgical technologist. The surgeon then removes any excess adipose tissue by grasping it with a DeBakey in one hand and cutting it using a curved Metzenbaum scissor with the other. The surgical technologist removes the excised fat from the DeBakey with a 4x4. The ESU is used throughout to coagulate additional blood vessels as needed. Opened and elongated 4x4s are saturated in saline and inserted momentarily into the subcutaneous path for irrigation purposes, during which time the Army/Navy retractor is removed. When the 4x4 is extracted, the Army/Navy retractor is reinserted. The surgical technologist must keep an accurate count of the 4x4s during this process. This series of actions is repeated until the surgeon is satisfied that all necessary excess fat has been removed and the platysma muscle is sufficiently exposed.

Using the DeBakey, the surgeon collects both posterior ends of the platysma muscles that have separated and trims any uneven edges in order to suture them together with a 2.0 PDS (non-coated, monofilament polydioxanone suture), using a reverse mattress stitch, to load and release the memory. The external submental derma is then flattened out and the excess is approximated to determine the

appropriate length to trim based on the initial incision line or cervicoplasty.

Using an Adson forceps with teeth, the surgeon holds the external derma with one hand and, with the other, trims away the excess skin using curved Metzenbaum scis-



sors. The amount of skin removed is customized for each patient. Using a 5.0 nylon suture, a subcutaneous stitch is applied with slight tension. Alternatively, a simple, uninterrupted stitch on the natural crease may be used. The method of suturing is based on the surgeon's preference and is chosen based on the amount of fat that has been removed,

thus it will vary from patient to patient. The suture ends are cut short to prevent them from causing interference. The 4x4 with antibiotic ointment should not adhere to the stitches and snag the skin when wrapped with the elastic bandage wrap.<sup>3</sup>

Another suturing technique that may be used is the “corset platysmaplasty,” so named for its similarity in appearance to the “X” pattern of an old-fashioned corset when fully laced. In this alternative, the muscle is gathered and sutured with a snug jaw line and a right-angled neck contour. This produces a successful restructuring of the platysma muscle at the midline.<sup>4</sup>

Once the procedure is completed, the patient’s vital signs are taken and recorded again. Prescriptions for antibiotics, which are mandatory, and any necessary pain relievers are noted. Many patients’ pain-relieving needs can be met with over-the-counter extra strength acetaminophen. A follow-up appointment is scheduled for the following week, and the patient is provided with written postoperative instructions. The surgeon will call the patient to follow up, but the patient is also instructed to call the surgeon with any concerns or to report any changes in their condition.

#### POSTOPERATIVE CARE

An elastic bandage should be wrapped around the head and neck for the first 24 hours postoperatively, and patients should be monitored by a friend or family member during this time. The bandage should be snug and comfortable, but not tightly wrapped. At the patient’s discretion, it may be worn for five days following the surgery for support, however, it should be removed to bathe and eat. Patients are advised to keep ice packs on the surgical area every three to four hours for the first 48-72 hours after surgery. The patient’s head must be elevated while sleeping to minimize edema, and it is suggested that patients sleep with two pillows to ensure this is maintained. No strenuous exercise is allowed, although short walks are acceptable. The patient’s diet must also be monitored as a restricted salt intake will reduce facial swelling. In addition, patients are encouraged to eat foods that are enriched with vitamin C, zinc and iron to promote healing.

Mild swelling in the surgical area may be present for up to six months postoperatively. Patients must also use a ther-

момeter to monitor increases in temperature, which may be an early sign of a possible surgical site infection. During this time, the patient should cleanse the surgical site using sterile gauze and a 50-50 mixture of hydrogen peroxide and water. Antibacterial ointment should be applied to the incision site after each cleansing.

All antibiotics must be finished as prescribed, and aspirin, ibuprofen, vitamin E and fish oil supplements are not allowed during the first week following surgery to help prevent bleeding.

The bandage should be snug and comfortable, but not tightly wrapped. At the patient’s discretion, it may be worn for five days following the surgery for support, however, it should be removed to bathe and eat.

#### POSTOPERATIVE RISKS AND COMPLICATIONS

Swelling, bruising and mild discomfort are common and should be expected in the week following a procedure. Infections, seroma, bleeding and hematoma, while not normally considered serious, may occur and should be monitored carefully. If a hematoma is detected—generally indicated by excessive swelling within 12 hours of the procedure’s completion—the patient must return to the surgeon’s office to have it drained with a needle in a sterile setting. Left untreated, it may become infected and possibly cause necrosis of the derma around the surgical site or enter the blood stream, leading to more complications.<sup>6</sup> If the incision site acquires a green or yellow coloration, it could signify a possible infection or that blood circulation to the area is impaired.

Follow-up visits are scheduled for one week post-procedure, two weeks post-procedure and four weeks post-procedure. At the final visit, another set of photographs are taken to compare to the pre-surgical images.

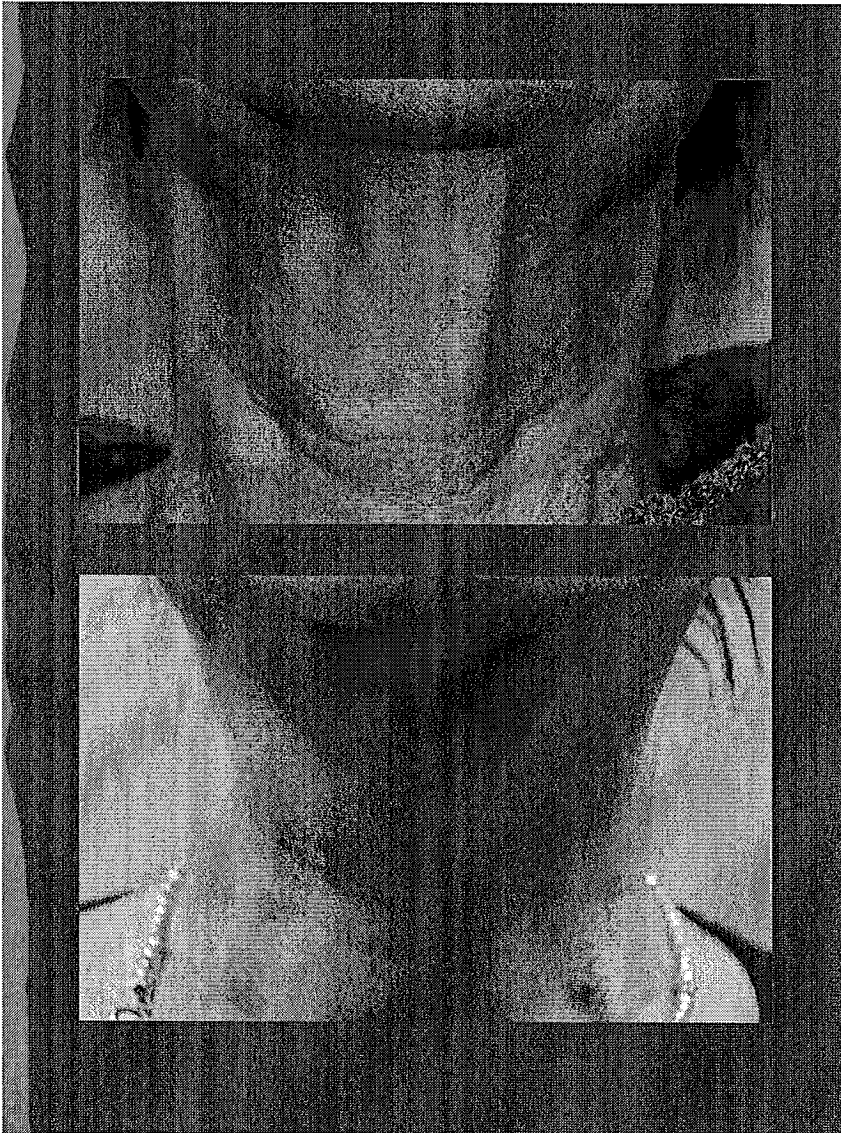
#### CONCLUSION

The end result of a successful platysmaplasty is a refined, smooth neck that enhances the patient’s features for a more youthful appearance. It can be combined with a face lift, filler, chemical peel and botulinum toxin injections.

Neck lifts may also be performed endoscopically, which is less invasive. This procedure lasts about an hour and a small incision is made under the chin through which the endoscope is inserted. Another alternative is a liposuction procedure, which also lasts about an hour and involves a small incision under the chin through which the fat is extracted. Finally, botulinum toxin injected directly into the platysma muscles will counteract muscle weakening and stop contractions.


#### ABOUT THE AUTHOR

Nydia I Morales, CST, was an elementary school teacher before entering the medical field. She graduated from New York University Langone Medical Center's surgical technology program in New York City, and became certified in September 2007. She presently assists Kamran Jafri, MD, as his surgical technologist in facial plastic surgery in New York City. She is also an adjunct lecturer (clinical site: Maimonides Medical Center) in the surgical technology program at Kingsborough Community College in Brooklyn, New York.



#### References

1. Mosby's Medical Dictionary, 8th ed. 2009. Elsevier.
2. Owsley J. 2007. drjohnowsley.com. "What is the 'SMAS'?" SMAS-Platysma Face-lift. Accessed: 5/7/2010. Available at: <http://www.drjohnowsley.com/html/smas.html#smas>.
3. Fuller J. Surgical Technology: Principles and Practice, 5th ed. 2010. Elsevier. p 746.
4. Feldman, J. Neck Lift. Quality Medical Publishing Inc. p 50.
5. Jafri K. Custom-Lift. Accessed: 5/7/2010. Available at: [www.custom-lift.com](http://www.custom-lift.com).
6. WebMD. 2010. "Cosmetic Surgery and the Neck Lift." Accessed: 5/7/2010. Available at: <http://www.webmd.com/skin-beauty/guide/cosmetic-procedures-neck-lift>



# Emergency Cesarean Delivery in the Labor and Delivery Room

by Gracelia A Scott, CST

This article addresses a new procedure for handling Cesarean deliveries performed in the Labor and Delivery Room (LDR) under extreme circumstances, eg, the mother is dying or has died.

## INTRODUCTION

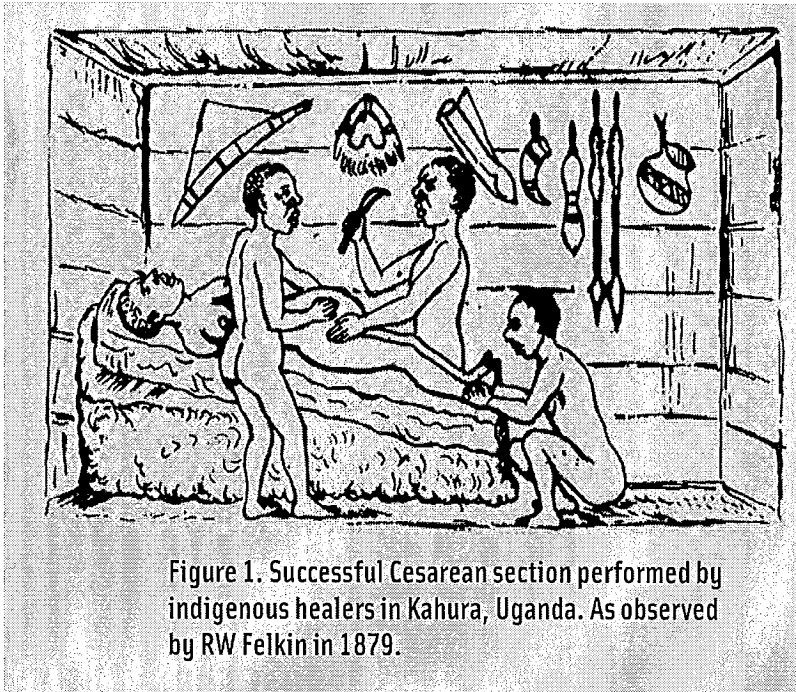
The origin of the term Cesarean has been thought to come from the birth of Julius Caesar. It is unlikely however, as his mother, Aurelia Cotta, lived for many years afterwards. It is more likely that the term originated from "Caesar's Law," which states that if a pregnant woman is clearly dead, the fetus should be cut out of her in an attempt to save it. Cesarean deliveries have been recorded in history for many centuries. Surgical removal of a baby from a dead or dying mother has been documented as far back as ancient Egyptian times. In these ancient times, if the mother-to-be was dying or had just died, Cesarean delivery was an attempt to rescue the fetus/neonate.

In the early 1900s, Cesarean delivery became more widely accepted, even though there were also other options, such as forceps and vaginal breech delivery. By the 1960s, the maternal mortality rate secondary to Cesarean delivery in severe emergencies, such as fetal bradycardia, shoulder dystocia, and cardiac arrest, was nearly zero because of major advances in anesthesiology and better methods of controlling hemorrhage.

Notwithstanding medical advances, the need for saving the

## LEARNING OBJECTIVES

- ▲ Review the relevant anatomy for this procedure
- ▲ Examine the set-up and surgical positioning for this procedure
- ▲ Compare and contrast the different types of breech birth
- ▲ Assess the needs of the surgical team for this type of procedure
- ▲ Evaluate the inherent dangers of Cesarean section births



**Figure 1. Successful Cesarean section performed by indigenous healers in Kahura, Uganda. As observed by RW Felkin in 1879.**

neonate when a mother is dying is great, and can happen in an instant and in a labor and delivery room (LDR) setting. Sometimes, the delivery must be performed immediately after maternal death. A Cesarean delivery in the LDR is the delivery of a neonate by means of an incision into the uterus in a life-threatening emergency. Every surgical technologist who works in labor and delivery needs to be prepared for any and all emergencies.

Despite the advances in medicine and the ability to respond to LDR emergencies, mortality still remains. Since anesthesia was first used in Cesarean deliveries in 1847, the likelihood of fetal or maternal death has played an important role in deciding whether the procedure is necessary. In a true LDR emergency, the goal is to deliver the neonate as quickly as possible.

#### **LDR CESAREAN DELIVERY REQUIREMENTS**

In an LDR Cesarean Section the hospital staff may include, but is not limited to:

- The attending obstetrician
- Charge nurse or (nurse team leader)
- Anesthesiologist
- Resident on call
- Physician assistant (PA) on call
- In-house obstetric attending physician
- Patient's primary nurse
- Circulating nurse

- Scrub person (ST, RN, LPN with best skills)
- Neonatal team
- Blood bank

New York Hospital Medical Center of Queens (NYHQ), where this author works, has developed a Code Blue cart that is equipped with the following supplies, required for Cesarean deliveries in the LDR:

- Betadine solution
- Disposable scalpels (2)
- Cesarean delivery tray tally sheets
- Blades: #10 (1), and #20 (1)
- PBDS Latex-Free Labor and Delivery Module, Cesarean delivery
- Laparotomy pads (40)
- ABG kits (5)
- Placenta bucket
- Sandbag
- OR Gowns (2)
- OR bonnets, caps
- OR boots
- Masks
- Goggles
- Gloves: 7.0 latex-free (2), and 7.5 latex-free (2)
- 3/4 sheets for table (2)
- Receptacle for lap count
- Sutures: 1.0 Polyglactin 910 (2), and 1.0 Chromic (2)
- Light handle (1)
- Bovie grounding pads (2)
- Bovie pencil (2)
- 3000 cc suction set-up for surgery
- Stapler
- Foley catheter kit
- 10 cc syringe
- Suction tubing

These supplies are kept in a locked (breakaway lock), designated Code Blue cart on the labor and delivery floor, and it is brought into the LDR immediately, along with the neonatal box and anesthesia box, at the time of emergency. These boxes contain all the supplies needed to resuscitate and support the fetus and mother. The Code Blue cart is checked and signed off once each shift (7:00 am to 3:00 pm; 3:00 pm to 11:00 pm; and 11:00 pm to 7:00 am) to ensure that it is always fully stocked and ready for emergencies.

#### **CODE BLUE PROCEDURE AT NYHQ**

Once the team leader (a physician or member of the nursing staff) decides to call an emergency Cesarean delivery in the

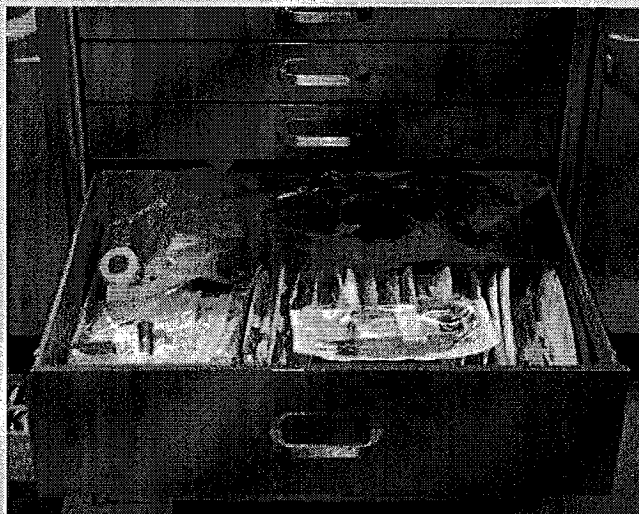



Figure 2. The anesthesia cart at NYHQ.

## VAGINAL BREECH BIRTH

While Cesarean section remains the most common way to deliver a breech baby in most First World countries, some infants are still delivered by a breech birth. In the breech presentation, the baby enters the birth canal with the buttocks or feet first as opposed to the normal head-first presentation.

According to the American Pregnancy Association, breech births occur in about one of 25 full-term births. When labor is premature, the incidence of breech presentation is higher. Instances of breech birth are also higher with multiple fetuses (twins, triplets, etc.); abnormal volume of amniotic fluid; fetal abnormalities; uterine abnormalities and in mothers who have undergone a prior Cesarean section.

### THERE ARE FOUR CATEGORIES OF BREECH BIRTHS:

- Frank breech—the neonate's bottom comes first, and his or her legs are flexed at the hip and extended at the knees with feet near the ears. Between 65-70 percent of breech babies are in the frank breech position.
- Complete breech—the neonate's hips and knees are flexed so that it is sitting cross-legged with feet beside the bottom
- Footling breech—one or both feet come first, with the bottom at a higher position. This is rare at term, but relatively common with premature fetuses.
- Kneeling breech—the neonate is in a kneeling position, with one or both legs extended at the hips and flexed at the knees. This is extremely rare and is excluded from many classifications.

Risks to a breech birth include umbilical cord prolapse, head entrapment and injury to the brain and skull. In both umbilical cord prolapse and head entrapment, oxygen deprivation is a major concern. Brain and skull injuries are more likely in preterm births. The rapid passage of the fetus's head through the mother's pelvis causes rapid decompression of the head, which may injure the brain. In contrast, a fetus delivered in the head-down position usually experiences gradual molding of the skull over the course of a few hours.

The potential injuries that may be sustained during a breech birth may also occur during Cesarean birth, though rare. A Cesarean birth is still a breech birth; however, the soft tissues of the uterus and abdominal wall are more forgiving than the hard, bony ring of the pelvis.

LDR (Code Blue), the patient's primary nurse must communicate the decision to the nurse team leader. The nurse team leader will immediately activate the Code Blue. The alarm is heard throughout the hospital, as well as in all LDR's and operating rooms. The entire hospital knows that the labor and delivery unit needs help. The charge nurse and the hospital support team from other floors arrive at labor and delivery as quickly as possible. The nurse team leader will then assign duties to designated nursing staff. At this time, the operating room should be opened so abdominal closure can occur in a more sterile and controlled environment.

The role of the surgical technologist is critical in managing the situation. He or she arrives at the LDR as fast as possible with OR gowns and gloves in hand. Upon arrival, the surgical technologist asks for the name of the team leader who is assigned to the Code Blue. The surgical technologist identifies him/herself as such. As other members of the medical staff arrive, they will give their names and titles to the nurse recorder. The team leader will direct a staff member (nurse, surgical technologist or nurse's aide) to bring the Code Blue cart into the LDR, open the Code Blue cart, and take out the instruments for the surgical technologist. The surgical technologist finds a table or any available space to set up the instruments. At the same time, the team leader gives the surgical technologist the situation, background and assessment recommendation (SBAR) report, history and physical (H&P) and the history of events preceding the Code.

The following staff, minimally, must be present in the LDR during a Code Blue:

- Team leader
- Anesthesiologist
- Resident (most experienced)
- Nurse recorder or patient's primary nurse
- Code Blue/CAT RN (bedside nurse)
- Medication nurse
- Nurse manager
- Assistant nurse manager/charge nurse
- Runner
- Neonatal team

The runner is placed in charge of obtaining additional supplies needed for the emergency (*ie*, STAT ECG machine, etc). The runner will transport and pick up blood products from the blood bank, as well as deliver all specimens to the laboratory. Only the team leader directs the runner.

The nurse recorder documents the initial basic life support (BLS), vital signs, assessment, medications, procedures




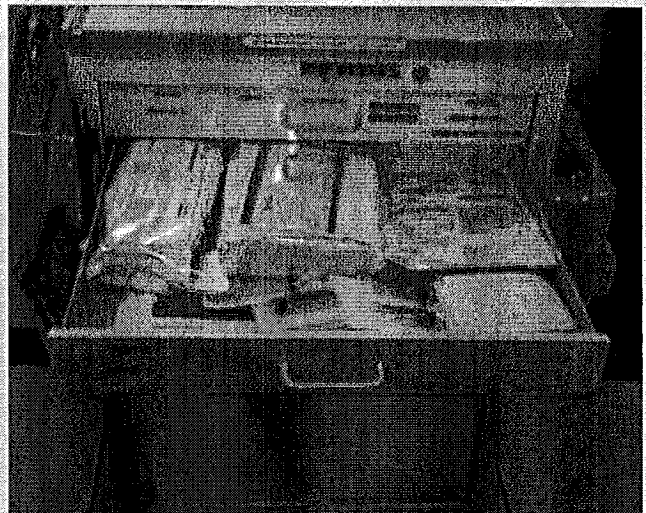


Figure 3. Cesarean section "Code Blue" cart at NYHQ

and tests performed. The nurse must also record times of event and activities of Code Blue/Response Code, recording as each team member arrives. He or she will always ask names of personnel in attendance, and will fill out a debriefing form.

#### SURGICAL OVERVIEW

In a Code Blue, the sandbag, or bolster, is not positioned under the patient's right hip. No safety strap is secured and, because the patient is in the LDR, the Foley catheter is already in place along with the blood pressure cuff. There is no skin preparation but, if time permits, Betadine solution is poured directly on the patient's skin, mid-chest to pubic

area. The Cesarean delivery drape is placed. A #10 blade is used to incise the skin via a midline vertical incision down to the level of fascia. The fascia is incised at the midline and carried laterally on both sides using Mayo scissors. The posterior fascia is bluntly dissected from the rectus abdominis muscle and secured with two Kocher clamps. Sharp dissection of the aponeurosis is accomplished superiorly to near the umbilicus and inferiorly to the symphysis pubis using Mayo scissors. The peritoneal cavity is entered atraumatically. No bladder flap is created. A bladder blade is placed over the bladder. A transverse incision is made in the lower uterine segment and carried bilaterally with Lister bandage scissors. The #10 blade is the only knife used. The surgical

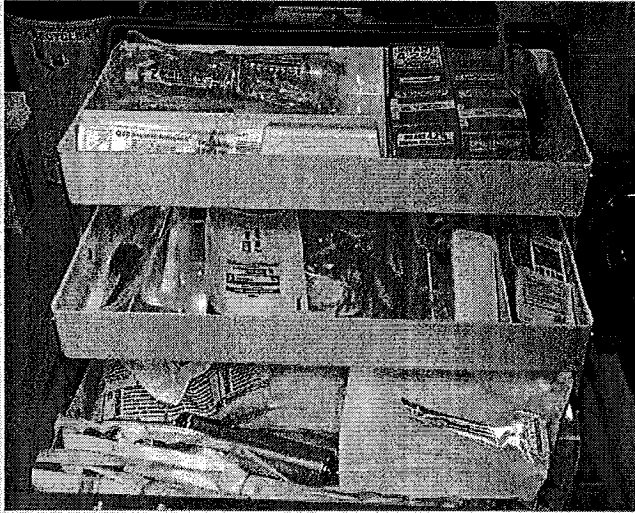


Figure 4. The neonatal box at NYHQ.

technologist should be moving as quickly as possible and must always know where the blade is. All sharp and metal objects should be removed from the field, if possible, before the delivery.

#### DELIVERY

The head is delivered first by flexing and elevating the fetal head. The umbilical cord is clamped with two small Kelly clamps and then cut with Lister bandage scissors. The neonate is then passed to the awaiting neonatal team. The Bovie can then be brought in for use. Warm Lactated Ringers solution and sterile water are also brought into the room at this time.

While the neonate is being taken care of, the surgical technologist prepares to move the patient. The attending physician makes the decision on when to move the patient from the LDR to the operating room (which should already be open) for the closure of the patient's abdominal wound. There should already be two #1 Polyglactin 910 CTX and two # 1 chromic sutures stocked in the Code Blue cart for use in the LDR.

#### CONCLUSION

Throughout the twentieth century, there have been many improvements in labor and delivery. Although the maternal mortality rate has decreased in the last several decades, women are having children at a much later age and under higher-risk circumstances. As surgical technologists, we

must be prepared for all situations and be able to react quickly. The Code Blue cart can be an invaluable tool to a surgical technologist and can save critical minutes. A Cesarean delivery that takes place in the LDR is the only hope for survival of the infant, and that can be maximized by rapid response and skilled, well-trained staff.

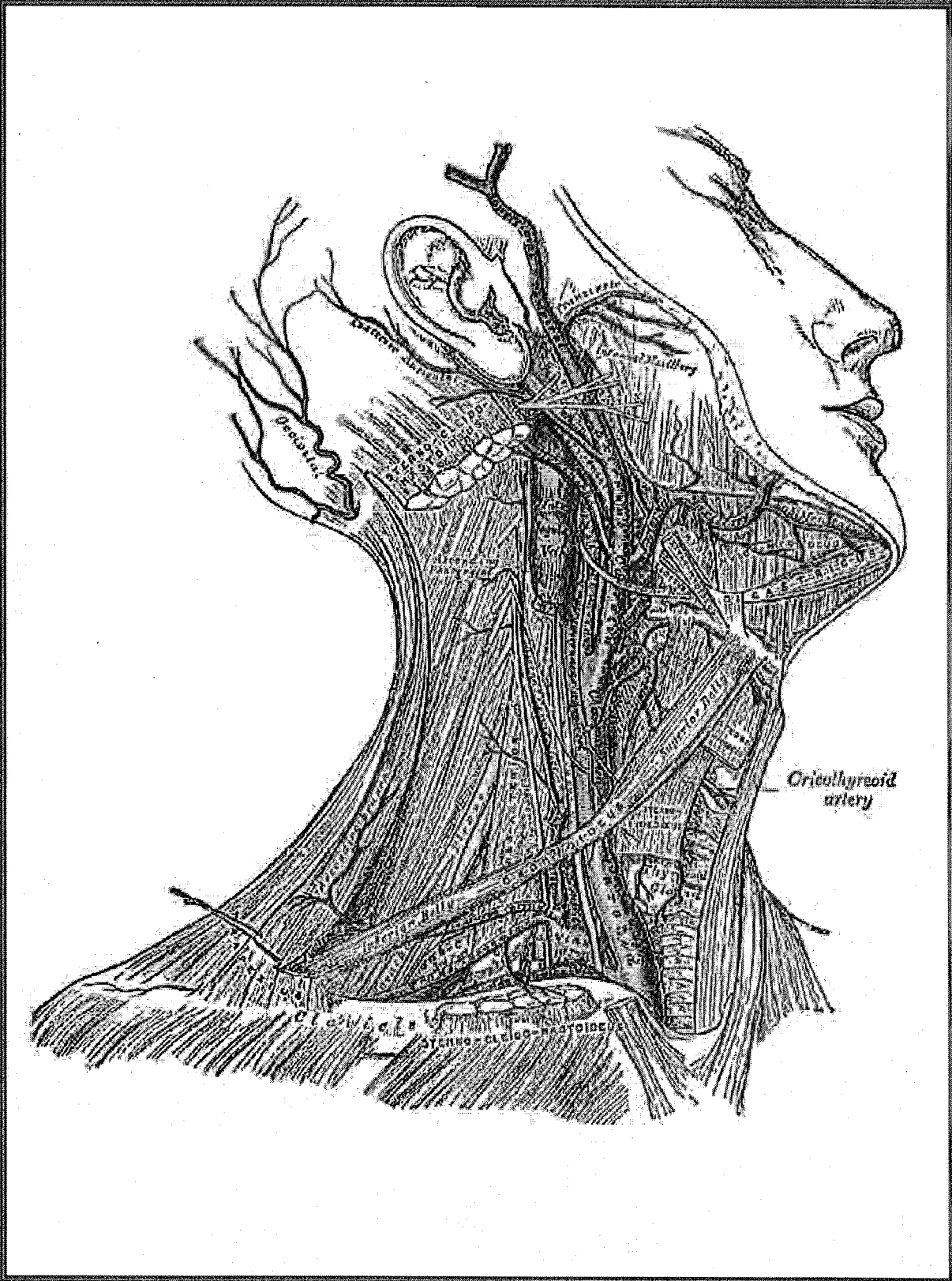
#### ABOUT THE AUTHOR

Gracelia A Scott, csr, lives in New York and graduated from the New York University Medical Center Surgical Technology Program. She has been a surgical technologist for more than 20 years at New York Hospital Medical Center of Queens. She is a member of AST and wrote this article to help fellow surgical technologists learn a new approach to an existing procedure as it is being performed in the LDR at New York Hospital Medical Center of Queens. In her spare time, Ms Scott enjoys riding her motorcycle and working with a different instrument kit—wrenches, sockets and pliers.



#### References

1. Code Blue/Rapid Response Drills: Roles & Responsibilities. New York Hospital Queens 2008, Department of Professional Development and Education.
2. Skupski DW; Eglinton GS; Lowenwirt IP; Weinbaum FI. "Building hospital systems for managing major obstetric hemorrhage." In: B-Lynch C, et al, eds. *A Textbook of Postpartum Hemorrhage*. Sapiens Publishing, 2006.
3. Kiefer BP. "Repeat Cesarean Section" *The Surgical Technologist*. 2008; 40: 13-20.
4. Todman D. "A History of Caesarean Section: From Ancient World to the Modern Era." *Australian and New Zealand Journal of Obstetrics and Gynaecology*. 2007; 47:357-361.
5. Hillan EM. "Caesarean Section: Historical Background." *Scottish Medical Journal*. 1991;36:150-154.
6. Hayden FJ. "Maternal Mortality In History And Today." *The Medical Journal of Australia*. January 17,1970:100-109.



# Radical Neck Dissection

Deborah D. Lamb, CST

A radical neck dissection is performed when malignant lesions are found in a patient's head and/or neck, as well as in his or her cervical nodes. This metastasis happens through the lymphatic channels via the bloodstream. The disease can affect the oral cavity, lips and the thyroid gland, which in turn can cause the cancer to spread slowly to the neck.

## HISTORY

The first radical neck dissection was described and performed by George Washington Crile at the Cleveland Clinic in 1906.<sup>1</sup> The revolutionary procedure marked a great step forward in the treatment of metastatic neck diseases. At the time, Crile, a founding member of both the Cleveland Clinic and the American College of Surgeons, was already well known for his work in thyroidectomies, of which he performed more than 25,000 in his career.<sup>1</sup>

As performed by Dr Crile, the radical neck dissection called for the removal of all the lymph nodes on one side of the neck, as well as the spinal accessory nerve, internal jugular vein and sternocleidomastoid muscle. The main drawback to this procedure was shoulder dysfunction, which occurred due to the sacrificing of the accessory nerve.<sup>2</sup> Future practitioners eventually established more conservative measures.

It wasn't until the 1940s that surgery began to take over as the treatment of choice for the majority of cancers of the head and neck. It was in this time frame that advances in the field of anesthesiology allowed for more elaborate surgeries. Additionally, the introduction of antibiotics during the second World War allowed

## LEARNING OBJECTIVES

- ▲ Review the relevant anatomy for this procedure
- ▲ Examine the set-up and surgical positioning for this procedure
- ▲ Compare and contrast the modifications of the radical neck dissection
- ▲ Assess the risks and benefits of skin and nerve grafts
- ▲ Evaluate the step-by-step procedure for a radical neck dissection

surgery to emerge as the primary choice for management of cancers of the head and neck.<sup>3</sup>

In the 1940s and 50s, Hayes Martin, MD, preformed radical neck dissections on a routine basis in order to manage neck metastasis. The main objective, as he saw it, was to remove and block the entire ipsilateral lymphatic structures from the mandible to the clavicle and from the infrahyoid muscles to the anterior border of the trapezius. His method also resected the spinal accessory nerve, the internal jugular vein, the sternocleidomastoid muscle and the submandibular gland. The remaining structures, including the carotid arteries, vagus nerve, hypoglossal nerve, brachial plexus and phrenic nerve were left intact.<sup>4</sup>

In the early 1960s, an Argentinean surgeon, Oswaldo Suarez, described the facial compartments in the neck and facial envelope covering a selective group of lymph nodes. He proposed a modification of Crile and Martin's radical neck dissection, which he termed as a functional neck dissection. Suarez's method was to remove a selected group of lymph nodes and preserve the vital structures, including the accessory nerve, jugular vein and sternomastoid muscle that Crile's procedure had originally designated for extraction.<sup>2</sup> This method was further popularized in Europe by Ettore Bocca and Caesar Gavilan, and in the United States by Richard Jesse, Alando Ballantyne and Robert Byers.<sup>2</sup>

The last four decades have made way for progressive advances to occur, giving an understanding of cervical fascial planes, lymphatic drainage patterns, preoperative staging and extracapsular spread. In 1991, a report was published by the American Academy of Otolaryngology-Head and Neck Surgery that standardized the terminology for the different types of neck dissections. In 2001, the report was updated with very few changes. These changes dealt with the application of various types of selective neck dissection procedures for oral cavity, pharyngeal and laryngeal, thyroid and cutaneous malignancies.

The modifications to the radical neck dissection are as follows:

*Type I:* The spinal accessory nerve is preserved.

*Type II:* The spinal accessory nerve and the internal jugular vein are preserved.

*Type III:* The spinal accessory nerve, internal jugular vein and the sternocleidomastoid muscle are preserved.

*Extended Radical Neck Dissection:* The lymph node groups and/or additional structures not included in the classic neck dissection are resected.

#### PRE-SURGICAL PREPARATION

The patient is placed on the OR table in the supine position. The anesthesiologist administers general endotracheal anesthesia, after which the patient is positioned for surgery. The patient's head is extended moderately with the affected side of the face and neck facing upward. The shoulder on the operative side is slightly rotated so that the surgical field from the posterior midline of the neck to the anterior midline of the neck is accessible. The face and neck skin prep is extensive and starts at the hairline and goes down to the nipples, as well as down to the table both anterior and posterior. If a skin graft is to be harvested, the thigh is also prepped and draped using sterile towels that are placed over the sterile area for later use as the dermal skin graft before the neck wound is closed. This graft is used to protect the carotid artery due to the possibility that the patient has undergone extensive previous or preoperative radiation therapy.

The patient is draped with a head drape, which consists of a drape sheet and two towels under the head with the upper towel wrapped around the head and clamped. The neck is draped with folded towels and secured with sterile plastic adhesive. Some surgeons' preference is to suture or staple the sterile towels to the skin. Once the sterile towels are in place, the fenestrated sheet, (diagram A), is then placed over the patient.

Fenestrated Laparotomy drape with reinforcement around the fenestration

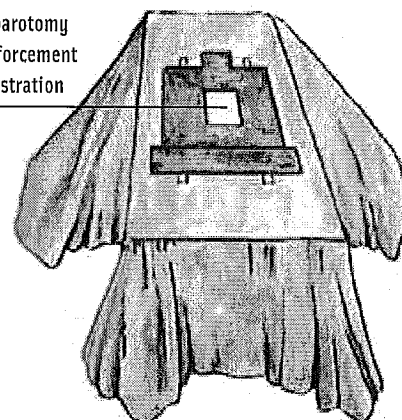


Diagram A

Instrumentation setup for this surgical procedure varies, depending on the surgeon's preference. The surgical technologist should familiarize him or herself with the surgeon's preference card, however, each setup does include the following:

- 50 Mosquito hemostats, curved
- 8 Allis forceps
- 8 Kelly hemostats
- 8 Pean forceps
- 4 Thyroid tenacula
- 4 Babcock forceps
- 2 Right angle clamps
- Assorted needle holders
- 12 Towel clamps
- 2 Tonsil suction tubes
- 1 Trousseau tracheal dilator
- 2 Rake retractors
- 2 Army-Navy retractors
- 2 Richardson retractors
- 2 Vein retractors
- 4 Skin hooks, 2 single and 2 double
- 1 Gelpi retractor
- 4 knife handles, no. 3, with no. 10 and no. 15 blades
- 1 Tracheal hook
- 2 Mayo scissors, straight and curved
- 2 Metzenbaum scissors
- 2 scissors, small, curved, sharp and blunt
- 4 Tissue forceps, 2 with and 2 without teeth
- 2 Adson tissue forceps
- 2 Brown-Adson tissue forceps
- 1 Periosteal elevators
- 2 Freer elevators
- 1 Bayonet forceps
- Brown or Stryker dermatome (if a skin graft is anticipated)

#### EQUIPMENT:

- Suction
- Electrosurgical unit (ESU)
- Scales (to weigh sponges)

#### SUPPLIES:

- Foley catheter and urimeter
- Basin set
- Marking pen
- Suction tubing
- Electrosurgical pencil

- Needle magnet or counter
- Graduate
- Bulb syringes (2)
- Dissectors (peanut)
- Umbilical tapes, vessel loops
- Nerve stimulator (locator)
- Suction drainage unit (Hemovac)
- Lap sponges
- 4x4 Raytech sponges

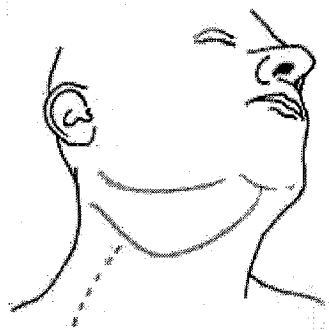
As with instruments, equipment and supplies vary depending on surgeon preference, so it is always a good idea to familiarize oneself with the surgeon's preference card.

The last four decades have made way for progressive advances to occur, giving an understanding of cervical fascial planes, lymphatic drainage patterns, preoperative staging and extracapsular spread.

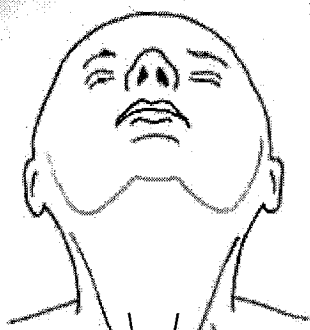
#### THE SURGICAL PROCEDURE

The surgical incision is made starting at the lateral neck from beneath the jaw to the supraclavicular area (diagram B). Skin flaps are mobilized while hemostasis is achieved using fine hemostats as well as ligatures on bleeding vessels. Once the skin flaps are freed, the surgeon places a traction suture in different areas of the skin flap and then places a hemostat on the end. This is done to retract the skin flap for better exposure. Using curved scissors, the anterior trapezius muscle is exposed, as well as the external jugular vein. The trapezius muscle and the external jugular vein are clamped, ligated and divided. The internal jugular vein is then found, isolated and divided. The omohyoid muscle is identified and transected. The fatty tissue in the neck houses lymph nodes. These lymph nodes are dissected away from other structures and the common carotid artery and vagus nerve are identified (diagram C).

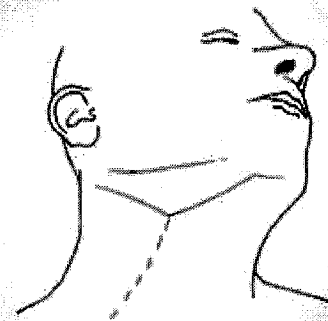
The thyrocervical artery is then clamped, divided, and ligated. The posterior triangle are dissected starting at the anterior of the trapezius muscle and continuing to the bra-



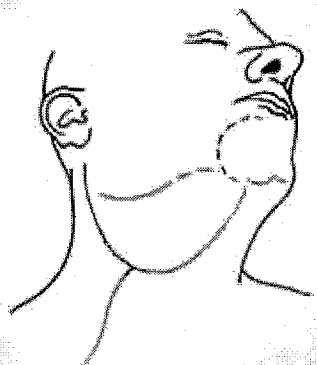
Latyshevsky and Freund



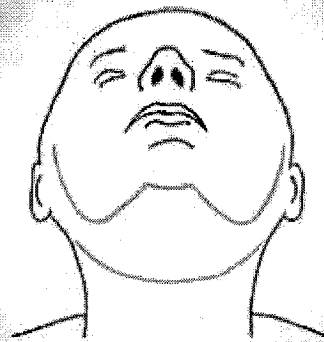
Freund



Crile



Incision used for unilateral supra-omohyoid neck dissection



Incision used for bilateral supra-omohyoid neck dissection

Diagram B

chial plexus, the levator scapulae and the scalene muscles. Branches of the cervical and suprascapular arteries are identified then clamped, ligated, and divided. Once the anterior portion dissection is complete, the omohyoid muscle is severed where it attaches to the hyoid bone. Once hemostasis is controlled, all hemostats are removed. The surgical field is then covered with warm, moist, sterile laparotomy packs. Next, the sternocleidomastoid muscle is cut and retracted out of the way. At this point the submental space is dissected from fatty tissue that houses lymph nodes, starting upward and working down. The fascia that is deep on the lower portion of the mandible is then incised and the facial vessels are then divided and ligated.

Entering the submandibular triangle, the submandibular duct is divided and ligated. The submandibular glands that have fatty tissue and lymph nodes surrounding them

are dissected going toward the digastrics muscle. The facial branch of the external carotid artery is identified and divided. Parts of the digastrics, as well as the stylohyoid muscles, are then cut where they attach to the hyoid bone and mastoid. The top end of the internal jugular vein is elevated and divided, and the mass is removed.

The entire surgical site is checked for any bleeding and irrigated with warm saline solution. If a skin graft is needed, it is placed over the bifurcation of the carotid artery downward about four inches, then sutured using 4-0 absorbable suture on a small cutting needle. Tubing for the Hemovac drain, if that is the surgeon's preference, is placed in the wound. The skin flaps are then approximated and closed with interrupted, fine non-absorbable sutures or skin staples. A pressure dressing is applied to the neck, which also depends on the surgeon's preference.

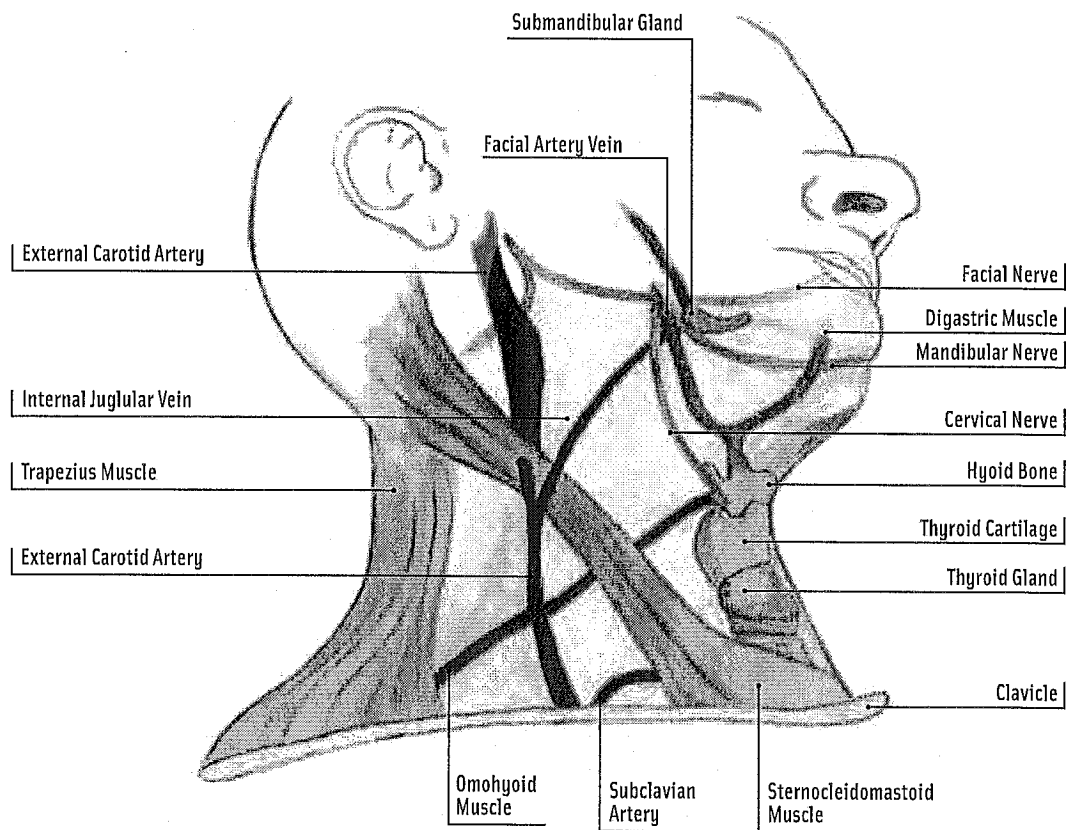


Diagram C

### RECONSTRUCTIVE PROCEDURES

When reconstructive procedures are performed, the method used depends on the surgical defect. The surgical wound may be closed primarily or with split-thickness skin grafts. Local flaps may be used. These skin grafts are used for facial or intraoral defects. For nasal and facial defects, full-thickness skin grafts are used. The pectoralis major musculocutaneous flap is an example of a regional flap. The radial forearm flap, free jejunal flap and rectus abdominis flap are used for microvascular tissue transfer. The iliac crest flap is used for microvascular osteocutaneous flaps. All of these flaps are used to restore function and cover defects. The grafts and flaps listed above are performed when it is deemed necessary due to large defects that are created. When microvascular flaps are used, surgical and anesthesia time increase significantly. This is because veins and arteries are connected



Radical Neck Dissection

Reprinted with permission of WoltersKluwer



microscopically. Nerve grafts and bone grafts may also be used, and must be connected by using plates and screws.

In a 2000 study, published in *The Laryngoscope*, it was determined that allograft, or cadaveric tissue, may be useful in this type of procedure. Benefits of allograft include a reduction in the the surgical time, as well as the amount of time that a patient is under general anesthesia. AlloDerm® is a dermal graft that is derived from banked human tissue. Because it has been decellularized, AlloDerm® does not induce an immune response in the body, reducing the probability that the graft will be rejected.<sup>5</sup> The study concludes that a previously-irradiated field does not adversely affect the integration of AlloDerm®, making it a potentially viable alternative to an autograft option—or the harvesting of the patient's own tissue for reconstructive purposes. Originally developed for use in burn patients, it has recently made strides toward wider acceptance and utilization in different surgical settings.

Doppler units are used intraoperatively as well as postoperatively. It is paramount to have thorough nursing assessment skills so that occlusions and/or spasms of the vessels can be spotted in order for the transplanted flap to survive. The patient's average hospital stay is 13-15 days.

#### SPECIAL NOTE:

- \* Make sure the blood bank has blood available and ready for the patient as ordered.
- \* The surgical sponges must be weighed and the irrigation fluids measured accurately.

#### ABOUT THE AUTHOR




Deborah D Lamb, CST, graduated from Hinds Community College in Jackson, Mississippi as a President's Scholar in 1997. She worked at a Level I trauma center in Jackson until 1998, when she transferred to a small hospital in Athens, Alabama, where she worked until 2000. After spending six years as a vet tech, Ms Lamb decided to retire, but she continues to maintain her certification.

AlloDerm® is a registered trademark of LifeCell Corp.

#### References

1. Kazi, RA. "The Life and Times of George Washington Crile: An Outstanding Surgeon." *The Internet Journal of Otorhinolaryngology*. 2003. Vol 2, No 2.
2. Shaha, A. 2007. "Editorial: Complications of Neck Dissection for Thyroid Cancer." *Annals of Surgical Oncology*. Accessed: August 19, 2010. Available at: <http://www.ncbi.nlm.nih.gov/pmc/articles/PMC2244697/>.
3. American Head & Neck Society. 2005. "Hayes Martin Biography." Accessed: August 19, 2010, Available at: <http://www.ahns.info/foundation/hayesmartin.php>.
4. Martin, H. "The Treatment of Cervical Metastatic Cancer." *Annals of Surgery*. 1941. Vol 114, No 6. Available online at: <http://www.ncbi.nlm.nih.gov/pmc/articles/PMC1385835/pdf/annsurg00378-0016.pdf>.
5. Dubin, M; Feldman, M, et al. "Allograft Dermal Implant (AlloDerm) in a Previously Irradiated Field." *The Laryngoscope*. Lippincott Williams & Wilkins, Inc. Philadelphia. 2000.



#### Earn CE Credits at Home

You will be awarded continuing education (CE) credits toward your recertification after reading the designated article and completing the test with a score of 70% or better. If you do not pass the test, it will be returned along with your payment.

Send the original answer sheet from the journal and make a copy for your records. If possible use a credit card (debit or credit) for payment. It is a faster option for processing of credits and offers more flexibility for correct payment. When submitting multiple tests, you do not need to submit a separate check for each journal test. You may submit multiple journal tests with one check or money order.

**Members this test is also available online at [www.ast.org](http://www.ast.org).** No stamps or checks and post to your record automatically!

**Members: \$6 per credit**  
(per credit not per test)

**Nonmembers: \$10 per credit**  
(per credit not per test plus the \$400 nonmember fee per submission)

After your credits are processed, AST will send you a letter acknowledging the number of credits that were accepted. Members can also check your CE credit status online with your login information at [www.ast.org](http://www.ast.org).

#### 3 WAYS TO SUBMIT YOUR CE CREDITS

**Mail to:** AST, Member Services, 6 West Dry Creek Circle Ste 200 Littleton, CO 80120-8031

**Fax CE credits to:** 303-694-9169

**E-mail scanned CE credits in PDF format to:** [memserv@ast.org](mailto:memserv@ast.org)

For questions please contact Member Services - [memserv@ast.org](mailto:memserv@ast.org) or 800-637-7433, option 3. Business hours: Mon-Fri, 8:00a.m. - 4:30 p.m., mountain time

*Pectus Carinatum:*

# Pigeon Chest

Tracy Cheek

*Pectus carinatum* is a deformity of the chest wall distinguished by a protuberant sternum and rib cage. It is caused by congenital and genetic abnormalities found in pediatric patients. This unusual deformity can have both physiological consequences and significant psychological impacts on the untreated patient.

## PATIENT CASE STUDY

The patient is a 13-year old Caucasian male who presented with a protuberant sternum and characteristic *pectus carinatum*. The chest wall deformity has slowly been increasing in prominence and distortion over time as the patient has grown, causing discomfort and pain on occasion. The patient was experiencing bouts of fatigue and dyspnea (shortness of breath) during physical activity, which became more frequent in the last year. The young man recently expressed concerns to his parents that he felt his chest deformity was hindering him from normal physical activities at school, and that he felt self-conscious of his appearance, particularly around his peers. The patient's parents noted that he was beginning to isolate himself from both friends and family and showing signs of depression. They articulated that, at this point, the primary concern with their son was his emotional state of mind, and that it was directly related to the cosmetic appearance of his chest wall deformity. The patient has a past history psychological issues and problems with socialization. The parents felt that the next logical step would be surgical intervention to repair the *pectus carinatum*.

## LEARNING OBJECTIVES

- ▲ Review the relevant anatomy for this procedure
- ▲ Examine the set-up and surgical positioning for this procedure
- ▲ Compare and contrast the various genetic disorders that may cause *pectus carinatum*
- ▲ Evaluate the step-by-step procedure for surgical correction of *pectus carinatum*
- ▲ Assess the postoperative precautions and recovery time for this procedure

## THE DISEASE

*Pectus carinatum* is an uncommon deformity of the anterior chest wall that is typically characterized by a protruding breast bone (sternum) and ribs caused by an overgrowth of the costal cartilages. It is a pediatric disease that can present solely as a congenital abnormality or in conjunction with other genetic disorders. It frequently goes unrecognized until adolescence, where it is predominantly seen in males, and typically increases in severity with age, particularly during growth spurts. It is sometimes referred to as “pigeon chest,” as it causes the patient’s chest to have the appearance of a bowed bird’s chest.<sup>1</sup>


Treatment for *pectus carinatum* includes both surgical and nonsurgical options. Children with mild forms of *pectus carinatum* will often only require nonsurgical treatments, which can include being fitted with an external pressure brace or no treatment at all. Similar in theory to how orthodontic braces work on the teeth, a pressure brace applies a constant, gentle pressure against the bone (in this case the sternum), which over time pushes the bone back into normal anatomical position. The number of days, as well as the amount of time per day that a child wears the brace until desired results are accomplished will be dependent on the amount of severity in disproportion of the child’s chest. Although this treatment option has been shown to provide positive results over time, some parents have found that it is difficult to keep their child from taking off the brace due to it being uncomfortable to wear, which reduces the overall therapeutic process.<sup>1</sup>

Patients with moderate to severe *pectus carinatum* will require surgical intervention. Surgical treatment involves removing the cartilages that project the sternum forward

and suturing them into normal, anatomical position. As the patient heals, the cartilage regenerates and forms in the new position. Surgical treatment can take anywhere from two to six hours, depending on the amount of cartilage to be removed, and a postoperative hospital stay can be anywhere from three to seven days, depending on complications and pain management.<sup>1</sup>

The most common method of surgical treatment for *pectus carinatum* is the Ravitch procedure. It involves cutting the costal cartilage away from each side of the sternum and making the sternum lie flat. In this procedure, the surgeon may choose to utilize stabilization bars that can be inserted into the sternum to help maintain its new shape. These bars remain in place permanently. Drains are placed on each side of the chest to evacuate fluids from the wound and are sutured in place. The Ravitch procedure has a 97 percent satisfaction rate among patients.<sup>2</sup>

*Pectus carinatum* is mainly an asymptomatic disease with little or no interference with the patient’s cardiopulmonary function. However, as studies have suggested, there can be decreased lung capacity and mitral valve prolapse associated with the disorder. The outward projecting and rigidity of the sternum can impair the gas exchange process of the cardiopulmonary system, which in turn can decrease a patient’s physical stamina. Additionally, connective tissue disorders affecting major blood vessels and heart valves are being seen along with emphysema, respiratory tract infections and dyspnea. Many patients experience pain and tenderness in the chest area. Yet among all of these symptoms, it appears the primary concern for patients suffering from *pectus carinatum* and their families revolves around the significant cosmetic concerns this disorder can present.<sup>3</sup>

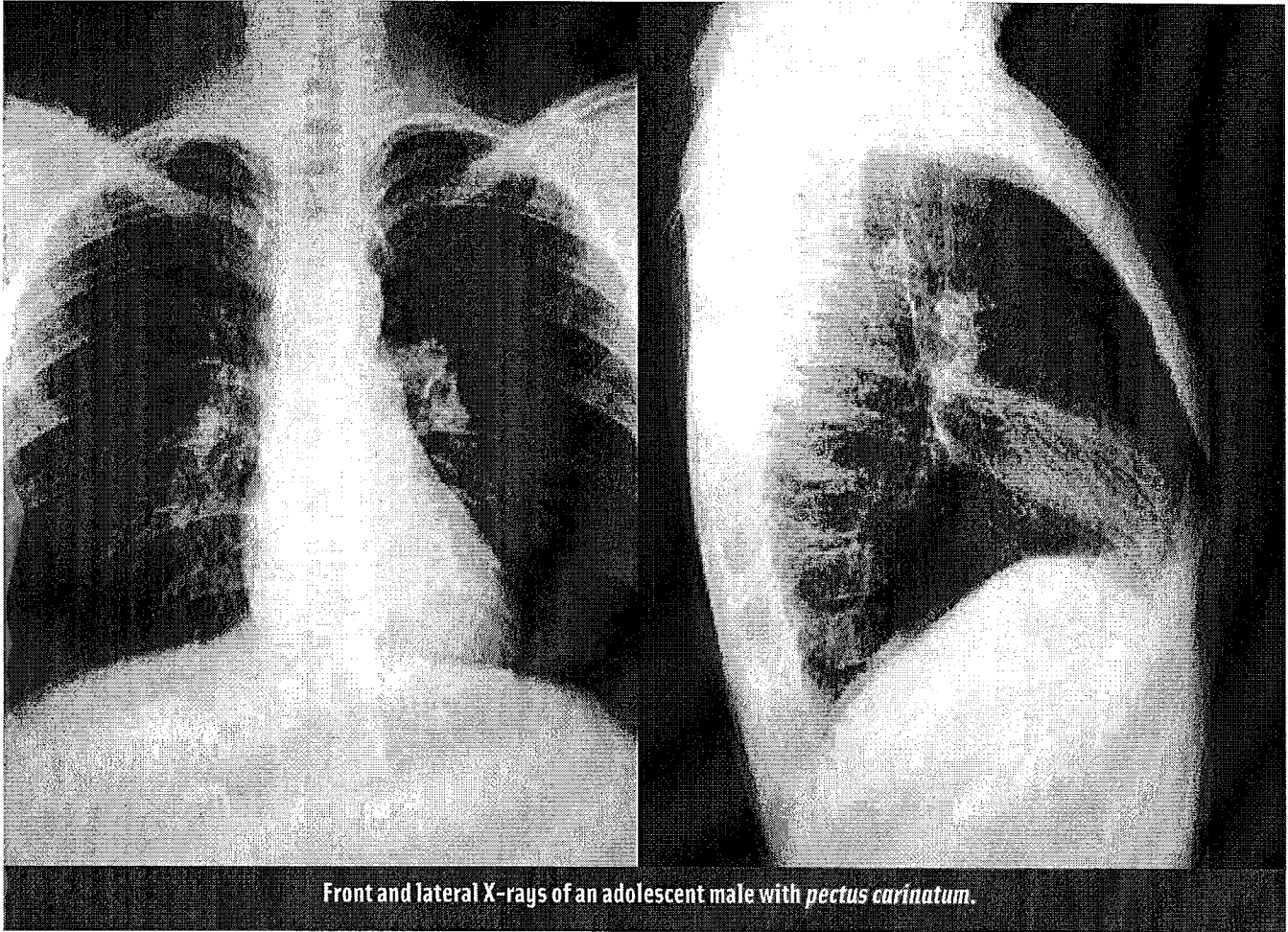


An external pressure brace.

## EPIDEMIOLOGY

According to the Seattle Children’s Research Foundation, *pectus carinatum* occurs in approximately one out of every 1,500 children. It is five times more likely to occur in males than in females.<sup>1</sup>

*Pectus excavatum* is another chest deformity that is similar to *pectus carinatum*, but has the reverse effect on the patient’s sternum. This disorder presents as an inverted, or “funnel chest,” as opposed to *pectus carinatum*’s protruding chest. *Pectus excavatum* generally affects the lower half of the sternum and is much more common than *pectus carinatum*, affecting one in every 500-1,000 children. Like *pectus carinatum*, *pectus excavatum* is also believed to be caused from genetic factors passed down familial lines.<sup>4</sup>



### ANATOMY AND PHYSIOLOGY

The thorax (chest) is a conical-shaped, airtight, protective compartment made up of an osseo-cartilaginous cage. The primary purpose of the thorax is to protect the principal organs of respiration and circulation (the lungs and heart).<sup>5</sup>

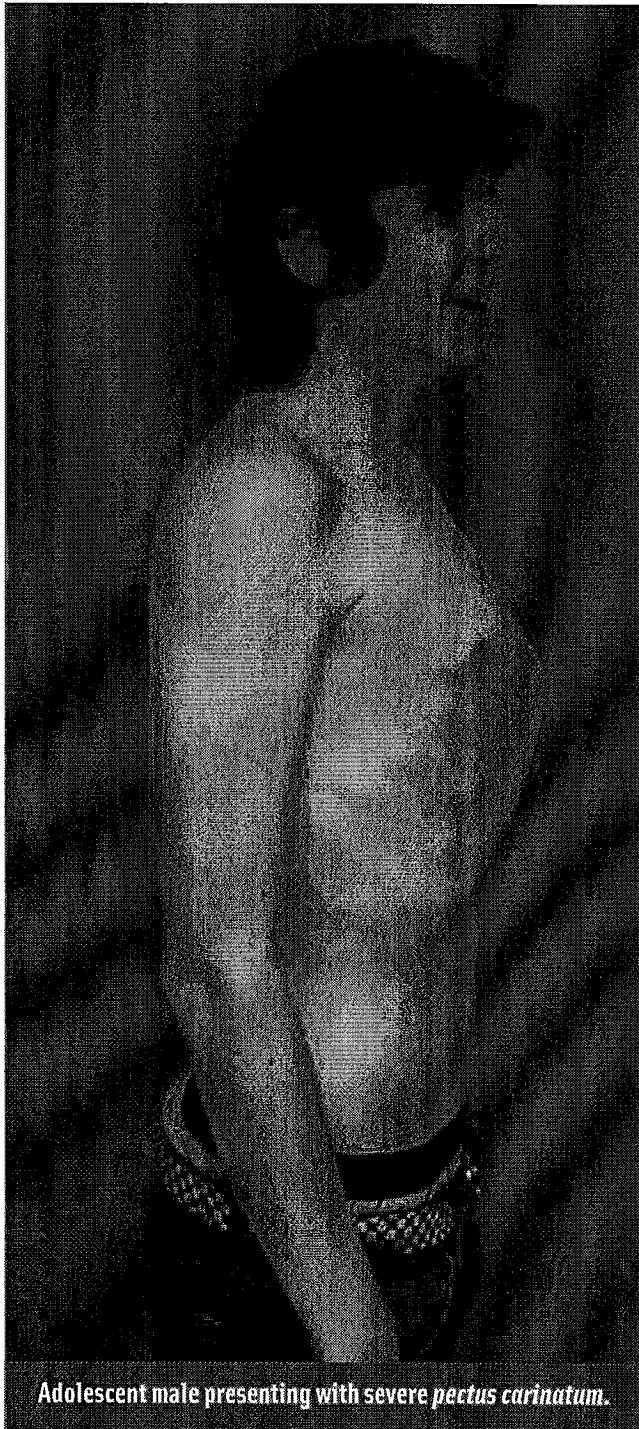The thorax is narrow at the superior end and wide at the inferior end. Its anatomical boundaries include the 12 thoracic vertebrae (T-1 through T-12), which form the posterior boundary; the sternum and costal cartilages, which form the anterior boundary; and the ribs, which are at each of the lateral margins.<sup>5</sup>

The human body contains 24 ribs, the first seven superior ribs are considered the “true ribs,” and they are attached to the sternum by the costal cartilages. The purpose of the costal cartilages is to allow the ribs to stretch forward and back during respirations. The eighth, ninth, and tenth ribs are considered the “false ribs.” These ribs adjoin with the costal cartilages of the superior ribs. The eleventh and twelfth ribs are also known as false ribs. These ribs are not

joined with the sternum by the costal cartilages. The false ribs are also known as the “floating ribs.”<sup>5</sup>

The superior opening of the thorax is wide from side to side. It is formed by the first thoracic vertebrae (T-1) posteriorly, the superior portion of the sternum anteriorly, and the first rib laterally. The inferior opening of the thorax is formed by the twelfth thoracic vertebrae (T-12) posteriorly, the eleventh and twelfth ribs laterally, and the seventh, eighth, ninth, and tenth rib cartilages (costal cartilages) anteriorly. The costal cartilages form the subcostal angle at the xiphoid process. The diaphragm, a large sheet of muscle, extends across the bottom of the thoracic compartment and separates the thoracic cavity from the abdominal cavity.<sup>5</sup>

The spaces between the ribs, known as the intercostal spaces, are occupied by muscles known as the intercostal muscles, which assist in the mechanics of respiration. There are 11 external intercostal muscles that aid in inhalation and 11 internal intercostal muscles that aid in exhalation. Each of these muscles has its own blood supply and inner-



Adolescent male presenting with severe *pectus carinatum*.

vation. The intercostal arteries supply blood to the muscles and branch from the internal thoracic artery and the aorta. The intercostal veins connect with the mammary veins and the azygos and hemiazygos veins. The intercostal nerves, branch from the thoracic spinal nerves and the ventral rami nerves, innervate the intercostal muscles.<sup>5</sup>

The pectoralis major is a large muscle group that is located on the sides of the chest, superiorly and contralaterally. This group of muscles branch from the sternum, the superior ribs, and the clavicle area. They are innervated by the lateral and medial pectoral nerves.<sup>6</sup>

The male thorax is different from the female thorax. In the male, the thorax has a larger capacity than that of the female. The level of the upper sternum is at the second thoracic vertebrae (T-2), whereas in the female the level of the upper sternum is at the third thoracic vertebrae (T-3). Additionally, the upper ribs in the male thorax are less mobile than the female thorax.<sup>5</sup>

#### DISEASE PRESENTATION

There are several possible causes for *pectus carinatum*, all of which can present in three separate situations: at birth, during growth spurts and post-surgically. Generally, post-surgical presentations of the disease are due to the sternum's malunion during healing. This is seen in cases where a patient has undergone cardiac surgery, but it is fairly uncommon. Patients who develop *pectus carinatum* from surgery will require additional future surgical intervention to correct the sternal protrusion.<sup>7</sup>

Congenital presentations are the second most likely presentation of *pectus carinatum*. The newborn will have a circular chest, which develops into a protrusion at around three years of age. Often in these cases, surgical intervention to correct the deformity will take place once the child reaches puberty.

The most frequent presentation of *pectus carinatum* is in adolescent males undergoing growth spurts. This kind of presentation can come on rapidly and can be the cause of much emotional turmoil for the child and the parents. Surgical intervention in these cases is generally more for the cosmetic effects than symptomatic reasons.<sup>7</sup>

#### PATHOPHYSIOLOGY

*Pectus carinatum* can be caused by either sole congenital abnormalities or from genetic abnormalities. One type of genetic disorder associated with the development of *pectus carinatum* is Edward's syndrome, or Trisomy 18. Trisomy 18 is a genetic disorder that involves a person having extra genetic material from chromosome 18. This genetic syndrome is fairly common and occurs in females more often than males. Symptoms of Trisomy 18 include low birth weight, mental deficiency, micrognathia, microcephaly, low-set ears, clenched hands, crossed legs, round-bottomed

feet, undescended testicles, underdeveloped fingernails, and *pectus carinatum*.<sup>8</sup>

Trisomy 21 is another genetic abnormality that is commonly associated with Down syndrome and another possible contributor to the development of *pectus carinatum*.<sup>9</sup>

Marfan syndrome is another genetic disorder that has been associated with *pectus carinatum*. Marfan syndrome is a connective tissue disorder that affects the eyes, skin, heart, blood vessels, lymphatic vessels and bones. In this disorder, a genetic defect involving the gene fibrillin-1 interferes with the body's tissue-building properties and, in turn, causes an excessive growth in the long bones of the body. Symptoms of Marfan syndrome include arachnodactyly, flat feet, loose joints, learning disabilities, nearsightedness, eye problems, scoliosis, and *pectus excavatum* or *pectus carinatum*.<sup>10</sup> Although Marfan syndrome is considered an inherited genetic disease, approximately 30 percent of the children presenting with this defect have no known family history of the disorder.<sup>10</sup>

It appears the primary concern for patients suffering from *pectus carinatum* and their families revolves around the significant cosmetic concerns this disorder can present.

Homocystinuria is another genetic disorder associated with the development of *pectus carinatum*. This genetic disorder involves the inability of the body to correctly metabolize methionine, an amino acid. Similar to Marfan syndrome, homocystinuria affects the tissue building properties of the body, particularly the joints. Marfan syndrome causes the body joints to become loose, whereas homocystinuria affects the joints by causing them to be stiff and tight. Common symptoms of homocystinuria include flushed cheeks, knocked knees, long limbs, mental retardation, psychiatric disorders, highly-arched feet and chest deformities such as *pectus excavatum* and *pectus carinatum*.<sup>11</sup>

Morquio syndrome is a genetically inherited disease that affects the metabolism. The body lacks the proper enzymes to breakdown glycosaminoglycan, a specific type of sugar molecule. Morquio is associated with a group of diseases known as mucopolysaccharidoses, or MPS. The common symptoms

of Morquio syndrome include knock knees, widely-spaced teeth, macrocephaly, loose joints and an abnormal development of bones including those of the thorax.<sup>12</sup>

Multiple lentiginos syndrome is a genetic disorder that is tied to *pectus excavatum* and *pectus carinatum*. Symptoms of this syndrome include dark skin spots on the neck and chest area, delayed puberty, pulmonic stenosis, cryptorchidism, hypogonadism, *pectus excavatum* or *pectus carinatum*.<sup>13</sup> Generally, patients diagnosed with multiple lentiginos have a strong family history of the disorder.

A congenital disorder called *osteogenesis imperfecta* (brittle bone disease) is another potential cause for the development of *pectus carinatum*. This disorder is caused by a defective gene that is responsible for the production of collagen. Type I collagen is an important component of bone building. Common symptoms of *osteogenesis imperfecta* include multiple bone fractures, deafness, eye discolorations, loose joints, flat feet, bowed limbs, scoliosis, kyphosis and *pectus carinatum*.<sup>14</sup>

#### DIAGNOSTIC TESTING

The patient in the case study has been given several preoperative diagnostic tests to confirm the diagnosis of *pectus carinatum*. The physician treating the patient performed a thorough physical examination and review of his complete medical history. The patient's medical history reveals that the 13-year old has a history of emotional disorder, specifically attention deficit hyperactivity disorder (ADHD), for which he is being treated with the drug methylphenidate. Additionally, it is found that when the patient was seven-years old, he underwent a right-side inguinal hernia repair with no noted postoperative complications. No other medical interventions or diagnoses are found in the patient's history and physical exam.<sup>15</sup>

Diagnostic testing continues with an X-ray exam to view the patient's chest abnormalities and verify any signs of scoliosis. Results of the X-ray are conclusive, revealing that the patient has a moderate protrusion of the thoracic wall with an over growth of five of the costal cartilages, contralaterally. No scoliosis is noted. A computed tomography (CT) scan is performed to review the patient's chest anatomy. His lungs and heart appear normal in size for the patient's age and build.<sup>15</sup>

A pulmonary function test (spirometry) is performed to identify any lung abnormalities and to verify lung function. The physician also performs an electrocardiogram (ECG) to observe the electrical conductivity of the patient's heart

and an echocardiogram to confirm the patient's heart structure is sufficient and functioning properly. The spirometry, electrocardiogram and echocardiogram show normal heart and lung function.<sup>15</sup>

Several blood tests are performed, including a complete CBC, metabolic, enzyme and chromosomal study panels. These blood tests are performed to confirm and rule out genetic disorders associated with pectus carinatum. No genetic disorder is identified.

Finally, the patient has a urine analysis conducted to verify kidney function and rule out diabetes.<sup>15</sup>

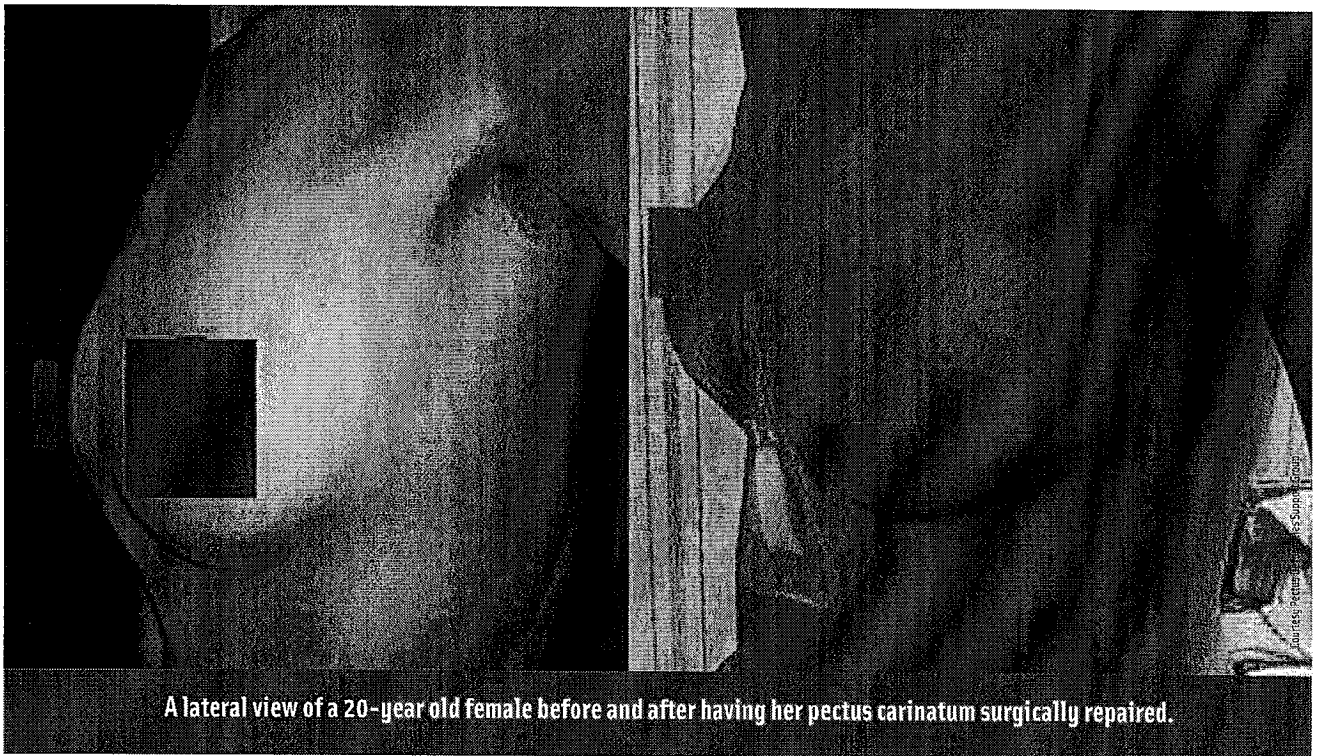
### PREOPERATIVE PREPARATION

The patient is scheduled for surgery at 13:30 hours. The surgical technologist (ST) and the circulator begin preparing the operating room for the procedure at approximately 12:50 hours. Per the surgeon's preference card, the pediatric instrumentation trays pulled for the case consist of a plastics set, a minor orthopedic set, and several specialty items that are requested by the surgeon for this procedure, including Lane bone holding forceps, a Shaw scalpel, additional Freer elevators (Freer elevators are included in the minor orthopedic set, however, the surgeon uses several during this particular procedure as they become dull, and requested to have extra on hand), and two Davol drain systems.

A major laparotomy module is pulled, which includes the basic items needed for setting up the sterile field, including:

- A back-table cover
- 77 x 108 pediatric drape
- Mayo stand cover
- 32-oz plastic basin
- Lap sponges
- X-ray-detectable sponges
- Bulb syringe
- Large basin
- Specimen cups
- Rigid light handle covers
- Towels
- Emesis basin
- Sterile marking pen
- #15 blades
- Electrosurgical-tip-cleaner pad
- Electrosurgical pencil with needle tip and holster
- Suture garbage bag
- Magnetic needle holder/counter
- Three sterile surgical gowns

Additional sterile items pulled for the procedure include bone wax, adhesive skin closure strips, suction tubing, cord



A lateral view of a 20-year old female before and after having her pectus carinatum surgically repaired.

and blade for Shaw scalpel, and several sutures including 2-0, 3-0, and 4-0 polyglactin 910 RB-1 and 4-0 polyglicaprone 25 CT-1.

At approximately 13:10 the ST began establishing the sterile field, starting by arranging the operating room furniture into place for the procedure and ensuring all items had been pulled for the case prior to opening. The ST opens the major laparotomy pack on the back table and places the instrumentation sets on a prep stand. Once the items are placed, the ST and the circulator don sterile face masks and begin opening the items to establish the sterile field. During this time, the circulator adjusts the room temperature and confirms with the ST what local anesthetic will be used for the procedure, (one percent lidocaine with epinephrine, 1:200,000). Once the back table (laparotomy pack) and the instrumentation sets are opened, the ST proceeds to the scrub sink to perform a surgical scrub, according to facility policy. After the scrub, the ST returns to the operating room and dons his or her gown and gloves. The circulator assists the ST as needed.

Once the ST is gowned and gloved he or she organizes the back table and performs an initial sponges, sharps, and instrument count, according to facility policy, with the circulator. At the conclusion of the initial count, the circulator pours sterile water and normal saline solutions in labeled bowls on the back table and prepares the local anesthetic. At this time, the circulator exits the operating room to get the patient. The ST continues setting up the Mayo stand and back table for the procedure. The anesthesia provider is now present in the room and advises that the patient had been given an epidural of morphine sulfate at 13:00 hours.


At approximately 13:15 the circulator returns to the operating room with the 13-year old male patient, who is conscious and alert. He has been given a preoperative sedative of midazolam (1 mg) to reduce anxiety. Shortly afterward, the surgeon and a resident surgeon enter the oper-

For some patients, additional surgical intervention will be required in the future due to inadequate contracture of the chest wall that resulted in an undesirable cosmetic look. It is for this reason that it is desirable to wait for a child's skeletal system to reach maturity prior to surgical intervention.

ating room and talk briefly with the patient. The surgeon confirms with the ST his or her suture preference and that two Davol drains are available for the procedure.

At 13:25 the patient is moved to the operating table, anesthetized, and intubated by the anesthesia provider. The circulator and the anesthesia provider assist in positioning the patient in supine position with his chest slightly hyperextended with a rolled towel. The patient's head is placed on a foam donut pad with his arms tucked at the sides with a sheet. A small pillow is placed under his knees, and a safety strap is applied. The circulator applies a dispersive electrode pad to the patient's posterior near the sacrum. The anesthesia provider adjusts the operating table height to an optimal level and at a slight reverse Trendelenburg position, as requested by the surgeon.

Once the patient is positioned, the circulator performs a skin prep on the patient's chest, beginning at the incision site and extending out to each side contralaterally, from chin to umbilicus, down to the table sides. Povidone-iodine solution is used as the skin prep agent. During this time, the surgeon and resident proceed out of the operating room to perform a surgical scrub, after which the ST assists them



Superior view of a 20-year old female before and after having her pectus carinatum surgically repaired.



with drying, gowning and gloving.

With the skin prep completed, the ST assists the surgeon with draping the patient. Draping consists of four folded towel drapes secured with Backhaus towel clips and a fenestrated, pediatric chest drape.

At approximately 13:30 hours, the surgeon performs a "time out" according to facility policy. The "time out" procedure verifies the patient's name, identification number, operative procedure and site (correct surgical site is marked on the patient's chest with a sterile surgical marking pen). Additionally, it is confirmed that the patient has no known allergies,<sup>15</sup> preoperative medications have been given, and consent has been signed. The ST, circulator, anesthesia provider, and resident acknowledge this information.

The ST moves the Mayo stand and back table into position and begins laying out the electro-surgical pencil, suction, Shaw scalpel and accessory light handles on the operative field and prepares for the intraoperative portion of the procedure.

#### INTRAOPERATIVE PROCEDURE

The ST places two X-ray-detectable sponges at the operative sight and hands the surgeon the Shaw scalpel. The surgeon begins by making a transverse inframammary incision on the left side of the patient's chest with the scalpel. The incision is carried down through the dermis, epidermis, and subcutaneous tissues. Hemostasis is achieved with periodic use of the electro-surgical pencil; however, minimal hemorrhaging is seen due to the surgeon's use of the Shaw scalpel and its cutting and coagulating properties.

As the surgeon continues incising downward through the layers of tissue, the ST prepares the Cobb elevator. Utilizing the Cobb elevator, the surgeon makes a skin flap and elevates it from the pectoral muscles superiorly and inferiorly. The pectoral muscles are then lifted off the costal cartilage on both sides. The surgeon observes that there appear to be five abnormal cartilages on each side of the patient's rib cage.

The ST retrieves the Cobb elevator and hands the surgeon the Freer elevator and the Lane bone holding forceps. Using the Freer elevator and the Lane bone forceps intermittently, the surgeon proceeds to remove each cartilage by incising the perichondrium, stripping it off of the cartilage, and then removing the cartilage, leaving behind the perichondrial bed.<sup>15</sup> The ST provides the surgeon with the electro-surgical pencil and suction as needed. As pieces of cartilage are removed, they are placed in a sterile specimen

cup. All pieces of cartilage are placed in one sterile specimen cup per the surgeon's request.

The surgeon removes all 10 of the abnormal costal cartilages and then proceeds to pull the sternum down into a more anatomical position. The ST hands the surgeon a prepared 2-0 polyglactin 910 RB-1 suture on an 8" Crile-Wood needle holder. The surgeon takes the suture and begins to imbricate the costal beds. This method of overlapping the cartilages and retracting the pectoral muscles pulls the sternum downward and contracts the thoracic wall. The ST provides the electro-surgical pencil, irrigation, suction and suture scissors as requested throughout this process. Care is taken to change out soiled X-ray-detectable sponges as necessary.

Once the surgeon completes pulling the sternum downward with the suturing technique, the ST prepares two Davol evacuating drainage systems, one 1/4 inch and one 3/16 inch, for use, along with additional 2-0 polyglactin 910 suture to secure the drains. The surgeon takes the 1/4-inch Davol drain and places it under the pectoral muscle. It is then re-approximated and affixed to the periosteum of the sternum using the 2-0 polyglactin 910. The surgeon then takes the 3/16-inch Davol drain and places it in the subcutaneous space. Once the drains are in place, the surgeon closes the skin using 3-0 and 4-0 polyglactin 910 in the subcutaneous tissue, and 4-0 polyglactin 910 in the skin (dermis and epidermis). He or she administers local anesthetic (one percent lidocaine with epinephrine, 1:200,000) at the operative site to provide additional postoperative pain management and hemostasis.

The ST initiates a final count of sharps and sponges with the circulator during the skin closure and prepares the postoperative dressings. A wet and dry sponge is also readied in anticipation of cleaning the operative site once the skin closure is complete.

While the surgeon finishes up the skin closure, the ST ensures all pieces of the cartilage are in the specimen cup securely. The cup is labeled appropriately, according to facility policy, with the patient's name, identification number, and the name of the specimen contents. This information is verified with the patient's chart. The cup is then handed off to the circulator, who transports it to pathology in a dry state.

#### POSTOPERATIVE PROCEDURE

At the completion of the skin closure the surgeon requests a wet and dry X-ray-detectable sponge to clean off the patient's

operative wound site and to remove any remaining skin prep solution. The ST assists the surgeon with this task. Once the wound has been cleaned, the ST hands the surgeon bacitracin antibiotic ointment (placed on the back of a tissue forceps handle), which the surgeon applies liberally onto the closed suture line. Using smooth Adson tissue forceps, pre-cut adhesive skin closure strips (the strips are cut into thirds per the surgeon's request) are then applied to the site followed by folded, sterile 4x4 dressings and padded tape.

Once the dressings are in place the ST carefully pulls back the Mayo stand and, in keeping with proper sterile technique, pushes the back table several feet away from the operative table as to allow for adequate room to remove drapes, disposable suction tubing and electrical cords from the field and provide space to move the patient to the gurney. After removing the disposable items, the ST removes his or her outer gloves and provides assistance in moving the patient off the operating table to the gurney. Once the patient is securely on the gurney and out of the operating room, the ST begins the postoperative clean up procedure.

All sharps (blades, hypodermic needles, suture needles and electrosurgical pencil tips) are verified with the count board and disposed of properly, according to facility policy, in the sharps container. Dirty instrumentation is separated from clean instrumentation. Dirty, sharp instrumentation is placed in a separated basin with sterile water while non-sharp, dirty instrumentation is placed in another basin with sterile water. Each of the basins is marked, according to facility policy, with the operating room number, the ST's initials, the time of the surgical procedure and the date. Clean instrumentation is returned to its set container with the lid on. All instrumentation is then placed in the dirty case cart. All sponges, disposable towels and items are rolled up in the back table cover and discarded. The facility's postoperative surgical team member (PST) removes the used suction canisters, takes out the waste containers and cleans and mops the operating room to prepare it for the next case. The ST doffs his or her gown and gloves, washes his or her hands and dons new nonsterile gloves. After ensuring all instrumentation is in placed in the case cart, the ST proceeds to the dirty dumb waiter and transfers the items to the facility's sterile processing and distribution center (SPD) for decontamination and sterilization. Upon return, the ST removes the gloves and washes his or her hands again. All unused core supplies are acquired from the operating room and returned to their specified locations in the sterile core.

## PATIENT POSTOPERATIVE

At 15:37 hours, the patient arrives at PACU for recovery and stays for approximately one hour. He is in a semi-conscious state upon his arrival, where he is given 10 milligrams of hydrocodone for postoperative pain management. At approximately 16:40, the patient is transferred to his hospital room.<sup>15</sup>

The first night post-operatively, the patient reports several episodes of moderate to severe postoperative pain in the chest area. On a scale of one to 10, the patient advises that he is experiencing an eight. Consequently, the patient is given additional hydrocodone the following night to ease his symptoms and help him sleep. On the second postoperative day, the patient's pain has lessened and he is more comfortable than he had been the night before. On day three, the patient has his Davol drains removed and is discharged from the hospital. A two-week postoperative appointment is made for the patient.<sup>15</sup>

The patient and his parents are instructed on postsurgical at-home care. They are advised to keep the incision site clean and dry, and dressings are to be changed daily. Any signs of redness, swelling or puckering around the incision site are indications of infection and the parents are directed to contact the doctor immediately if this is the case. The patient is given a breathing treatment machine (spirometer) to improve lung function while healing.

The patient is directed to limit his physical activity level, particularly any twisting movements or rapid elevation of arms over his head for the next four months. The patient is given a list of lower extremity exercises that he is to perform for the next two weeks prior to his next postoperative checkup. He is told that light weights are beneficial for his upper extremities, but was to avoid lifting or carrying anything weighing more than 25 pounds. The patient will not be able to participate in any athletic activities for the next five months. Pain will be managed with ibuprofen and acetaminophen.

## SPECIAL CONSIDERATIONS AND COMPLICATIONS

Postoperative complications for a repair of a *pectus carinatum* include hemorrhage, infection, pleural effusion, pneumothorax, keloid scarring and pain. Generally, a patient's hospital stay will be based on postoperative complications and pain management. An average hospital stay for this procedure is anywhere from three to seven days.<sup>1</sup>

Although pain was a significant complication in the first night post-op, the patient in this case study showed marked

improvement in tolerance within 24 hours, and therefore his postoperative hospital stay was only three days. At the time of this report, the patient is healing as expected and no complications have been reported as of his last postoperative check up.<sup>15</sup>

For some patients, additional surgical intervention will be required in the future due to inadequate contracture of the chest wall that resulted in an undesirable cosmetic look. It is for this reason that it is desirable to wait for a child's skeletal system to reach maturity prior to surgical intervention.<sup>9</sup>

## CONCLUSION

Aside from the apparent physiological problems resulting from a pectus abnormality, pediatric patients can have considerable emotional issues that affect their daily lives. As with the patient in the case study, although he did suffer occasional pain and discomfort related to the pectus carinatum, and consequently physical activities were cut short due to dyspnea, there was clearly a negative social impact that the deformity was having on his life. His self image and confidence were causing him to isolate from his peers and family members, and he was beginning to show progressive signs of clinical depression. Already having a past medical history of psychiatric behavioral issues, it was apparent that this physical abnormality was causing additional emotional stress on the child that could possibly have devastating consequences in the future if surgical intervention was not taken.

## ABOUT THE AUTHOR



Tracy Cheek is a surgical technology student at San Joaquin Valley College in Fresno, California. Prior to going back to school to pursue this career, she spent 21 years in the fire service, working for the California Department of Forestry and Fire Protection. She is currently in her clinical externship at Children's Hospital of Central California and Community Regional Medical Center in Fresno, California.


## References

1. Seattle Children's Hospital Research and Foundation (July 2010), *Pectus carinatum*. Retrieved on July 30, 2010 from <http://www.seattlechildrens.org/medical-conditions/bone-joint-muscle-conditions/pectus-carinatum/>.
2. UK Pectus Excavatum and Pectus Carinatum Information (2010), *Surgical treatment*. Retrieved on July 30, 2010 from <http://www.pectus.org/surgical.htm>.
3. Cataletto, M. (August 25, 2008). Pectus carinatum. Retrieved June 30, 2010 from <http://emedicine.medscape.com/article>.
4. Family Practice Notebook (2010), *Pectus carinatum*. Retrieved July 30, 2010 from <http://www.fpnotebook.com/lung/Exam/>.
5. Rothrock, J. (2007). *Alexander's care of the patient in surgery*, 13 ed, St. Louis, MI: Mosby, Elsevier.
6. Cohen, B. (2009). *Memmler's the human body in health and disease*, 11th ed, USA: Lippincott, Williams, and Wilkins.
7. Wisegeek, (2010), What is pectus carinatum. Retrieved July 30, 2010 from <http://www.wisegeek.com/what-is-pectus-carinatum.htm>.
8. US National Library of Medicine. 2010. "Trisomy 18." Medline Plus. Accessed: August 18, 2010. Available at: <http://www.nlm.nih.gov/medlineplus/ency/article/001661.htm>.
9. Medline Plus (June 25, 2010), Pectus carinatum. Retrieved on July 2, 2010 from <http://www.nlm.nih.gov/medlineplus/ency/article/003321.htm>.
10. US National Library of Medicine. 2010. "Marfan syndrome." Medline Plus. Accessed: August 18, 2010. Available at: <http://www.nlm.nih.gov/medlineplus/ency/article/000418.htm>.
11. US National Library of Medicine. 2010. "Homocystinuria." Medline Plus. Accessed: August 18, 2010. Available at: <http://www.nlm.nih.gov/medlineplus/ency/article/001199.htm>.
12. US National Library of Medicine. 2010. "Morquio syndrome." Medline Plus. Accessed: August 18, 2010. Available at: <http://www.nlm.nih.gov/medlineplus/ency/article/001206.htm>.
13. US National Library of Medicine. 2010. "Multiple lentiginos syndrome." Medline Plus. Accessed: August 18, 2010. Available at: <http://www.nlm.nih.gov/medlineplus/ency/article/001473.htm>.
14. US National Library of Medicine. 2010. "Osteogenesis Imperfecta." Medline Plus. Accessed: August 18, 2010. Available at: <http://www.nlm.nih.gov/medlineplus/osteogenesisimperfecta.html>.
15. Children' Hospital of Central California. Patient Chart. 2010. Unpublished patient chart. Cincinnati Children's (2010), Chest/lungs diagnoses and conditions. Retrieved July 30, 2010. Available at: <http://www.cincinnatichildrens.org/health/info/chest/diagnose/pectus-carinatum.htm>.

## Additional Resources

- Frey, K. (2008). *Surgical technology for the surgical technologist: a positive care approach*, 3rd ed, USA: Delmar Cengage Learning.
- Goldman, M. (2000). *Pocket guide to the operating room*, 3rd ed, Philadelphia, PA: F.A. Davis Company.
- \*Westcoast Brace & Limb, 5311 E Fletcher Ave, Tampa, FL 33617, 813-985-5000

## CE EXAM



### Earn CE Credits at Home

You will be awarded continuing education (CE) credit(s) for recertification after reading the designated article and completing the exam with a score of 70% or better.

If you are a current AST member and are certified, credit earned through completion of the CE exam will automatically be recorded in your file—you do not have to submit a CE reporting form. A printout of all the CE credits you have earned, including Journal CE credits, will be mailed to you in the first quarter following the end of the calendar year. You may check the status of your CE record with AST at any time.

If you are not an AST member or are not certified, you will be notified by mail when Journal credits are submitted, but your credits will not be recorded in AST's files.

Detach or photocopy the answer block, include your check or money order made payable to AST, and send it to Member Services, AST, 6 West Dry Creek Circle, Suite 200, Littleton, CO 80120-8031.

**Members: \$6, nonmembers: \$10**

# Total Knee Arthroplasty

314 FEBRUARY 2010 | CE credit

- The first known total knee implant was made of \_\_\_\_\_.
  - Ivory
  - Plaster of paris
  - Wood
  - Acrylic
- From 1951 through the early 70s, the \_\_\_\_\_ was the primary knee replacement system.
  - Polycentric knee
  - Condylar knee
  - Walldius hinge
  - Geometric prosthesis
- Universal instrumentation was introduced in \_\_\_\_\_.
  - 1975
  - 1987
  - 1978
  - 1971
- Surgical navigation systems can record \_\_\_\_\_ intraoperatively.
  - Joint range-of-motion
  - Laxity
  - Kinematics
  - All of the above
- The greatest detriment to early robotics systems was \_\_\_\_\_.
  - Inaccuracy
  - Cost and complexity
  - Training personnel
  - None of the above
- A system with dedicated instruments that are compatible with different implant systems is considered \_\_\_\_\_.
  - Open platform
  - Interchangeable
  - Imageless navigation
  - Precision 4.0
- The \_\_\_\_\_ digitizes bony landmarks, monitored by a camera attached to a computer.
  - Optical tracking system
  - Fixation pin
  - Camera
  - None of the above
- The \_\_\_\_\_ is used to determine a patient's correct standing anatomy.
  - Femoral tracker
  - Femoral rotation axis
  - Mechanical axis
  - Reference for resection level
- Pins are placed with the knee in flexion to reduce \_\_\_\_\_.
  - Incidence of fracture
  - Muscle load
  - Collisions with the tibial implant
  - All of the above
- When setting up for a total knee using navigation, the ST will need \_\_\_\_\_.
  - Navigation jigs
  - Standard jigs
  - All regular total knee instruments
  - A&C only

## TOTAL KNEE ARTHROSCOPY 314 FEBRUARY 2010 | CE credit

NBSTSA Certification No. \_\_\_\_\_

AST Member No. \_\_\_\_\_

My address has changed. The address below is the new address.

Name \_\_\_\_\_

Address \_\_\_\_\_


City \_\_\_\_\_ State \_\_\_\_\_

Zip \_\_\_\_\_

Telephone \_\_\_\_\_

	a	b	c	d		a	b	c	d
1	<input type="checkbox"/>	<input type="checkbox"/>	<input type="checkbox"/>	<input type="checkbox"/>	6	<input type="checkbox"/>	<input type="checkbox"/>	<input type="checkbox"/>	<input type="checkbox"/>
2	<input type="checkbox"/>	<input type="checkbox"/>	<input type="checkbox"/>	<input type="checkbox"/>	7	<input type="checkbox"/>	<input type="checkbox"/>	<input type="checkbox"/>	<input type="checkbox"/>
3	<input type="checkbox"/>	<input type="checkbox"/>	<input type="checkbox"/>	<input type="checkbox"/>	8	<input type="checkbox"/>	<input type="checkbox"/>	<input type="checkbox"/>	<input type="checkbox"/>
4	<input type="checkbox"/>	<input type="checkbox"/>	<input type="checkbox"/>	<input type="checkbox"/>	9	<input type="checkbox"/>	<input type="checkbox"/>	<input type="checkbox"/>	<input type="checkbox"/>
5	<input type="checkbox"/>	<input type="checkbox"/>	<input type="checkbox"/>	<input type="checkbox"/>	10	<input type="checkbox"/>	<input type="checkbox"/>	<input type="checkbox"/>	<input type="checkbox"/>

Mark one box next to each number.  
Only one correct or best answer can be selected for each question.



**Earn CE Credits at Home**

You will be awarded continuing education (CE) credit(s) for recertification after reading the designated article and completing the exam with a score of 70% or better.

If you are a current AST member and are certified, credit earned through completion of the CE exam will automatically be recorded in your file—you do not have to submit a CE reporting form. A printout of all the CE credits you have earned, including Journal CE credits, will be mailed to you in the first quarter following the end of the calendar year. You may check the status of your CE record with AST at any time.

If you are not an AST member or are not certified, you will be notified by mail when Journal credits are submitted, but your credits will not be recorded in AST's files.

Detach or photocopy the answer block, include your check or money order made payable to AST, and send it to Member Services, AST, 6 West Dry Creek Circle, Suite 200, Littleton, CO 80120-8031.

**Members: \$6, nonmembers: \$10**

# Acquired Adult Flatfoot Deformity

316 APRIL 2010 1 CE credit

1. The talonavicular joint is located \_\_\_\_\_.
  - a. Between the talus and navicular
  - b. On the anterolateral midfoot
  - c. On the dorsal foot, below the ankle
  - d. a & c
2. Attaching the posterior tibial tendon to the transferred FDL is called \_\_\_\_\_.
  - a. Midfoot dissection
  - b. Tenodesis
  - c. Spring ligament repair
  - d. Ligament fixation
3. Surgical procedures to correct flatfoot include \_\_\_\_\_.
  - a. Spring ligament reconstruction
  - b. Triple arthrodesis
  - c. Subtalar arthrodesis
  - d. All of the above
4. Weight-bearing radiographs should be taken \_\_\_\_\_.
  - a. Preoperatively
  - b. Postoperatively
  - c. At the surgeon's discretion
  - d. Only when screws are used
5. The most common cause of adult-acquired flatfoot is \_\_\_\_\_.
  - a. Lateral hindfoot pain
  - b. Navicular tuberosity
  - c. Posterior tibial tendon dysfunction
  - d. Achilles tendonitis
6. The \_\_\_\_\_ can be used to replace the posterior tibial tendon.
  - a. Achilles tendon
  - b. FDL tendon
  - c. Peroneal tendon
  - d. None of the above
7. \_\_\_\_\_ can be used to lengthen the lateral column in this surgical alternative.
  - a. Iliac crest block autograft
  - b. Structural allograft
  - c. FDL transfer
  - d. a & b
8. Varying degrees of flatfoot are present in \_\_\_\_\_ percent of the population.
  - a. 10-25
  - b. 15-30
  - c. More than 50
  - d. Unknown
9. In the lateral column lengthening procedure, the "bump" under the ipsilateral hip provides \_\_\_\_\_.
  - a. Support for the hip
  - b. Relief of a bony pressure point
  - c. Better access to the lateral side of the foot
  - d. Stability for the thigh
10. Patients with painful arthritis or fixed flatfoot with PTTD are usually best served with \_\_\_\_\_.
  - a. Motion-sparing procedures
  - b. Subtalar arthrodesis
  - c. Triple arthrodesis
  - d. b & c

**ACQUIRED ADULT FLATFOOT DEFORMITY 316 APRIL 2010 1 CE credit**

NBSTSA Certification No. \_\_\_\_\_

AST Member No. \_\_\_\_\_

My address has changed. The address below is the new address.

Name \_\_\_\_\_

Address \_\_\_\_\_


City \_\_\_\_\_ State \_\_\_\_\_ Zip \_\_\_\_\_

Telephone \_\_\_\_\_

	a	b	c	d		a	b	c	d
1	<input type="checkbox"/>	<input type="checkbox"/>	<input type="checkbox"/>	<input type="checkbox"/>	6	<input type="checkbox"/>	<input type="checkbox"/>	<input type="checkbox"/>	<input type="checkbox"/>
2	<input type="checkbox"/>	<input type="checkbox"/>	<input type="checkbox"/>	<input type="checkbox"/>	7	<input type="checkbox"/>	<input type="checkbox"/>	<input type="checkbox"/>	<input type="checkbox"/>
3	<input type="checkbox"/>	<input type="checkbox"/>	<input type="checkbox"/>	<input type="checkbox"/>	8	<input type="checkbox"/>	<input type="checkbox"/>	<input type="checkbox"/>	<input type="checkbox"/>
4	<input type="checkbox"/>	<input type="checkbox"/>	<input type="checkbox"/>	<input type="checkbox"/>	9	<input type="checkbox"/>	<input type="checkbox"/>	<input type="checkbox"/>	<input type="checkbox"/>
5	<input type="checkbox"/>	<input type="checkbox"/>	<input type="checkbox"/>	<input type="checkbox"/>	10	<input type="checkbox"/>	<input type="checkbox"/>	<input type="checkbox"/>	<input type="checkbox"/>

Mark one box next to each number. Only one correct or best answer can be selected for each question.

## CE EXAM



### Earn CE Credits at Home

You will be awarded continuing education (CE) credit(s) for recertification after reading the designated article and completing the exam with a score of 70% or better.

If you are a current AST member and are certified, credit earned through completion of the CE exam will automatically be recorded in your file—you do not have to submit a CE reporting form. A printout of all the CE credits you have earned, including Journal CE credits, will be mailed to you in the first quarter following the end of the calendar year. You may check the status of your CE record with AST at any time.

If you are not an AST member or are not certified, you will be notified by mail when Journal credits are submitted, but your credits will not be recorded in AST's files.

Detach or photocopy the answer block, include your check or money order made payable to AST, and send it to Member Services, AST, 6 West Dry Creek Circle, Suite 200, Littleton, CO 80120-8031.

**Members: \$6, nonmembers: \$10**

# Hip Arthroscopy

317 MAY 2010 1 CE credit

- The \_\_\_\_\_ should include the qualitative nature of discomfort, location, onset and history of trauma/developmental abnormality.
  - Diagnosis
  - Patient history
  - Treatment
  - Rehabilitation
- Primary portals are placed \_\_\_\_\_.
  - Anterior and anterolateral
  - Anterior and posterior
  - Anterolateral and posterolateral
  - Superior and Inferior
- A pincer lesion is located on the \_\_\_\_\_.
  - Femoral head
  - Femoral head neck junction
  - Acetabular fossa
  - Acetabular rim
- The labrum is made up of \_\_\_\_\_.
  - Fibrocartilage
  - Osseous abnormalities
  - Bone
  - Hyaline cartilage
- The \_\_\_\_\_ is/are located on the femoral head-neck junction.
  - Cam lesion
  - Pincer lesion
  - Labrum
  - Nerve fibers
- The anterolateral portal penetrates the \_\_\_\_\_.
  - Sartorius
  - Rectus femoris
  - Gluteus medius
  - Greater trochanter
- The femoral artery and nerve lie \_\_\_\_\_ to the anterior portal.
  - Posterior
  - Medial
  - Lateral
  - Superior
- A type 2 tear is \_\_\_\_\_.
  - Detachment or pincer impingement
  - Detachment or cam impingement
  - Intrasubstance tear or pincer impingement
  - Intrasubstance tear or cam impingement
- The anterior portal penetrates the \_\_\_\_\_.
  - Sartorius
  - Rectus femoris
  - Gluteus medius
  - Both a & b
- Postoperative rehabilitation includes \_\_\_\_\_.
  - Walking or light jogging
  - Rest
  - Crutches
  - Continuous passive motion and physical therapy

## HIP ARTHROSCOPY: FEMOROACETABULAR IMPINGEMENT 317 MAY 2010 1 CE credit

NBSTSA Certification No. \_\_\_\_\_

AST Member No. \_\_\_\_\_

My address has changed. The address below is the new address.

Name \_\_\_\_\_


Address \_\_\_\_\_

City \_\_\_\_\_ State \_\_\_\_\_ Zip \_\_\_\_\_

Telephone \_\_\_\_\_

	a	b	c	d		a	b	c	d
1	<input type="checkbox"/>	<input type="checkbox"/>	<input type="checkbox"/>	<input type="checkbox"/>	6	<input type="checkbox"/>	<input type="checkbox"/>	<input type="checkbox"/>	<input type="checkbox"/>
2	<input type="checkbox"/>	<input type="checkbox"/>	<input type="checkbox"/>	<input type="checkbox"/>	7	<input type="checkbox"/>	<input type="checkbox"/>	<input type="checkbox"/>	<input type="checkbox"/>
3	<input type="checkbox"/>	<input type="checkbox"/>	<input type="checkbox"/>	<input type="checkbox"/>	8	<input type="checkbox"/>	<input type="checkbox"/>	<input type="checkbox"/>	<input type="checkbox"/>
4	<input type="checkbox"/>	<input type="checkbox"/>	<input type="checkbox"/>	<input type="checkbox"/>	9	<input type="checkbox"/>	<input type="checkbox"/>	<input type="checkbox"/>	<input type="checkbox"/>
5	<input type="checkbox"/>	<input type="checkbox"/>	<input type="checkbox"/>	<input type="checkbox"/>	10	<input type="checkbox"/>	<input type="checkbox"/>	<input type="checkbox"/>	<input type="checkbox"/>

Mark one box next to each number.  
Only one correct or best answer can be selected for each question.



**Earn CE Credits at Home**

You will be awarded continuing education (CE) credit(s) for recertification after reading the designated article and completing the exam with a score of 70% or better.

If you are a current AST member and are certified, credit earned through completion of the CE exam will automatically be recorded in your file—you do not have to submit a CE reporting form. A printout of all the CE credits you have earned, including Journal CE credits, will be mailed to you in the first quarter following the end of the calendar year. You may check the status of your CE record with AST at any time.

If you are not an AST member or are not certified, you will be notified by mail when Journal credits are submitted, but your credits will not be recorded in AST's files.

Detach or photocopy the answer block, include your check or money order made payable to AST, and send it to Member Services, AST, 6 West Dry Creek Circle, Suite 200, Littleton, CO 80120-8031.

**Members: \$6, nonmembers: \$10**

# Platysmaplasty

319 JULY 2010 1 CE credit

1. The \_\_\_\_\_ covers the external jugular vein in the neck.
  - a. Platysma
  - b. Deltoideus
  - c. Superior part of the pectoralis major
  - d. None of the above
  
2. A \_\_\_\_\_ is used to separate the subcutaneous layer from the platysma muscle.
  - a. Army/Navy retractor
  - b. Adson forceps
  - c. #15 blade
  - d. Straight Metzenbaum scissor
  
3. Patients must cease drinking and smoking \_\_\_\_\_ prior to the procedure.
  - a. 24 hours
  - b. One week
  - c. Two weeks
  - d. One month
  
4. Patients should wear an elastic bandage around the head and neck for \_\_\_\_\_.
  - a. 24 hours postoperatively
  - b. 48-72 hours postoperatively
  - c. Up to five days postoperatively
  - d. All of the above
  
5. Platysmaplasty can be performed using \_\_\_\_\_ anesthesia.
  - a. General
  - b. IV sedation
  - c. Local
  - d. All of the above
  
6. The method of suturing for this procedure is based on \_\_\_\_\_.
  - a. Surgeon's preference
  - b. The amount of fat removed
  - c. The type of suture
  - d. a & b
  
7. \_\_\_\_\_ is administered preoperatively to help prevent infection.
  - a. Cleocin
  - b. Cephalixin
  - c. Azithromycin
  - d. Penicillin
  
8. To prevent bleeding, \_\_\_\_\_ are not allowed during the first week following surgery.
  - a. Vitamin D
  - b. Aspirin
  - c. Acetaminophen
  - d. a & b
  
9. Which item is *not* laid out on the Mayo stand?
  - a. DeBakey tissue forceps
  - b. Elastic bandage
  - c. Head light source
  - d. Surgeon's magnified intense glasses
  
10. Possible complications from platysmaplasty include \_\_\_\_\_.
  - a. Hematoma
  - b. Infection
  - c. Seroma
  - d. All of the above

**PLATYSMAPLASTY: A SURGICAL RESOLUTION FOR THE TURKEY NECK** 319 JULY 2010 1 CE credit

NBSTSA Certification No. \_\_\_\_\_

AST Member No. \_\_\_\_\_

My address has changed. The address below is the new address.

Name \_\_\_\_\_

Address \_\_\_\_\_


City \_\_\_\_\_ State \_\_\_\_\_ Zip \_\_\_\_\_

Telephone \_\_\_\_\_

	a	b	c	d		a	b	c	d
1	<input type="checkbox"/>	<input type="checkbox"/>	<input type="checkbox"/>	<input type="checkbox"/>	6	<input type="checkbox"/>	<input type="checkbox"/>	<input type="checkbox"/>	<input type="checkbox"/>
2	<input type="checkbox"/>	<input type="checkbox"/>	<input type="checkbox"/>	<input type="checkbox"/>	7	<input type="checkbox"/>	<input type="checkbox"/>	<input type="checkbox"/>	<input type="checkbox"/>
3	<input type="checkbox"/>	<input type="checkbox"/>	<input type="checkbox"/>	<input type="checkbox"/>	8	<input type="checkbox"/>	<input type="checkbox"/>	<input type="checkbox"/>	<input type="checkbox"/>
4	<input type="checkbox"/>	<input type="checkbox"/>	<input type="checkbox"/>	<input type="checkbox"/>	9	<input type="checkbox"/>	<input type="checkbox"/>	<input type="checkbox"/>	<input type="checkbox"/>
5	<input type="checkbox"/>	<input type="checkbox"/>	<input type="checkbox"/>	<input type="checkbox"/>	10	<input type="checkbox"/>	<input type="checkbox"/>	<input type="checkbox"/>	<input type="checkbox"/>

Mark one box next to each number. Only one correct or best answer can be selected for each question.

**CE EXAM**



**Earn CE Credits at Home**

You will be awarded continuing education (CE) credit(s) for recertification after reading the designated article and completing the exam with a score of 70% or better.

If you are a current AST member and are certified, credit earned through completion of the CE exam will automatically be recorded in your file—you do not have to submit a CE reporting form. A printout of all the CE credits you have earned, including Journal CE credits, will be mailed to you in the first quarter following the end of the calendar year. You may check the status of your CE record with AST at any time.

If you are not an AST member or are not certified, you will be notified by mail when Journal credits are submitted, but your credits will not be recorded in AST's files.

Detach or photocopy the answer block, include your check or money order made payable to AST, and send it to Member Services, AST, 6 West Dry Creek Circle, Suite 200, Littleton, CO 80120-8031.

**Members: \$6, nonmembers: \$10**

# Emergency Cesarean Delivery

320 AUGUST 2010 1 CE credit

1. Early practice of Cesarean section often resulted in \_\_\_\_\_.
  - a. Fetal bradycardia
  - b. Shoulder dystocia
  - c. Cardiac arrest
  - d. All of the above
2. What important innovation helped make the Cesarean delivery safer in the mid-1800s?
  - a. Anesthesia
  - b. Blood bank
  - c. ESU
  - d. Oxytocin
3. The \_\_\_\_\_ must be present in the LDR during a Code Blue.
  - a. Patient's next of kin
  - b. Anesthesiologist
  - c. Blood bank
  - d. In-house obstetric attending physician
4. The rarest presentation of a breech birth \_\_\_\_\_.
  - a. Kneeling breech
  - b. Complete breech
  - c. Frank breech
  - d. Footling breech
5. The \_\_\_\_\_ is placed in charge of obtaining additional supplies in emergency situations.
  - a. Nurse manager
  - b. Assistant nurse manager
  - c. Patient's primary nurse
  - d. Runner
6. During the delivery, the \_\_\_\_\_ is delivered first.
  - a. Bottom
  - b. Head
  - c. Feet
  - d. Umbilical cord
7. Breech birth risks include \_\_\_\_\_.
  - a. Umbilical cord prolapse
  - b. Head entrapment
  - c. Oxygen deprivation
  - d. All of the above
8. What size blade does the surgical technologist need to incise the patient's skin?
  - a. #20
  - b. #11
  - c. #15
  - d. #10
9. Which of the following factors is not influential in the occurrence of a breech birth?
  - a. The sex of the baby
  - b. Multiple fetuses
  - c. Premature labor
  - d. Uterine abnormalities
10. Who determines if the patient should be moved to the OR for further patient management and/or closure?
  - a. Team leader
  - b. Physician
  - c. Medication nurse
  - d. None of the above

**EMERGENCY CESAREAN DELIVERY 320 AUGUST 2010 1 CE credit**

NBSTSA Certification No. \_\_\_\_\_

AST Member No. \_\_\_\_\_

My address has changed. The address below is the new address.

Name \_\_\_\_\_

Address \_\_\_\_\_

City \_\_\_\_\_ State \_\_\_\_\_ Zip \_\_\_\_\_

Telephone \_\_\_\_\_

	a	b	c	d		a	b	c	d
1	<input type="checkbox"/>	<input type="checkbox"/>	<input type="checkbox"/>	<input type="checkbox"/>	6	<input type="checkbox"/>	<input type="checkbox"/>	<input type="checkbox"/>	<input type="checkbox"/>
2	<input type="checkbox"/>	<input type="checkbox"/>	<input type="checkbox"/>	<input type="checkbox"/>	7	<input type="checkbox"/>	<input type="checkbox"/>	<input type="checkbox"/>	<input type="checkbox"/>
3	<input type="checkbox"/>	<input type="checkbox"/>	<input type="checkbox"/>	<input type="checkbox"/>	8	<input type="checkbox"/>	<input type="checkbox"/>	<input type="checkbox"/>	<input type="checkbox"/>
4	<input type="checkbox"/>	<input type="checkbox"/>	<input type="checkbox"/>	<input type="checkbox"/>	9	<input type="checkbox"/>	<input type="checkbox"/>	<input type="checkbox"/>	<input type="checkbox"/>
5	<input type="checkbox"/>	<input type="checkbox"/>	<input type="checkbox"/>	<input type="checkbox"/>	10	<input type="checkbox"/>	<input type="checkbox"/>	<input type="checkbox"/>	<input type="checkbox"/>

Mark one box next to each number. Only one correct or best answer can be selected for each question.



# Radical Neck Dissection

322 OCTOBER 2010 1 CE credit

1. How many modifications to the radical neck dissection are there?
  - a. 1
  - b. 2
  - c. 3
  - d. 4
  
2. The \_\_\_\_ is isolated and divided immediately after the external jugular vein.
  - a. Anterior trapezius muscle
  - b. Omohyoid muscle
  - c. Internal jugular vein
  - d. Thyrocervical artery
  
3. The first radical neck dissection was performed by \_\_\_\_ .
  - a. George Crile
  - b. Hayes Martin
  - c. Oswaldo Suarez
  - d. Ettore Bocca
  
4. A \_\_\_\_ is used to protect the carotid artery in the event the patient has undergone previous radiation therapy.
  - a. Sterile towel
  - b. Dermal skin graft
  - c. Sterile plastic adhesive
  - d. Fenestrated sheet
  
5. The lymph node groups and additional structures not included in the classic neck dissection are resected in the \_\_\_\_ .
  - a. Type I modification
  - b. Type II modification
  - c. Type III modification
  - d. Extended radical neck dissection
  
6. Surgical and anesthesia times increase significantly when \_\_\_\_ are used.
  - a. Radial forearm flaps
  - b. Rectus abdominis flaps
  - c. Microvascular flaps
  - d. Nerve grafts
  
7. Which medical advancement allowed surgery to become the primary treatment for cancers of the head and neck?
  - a. Radical neck dissection
  - b. Preservation of the spinal accessory nerve
  - c. Antibiotics
  - d. All of the above
  
8. Cadaveric tissue grafts may be successful in radical neck dissections because \_\_\_\_ .
  - a. It can reduce surgical time
  - b. It can reduce time under anesthetic
  - c. A previously-irradiated field does not affect its integration
  - d. All of the above
  
9. After the thyrocervical artery is clamped, divided and ligated, the \_\_\_\_ is/are dissected.
  - a. Posterior triangle
  - b. Cervical and suprascapular arteries
  - c. Omohyoid muscle
  - d. None of the above
  
10. A radical neck dissection will generally keep a patient in the hospital for \_\_\_\_ .
  - a. 3-5 days
  - b. 5-7 days
  - c. 7-12 days
  - d. 13-15 days

RADICAL NECK DISSECTION 322 OCTOBER 2010 1 CE credit

NBSTSA Certification No. \_\_\_\_\_

AST Member No. \_\_\_\_\_

My address has changed. The address below is the new address.

Name \_\_\_\_\_

Address \_\_\_\_\_


City \_\_\_\_\_ State \_\_\_\_\_ Zip \_\_\_\_\_

Telephone \_\_\_\_\_

	a	b	c	d		a	b	c	d
1	<input type="checkbox"/>	<input type="checkbox"/>	<input type="checkbox"/>	<input type="checkbox"/>	6	<input type="checkbox"/>	<input type="checkbox"/>	<input type="checkbox"/>	<input type="checkbox"/>
2	<input type="checkbox"/>	<input type="checkbox"/>	<input type="checkbox"/>	<input type="checkbox"/>	7	<input type="checkbox"/>	<input type="checkbox"/>	<input type="checkbox"/>	<input type="checkbox"/>
3	<input type="checkbox"/>	<input type="checkbox"/>	<input type="checkbox"/>	<input type="checkbox"/>	8	<input type="checkbox"/>	<input type="checkbox"/>	<input type="checkbox"/>	<input type="checkbox"/>
4	<input type="checkbox"/>	<input type="checkbox"/>	<input type="checkbox"/>	<input type="checkbox"/>	9	<input type="checkbox"/>	<input type="checkbox"/>	<input type="checkbox"/>	<input type="checkbox"/>
5	<input type="checkbox"/>	<input type="checkbox"/>	<input type="checkbox"/>	<input type="checkbox"/>	10	<input type="checkbox"/>	<input type="checkbox"/>	<input type="checkbox"/>	<input type="checkbox"/>

Mark one box next to each number.  
Only one correct or best answer can be selected for each question.

## CE EXAM



### Earn CE Credits at Home

You will be awarded continuing education (CE) credits toward your recertification after reading the designated article and completing the test with a score of 70% or better. If you do not pass the test, it will be returned along with your payment.

Send the original answer sheet from the journal and make a copy for your records. If possible use a credit card (debit or credit) for payment. It is a faster option for processing of credits and offers more flexibility for correct payment. When submitting multiple tests, you do not need to submit a separate check for each journal test. You may submit multiple journal tests with one check or money order.

Members this test is also available online at [www.ast.org](http://www.ast.org). No stamps or checks and post to your record automatically!

**Members: \$6 per credit**

(per credit not per test)

**Nonmembers: \$10 per credit**

(per credit not per test plus the \$400 nonmember fee per submission)

After your credits are processed, AST will send you a letter acknowledging the number of credits that were accepted. Members can also check your CE credit status online with your login information at [www.ast.org](http://www.ast.org).

### 3 WAYS TO SUBMIT YOUR CE CREDITS

Mail to: AST, Member Services, 6 West Dry Creek Circle Ste 200 Littleton, CO 80120-8031

Fax CE credits to: 303-694-9169

E-mail scanned CE credits in PDF format to: [memserv@ast.org](mailto:memserv@ast.org)

For questions please contact Member Services - [memserv@ast.org](mailto:memserv@ast.org) or 800-637-7433, option 3. Business hours: Mon-Fri, 8:00a.m. - 4:30 p.m., mountain time

## Pectus Carinatum: Pigeon Chest

323 NOVEMBER 2010 2 CE credit

1. Pectus Carinatum is characterized by a/an \_\_\_\_ of the sternum.
  - a. Protrusion
  - b. Indentation
  - c. Fracture
  - d. A & C
2. Effects of pigeon chest include \_\_\_\_.
  - a. Fatigue
  - b. Dyspnea
  - c. Psychological issues
  - d. All of the above
3. The surgical procedure can take anywhere from \_\_\_\_.
  - a. 2-4 hours
  - b. 2-6 hours
  - c. 4-6 hours
  - d. None of the above
4. The Ravitch procedure has a \_\_\_\_ percent satisfaction rate among patients.
  - a. 97
  - b. 87
  - c. 79
  - d. 92
5. Patients' cardiopulmonary function can be affected by \_\_\_\_.
  - a. Mitral valve prolapsed
  - b. Decreased lung capacity
  - c. Impaired gas exchange in cardiopulmonary system
  - d. All of the above
6. The Ravitch procedure does not involve \_\_\_\_.
  - a. Cutting the costal cartilage
  - b. Using a stabilization bar
  - c. External pressure brace
  - d. Removal of some costal cartilage
7. The ratio of males to females that develop pectus carinatum is \_\_\_\_.
  - a. 3:1
  - b. 7:2
  - c. 6:2
  - d. 5:1
8. The principal organs of respiration and circulation are protected by the \_\_\_\_.
  - a. Thorax
  - b. Pectoral muscles
  - c. Sternum
  - d. Thoracic vertebrae
9. The human body has \_\_\_\_ false ribs.
  - a. Ten
  - b. Six
  - c. Three
  - d. Two
10. A chest deformity characterized by an inverted sternum is \_\_\_\_.
  - a. Pectus carinatum
  - b. Pigeon chest
  - c. Pectus excavatum
  - d. All of the above
11. The intercostal spaces are located between the \_\_\_\_.
  - a. Lungs
  - b. Ribs
  - c. Vertebral bodies
  - d. Costal cartilages
12. Pectus carinatum can present at which phase of a patient's life?
  - a. At birth
  - b. Post surgically
  - c. During growth spurts
  - d. All of the above

13. Which genetic disorder is not considered a possible cause of pectus carinatum?

- a. Trisomy 21
- b. Morquio syndrome
- c. Brittle bone disease
- d. Scoliosis

14. One percent lidocaine with epinephrine, 1:200,000 describes \_\_\_\_.

- a. Sterile solution
- b. General anesthetic
- c. Local anesthetic
- d. Anxiety medication

15. In the case presented, the patient is in the \_\_\_\_ position for surgery.

- a. Reverse Trendelenburg
- b. Supine
- c. Trendelenburg
- d. None of the above

16. \_\_\_\_ is/are performed preoperatively to rule out genetic disorders.

- a. Blood tests
- b. Urine analysis
- c. X-ray
- d. ECG

17. The average hospital stay for this procedure is \_\_\_\_.

- a. 1-5 days
- b. 3-5 days
- c. 3-7 days
- d. 5-9 days

18. Preoperative diagnostic tests include \_\_\_\_.

- a. Pulmonary function
- b. CT scan
- c. Urine analysis
- d. All of the above

19. \_\_\_\_ is a genetic disorder in which the body cannot metabolize methionine.

- a. Homocystinuria
- b. Morquio syndrome
- c. Trisomy 18
- d. Marfan syndrome

20. Twisting movement or rapid elevation of the arms is restricted for \_\_\_\_.

- a. Two months
- b. Four months
- c. Six weeks
- d. Until postoperative checkup

**PECTUS CARINATUM: PIGEON CHEST 323 NOVEMBER 2010 2 CE credit**

NBSTSA Certification No. \_\_\_\_\_

AST Member No. \_\_\_\_\_

My address has changed. The address below is the new address.

Name \_\_\_\_\_

Address \_\_\_\_\_

City \_\_\_\_\_ State \_\_\_\_\_ Zip \_\_\_\_\_

Telephone \_\_\_\_\_

	a	b	c	d		a	b	c	d
1	<input type="checkbox"/>	<input type="checkbox"/>	<input type="checkbox"/>	<input type="checkbox"/>	11	<input type="checkbox"/>	<input type="checkbox"/>	<input type="checkbox"/>	<input type="checkbox"/>
2	<input type="checkbox"/>	<input type="checkbox"/>	<input type="checkbox"/>	<input type="checkbox"/>	12	<input type="checkbox"/>	<input type="checkbox"/>	<input type="checkbox"/>	<input type="checkbox"/>
3	<input type="checkbox"/>	<input type="checkbox"/>	<input type="checkbox"/>	<input type="checkbox"/>	13	<input type="checkbox"/>	<input type="checkbox"/>	<input type="checkbox"/>	<input type="checkbox"/>
4	<input type="checkbox"/>	<input type="checkbox"/>	<input type="checkbox"/>	<input type="checkbox"/>	14	<input type="checkbox"/>	<input type="checkbox"/>	<input type="checkbox"/>	<input type="checkbox"/>
5	<input type="checkbox"/>	<input type="checkbox"/>	<input type="checkbox"/>	<input type="checkbox"/>	15	<input type="checkbox"/>	<input type="checkbox"/>	<input type="checkbox"/>	<input type="checkbox"/>
6	<input type="checkbox"/>	<input type="checkbox"/>	<input type="checkbox"/>	<input type="checkbox"/>	16	<input type="checkbox"/>	<input type="checkbox"/>	<input type="checkbox"/>	<input type="checkbox"/>
7	<input type="checkbox"/>	<input type="checkbox"/>	<input type="checkbox"/>	<input type="checkbox"/>	17	<input type="checkbox"/>	<input type="checkbox"/>	<input type="checkbox"/>	<input type="checkbox"/>
8	<input type="checkbox"/>	<input type="checkbox"/>	<input type="checkbox"/>	<input type="checkbox"/>	18	<input type="checkbox"/>	<input type="checkbox"/>	<input type="checkbox"/>	<input type="checkbox"/>
9	<input type="checkbox"/>	<input type="checkbox"/>	<input type="checkbox"/>	<input type="checkbox"/>	19	<input type="checkbox"/>	<input type="checkbox"/>	<input type="checkbox"/>	<input type="checkbox"/>
10	<input type="checkbox"/>	<input type="checkbox"/>	<input type="checkbox"/>	<input type="checkbox"/>	20	<input type="checkbox"/>	<input type="checkbox"/>	<input type="checkbox"/>	<input type="checkbox"/>

Mark one box next to each number. Only one correct or best answer can be selected for each question.

# Answers CE CREDIT PKG 8: 8 CONTINUING EDUCATION CREDITS

Certified Member

AST Member No: \_\_\_\_\_

Name: \_\_\_\_\_

Certification No: \_\_\_\_\_

Address: \_\_\_\_\_ City: \_\_\_\_\_ State: \_\_\_\_\_ Zip: \_\_\_\_\_

Telephone: \_\_\_\_\_ Email: \_\_\_\_\_

## CE Credit PKG 8: 8 CONTINUING EDUCATION CREDITS

The fee is \$13. This package is only available to AST members.

Check Enclosed Yes, I want to pay by Credit Card:  Visa  MasterCard  AmEx

Card# \_\_\_\_\_ Expiration Date \_\_\_\_\_ Signature \_\_\_\_\_

### Total Knee Arthroplasty

a	b	c	d	a	b	c	d	a	b	c	d	a	b	c	d				
1.	<input type="checkbox"/>	<input type="checkbox"/>	<input type="checkbox"/>	<input type="checkbox"/>	7.	<input type="checkbox"/>	<input type="checkbox"/>	<input type="checkbox"/>	<input type="checkbox"/>	13.	<input type="checkbox"/>	<input type="checkbox"/>	<input type="checkbox"/>	<input type="checkbox"/>	19.	<input type="checkbox"/>	<input type="checkbox"/>	<input type="checkbox"/>	<input type="checkbox"/>
2.	<input type="checkbox"/>	<input type="checkbox"/>	<input type="checkbox"/>	<input type="checkbox"/>	8.	<input type="checkbox"/>	<input type="checkbox"/>	<input type="checkbox"/>	<input type="checkbox"/>	14.	<input type="checkbox"/>	<input type="checkbox"/>	<input type="checkbox"/>	<input type="checkbox"/>	20.	<input type="checkbox"/>	<input type="checkbox"/>	<input type="checkbox"/>	<input type="checkbox"/>
3.	<input type="checkbox"/>	<input type="checkbox"/>	<input type="checkbox"/>	<input type="checkbox"/>	9.	<input type="checkbox"/>	<input type="checkbox"/>	<input type="checkbox"/>	<input type="checkbox"/>	15.	<input type="checkbox"/>	<input type="checkbox"/>	<input type="checkbox"/>	<input type="checkbox"/>	Mark one box next to each number. Only one correct or best answer will be selected for each question.				
4.	<input type="checkbox"/>	<input type="checkbox"/>	<input type="checkbox"/>	<input type="checkbox"/>	10.	<input type="checkbox"/>	<input type="checkbox"/>	<input type="checkbox"/>	<input type="checkbox"/>	16.	<input type="checkbox"/>	<input type="checkbox"/>	<input type="checkbox"/>	<input type="checkbox"/>					
5.	<input type="checkbox"/>	<input type="checkbox"/>	<input type="checkbox"/>	<input type="checkbox"/>	11.	<input type="checkbox"/>	<input type="checkbox"/>	<input type="checkbox"/>	<input type="checkbox"/>	17.	<input type="checkbox"/>	<input type="checkbox"/>	<input type="checkbox"/>	<input type="checkbox"/>					
6.	<input type="checkbox"/>	<input type="checkbox"/>	<input type="checkbox"/>	<input type="checkbox"/>	12.	<input type="checkbox"/>	<input type="checkbox"/>	<input type="checkbox"/>	<input type="checkbox"/>	18.	<input type="checkbox"/>	<input type="checkbox"/>	<input type="checkbox"/>	<input type="checkbox"/>					

### Surgical Correction of Acquired Adult Flatfoot Deformity

a	b	c	d	a	b	c	d	a	b	c	d	a	b	c	d				
1.	<input type="checkbox"/>	<input type="checkbox"/>	<input type="checkbox"/>	<input type="checkbox"/>	7.	<input type="checkbox"/>	<input type="checkbox"/>	<input type="checkbox"/>	<input type="checkbox"/>	13.	<input type="checkbox"/>	<input type="checkbox"/>	<input type="checkbox"/>	<input type="checkbox"/>	19.	<input type="checkbox"/>	<input type="checkbox"/>	<input type="checkbox"/>	<input type="checkbox"/>
2.	<input type="checkbox"/>	<input type="checkbox"/>	<input type="checkbox"/>	<input type="checkbox"/>	8.	<input type="checkbox"/>	<input type="checkbox"/>	<input type="checkbox"/>	<input type="checkbox"/>	14.	<input type="checkbox"/>	<input type="checkbox"/>	<input type="checkbox"/>	<input type="checkbox"/>	20.	<input type="checkbox"/>	<input type="checkbox"/>	<input type="checkbox"/>	<input type="checkbox"/>
3.	<input type="checkbox"/>	<input type="checkbox"/>	<input type="checkbox"/>	<input type="checkbox"/>	9.	<input type="checkbox"/>	<input type="checkbox"/>	<input type="checkbox"/>	<input type="checkbox"/>	15.	<input type="checkbox"/>	<input type="checkbox"/>	<input type="checkbox"/>	<input type="checkbox"/>	Mark one box next to each number. Only one correct or best answer will be selected for each question.				
4.	<input type="checkbox"/>	<input type="checkbox"/>	<input type="checkbox"/>	<input type="checkbox"/>	10.	<input type="checkbox"/>	<input type="checkbox"/>	<input type="checkbox"/>	<input type="checkbox"/>	16.	<input type="checkbox"/>	<input type="checkbox"/>	<input type="checkbox"/>	<input type="checkbox"/>					
5.	<input type="checkbox"/>	<input type="checkbox"/>	<input type="checkbox"/>	<input type="checkbox"/>	11.	<input type="checkbox"/>	<input type="checkbox"/>	<input type="checkbox"/>	<input type="checkbox"/>	17.	<input type="checkbox"/>	<input type="checkbox"/>	<input type="checkbox"/>	<input type="checkbox"/>					
6.	<input type="checkbox"/>	<input type="checkbox"/>	<input type="checkbox"/>	<input type="checkbox"/>	12.	<input type="checkbox"/>	<input type="checkbox"/>	<input type="checkbox"/>	<input type="checkbox"/>	18.	<input type="checkbox"/>	<input type="checkbox"/>	<input type="checkbox"/>	<input type="checkbox"/>					

## Hip Arthroscopy: Treating Femoroacetabular Impingement

a	b	c	d	a	b	c	d	a	b	c	d	a	b	c	d				
1.	<input type="checkbox"/>	<input type="checkbox"/>	<input type="checkbox"/>	<input type="checkbox"/>	7.	<input type="checkbox"/>	<input type="checkbox"/>	<input type="checkbox"/>	<input type="checkbox"/>	13.	<input type="checkbox"/>	<input type="checkbox"/>	<input type="checkbox"/>	<input type="checkbox"/>	19.	<input type="checkbox"/>	<input type="checkbox"/>	<input type="checkbox"/>	Mark one box next to each number. Only one correct or best answer will be selected for each question.
2.	<input type="checkbox"/>	<input type="checkbox"/>	<input type="checkbox"/>	<input type="checkbox"/>	8.	<input type="checkbox"/>	<input type="checkbox"/>	<input type="checkbox"/>	<input type="checkbox"/>	14.	<input type="checkbox"/>	<input type="checkbox"/>	<input type="checkbox"/>	<input type="checkbox"/>	20.	<input type="checkbox"/>	<input type="checkbox"/>	<input type="checkbox"/>	
3.	<input type="checkbox"/>	<input type="checkbox"/>	<input type="checkbox"/>	<input type="checkbox"/>	9.	<input type="checkbox"/>	<input type="checkbox"/>	<input type="checkbox"/>	<input type="checkbox"/>	15.	<input type="checkbox"/>	<input type="checkbox"/>	<input type="checkbox"/>	<input type="checkbox"/>					
4.	<input type="checkbox"/>	<input type="checkbox"/>	<input type="checkbox"/>	<input type="checkbox"/>	10.	<input type="checkbox"/>	<input type="checkbox"/>	<input type="checkbox"/>	<input type="checkbox"/>	16.	<input type="checkbox"/>	<input type="checkbox"/>	<input type="checkbox"/>	<input type="checkbox"/>					
5.	<input type="checkbox"/>	<input type="checkbox"/>	<input type="checkbox"/>	<input type="checkbox"/>	11.	<input type="checkbox"/>	<input type="checkbox"/>	<input type="checkbox"/>	<input type="checkbox"/>	17.	<input type="checkbox"/>	<input type="checkbox"/>	<input type="checkbox"/>	<input type="checkbox"/>					
6.	<input type="checkbox"/>	<input type="checkbox"/>	<input type="checkbox"/>	<input type="checkbox"/>	12.	<input type="checkbox"/>	<input type="checkbox"/>	<input type="checkbox"/>	<input type="checkbox"/>	18.	<input type="checkbox"/>	<input type="checkbox"/>	<input type="checkbox"/>	<input type="checkbox"/>					

## Platysmaplasty: A Surgical Resolution for the "Turkey Neck"

a	b	c	d	a	b	c	d	a	b	c	d	a	b	c	d				
1.	<input type="checkbox"/>	<input type="checkbox"/>	<input type="checkbox"/>	<input type="checkbox"/>	7.	<input type="checkbox"/>	<input type="checkbox"/>	<input type="checkbox"/>	<input type="checkbox"/>	13.	<input type="checkbox"/>	<input type="checkbox"/>	<input type="checkbox"/>	<input type="checkbox"/>	19.	<input type="checkbox"/>	<input type="checkbox"/>	<input type="checkbox"/>	Mark one box next to each number. Only one correct or best answer will be selected for each question.
2.	<input type="checkbox"/>	<input type="checkbox"/>	<input type="checkbox"/>	<input type="checkbox"/>	8.	<input type="checkbox"/>	<input type="checkbox"/>	<input type="checkbox"/>	<input type="checkbox"/>	14.	<input type="checkbox"/>	<input type="checkbox"/>	<input type="checkbox"/>	<input type="checkbox"/>	20.	<input type="checkbox"/>	<input type="checkbox"/>	<input type="checkbox"/>	
3.	<input type="checkbox"/>	<input type="checkbox"/>	<input type="checkbox"/>	<input type="checkbox"/>	9.	<input type="checkbox"/>	<input type="checkbox"/>	<input type="checkbox"/>	<input type="checkbox"/>	15.	<input type="checkbox"/>	<input type="checkbox"/>	<input type="checkbox"/>	<input type="checkbox"/>					
4.	<input type="checkbox"/>	<input type="checkbox"/>	<input type="checkbox"/>	<input type="checkbox"/>	10.	<input type="checkbox"/>	<input type="checkbox"/>	<input type="checkbox"/>	<input type="checkbox"/>	16.	<input type="checkbox"/>	<input type="checkbox"/>	<input type="checkbox"/>	<input type="checkbox"/>					
5.	<input type="checkbox"/>	<input type="checkbox"/>	<input type="checkbox"/>	<input type="checkbox"/>	11.	<input type="checkbox"/>	<input type="checkbox"/>	<input type="checkbox"/>	<input type="checkbox"/>	17.	<input type="checkbox"/>	<input type="checkbox"/>	<input type="checkbox"/>	<input type="checkbox"/>					
6.	<input type="checkbox"/>	<input type="checkbox"/>	<input type="checkbox"/>	<input type="checkbox"/>	12.	<input type="checkbox"/>	<input type="checkbox"/>	<input type="checkbox"/>	<input type="checkbox"/>	18.	<input type="checkbox"/>	<input type="checkbox"/>	<input type="checkbox"/>	<input type="checkbox"/>					

## Emergency Cesarean Deliver in the Labor and Delivery Room

a	b	c	d	a	b	c	d	a	b	c	d	a	b	c	d				
1.	<input type="checkbox"/>	<input type="checkbox"/>	<input type="checkbox"/>	<input type="checkbox"/>	7.	<input type="checkbox"/>	<input type="checkbox"/>	<input type="checkbox"/>	<input type="checkbox"/>	13.	<input type="checkbox"/>	<input type="checkbox"/>	<input type="checkbox"/>	<input type="checkbox"/>	19.	<input type="checkbox"/>	<input type="checkbox"/>	<input type="checkbox"/>	Mark one box next to each number. Only one correct or best answer will be selected for each question.
2.	<input type="checkbox"/>	<input type="checkbox"/>	<input type="checkbox"/>	<input type="checkbox"/>	8.	<input type="checkbox"/>	<input type="checkbox"/>	<input type="checkbox"/>	<input type="checkbox"/>	14.	<input type="checkbox"/>	<input type="checkbox"/>	<input type="checkbox"/>	<input type="checkbox"/>	20.	<input type="checkbox"/>	<input type="checkbox"/>	<input type="checkbox"/>	
3.	<input type="checkbox"/>	<input type="checkbox"/>	<input type="checkbox"/>	<input type="checkbox"/>	9.	<input type="checkbox"/>	<input type="checkbox"/>	<input type="checkbox"/>	<input type="checkbox"/>	15.	<input type="checkbox"/>	<input type="checkbox"/>	<input type="checkbox"/>	<input type="checkbox"/>					
4.	<input type="checkbox"/>	<input type="checkbox"/>	<input type="checkbox"/>	<input type="checkbox"/>	10.	<input type="checkbox"/>	<input type="checkbox"/>	<input type="checkbox"/>	<input type="checkbox"/>	16.	<input type="checkbox"/>	<input type="checkbox"/>	<input type="checkbox"/>	<input type="checkbox"/>					
5.	<input type="checkbox"/>	<input type="checkbox"/>	<input type="checkbox"/>	<input type="checkbox"/>	11.	<input type="checkbox"/>	<input type="checkbox"/>	<input type="checkbox"/>	<input type="checkbox"/>	17.	<input type="checkbox"/>	<input type="checkbox"/>	<input type="checkbox"/>	<input type="checkbox"/>					
6.	<input type="checkbox"/>	<input type="checkbox"/>	<input type="checkbox"/>	<input type="checkbox"/>	12.	<input type="checkbox"/>	<input type="checkbox"/>	<input type="checkbox"/>	<input type="checkbox"/>	18.	<input type="checkbox"/>	<input type="checkbox"/>	<input type="checkbox"/>	<input type="checkbox"/>					

## Radical Neck Dissection

a	b	c	d	a	b	c	d	a	b	c	d	a	b	c	d				
1.	<input type="checkbox"/>	<input type="checkbox"/>	<input type="checkbox"/>	<input type="checkbox"/>	7.	<input type="checkbox"/>	<input type="checkbox"/>	<input type="checkbox"/>	<input type="checkbox"/>	13.	<input type="checkbox"/>	<input type="checkbox"/>	<input type="checkbox"/>	<input type="checkbox"/>	19.	<input type="checkbox"/>	<input type="checkbox"/>	<input type="checkbox"/>	Mark one box next to each number. Only one correct or best answer will be selected for each question.
2.	<input type="checkbox"/>	<input type="checkbox"/>	<input type="checkbox"/>	<input type="checkbox"/>	8.	<input type="checkbox"/>	<input type="checkbox"/>	<input type="checkbox"/>	<input type="checkbox"/>	14.	<input type="checkbox"/>	<input type="checkbox"/>	<input type="checkbox"/>	<input type="checkbox"/>	20.	<input type="checkbox"/>	<input type="checkbox"/>	<input type="checkbox"/>	
3.	<input type="checkbox"/>	<input type="checkbox"/>	<input type="checkbox"/>	<input type="checkbox"/>	9.	<input type="checkbox"/>	<input type="checkbox"/>	<input type="checkbox"/>	<input type="checkbox"/>	15.	<input type="checkbox"/>	<input type="checkbox"/>	<input type="checkbox"/>	<input type="checkbox"/>					
4.	<input type="checkbox"/>	<input type="checkbox"/>	<input type="checkbox"/>	<input type="checkbox"/>	10.	<input type="checkbox"/>	<input type="checkbox"/>	<input type="checkbox"/>	<input type="checkbox"/>	16.	<input type="checkbox"/>	<input type="checkbox"/>	<input type="checkbox"/>	<input type="checkbox"/>					
5.	<input type="checkbox"/>	<input type="checkbox"/>	<input type="checkbox"/>	<input type="checkbox"/>	11.	<input type="checkbox"/>	<input type="checkbox"/>	<input type="checkbox"/>	<input type="checkbox"/>	17.	<input type="checkbox"/>	<input type="checkbox"/>	<input type="checkbox"/>	<input type="checkbox"/>					
6.	<input type="checkbox"/>	<input type="checkbox"/>	<input type="checkbox"/>	<input type="checkbox"/>	12.	<input type="checkbox"/>	<input type="checkbox"/>	<input type="checkbox"/>	<input type="checkbox"/>	18.	<input type="checkbox"/>	<input type="checkbox"/>	<input type="checkbox"/>	<input type="checkbox"/>					

## Pectus Carinatum: Pigeon Chest

a	b	c	d	a	b	c	d	a	b	c	d	a	b	c	d				
1.	<input type="checkbox"/>	<input type="checkbox"/>	<input type="checkbox"/>	<input type="checkbox"/>	7.	<input type="checkbox"/>	<input type="checkbox"/>	<input type="checkbox"/>	<input type="checkbox"/>	13.	<input type="checkbox"/>	<input type="checkbox"/>	<input type="checkbox"/>	<input type="checkbox"/>	19.	<input type="checkbox"/>	<input type="checkbox"/>	<input type="checkbox"/>	Mark one box next to each number. Only one correct or best answer will be selected for each question.
2.	<input type="checkbox"/>	<input type="checkbox"/>	<input type="checkbox"/>	<input type="checkbox"/>	8.	<input type="checkbox"/>	<input type="checkbox"/>	<input type="checkbox"/>	<input type="checkbox"/>	14.	<input type="checkbox"/>	<input type="checkbox"/>	<input type="checkbox"/>	<input type="checkbox"/>	20.	<input type="checkbox"/>	<input type="checkbox"/>	<input type="checkbox"/>	
3.	<input type="checkbox"/>	<input type="checkbox"/>	<input type="checkbox"/>	<input type="checkbox"/>	9.	<input type="checkbox"/>	<input type="checkbox"/>	<input type="checkbox"/>	<input type="checkbox"/>	15.	<input type="checkbox"/>	<input type="checkbox"/>	<input type="checkbox"/>	<input type="checkbox"/>					
4.	<input type="checkbox"/>	<input type="checkbox"/>	<input type="checkbox"/>	<input type="checkbox"/>	10.	<input type="checkbox"/>	<input type="checkbox"/>	<input type="checkbox"/>	<input type="checkbox"/>	16.	<input type="checkbox"/>	<input type="checkbox"/>	<input type="checkbox"/>	<input type="checkbox"/>					
5.	<input type="checkbox"/>	<input type="checkbox"/>	<input type="checkbox"/>	<input type="checkbox"/>	11.	<input type="checkbox"/>	<input type="checkbox"/>	<input type="checkbox"/>	<input type="checkbox"/>	17.	<input type="checkbox"/>	<input type="checkbox"/>	<input type="checkbox"/>	<input type="checkbox"/>					
6.	<input type="checkbox"/>	<input type="checkbox"/>	<input type="checkbox"/>	<input type="checkbox"/>	12.	<input type="checkbox"/>	<input type="checkbox"/>	<input type="checkbox"/>	<input type="checkbox"/>	18.	<input type="checkbox"/>	<input type="checkbox"/>	<input type="checkbox"/>	<input type="checkbox"/>					