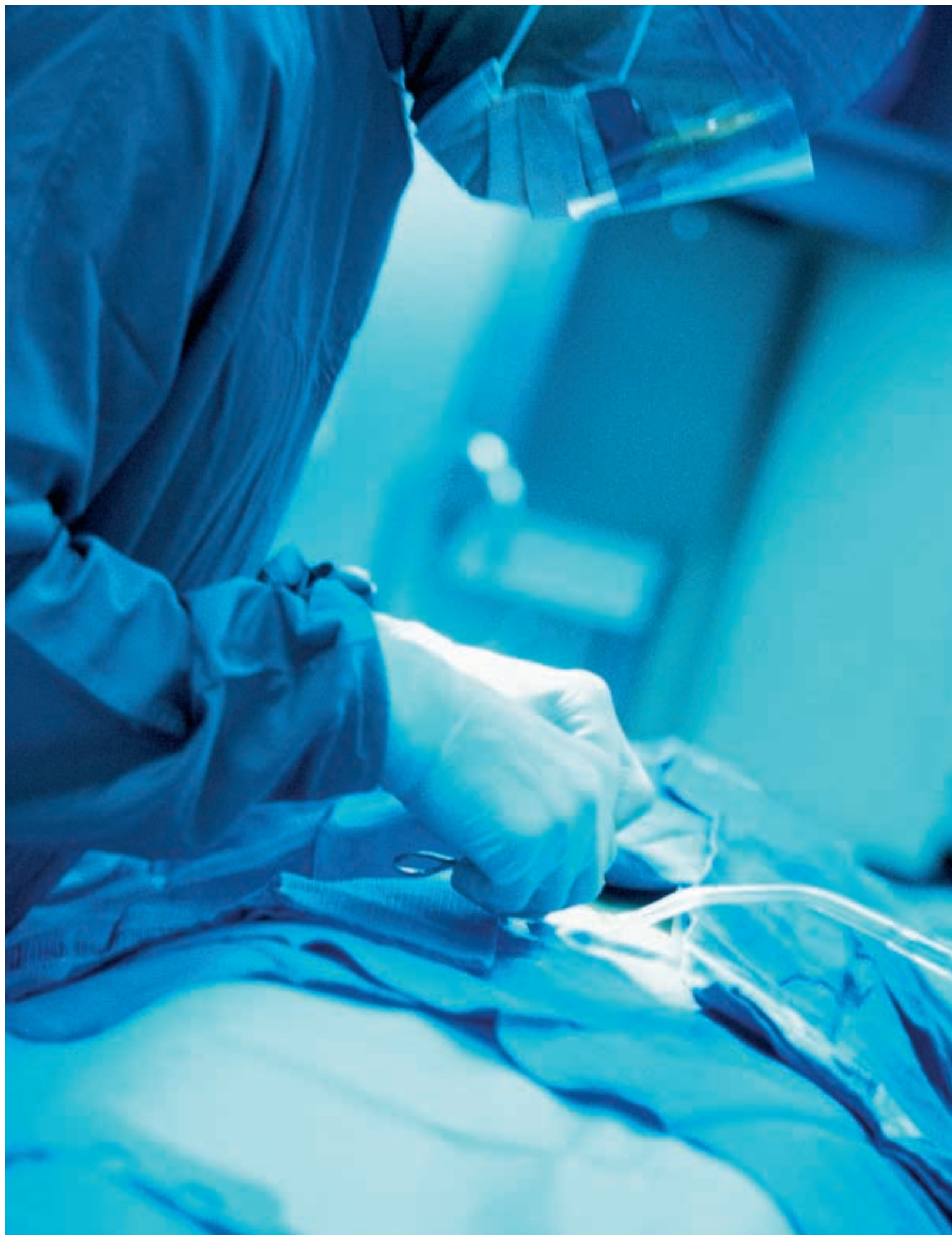



Understanding stomas

Gary J Allen

The United Ostomy Association estimates that there are more than 15,000 American ostomates, people who now have stomas as a result of the surgical treatment for conditions such as Crohn's disease, ulcerative colitis, and rectal cancer.¹ This article is intended as an overview of the purpose, creation, and care of stomas and will discuss indications for stoma creation, the types of stomas, the surgical procedures utilized, complications of stomas, and the postoperative care required for maintaining a stoma. Included also in this discussion will be a brief presentation of anatomy and physiology.

Definition

A stoma (Greek for mouth) is defined as a small opening or pore.² An ostomy refers specifically to an artificially (in this case surgically) created opening between two passages or body cavities, or between a cavity or passage and the body's surface that results in a stoma, as seen with an ileostomy or colostomy.² The term ostomy may also refer to an internal communication between two organs, such as seen with an ileocecostomy, or between two bodily cavities, such as that created between the abdomen and thorax, however these latter definitions will not be discussed. For this article, a stoma is a communication of a section of bowel with the outside of the abdominal cavity created to divert the fecal stream.^{3,4} The purposes of this diversion is to protect a recent intestinal anastomosis, to avoid potential abdominal "spillage" postoperatively, as a step in resection therapy, or as an end result of bowel resection.^{5,4}

Anatomy and physiology

The small intestine begins at the pyloric region of the stomach and is composed of three contiguous sections (from proximal to distal): duodenum, jejunum, and ileum.⁶ The latter two segments are termed the mesenteric small intestine.⁷ The mesenteries are peritoneal folds that contain the blood vessels, nerves, and lymph vessels serving their adjoining organ.⁸ The mesentery is also associated with portions of the colon.⁷

The small intestine is approximately 6-7 meters in length and varies in luminal diameter from 3 cm to 5 cm.⁹ The small intestine digests food, absorbs nutrients, and produces the various acids and enzymes necessary for these functions.⁷ The wall of the small intestine is composed of mucosa, the submucosa, the muscle layer (muscularis propria), the subserosa, and the serosa.⁹ (Figure 1)

The colon averages 90-125 cm in length and can be referred to as right and left segments. However, it is more technically divided into its specific anatomical sections: the cecum, the ascending colon, the transverse colon, the

descending colon, the sigmoid colon, and the rectum.^{7,10} (Figure 2) The ileum terminates on the superior aspect of the cecum (ileocec junction) with a semilunar valve, the competency of which is of clinical importance in assessing colon obstruction.^{7,11} The wall of the colon has four layers: mucosa, submucosa, muscularis, and serosa. The outer longitudinal muscularis is arranged in three separate taenia rather than the continuous enveloping layer seen in the small intestine.⁷ (Figure 3) The colon is responsible for the absorption of water and electrolytes, the compaction of fecal waste, and the production of Vitamin K by its intestinal flora.¹²

Also of concern in stoma creation are the muscles of the anterior abdomen, which include the external and internal oblique, the transverse abdominis and the rectus abdominis.¹³ The three flat muscles, the obliques and transverse abdominis, attach at varying levels to the lower ribs and the iliac crests, whereas the rectus abdominis, a long strap-like muscle, arises from the costal margin and the sides of the xiphoid process and extends to the symphysis pubis.⁷ The abdominal muscles are wrapped in fascia, named for the nearby structures (eg transversalis fascia covers the transversalis abdominis muscle).⁷ The flat muscles have a dense white tendon of insertion, the aponeurosis, which join at midline to form the sheath around the rectus abdominis as well as the midline linea alba.^{7,14}

Types of stomas

Stomas may be temporary or permanent and are created from either an end section or loop of the ileum (ileostomy) or colon (colostomy).^{4,15} The sigmoid colon is also used as an end colostomy following abdominoperineal (A/P) resection.⁴ End stomas have a single aperture at the skin surface, and those created from loops generally have two apertures in the same stomal wound.^{5,15} Loop-type stomas have a proximal afferent (functioning) aperture and a distal efferent (non-functioning) aperture, and may be created from the bowel in continuity (without dividing the bowel), or separately (using both the proximal and distal portions of a transected bowel).^{15,16}

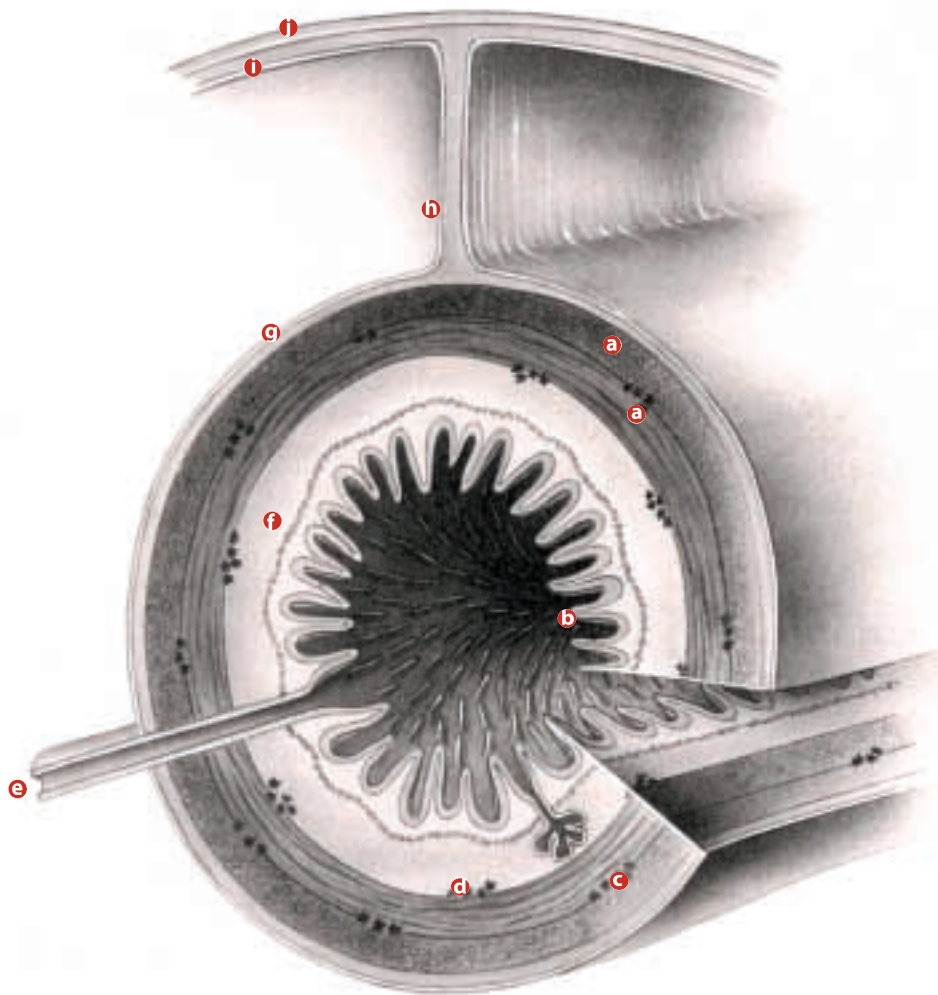


FIGURE 1

Layers of the intestinal wall.

- a** muscularis externa
- b** lumen
- c** myenteric plexus
- g** submucosal plexus
- e** duct from external exocrine gland
- f** submucosa
- d** serosa
- h** mesentery
- i** peritoneal membrane
- j** body wall

Indications for stomas

Creation of a temporary end ileostomy is seen with partial or total colectomy when a primary anastomosis is considered to be unacceptable (eg in the presence of peritonitis), in cases of ileal or ileocecal resection for Crohn’s disease, or to provide diversion to allow a severely inflamed bowel a chance to be resolved prior to its resection. (Figure 4) A permanent end ileostomy is created following total abdominal colectomy or proctocolectomy and in incidences of chronic ulcerative colitis.^{1,18}

Loop ileostomy is primarily a temporary stoma for fecal diversion and is preferred in the obese patient.^{15,17} It is indicated: following ileal

pouch-anal, coloanal, and colorectal anastomoses; after construction of a continent ileal reservoir; proximal to an enterocutaneous fistula; as an outlet proximal to an intestinal anastomosis when poor nutrition, local sepsis, or the long-term effects of steroid or immunosuppressive therapy may increase the chance of leakage at the anastomotic site; and in cases of severe perianal Crohn’s disease.^{4,15,17} The end-loop ileostomy, a variation of the loop-type stoma, is

Images from Surgical Technology for the Surgical Technologist: A Positive Care Approach, 1st edition, by Delmar Thompson Learning.

primarily used as a permanent stoma in obese individuals.¹⁷

End colostomy is indicated after A/P resection for rectal cancer, when fistulas exist, for permanent fecal diversion due to X-ray injury, for treatment of Crohn's disease, for incontinence, and in cases of rectal trauma.¹⁷ Loop colostomy usually utilizes a part of the transverse colon, and is not generally used as a permanent colostomy as it discharges a semi-liquid stool.^{3,4} Loop colostomy is the most frequently used method of stoma creation for temporary fecal diversion. The most common site for a loop colostomy is in the upper right quadrant.^{4,17} Loop colostomy is also used to decompress the colon, especially in cases of toxic megacolon (venting colostomy).¹⁹

Preoperative preparations

The patient is allowed only clear liquids the day prior to surgery, and mechanical cleansing (laxatives and enemas) is encouraged except in cases of obstruction.^{3,4} In preparation of a planned colostomy, elimination of as much fecal matter preoperatively is important, as the high bacterial count of the colon contributes to postoperative infection and anastomotic dehiscence rates.³

In all cases, general anesthesia is administered. The patient is positioned supinely on the OR table and the skin is prepped from the nipple line to the pubic region, from table to table laterally. Generally, a midline incision is used to enter the abdomen, and exposure of the target area is achieved by the use of various instrumentation, including Deaver retractors and elaborate self-retaining retractor systems, such as the Thompson or Bookwalter. A standard major abdominal kit is adequate in most cases, and a variety of bowel clamps and intestinal staplers should be available.

Site selection

The stomal skin site is carefully selected at a point below the costal margin, above the belt line, and usually at the appropriate lateral edge of the rectus abdominis muscle.^{20,21} Site selection is preferably accomplished prior to surgery, with the site marked on the patient after review of the

area in both the standing and sitting positions.^{4,20} This technique provides maximum patient comfort.¹⁶ In some cases, of course, stoma creation is a result of decisions during surgery, therefore, preoperative site selection is moot. Intraoperative site selection will still follow the basic guidelines described.

Ileostomy

End ileostomy

End ileostomy is constructed from a terminal portion of ileum and may be either temporary or permanent.^{5,15,17} The technique begins with transection of the ileum at a point that preserves as much of the distal ileum as possible.¹⁷ This may be as close as 1 cm to 2 cm proximal to the ileocecal valve in benign resections, or 6 cm to 10 cm from this same point when ileocecal malignant pathology is involved.^{4,15} The mesentery of the terminal 5 cm to 8 cm of ileum is divided from the bowel about 1 cm from the bowel wall.¹⁵ A stoma site is then selected in the right lower quadrant of the anterior abdomen, a 2-inch disc of skin is excised, and a wedge of the underlying subcutaneous tissue is removed with cautery.^{15,16,20}

Next, right-angle retractors, such as Army-Navy, are placed for exposure of the anterior rectus sheath and a cruciate incision is made in the anterior rectus sheath.^{15,18} The rectus muscle is bluntly separated in the direction of its fibers (longitudinally), and the retractors are repositioned to expose the underlying posterior rectus sheath.^{18,20} The posterior rectus sheath and peritoneum are then opened with a hemostat or scalpel.⁴ This incision is then dilated bluntly to 3 cm to 4 cm in width, large enough for the surgeon to pass two fingers through the aperture.^{18,20}

A Babcock is then passed through the incision, and the terminal ileum is grasped and delivered out of the wound.²⁵ Since the finished ileostomy will need 2 cm to 2.5 cm of spout to adequately fit the fecal pouch appliance, 5 cm of ileum is exteriorized above the skin line.^{15,18} There should be no tension within the abdomen

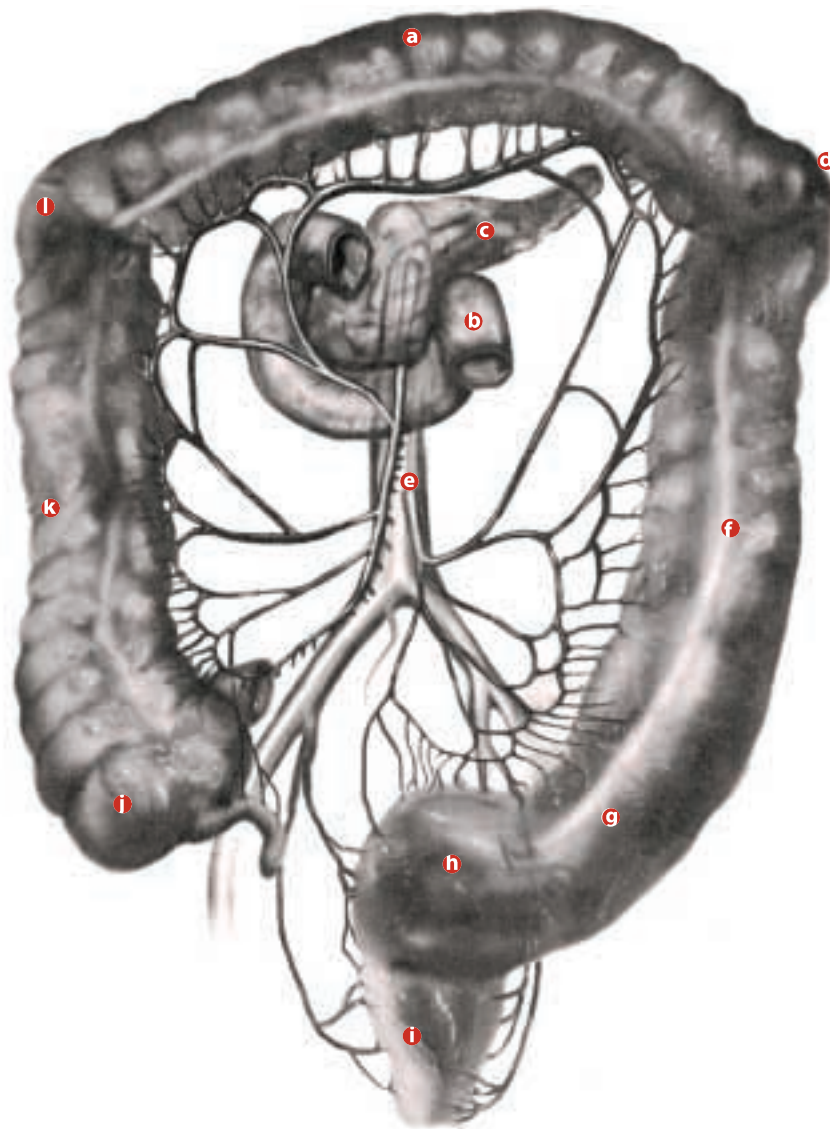


FIGURE 2

**Anatomy of
the colon.**

- Ⓐ transverse colon
- Ⓑ duodenum
- Ⓒ pancreas
- Ⓓ splenic flexure
- Ⓔ aorta
- Ⓕ descending colon
- Ⓖ sigmoid
- Ⓗ rectosigmoid
- Ⓘ rectum
- ⓷ cecum
- Ⓚ ascending colon
- Ⓛ hepatic flexure

on this section of bowel.⁴ The free edge of divided mesentery is sutured comfortably to the posterior and lateral abdominal wall.^{18,25} The terminal section of bowel is secured within the abdomen to the peritoneum and posterior rectus sheath with 3-0 interrupted absorbable suture.^{15,20}

The stoma can now be secured with several 3-0 interrupted silk or absorbable sutures passed through the anterior rectus sheath and the sero-muscular layer of the bowel.^{15,18,20} The abdomen is then closed prior to maturation of the stoma to prevent inadvertent spillage from the stoma into the peritoneal cavity.^{4,5} Maturation of the stoma refers to securing of the most terminal

extent of the stomal serosa to the skin surface, usually with eight or more interrupted 3-0 chromic sutures, which cause the mucosa to form into a spout.^{17,18,22} (Figure 5)

Loop ileostomy

An incision is made in the same manner as that for end ileostomy, however it may be slightly larger. The bowel is brought through the skin, with an umbilical tape passed through a small hole in the ileal mesentery, until a 4 cm loop of bowel is extracted.²⁰ Care is taken to maintain orientation of the bowel to discern the afferent and efferent ends.^{16,18} The tape is removed and replaced by a rod or butterfly bridge.¹⁸ The bowel

loop is then secured to the anterior rectus sheath with a few interrupted 3-0 chromic sutures placed through the seromuscular coat of each limb.^{15,20} The loop can now be incised on the antimesenteric border, close to the distal limb, for 80% of its circumference.²⁰

The proximal (afferent) end is matured as previously described, forming a stomal spout, and the distal end subsequently assumes a semi-closed crescent shape.^{18,20} Maturation of a loop ileostomy includes passing the sutures through the dermal layer, thus closing the larger defect used for this procedure.^{16,18} The supportive rod or bridge can be removed in seven to 10 days.¹⁸

End-loop ileostomy

The end-loop ileostomy is a modification of the loop method in which the loop is divided with an intestinal stapler, and both ends are brought out through the skin incision.¹⁸ The entire staple line of the proximal limb is excised and matured as with end ileostomy.⁵ However, only a corner of the distal limb's staple line is excised, and two sutures are placed merely to stabilize the limb, rather than creating a functional stoma.^{16,18}

Colostomy

End colostomy

End colostomy is created from the descending and sigmoid portions of the colon essentially in the same manner described for end ileostomy.¹⁷ After resection, the section of colon used for the stoma is mobilized and brought out through the stoma site, secured to the abdominal wall and matured.^{5,19} However, an end colostomy is not generally elevated to a point a few centimeters above the skin as an ileostomy, and it needs to be brought through a slightly larger stoma site, which can require partial division of the rectus muscle.^{17,19,21} An end colostomy is usually created with the mucosa everted level to or slightly above the skin level, thus allowing for better irrigating.¹⁹ This also affords the patient options beyond the pouch appliances, such as a stomal cap or plug.²¹

Loop colostomy

There are more than a dozen variations for creating a loop colostomy, but all achieve complete fecal diversion for at least a few months postoperatively.^{4,17,19} These variations are generalized into three types: loop colostomy over a fascial bridge, loop colostomy utilizing a rod or bridge as a support structure, or end-loop colostomy.⁴ A loop colostomy can be created following colon resection or as a primary procedure, but both are created in the same manner.^{3,19} An advantage of loop colostomy is that it can be reduced at a later time by a simple local procedure without need for other laparotomy.^{5,19}

A transverse incision is made in the upper-right quadrant and a loop of transverse bowel is selected and brought through the incision.¹⁷ The mobility of the transverse colon is such that only minimal release of peritoneal attachments is usually required, and care is taken to maintain the orientation of the bowel.^{5,19} From this start, a loop colostomy is then created like a loop ileostomy. A 6 mm opening is created in the mesentery, a rod or bridge is positioned to support the colon, and the colon is secured to the peritoneum and posterior rectus sheath.^{4,21} The loop of colon is then incised along the antimesenteric border, and the stoma is matured in the same fashion as that for loop ileostomy. It may be preferable to wait two to three days prior to maturing the stoma in the case of concurrent surgery.¹⁹

End-loop colostomy

The end-loop colostomy method takes into consideration the same needs required for creation of a loop colostomy (eg larger stomal opening, limited mobilization, proper orientation of the bowel, etc), while being performed in the same manner as an end-loop ileostomy. As in an end-loop ileostomy, closure of the distal stoma results in complete fecal diversion.

Tube cecostomy

Tube cecostomy is not a common procedure but is used to temporarily decompress the colon or to relieve cecal volvulus, and can also be per-

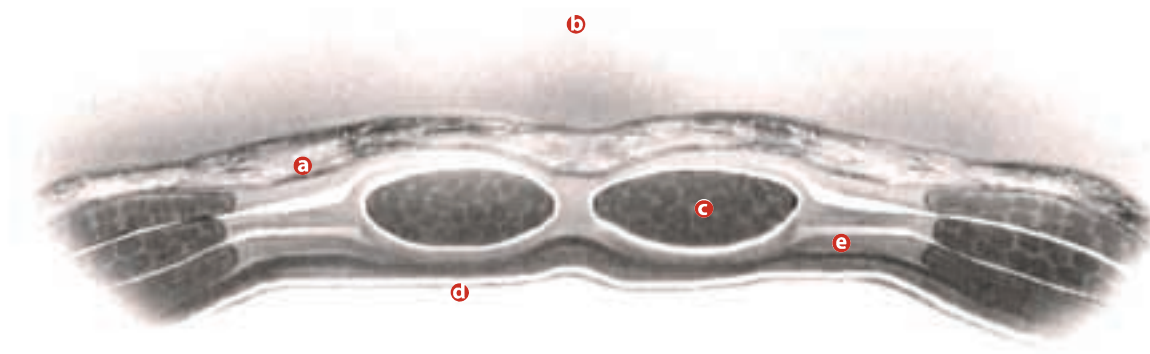
formed as a primary operation through a McBurney's or lateral transverse incision.^{4,19} Following the abdominal incision, the dilated cecum is easily identified and delivered into the wound.⁴ The cecal serosa is secured to the peritoneum with a few interrupted absorbable sutures, and two purse-string sutures are placed around the tube insertion site, usually the apex of the cecum.^{4,19}

The full thickness of the bowel is incised for a few millimeters, the tube (a 30 French Foley or No 36 to No 40 mushroom-tipped Pezzar) is inserted into the cecal lumen, the purse-string sutures tightened around it, and the tube is then brought out to the outside of the abdomen

making it the easiest stoma to manage.⁴ A sigmoid colostomy expels compacted stool about once a day, and an appliance may not be necessary.³ A sigmoid colostomy is suitable for irrigation.¹⁷

Complications associated with stomas

Besides the complications inherent with the disease that dictated the need for intestinal surgery, several characteristics are common to all stomas and their creation. The mucous lining of the bowel is exposed (matured) for accessibility and is, therefore, subject to the effects of the outside environment.²¹ The stoma is usually fitted with an appliance (a bag-type reservoir) which



© 2010 Elsevier Inc.

through a separate stab wound in the lower-right quadrant.^{4,19} This procedure has the advantage of spontaneous closure of the bowel once the tube is removed; however, it requires irrigation to prevent obstruction by fecal particles and the tube may become dislodged.^{19,21}

Sigmoid colostomy

The sigmoid (iliac) colostomy is the most common type of permanent colostomy, and is created at the time of A/P resection.^{4,17} It is usually created as an end colostomy in the left-lower quadrant of the abdomen. A sigmoid colostomy allows the patient to take advantage of the absorptive capacity of the proximal colon, thus

adheres to the skin, surrounding the stoma and collecting the intestinal contents. These appliances can experience mechanical problems.^{5,15}

Potential complications common to all stomas are many, frequent, and include: ischemia, stenosis, stomal prolapse, stomal retraction, parastomal hernia, fistula formation, bleeding from varices around the stoma, leakage from the appliance, offensive odors, contact dermatitis, laceration, urinary tract calculi, gallstones, infection, hyperplasia, and bowel obstruction secondary to stomal creation.^{15,18,23,17,21} There may also be an incidence of allergic reaction to the appliance and constipation and/or fecal impaction can occur.¹

FIGURE 3

Muscular layers of the colon.

- Ⓐ subcutaneous fat
- Ⓑ skin
- Ⓒ muscle tissue
- Ⓓ peritoneum
- Ⓔ transverse fascia

Complications of loop colostomy are the same as those for all stomas; however, the colon is particularly prone to prolapse, especially with obese patients and stenosis.^{3,4,17}

Two-thirds of all ileostomy patients will experience at least one complication.¹⁵ Ischemia is particularly noted with colostomies, as the blood supply to the colon is less developed than that of the small intestine.¹ Many complications can require stomal revision, and the takedown of stomas (reanastomosis) can incur its own difficulties.^{4,5} An estimated 15% to 25% of people with ostomies, especially those with a recurrence of Crohn's disease, will eventually need additional surgery.¹

Postoperative care

Patients can do nearly anything with an ostomy: bear children, ride a bicycle, swim, or even play professional football.¹ Education is the most important aspect of the postoperative period and, at many hospitals, either an enterostomal therapist or ostomy support group is available to assist the patient with stomal care and quality of life issues.^{1,2} The patient's family should also be educated and encouraged to be involved with the stomal care.²

The stoma should be pink or dark red in color.²¹ Patients are not allowed to eat or drink anything until bowel sounds and other signs of normal bowel function (such as passing gas) are detected. It may require several days for normal peristalsis to return.¹ Postoperative diet is adjusted to provide stool consistency, and high-residue foods, such as popcorn, nuts, cabbage, and mushrooms should be avoided.^{1,2} It is an essential part of stomal care that the skin around any ostomy be kept clean.¹

Although postoperative care is required to differing degrees, it generally includes irrigating the stoma periodically, emptying the contents of the collection pouch (appliance) four to five times daily, and changing the entire appliance no more than every four to five days.^{4,16,21} Some patients with end sigmoid colostomies may opt to irrigate the stoma, but instead of a collecting pouch, a cap or plug is used.¹ A suitable irrigating solution is lukewarm saline (1 teaspoon salt to one pint of water) infused directly into the stoma through a catheter.² Irrigation and return of the effluent requires about two hours per day.¹

An ileostomy does not require irrigation and requires the wearing of an appliance at all times because it spills a liquid material continuously.³ An ileostomy will begin to function within two to three days.¹⁷ The effluent will be thin, watery, light green in color, and will vary in output from 100 ml to 1000 ml initially.^{3,4,17} Excretions from the colon vary from semifluid (upper-right colon) to solid (sigmoid colon).²

Postoperative care of a transverse loop colostomy requires immediate application of a well-fitted stomal pouch, since the bowel con-

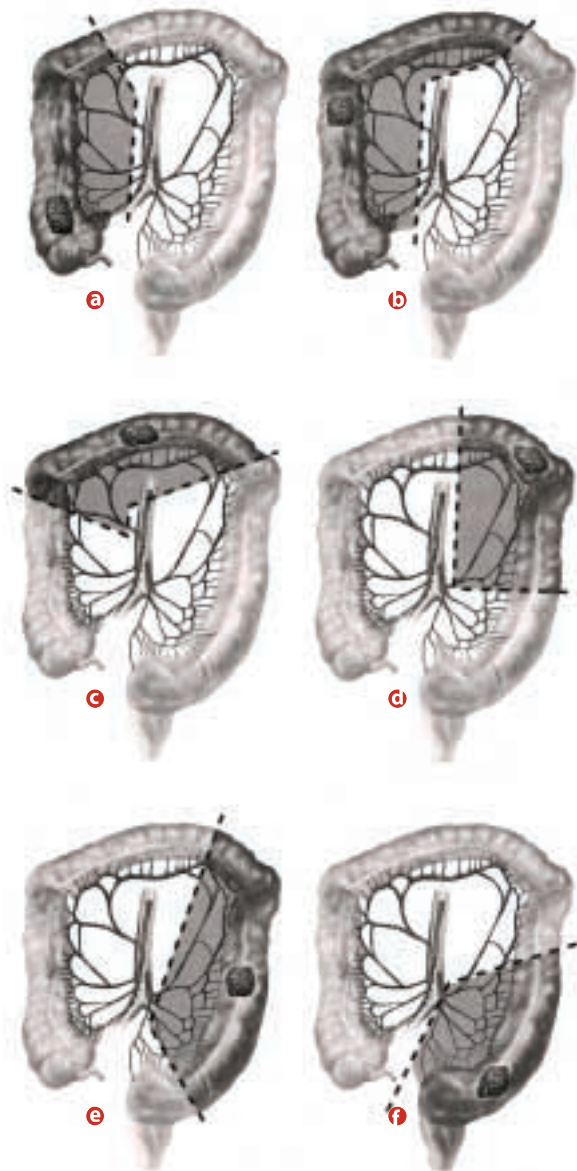


FIGURE 4

Options for colon

resection.

- a right colectomy
- b right hemicolectomy
- c transverse colectomy
- d left colectomy
- e left hemicolectomy
- f abdominoperineal resection

tents are such that evacuation is unpredictable.⁴ The exteriorized serosa of the colon usually becomes fixed to the skin in two to four days.¹⁹ Irrigation is not necessary with the transverse loop colostomy.²¹ However, when irrigation is required of any loop-type stoma, only the proximal portion of the bowel is irrigated.¹

Conclusions


Despite the apparent morbidity associated with their creation, stomas are an integral part of gastrointestinal surgery, and in many cases mean an end to a patient's weight loss, pain, and the debilitating side effects of previously employed medications.¹ Stomas provide a period of rest for a healing portion of the bowel, serving as temporary or permanent fecal outlets. The care of stomas is considered only moderately demanding on the patient and, with proper education, the patient can lead a very normal and active life.

About the author

Gary J Allen has been CST since 1986 and spent a decade working in Springfield, MA. He is currently employed as a traveler.

References

1. Digestive System. In: *Johns Hopkins Family Health Book*. New York: Harper Collins Publishers; 1999:1012-1014.
2. Thomas CL. *Taber's Cyclopedic Medical Dictionary*. 18th ed. Philadelphia: FA Davis Co; 1997:1370-1371, 1837.
3. Schrock TR. Large Intestine. In: Way LW, ed. *Current Surgical Diagnosis and Treatment*. 10th ed. Norwalk, CT: Appleton and Lange Publishers; 1994: 687-691.
4. Bubrick MP, Rolstad BS. Intestinal Stomas. In: Gordon PH, Nivatvongs S, eds. *Principles and Practices of Surgery for the Colon, Rectum, and Anus*. 2nd ed. St Louis: Quality Medical Publishing, Inc; 1999:1118, 1120-1127, 1130-1133, 1139-1146, 1151-1158, 1161-1169.
5. Reed II RL. Colorectal Trauma. In: Bell RH, Rikkers LF, Mulholland MW, eds. *Digestive*



Tract Surgery. Philadelphia: Lippincott-Raven Publishers; 1996:412-413.

6. Shiner M. Anatomy of the Small Intestine. In: Haubrich WS, Schaffner F and Berk JE, eds. *Bockus' Gastroenterology*. 5th ed, Vol 2. Philadelphia: WB Saunders Co; 1995:885-892.
7. Bannister LH. Alimentary System. In: Bannister LH, et al, eds. *Gray's Anatomy: The Anatomical Basis of Medicine and Surgery*. 38th ed. New York: Churchill Livingstone; 1995:1751-1786.
8. Nance FC. Diseases of the Peritoneum, Retroperitoneum, Mesentery, and Omentum. In: Haubrich WS, Schaffner F

FIGURE 5

End-loop ileostomy.

- Ⓐ incision for stoma
- Ⓑ ileum brought through the abdominal wall
- Ⓒ ileal edge everted to create stoma
- Ⓓ end ileal stoma

- and Berk JE, eds. *Bockus' Gastroenterology*. 5th ed, Vol 4. Philadelphia: WB Saunders Co; 1995:3061-3063.
9. Keljo DJ and Squires Jr RH. Anatomy and Anomalies of the Small and Large Intestines. In: Feldman M, Sleisenger MH, and Scharschmidt BF, eds. *Sleisenger and Fordtran's Gastrointestinal and Liver Disease*. Vol. 2. Philadelphia: WB Saunders Co; 1998:1419-1422.
 10. Haubrich WS. Anatomy of the Colon. In: Haubrich WS, Schaffner F, Berk JE, eds. *Bockus' Gastroenterology*. 5th ed, Vol 2. Philadelphia: WB Saunders Co; 1995: 1573-1589.
 11. Romolo JL. Embryology and Anatomy of the Colon. In: GD Zuidema, ed. *Shackelford's Surgery of the Alimentary Tract*. 4th ed. Vol. 4. Philadelphia: WB Saunders Co; 1996:4-15.
 12. Selub SE. Digestion and Absorption: Water, Electrolyte, and Vitamin Transport. In: Haubrich WS, Schaffner F and Berk JE, eds. *Bockus' Gastroenterology*. 5th ed, Vol 2. Philadelphia: WB Saunders Co; 1995: 941, 947-953.
 13. Ellis H. Incisions, Closures, and Wound Management. In: MJ Zinner et al, eds. *Maingot's Abdominal Operations*. 10th ed. Vol. 1. Stamford, CT: Appleton and Lange; 1997:395-399.
 14. Salmons S. Muscles. In: Bannister LH, et al, eds. *Gray's Anatomy: The Anatomical Basis of Medicine and Surgery*. 38th ed. New York: Churchill Livingstone; 1995: 819-828.
 15. Condon RE. The Anatomy of the Inguinal Region and Its Relation to Groin Hernia. In: Nyhus LM and Condon RE, eds. *Hernia*. 4th ed. Philadelphia: JB Lippincott Co; 1995:16-49.
 16. Kong-Weng Eu and Oakley FR. Stoma Construction. In: RN Allan et al, eds. *Inflammatory Bowel Diseases*. 3rd ed. New York: Churchill Livingstone Publishers; 1997:927-929.
 17. Kodner IJ, et al. Colon, Rectum, and Anus. In: Schwartz SI et al, eds. *Principles of Surgery*. New York: McGraw Hill Co, Inc; 1999:1328-1331.
 18. Fazio VW and Erwin-Toth P. Stomal and Pouch Function and Care. In: Haubrich WS, Schaffner F and Berk JE, eds. *Bockus' Gastroenterology*. 5th ed, Vol 2. Philadelphia: WB Saunders Co; 1995:1547-1560.
 19. Pearl RK. Indications for and Techniques of Ileostomy. In: Wastell C, Nyhus LM, and Donahue PE, eds. *Surgery of the Esophagus, Stomach, and Small Intestine*. 5th ed. Boston: Little, Brown and Co; 1995:940-946.
 20. Lavery IC. Technique of Colostomy Construction and Closure. In: Nyhus LM, Baker RJ, and Fischer JE, eds. *Mastery of Surgery*. Vol. 2. New York: Little, Brown and Co; 1997:1420-1429.
 21. Mulholland MW, Zelenock GB, Michelassi F. Atlas of Small Intestine. In: Bell RH, Rikkers LF, Mulholland MW, eds. *Digestive Tract Surgery*. Philadelphia: Lippincott-Raven Publishers; 1996:1284-1288.
 22. Flesch L. Care of Stomas. In: Nyhus LM, Baker RJ, and Fischer JE, eds. *Mastery of Surgery*. Vol. 2. New York: Little, Brown and Co; 1997: 1431-1436.
 23. Dozios RG and Kelly KA. The Surgical Management of Ulcerative Colitis. In: Kirsner JB and Shorter RG, eds. *Inflammatory Bowel Disease*. 4th ed. Baltimore: Williams and Wilkins; 1995:823-824.
 24. Block GE and Hurst RD. Complications of the Surgical Treatment of Ulcerative Colitis and Crohn's Disease. In: Kirsner JB and Shorter RG, eds. *Inflammatory Bowel Disease*. 4th ed. Baltimore: Williams and Wilkins; 1995: 908-910.
 25. Bell et al 1996:32

Understanding Stomas

Earn CE credit at home

You will be awarded one continuing education (CE) credit for recertification after reading the designated article and completing the exam with a score of 70% or better.

If you are a current AST member and are certified, credit earned through completion of the CE exam will automatically be recorded in your file—you do not have to submit a CE reporting form. A printout of all the CE credits you have earned, including Journal CE credits, will be mailed to you in the first quarter following the end of the calendar year. You may check the status of your CE record with AST at any time.

If you are not an AST member or not certified, you will be notified by mail when *Journal* credits are submitted, but your credits will not be recorded in AST's files.

Detach or photocopy the answer block, include your check or money order made payable to AST and send it to the Accounting Department, AST, 6 West Dry Creek Circle, Suite 200, Littleton, CO 80120-8031.

Members: \$6 per CE, nonmembers: \$10 per CE

1. Which is not a section of the small intestine?

- a. jejunum
- b. ileum
- c. cecum
- d. duodenum

2. Which is not a function of the small intestine?

- a. digest food
- b. compact waste
- c. absorb nutrients
- d. produce enzymes

3. Which long, strap-like muscle arises from the costal margin?

- a. xiphoid process
- b. rectus abdominis
- c. internal oblique
- d. transverse abdominis

4. What is the average length of the colon?

- a. 90-125 mm
- b. 90-125 cm
- c. 125-150 mm
- d. 125-150 cm

5. Which of the following criteria is used in site selection?

- a. rectus abdominis muscle
- b. belt line
- c. costal margin
- d. all of the above

6. _____ refers to securing the terminal extent of the stomal serosa to the skin's surface.

- a. tension
- b. maturation
- c. exposure
- d. transection

7. _____ colostomy is indicated after A/P resection.

- a. end-loop
- b. end
- c. loop
- d. tube

8. What is the complication rate for patients who have an ileostomy?

- a. one third
- b. one half
- c. two thirds
- d. three fourths

9. Complications of _____ includes prolapse of the colon, especially with obese patients and stenosis.

- a. end ileostomy
- b. tube colostomy
- c. loop colostomy
- d. end colostomy

10. Which is not part of postoperative care?

- a. high-residue food diet
- b. stoma irrigation
- c. appliance irrigation
- d. cleaning ostomy site

Understanding Stomas

Certified Member

Certified Nonmember

Certification No _____

Name _____

Address _____

City _____ State _____ ZIP _____

Telephone _____

	a	b	c	d		a	b	c	d
1	<input type="checkbox"/>	<input type="checkbox"/>	<input type="checkbox"/>	<input type="checkbox"/>	6	<input type="checkbox"/>	<input type="checkbox"/>	<input type="checkbox"/>	<input type="checkbox"/>
2	<input type="checkbox"/>	<input type="checkbox"/>	<input type="checkbox"/>	<input type="checkbox"/>	7	<input type="checkbox"/>	<input type="checkbox"/>	<input type="checkbox"/>	<input type="checkbox"/>
3	<input type="checkbox"/>	<input type="checkbox"/>	<input type="checkbox"/>	<input type="checkbox"/>	8	<input type="checkbox"/>	<input type="checkbox"/>	<input type="checkbox"/>	<input type="checkbox"/>
4	<input type="checkbox"/>	<input type="checkbox"/>	<input type="checkbox"/>	<input type="checkbox"/>	9	<input type="checkbox"/>	<input type="checkbox"/>	<input type="checkbox"/>	<input type="checkbox"/>
5	<input type="checkbox"/>	<input type="checkbox"/>	<input type="checkbox"/>	<input type="checkbox"/>	10	<input type="checkbox"/>	<input type="checkbox"/>	<input type="checkbox"/>	<input type="checkbox"/>

Mark one box next to each number. Only one correct or best answer can be selected for each question.