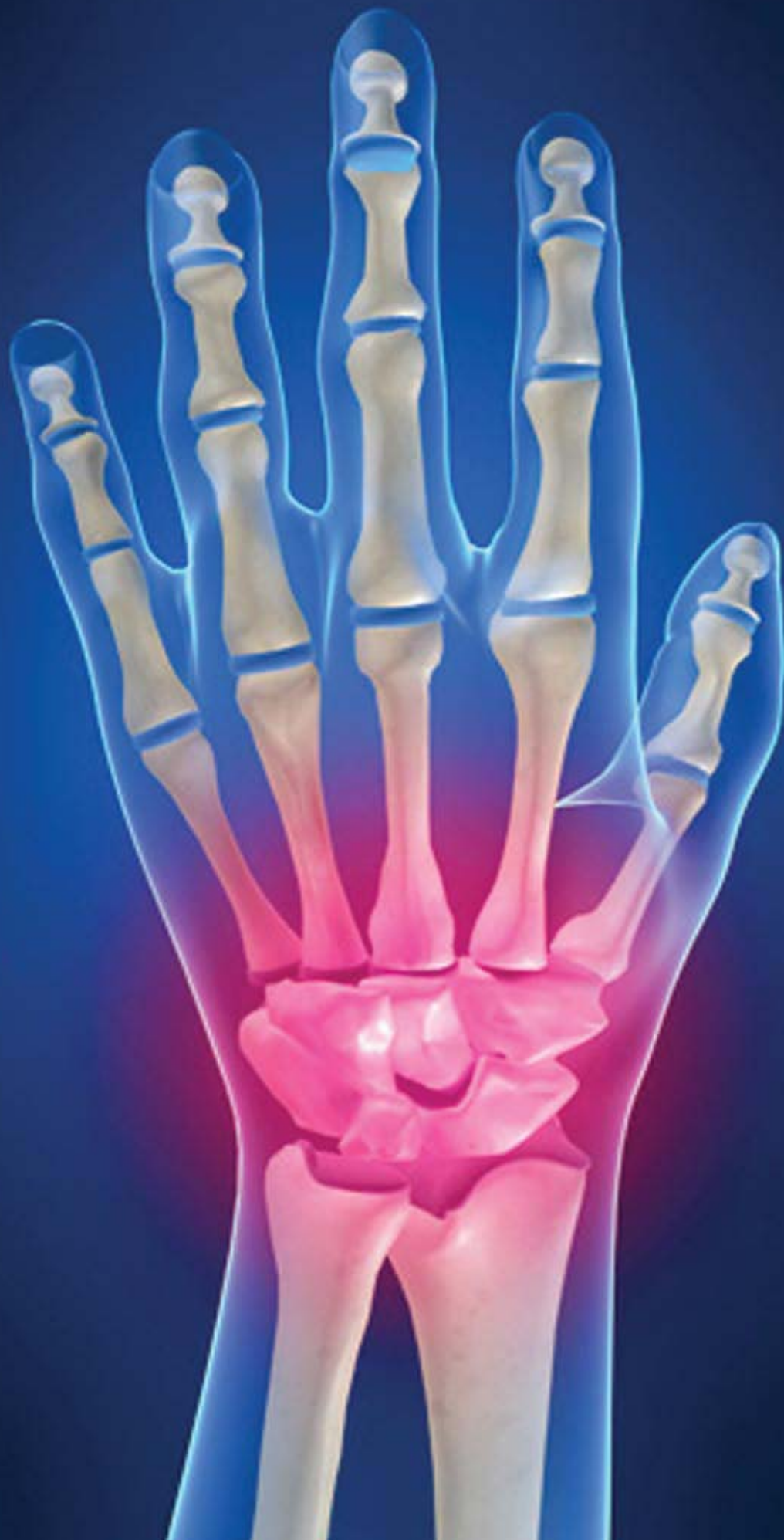



WRIST FUSION:

Fighting back against rheumatoid arthritis

DEBBIE UCHIDA, CST

Rheumatoid arthritis, commonly known as RA, affects more than 2 million people in the United States annually. The disease affects more women than men and typically develops between the ages of 25 and 50. It is a chronic, inflammatory, autoimmune disease that causes the immune system to attack the joints. It can be a very painful and disabling condition that can lead to substantial loss of mobility due to joint destruction.³

LEARNING OBJECTIVES

- Compare and contrast treatment options of rheumatoid arthritis
- Evaluate the advantages and disadvantages of wrist fusion as treatment for arthritis
- Summarize the steps of a wrist fusion procedure
- Distinguish the different categories of arthritis drugs
- Compare and contrast wrist fusion and wrist replacement

While RA is not inherited, genes that may make an individual more likely to develop the disease can be inherited. Researchers continue to work to discover what roles genes may play in developing the condition. It is important to note that there is no known cause for the disease.

While pharmaceutical options can temporarily curb the onset of RA, surgery is also an option. Surgical fusion, sometimes called arthrodesis, has a high success rate in patients with advanced cases of RA. Arthrodesis comes from the words “arthro,” or joint, and “desis,” or binding.

DIAGNOSING RA

The first step in diagnosing the disease is meeting with a rheumatologist, who specializes in rheumatoid diseases, including detecting signs and symptoms of certain types of arthritis. Diagnosis begins with reviewing family history, examining joints for inflammation and deformity, and the skin for rheumatoid nodules, firm, nontender, subcutaneous nodules, which usually occur in chronic active cases of RA. They are commonly associated with more joint deformity and serious extra-articular manifestations, including lungs, eyes and blood vessels.⁹ Certain blood tests and X-rays are often common steps in the diagnosis, which is based on the pattern of symptoms, distribution of the inflamed joints and the blood and X-ray findings. X-rays can show bony erosions typical of RA in the joints. Joint X-rays can also be helpful in monitoring the progression of the disease and joint damage over time.⁹

Abnormal blood antibodies, specifically rheumatoid factor, is found in 80 percent of RA patients. Citrulline antibody is also present in most patients with RA. It is useful in the diagnosis of the disease when evaluating patients with unexplained joint inflammation.

An arthrocentesis may also aid in diagnosis. In this procedure, a sterile needle and syringe are used to drain joint fluid for laboratory testing.

Analysis of the joint fluid can help exclude other causes of arthritis, such as infection or gout.

ANATOMY OF THE WRIST

The wrist is a collection of many bones and joints, making it one of the most complex joints in the entire body. These bones and joints allow us to use our hands in many ways. The wrist must be

extremely mobile to give our hands full range of motion. The metacarpal bones are the long bones in the palm and are connected to the phalanges, the bones in the fingers and thumb. Eight carpal bones, arranged in two rows, compose the anatomy of the wrist

Although it is desirable to avoid surgery on the wrist joint during a period of heightened activity, delay in the face of rampant disease is inadvisable.

joint. The carpal bones connect the two bones of the forearm, the radius and the ulna, to the bones of the hand. The distal row proceeding from the radius to the ulnar side includes the trapezium, trapezoid, capitate and hamate. The proximal row consists of the scaphoid, lunate, triquetrum and pisiform. Functionally, the scaphoid links the rows as it stabilizes and coordinates the movement of the proximal and distal rows.⁴ (Figure 1)

RHEUMATOID DISEASE OF THE WRIST

RA of the hand and wrist principally affects the synovial lining of joints and tendon sheaths. As it progresses, the disease process invades and destroys ligaments and tendons. Intrinsic contracture, a crippling process, develops during the early, acute inflammatory stage.⁵ The synovial disease may directly invade the tendons, which become frayed, fragile, attenuated or weakened and can potentially rupture, although rupture is more likely when bony compression and friction occur. This process within the wrist joint invades and destroys the supportive ligaments and capsules. The disease can extend into the distal radioulnar joint (DRUJ), which becomes fixed in pronation, and the lower end of the ulna is subluxed dorsally, making rotary motion painful.

Symptoms of RA in the wrist joint include pain, swelling, muscle cramping, stiffness at rest and feeling of weakness, especially after extensive use. Numbness to the areas surrounding the metacarpals and phalanges may also occur if swelling is persistent.

CONSERVATIVE TREATMENT FOR RA

RA of the hand and wrist is part of a generalized disease that requires medical treatment. It is important to remember that managing the disease process is critical. Alternatives to surgery

may begin with medical treatment prescribed by a rheumatologist or an orthopedic surgeon. Fast-acting “first-line drugs,” such as methylprednisolone acetate, cortisone and aspirin, are prescribed to reduce pain and inflammation. Slow acting “second-line drugs,” such as gold salts, methotrexate and hydroxychloroquine, promote remission and prevent progressive joint destruction. Newer prescription drug treatments include etanercept, adalimumab, infliximab and rituximab. These drugs are prescribed based of the severity of the patient’s condition.⁷

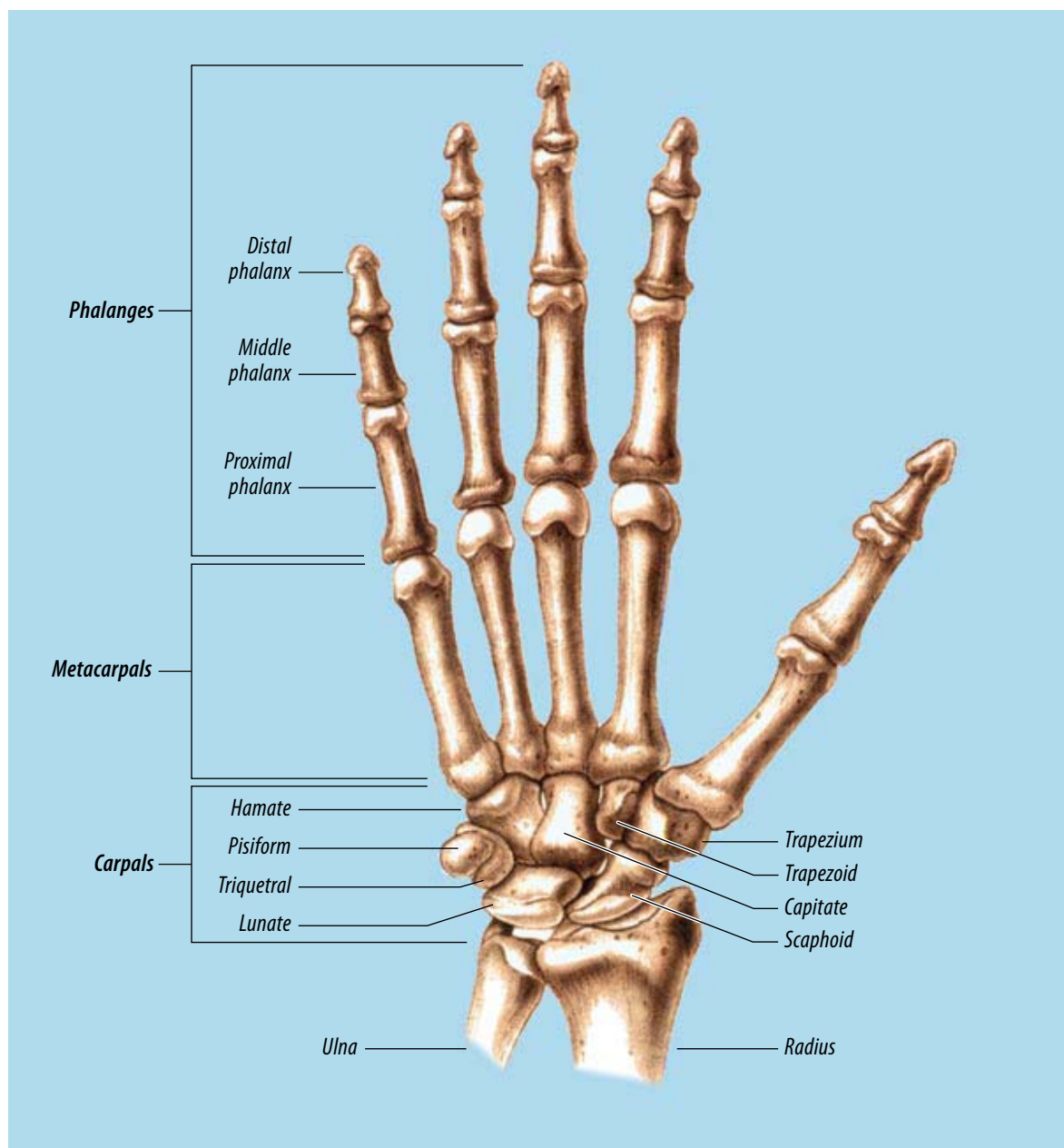


Figure 1.

Surgical Technology for the Surgical Technologist: A Positive Care Approach, Delmar Cengage Learning, © 2008

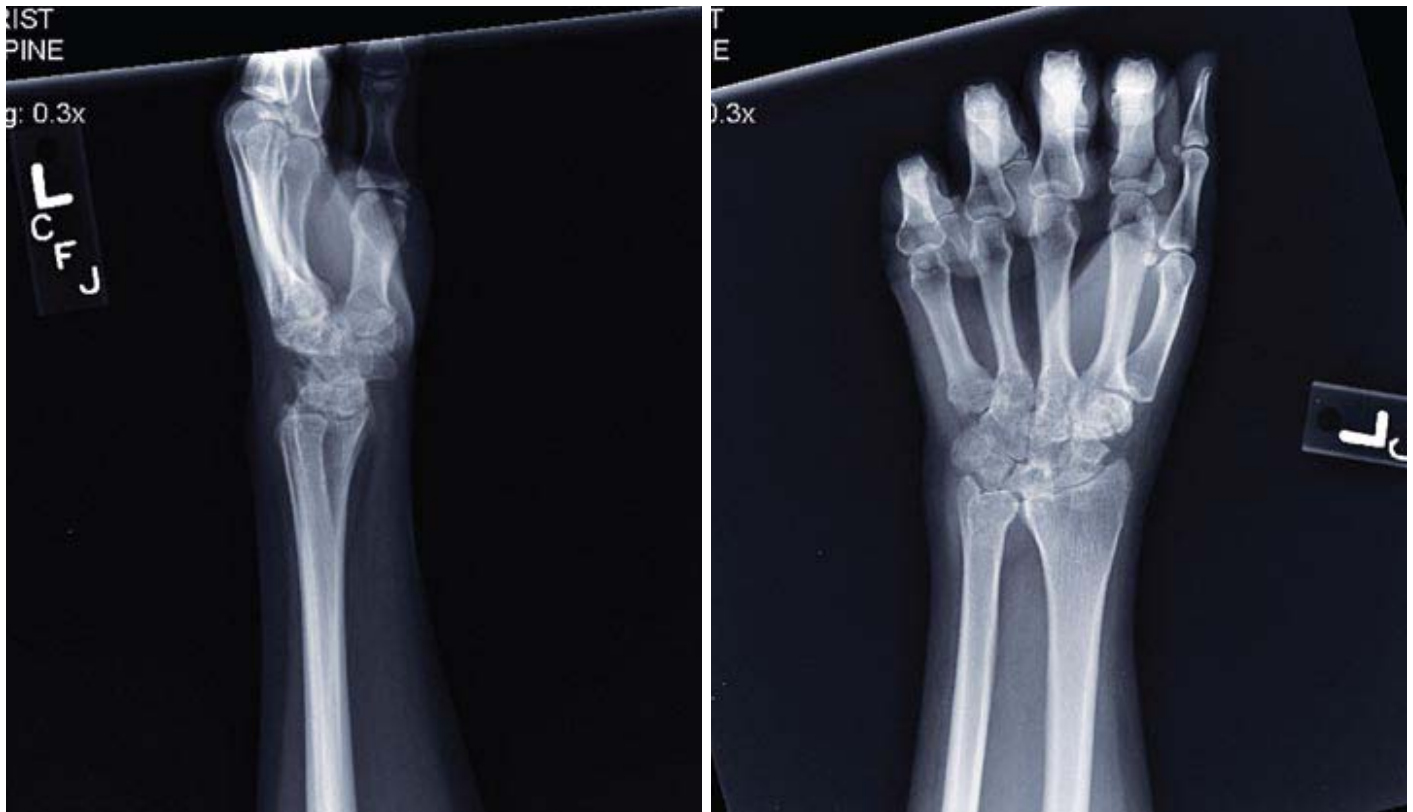

Figure 2.

Proper regular exercise is important in maintaining joint mobility and strengthening the muscles around the joint. Eating a well-balanced diet is also an easy way to help keep the disease under control.

SURGICAL TREATMENT, INCLUDING FUSION

Although it is desirable to avoid surgery on the wrist joint during a period of heightened activity, delay in the face of rampant disease is inadvisable. Procrastination allows further degeneration of secondary joints, articular destruction and muscle and capsular contracture.⁶

Most joints are made up of only two bones that require fusion; however, the wrist is somewhat different because of the complexity of the joint.

A successful fusion involves several bones. The goal of a wrist fusion is to get the radius to fuse into one long bone that connects the carpal bones

of the wrist and the metacarpals of the hand. Fusing the bones together can prevent further deformity, eliminate pain and improve alignment.

If the ulna is not fused, the patient will have continued rotation in the hand. However, with a fused wrist, the patient will not be able to bend the wrist after the operation.

CASE STUDY WITH RATIONALE FOR A SURGICAL WRIST FUSION

The subject in this case study was diagnosed with

RA at 26-years old. She underwent a right knee arthroscopy for complete synovectomy in April 1999, and a left wrist arthroscopy in December 2002, for severe rheumatoid disease with radiocarpal, midcarpal and DRUJ

“The pain I experienced was indescribable. There were many days when I could not even feel my fingertips.” – Debbie Uchida

involvement. After a flare-up in 2005, radiographic evidence showed significant joint destruction in the left wrist. The subject opted for a wrist fusion

procedure to stop further destruction of the joint. The surgery took place on December 1, 2006.

Procedural overview

The patient is taken to the operating room, placed in the supine position and given a general anesthetic. In this case, the left arm is prepped, draped with a tourniquet, and a time out is performed.

A dorsal, longitudinal incision is made and centered over the Lister tubercle, extending along the middle finger metacarpal, and proximally over the distal forearm. A dissection is made down the extensor retinaculum. An incision is then made down into the third compartment and dissection continues down through the capsule and the second and third compartments are elevated radially and ulnarly, respectively. The radiocarpal joint is then opened.

In this case, the metacarpal and radiocarpal joints were extremely involved with active synovium, so a synovectomy was performed. Dissection continued along the middle finger carpal metacarpal (CMC). The CMC joint was debrided, as were the capitate, lunate, scaphoid-capitate, radioscapoid and radiolunate joints. A high-speed burr was used to debride the distal radius. The lunate bone was very necrotic and fragmented. A bone graft was taken from the Lister tubercle in the distal radius and placed in the midcarpal and radiocarpal joints.

A standard bend, Synthes wrist fusion titanium plate was fixed distally, first to the middle finger metacarpal and then proximally to the radius. The wrist was placed in five degrees of ulnar deviation and five degrees of extension based on the bend of the plate. A surgery-directed fluoroscopy confirmed positioning of the plate clinically and radiographically. Screws were then placed and measured. Once the plate was fixed and the wrist was fused, the distal ulna was addressed.² (Figure 3).

The ulnar head was extremely synovitic and had sharp ridges. A distal ulnar resection was deemed

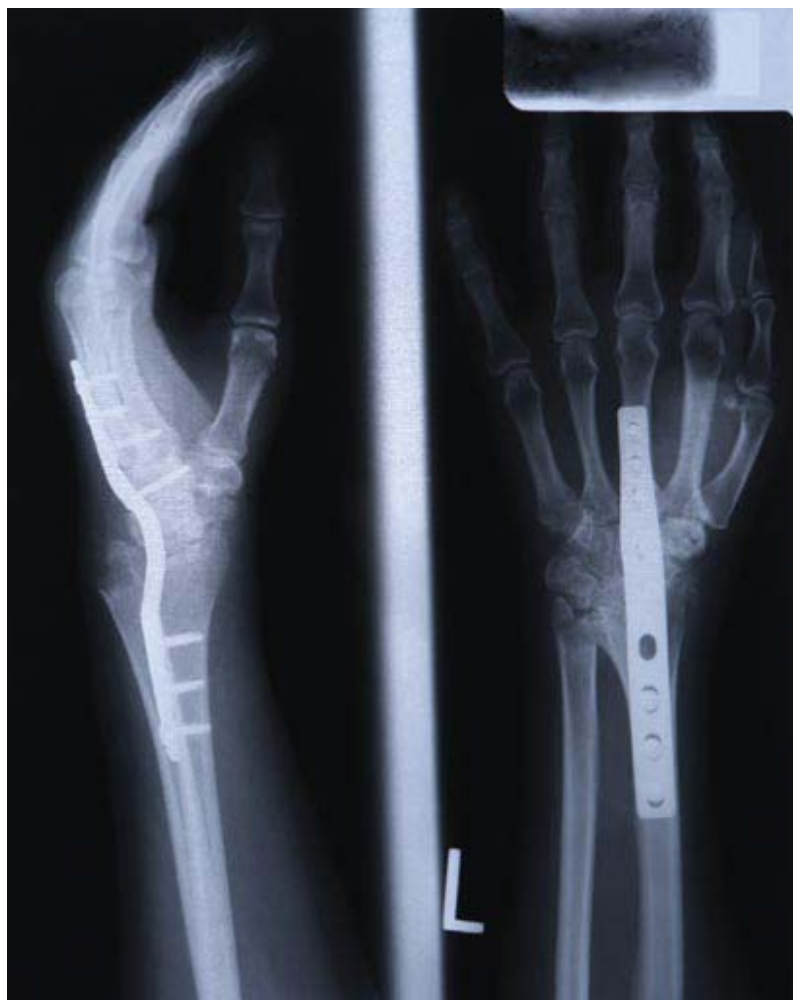


Figure 3.

Image courtesy Synthes, Inc.

necessary because of the synovitis and instability of the DRUJ. The resection was performed using an oscillating saw. The distal ulna was stabilized using local tissue and 3-0 braided nylon suture to imbricate the distal stump of the ulna.

The ulnar head that was removed was used as bone graft in the fusion site, and the wound was irrigated thoroughly. The tourniquet was deflated and bleeding was controlled.

The extensor retinaculum was reapproximated, leaving the extensor pollicis longus (EPL) tendon transposed. The wound was closed with

4-0 polyglactin 910, and 5-0 nylon. A light dressing and volar splint were applied. The patient was taken to the recovery room without apparent complications.¹

CONCLUSION

The goal of a wrist fusion is to halt progression of the disease, relieve pain, provide stability and preserve mobility. Wrist fusion gives patients a stronger wrist for gripping. Regaining strength is especially important to young patients whose work involves intense activities using their hands.

What if surgery isn't the answer?

If surgery is an impractical response to a particular case of arthritis, other, more traditional methods of treatment are available. Prescription drugs have long been considered a primary treatment option for those with chronic arthritis symptoms. Since an individual's response to drugs can vary, and because potential side effects and adverse reactions are also factors, finding the most effective combination of arthritis drugs can be a more difficult process than one might expect. Patients should become knowledgeable about the various arthritis drugs so they can make informed decisions with their doctor.

NSAIDs / COX-2 Inhibitors

Nonsteroidal anti-inflammatory drugs (NSAIDs) are among the most commonly prescribed and widely-used arthritis drugs. There are three types of NSAIDs: salicylates, traditional NSAIDs and Cox-2 selective inhibitors.¹

How they work

Prostaglandins are a related family of compounds that are produced by the cells of the body and have several important functions, including promoting inflammation, pain and fever. They also facilitate the function of blood platelets and protect the stomach lining from the effects of acid. Prostaglandins are produced in the body's

cells by the enzyme cyclooxygenase (Cox). There are actually two Cox enzymes, Cox-1 and Cox-2, both of which produce prostaglandins that promote inflammation, pain and fever. However, only Cox-1 produces prostaglandins that support platelets and protect the stomach. NSAIDs block the Cox enzymes and reduce prostaglandins throughout the body. Consequently, ongoing inflammation, pain and fever are reduced. However, since the prostaglandins that protect the stomach and support the platelets and blood clotting also are reduced, NSAIDs can cause ulcers in the stomach and promote bleeding. NSAIDs differ in how strongly they inhibit Cox-1 and, therefore, in their tendency to cause ulcers and promote bleeding.²

DMARDs

Disease-modifying anti-rheumatic drugs (DMARDs), sometimes called "slow-acting anti-rheumatic drugs," or "second-line agents," can take weeks or months to work and are typically only administered after other treatments have failed. However, research has shown the effectiveness of DMARDs in the treatment of rheumatoid arthritis, psoriatic arthritis and ankylosing spondylitis and the importance of early, aggressive treatment with these drugs. For some, these drugs can stop disease progression and halt joint damage.¹

How they work

DMARDs halt the underlying processes that cause certain forms of inflammatory arthritis, including rheumatoid arthritis (RA), ankylosing spondylitis and psoriatic arthritis. These drugs not only treat arthritis symptoms, but they can also slow progressive joint destruction. Some of these medications are traditionally used to treat other conditions, including cancer or inflammatory bowel disease, or to reduce the risk of rejection of a transplanted organ. However, when chemotherapy medications (such as rheumatrex, trexall or cyclophosphamide) are used to treat RA, the doses are significantly lower and the risk of side effects tends to be considerably less than when prescribed in higher doses for cancer treatment.³

Corticosteroids (Steroids)

Corticosteroids, or glucocorticoids, often called "steroids," are potent drugs that can reduce swelling and inflammation quickly. Most patients notice an improvement in symptoms within days of treatment. These drugs are closely related to cortisol, a hormone produced on the cortex of the adrenal glands. They are prescribed in widely varying doses, depending on the condition and goal of treatment. It has been determined that the potential for serious side effects increases at high doses or with long-term use. Doctors can

It is important to remember to be proactive if a person is experiencing RA symptoms. Early consultation with an orthopedic surgeon or rheumatologist is always recommended. Although there is no cure for rheumatoid arthritis, several medications are available including nonsteroidal anti-inflammatory drugs, steroids and biological therapies to help manage the disease.

ABOUT THE AUTHOR

Debbie Uchida, CST, graduated from surgical technology school in May 1991, and currently

works as a surgical first assistant at Saint Thomas Hospital in Nashville, Tennessee. She has a Synthes wrist fusion plate in her left wrist due to her rheumatoid arthritis. Ms Uchida has served on the Tennessee State Assembly Board of Directors, as well as the education committee, and was awarded the Surgical Technologist of the Year recognition in September 2006, by her co-workers. She would like to respectfully dedicate this article to David Schmidt, MD, and Douglas Weikert, MD.

prescribe short-term, high-dose intravenous steroids in some situations, or give shots or local injections into specific joints for relief.

How they work

Corticosteroids are used to control inflammation of the joints and organs in diseases such as rheumatoid arthritis, lupus, polymyalgia rheumatica and vasculitis. In addition to their anti-inflammatory action, corticosteroids also are immunosuppressive. As a result, they may make certain individuals more susceptible to infection. Corticosteroids closely resemble cortisol, a hormone naturally produced by the body's adrenal glands. This group of medications is available in oral, rectal and intravenous (IV) forms. When people take corticosteroids, their adrenal glands stop producing or slow down the production of normal cortisol. In general, corticosteroids are recommended only for short-term use in order to achieve remission. As valuable as they are in acute situations, corticosteroids are not effective in preventing flare-ups. They are usually given in the lowest possible dosage for the shortest amount of time. *Frequent* short-duration use, however, is not recommended.⁴

Analgesics (Pain Killers)

Analgesics are pain-relieving drugs. Controlling pain is a vital part of treating arthritis. However,

unlike NSAIDs, analgesics do not relieve inflammation. Acetaminophen is the most commonly used analgesic. Narcotic analgesic drugs can also be prescribed for more severe pain.

Biologic Response Modifiers (Biologics)

Biologic Response Modifiers (BRMs) stimulate or restore the ability of the immune system to fight disease or infection. BRMs are drugs derived from living sources, as opposed to being synthesized chemicals. Biological therapy is also called biotherapy or immunotherapy.¹ The body normally produces these substances in small amounts in response to infection and disease. Using modern laboratory techniques, scientists can produce BRMs in large amounts for use in the treatment of cancer and other diseases, such as RA and Crohn's disease.

How they work

Etanercept, infliximab, and adalimumab target TNF-alpha, one of the most important cytokines involved in RA. BRMs, which bind to TNF-alpha, render it inactive, interfering with inflammatory activity and ultimately decreasing joint damage. Anakinra, also a BRM, is considered an IL-1 antagonist. It is the first selective blocker of interleukin-1 (IL-1), a protein that is found in excess in rheumatoid arthritis patients. By blocking IL-1, Anakinra inhibits inflammation

and pain associated with rheumatoid arthritis. It can be used alone, or in combination with DMARDs other than anti-TNF drugs. Abatacept is the first T-cell co-stimulation modulator approved for the treatment of RA. Rituximab, the world's best-selling cancer drug, was FDA approved on March 1, 2006, to be used in combination with methotrexate to treat RA by reducing the signs and symptoms in adult patients, who have moderately-to-severely active RA and have failed with one or more anti-TNF drugs. It is the first treatment for RA that selectively targets the CD20-positive B-cells.⁵

References

1. Eustice Carol. Eustice Richard. Arthritis Drugs: What Are My Options? June 14, 2008. <http://arthritis.about.com/cs/druggen/a/arthdrugoptions.htm>. Accessed July 31, 2008
2. Ogbru Omudhome. Marks Jay W. Nonsteroidal Antiinflammatory Drugs (NSAIDs). September 18, 2005. http://www.medicinenet.com/nonsteroidal_anti-inflammatory_drugs/article.htm. Accessed August 4, 2008.
3. Arthritis: Disease Modifying Medications. <http://arthritis.webmd.com/modifying-medications>. Accessed August 4, 2008.
4. Corticosteroids. February 24, 2006. Chron's & Colitis Foundation of America. <http://www.cffa.org/info/treatment/corticosteroids>. Accessed August 4, 2008.
5. Biological Therapy. April 16, 2002. http://www.medicinenet.com/biological_therapy/article.htm. Accessed August 5, 2008.

References

1. Weikert Douglas MD. Surgeon's dictation obtained with permission. Accessed May 1, 2008.
2. Synthes Wrist Fusion Guide. West Chester PA 2006. Accessed May 1, 2008.
3. Wrist Joint Fusion. Available at: <http://www.allaboutarthritis.com/ALLABOUTARTHRITIS/layoutTemplates/html/en/documentation.com>. Accessed May 1, 2008.
4. Turek Samuel L. Orthopaedics Principles and Their Applications, Fourth Edition, vol.2 J.B. Lippincott 1994. Accessed April 4 2008.
5. Orthopod Wrist Fusion. Available at: http://www.eorthopod.com/public/patient_education/6455/wrist-fusion.html.com. Accessed April 16, 2008.
6. Intrinsic Contracture. Available at: <http://www.ejbs.org/cgi/content/abstract/36/1/10.com>. Accessed April 20, 2008.
7. Lippincott. Raven. Surgical Exposures in Orthopaedics, The Anatomic Approach. Second Edition 1994. Accessed May 1, 2008.
8. Understanding RA. http://www.enbrel.com/ra/understanding_ra.jspchannel=GOSEAandsubchannel=SRAC.com
9. Shiel William C. Rheumatoid Arthritis. http://www.medicinenet.com/rheumatoid_arthritis/page3.htm Accessed July 30, 2008.

Wrist fusion or wrist replacement?

Another surgical option, which many choose over fusion, is wrist replacement. A total wrist replacement is generally indicated when a wrist has sustained a traumatic injury or has been affected by a severe degenerative disease, such as arthritis, and has not responded well to alternative treatments, such as a prescription drug regimen. A wrist replacement eliminates pain and recovers diminished strength in the wrist by restoring length to the muscles and tendons of the fingers and wrist, which improves motion and stability and improves the performance of many every-day activities. Total wrist arthroplasty has become increasingly popular with technological advancements constantly improving results.¹ The most significant advantage to this procedure is that it allows postoperative joint movement, unlike a fusion.

The Procedure

Wrist replacement surgery can be performed under either general or regional anesthesia. Similar to an arthrodesis, an incision is made over the dorsum of the wrist. Sections of the distal ends of the radius and ulna are resected in order to make room for the artificial joint, which is composed of both metal and plastic components. Most of the first row of carpal bones is also removed.²

After the wrist bones have been removed, reamers are used to prepare the central canals in the radius and metacarpals for the stems of the prosthesis, which comes in two parts. The radial component fits against the end of the radius, while the distal, or metacarpal component, replaces the extracted carpals in the wrist. Trial implants are used to determine the proper size of the implant.² Once the correct

size is established and the joint is securely fit into the wrist, a series of tests are performed to ensure proper range of motion and correct movement.¹ The stems of the prosthesis are then permanently secured in place using bone cement. The tendons are returned to their proper position, and the skin is closed and secured with sutures. The wrist is bandaged and secured with a small splint to restrict movement while keeping the wrist in a natural position as it heals. A small drain may be placed in the wound immediately following surgery to prevent fluids from accumulating in the wound, which reduces the chance of swelling and the subsequent stiffness it can cause.¹

While the success rate for total wrist replacements is high, complications do occur, including infection, dislocation, imbalance and loosening. Although early joint replacements were fraught with these problems, complications have been greatly reduced. More attention is being given to the replacement wrist joint after many years of focus on knees and hips. This has generated newer and more effective joint designs and alleviated many of the problems with some of the earlier models. Most implants are expected to last between 10-15 years.¹

References

1. Collins Evan MD. Total Wrist Replacement. http://www.dreanacolins.com/wrist_replacement.html. Accessed: August 11, 2008.
2. Wrist Replacement Surgery. http://allaboutarthritis.com/AllAboutArthritis/layoutTemplates/html/en/contentdisplay/document/condition/arthritis/clinicalArticle/Wrist_Replacement_Surgery.htm;jsessionid=12R2KHW13YU4CQPCCFVDVYKB2IIWTT1. Accessed: August 11, 2008.

Living and Working with Rheumatoid Arthritis: A First-Hand Account

Debbie Uchida, CST

I have been a surgical technologist for 17 years. My hands, and the tasks they perform, have become my life. I have witnessed many procedures to correct deformities caused by rheumatoid arthritis (RA), including wrist fusions and wrist replacements. You never forget the sight of bone destruction. It was horrifying to imagine that I would one day trade places and become a patient, suffering from the crippling disease.

I was diagnosed with RA at age 25. There is no history of the disease in my family, so the diagnosis came as a big surprise. The early stages of my symptoms included excruciating pain and swelling of my right knee and left wrist joints, which limited my daily activities. Mornings were particularly difficult. My joints felt cold and almost frozen. It became increasingly harder for me to lift instrument pans and even set up a sterile field. I wore surgical gloves two sizes too big to accommodate my swollen hand. Heat applied to my wrist between surgeries offered brief comfort. I also wore a brace on my right knee—standing on my feet in the O.R. for a 12-hour shift was challenging.

My rheumatologist prescribed two medications to treat my arthritis: cortisone and methotrexate. I received cortisone injections in my knee and wrist joints every three months to ease the pain and build strength in my joints. Methotrexate, an antimetabolite drug used to treat certain types of cancer and autoimmune diseases, such as RA, was injected into my subcutaneous tissue once a week for two years. Folic acid supplementation is highly recommended while taking methotrexate. All of these drugs were deemed necessary due to the severity of my condition.

After living with RA for many years and surviving both a knee and wrist arthroscopy for complete synovectomies, my condition seemed to be in remission. However, in early 2006, new X-rays of my left wrist revealed a disturbing image. My wrist was in grave danger. My radius, ulna and all eight bones in my wrist were deteriorating and fusing together as one. The pain I experienced was indescribable. There were many days when I could not even feel my fingertips. I met with my orthopedic hand surgeon, Douglas Weikert, MD, to review operative and non-operative options. He warned me that avoiding surgery could potentially destroy my wrist, and the already intense pain would only worsen. Weikert advised that a wrist replacement would be very involved and would require more than one procedure to have a successful outcome. He told me that at my age, and with my occupation, this would not be his recommendation. Instead, he suggested a wrist fusion. This operation would eliminate my pain and rebuild my wrist. My only limitation would be not being able to bend my wrist.

Nervously, I sat trying to gather my thoughts. It was a huge decision, one that I would have to carefully weigh. However, continued pain, swelling and weakness quickly influenced my decision. I would not undergo the wrist replacement, but rather move forward and have the wrist fusion. I received my wrist-saving surgery in December 2006. I went into the operating room with the mindset that I would soon be healed.

I was slightly nervous on the morning of my surgery, but I remember feeling comforted with my teammates at my side. The major surgery lasted only two short hours. Dr Weikert spoke to my husband while I was in the recov-

ery room, and he was extremely pleased with the fusion. There were no unexpected complications. After the operation, I was fitted with a sugar tong splint and I was back at home seven hours after my operation.

The pain was surprisingly tolerable. A few days of rest allowed me to get back on my feet. The splint was removed five weeks after surgery, and a short arm cast was applied. I began physical therapy (pt) immediately, and for those of you who haven't had the pleasure of pt, it is not a pleasant experience! Intensive daily therapy is necessary to rehab the muscles and tendons. It is a vigorous and painful process, however, regaining my motion was crucial. Dedication, determination and a strong will guided me through my therapy. Every day I regained more motion in my fingers, and I was able to grip and hold items tightly. I returned to my role as a surgical technologist 10 weeks after my wrist fusion was performed. I was once again setting up sterile fields, lifting heavy pans and assisting on all surgeries.

I am now almost two years post-op, and it is amazing how much stronger my wrist has become. A small, four-inch scar is all that is visible. Being a surgical technologist and first assistant helped me through both the surgery and recovery process. The knowledge I have gained regarding wrist fusions is a tremendous aid, and I am so very grateful and proud of my profession.

I would like to extend my deepest gratitude to the physicians at Tennessee Orthopedic Alliance for their on-going care and for helping me manage my rheumatoid arthritis. I would also like to thank Joanna Hearington for retrieving my medical information and Chris Bristow with Synthes Orthopedics.

Wrist fusion

Earn CE credits at home

You will be awarded continuing education (CE) credit(s) for recertification after reading the designated article and completing the exam with a score of 70% or better.

If you are a current AST member and are certified, credit earned through completion of the CE exam will automatically be recorded in your file—you do not have to submit a CE reporting form. A printout of all the CE credits you have earned, including Journal CE credits, will be mailed to you in the first quarter following the end of the calendar year. You may check the status of your CE record with AST at any time.

If you are not an AST member or are not certified, you will be notified by mail when Journal credits are submitted, but your credits will not be recorded in AST's files.

Detach or photocopy the answer block, include your check or money order made payable to AST, and send it to Member Services, AST, 6 West Dry Creek Circle, Suite 200, Littleton, CO 80120-8031.

Note this exam awards two continuing education credits. Members: \$12, nonmembers: \$20

- Diagnosis of rheumatoid arthritis does not involve:
 - Reviewing family history
 - Examining joints for inflammation and deformity
 - Blood tests
 - Stress tests
- A/An _____ utilizes a sterile needle and syringe to drain joint fluid.
 - Arthrocentesis
 - Arthroscopy
 - Spinal tap
 - Synovectomy
- _____ develops during the early, acute inflammatory stage.
 - Subluxation of the ulna
 - Intrinsic contracture
 - Fixed DRUJ
 - Bony compression
- _____ bones are the long bones in the palm.
 - Phalanges
 - Trapezium
 - Carpal
 - Metacarpal
- The proximal row does not include the:
 - Scaphoid
 - Lunate
 - Trapezoid
 - Pisiform
- The _____ coordinates the movement of the distal and proximal rows.
 - Radius
 - Scaphoid
 - Hamate
 - Carpal
- Carpal bones connect the _____ and _____ to the bones in the hand.
 - Capitate and trapezium
 - Scaphoid and pisiform
 - Radius and ulna
 - Trapezoid and lunate
- Second-line drugs include all but:
 - Cortisone
 - Methotrexate
 - Gold salts
 - Adalimumab
- If the _____ is not fused, a patient will have continued rotation in the hand,
 - Radius
 - Hamate
 - Ulna
 - Lunate
- Fusing wrist bones together may:
 - Prevent deformity
 - Eliminate pain
 - Improve alignment
 - All of the above

Wrist fusion

- Certified Member Certified Nonmember
- My address has changed. The address below is the new address.

Certification No. _____

Name _____

Address _____

City _____ State _____ ZIP _____

Telephone _____

	a	b	c	d		a	b	c	d
1	<input type="checkbox"/>	<input type="checkbox"/>	<input type="checkbox"/>	<input type="checkbox"/>	6	<input type="checkbox"/>	<input type="checkbox"/>	<input type="checkbox"/>	<input type="checkbox"/>
2	<input type="checkbox"/>	<input type="checkbox"/>	<input type="checkbox"/>	<input type="checkbox"/>	7	<input type="checkbox"/>	<input type="checkbox"/>	<input type="checkbox"/>	<input type="checkbox"/>
3	<input type="checkbox"/>	<input type="checkbox"/>	<input type="checkbox"/>	<input type="checkbox"/>	8	<input type="checkbox"/>	<input type="checkbox"/>	<input type="checkbox"/>	<input type="checkbox"/>
4	<input type="checkbox"/>	<input type="checkbox"/>	<input type="checkbox"/>	<input type="checkbox"/>	9	<input type="checkbox"/>	<input type="checkbox"/>	<input type="checkbox"/>	<input type="checkbox"/>
5	<input type="checkbox"/>	<input type="checkbox"/>	<input type="checkbox"/>	<input type="checkbox"/>	10	<input type="checkbox"/>	<input type="checkbox"/>	<input type="checkbox"/>	<input type="checkbox"/>

Mark one box next to each number. Only one correct or best answer can be selected for each question.

11. The intraoperative phase of a wrist fusion begins with a:

- a. Dissection down the extensor retinaculum
- b. Opening of the radiocarpal joint
- c. Dorsal, longitudinal incision over Lister tubercle
- d. Synovectomy

12. Types of NSAIDs are:

- a. Salicylates
- b. Traditional NSAIDs
- c. Cox-2 selective inhibitors
- d. All of the above

13. Prostaglandins do all but:

- a. Promote inflammation
- b. Facilitate the function of blood platelets
- c. Protect the stomach lining
- d. Halt joint damage

14. Disease-modifying anti-rheumatic drugs are effective in

- a. Rheumatoid arthritis
- b. Psoriatic arthritis
- c. Ankylosing spondylitis
- d. All of the above

15. _____ is a hormone produced in the adrenal gland.

- a. Calcitonin
- b. Thyroxine
- c. Cortisol
- d. GnRh

16. Steroids are used to alleviate:

- a. Lupus
- b. Rheumatoid arthritis
- c. Vasculitis
- d. All of the above

17. _____ stimulate or restore the ability of the immune system to fight disease or infection.

- a. Analgesics
- b. Corticosteroids
- c. BRMs
- d. Cox-2

18. _____ block the Cox enzymes and reduce prostaglandins.

- a. Steroids
- b. Analgesics
- c. BRMs
- d. NSAIDS

19. Which of the following agents is commonly applied to the bleeding surface and edges of bone?

- a. Bone wax
- b. Thrombin
- c. Avitene
- d. Bacitracin

20. For the wrist fusion procedure, the patient was placed in the supine position. What muscles are relaxed by the small pad under the patient's head?

- a. Deltoid
- b. Pyramidal
- c. Strap
- d. Cremaster

Wrist fusion

	a	b	c	d		a	b	c	d
11	<input type="checkbox"/>	<input type="checkbox"/>	<input type="checkbox"/>	<input type="checkbox"/>	16	<input type="checkbox"/>	<input type="checkbox"/>	<input type="checkbox"/>	<input type="checkbox"/>
12	<input type="checkbox"/>	<input type="checkbox"/>	<input type="checkbox"/>	<input type="checkbox"/>	17	<input type="checkbox"/>	<input type="checkbox"/>	<input type="checkbox"/>	<input type="checkbox"/>
13	<input type="checkbox"/>	<input type="checkbox"/>	<input type="checkbox"/>	<input type="checkbox"/>	18	<input type="checkbox"/>	<input type="checkbox"/>	<input type="checkbox"/>	<input type="checkbox"/>
14	<input type="checkbox"/>	<input type="checkbox"/>	<input type="checkbox"/>	<input type="checkbox"/>	19	<input type="checkbox"/>	<input type="checkbox"/>	<input type="checkbox"/>	<input type="checkbox"/>
15	<input type="checkbox"/>	<input type="checkbox"/>	<input type="checkbox"/>	<input type="checkbox"/>	20	<input type="checkbox"/>	<input type="checkbox"/>	<input type="checkbox"/>	<input type="checkbox"/>

Mark one box next to each number. Only one correct or best answer can be selected for each question.