

Ulnar Collateral Ligament Reconstruction

A Look Inside Tommy John Surgery

TOM BORAK

REVIEWED BY GORDON M SINGER, MD, MS

In the summer of 1974, Los Angeles Dodgers pitcher, Tommy John, was 11 years into his major league career and, with a 13-3 record, well on his way towards a potential CY Young Award-winning season. In the process, however, John permanently damaged the ulnar collateral ligament (UCL), also known as the medial collateral ligament (MCL), in his pitching arm.¹

Cryptically referred to as a “dead arm,” symptoms included a significant decrease in pitch velocity and noticeable discomfort during and after throwing sessions. Little was known about this injury at the time, but it was considered a death sentence for a professional baseball career. In fact, many now believe that an undiagnosed UCL tear ultimately forced fellow-Dodger and Hall of Fame pitcher, Sandy Koufax, into early retirement. By all accounts, John’s career as a big-league pitcher was over.

Undeterred by the prognosis, John consulted the Dodgers’ team physician, noted orthopedist Frank Jobe, MD. Faced with the specter of retirement, John was willing to try anything, including surgery, that might resurrect his career. He asked Jobe to “make up something” to fix his dead arm. The procedure that Jobe devised ultimately became the most revolutionary surgery in the history of professional baseball.

LEARNING OBJECTIVES

- Examine the causes of UCL tear or rupture
- Compare and contrast the types of Tommy John procedures
- Assess the pros and cons of allograft versus autograft tendon
- Evaluate the postsurgical rehabilitation program for UCL reconstruction
- Explain the UCL reconstruction procedure

INJURY OVERVIEW AND ANATOMY

The diagnosis of a “dead arm” is the result of a damaged ulnar collateral ligament (UCL) in the elbow of the athlete’s throwing arm. It primarily occurs in athletes competing in overhead-throwing sports, such as baseball, football and javelin. The vast majority of those affected, however, are baseball pitchers.

How common is this injury? According to *USA Today*, during the 2002 and 2003 Major League Baseball seasons, 75 of the nearly 700 pitchers who made an appearance were recipients of UCL reconstruction—approximately one in every nine pitchers.¹⁴ Today, that number has significantly increased.

The UCL is the primary medial stabilizer of the flexed elbow joint. In full extension, the ligament provides about 30 percent of the elbow’s stability, versus about 54 percent when the elbow is in 90 degrees of flexion—where most pitchers’ arms are positioned during delivery. Some estimates contend that the ligament provides more than 70 percent of the elbow’s stability at 90 degrees of flexion.²

In contrast, the radial head is an important secondary stabilizer in extension as well as flexion, providing approximately 30 percent of the elbow’s stability. Resection of both the UCL and the radial head results in gross instability of the elbow and can produce subluxation or dislocation.²

The UCL is composed of three bands: anterior, posterior and transverse. The anterior band, which arises from the anteroinferior surface of the medial epicondyle and inserts on the sublime tubercle of the ulna, provides the major contribution to valgus stability.³

The acceleration phase of the overhead throwing motion, common in baseball, football and javelin, among other sports, causes the greatest amount of valgus stress to the elbow. Extension occurs at a rate of up to 2,500 degrees per second, and continues to 20 degrees of flexion. Dur-

ing this phase, the forearm lags behind the upper arm and generates valgus stress, while the elbow is primarily dependent on the anterior band of the UCL for stability. During the acceleration phase, valgus stress can exceed 60 Newton meters (Nm), which is significantly higher than the measured strength of the UCL in cadavers. The valgus force can, therefore, overcome the tensile strength of the UCL and cause either chronic microscopic tears or acute rupture.³

TREATMENT OPTIONS

This injury is not necessarily life-altering. A person suffering a strained or partially-torn UCL can maintain a relatively normal lifestyle without losing the ability to perform day-to-day functions. With rest and some light rehabilitation, the average weekend-warrior can still go to the gym, play golf and participate in his or her recreational softball league, however, those patients who aspire to return to a high level of competition will most likely require surgery.

In a 2004 interview, James Andrews, MD, a highly-sought specialist for UCL reconstruction, told *Baseball Digest* that, “The [non-surgical] success rate healing these partial tears is a lot lower than we initially thought. It’s at best a 50-50 chance they’ll heal with conservative treatment.”⁴

The reason many athletes simply opt for the surgery is that while the procedure and subsequent recovery period can take a full season from a pitcher’s professional career, those who don’t opt for surgery can wind up being hampered by the injury for two to three years as they rest the injury and then try to return. Despite the rest, which can allow the body to repair some of the small tears, the ligament never regains its full tensile strength, which is critical in holding the joint together structurally. This makes it much easier to re-aggravate the injury and cause further setbacks.

“They yo-yo back and forth,” says Andrews. “They think they’re well, they throw and they get sore. In a lot of cases, we’ve now become more aggressive to go ahead and reconstruct them earlier.”⁴

DURING THE 2002 AND 2003 MAJOR LEAGUE BASEBALL SEASONS, 75 OF THE NEARLY 700 PITCHERS WHO MADE AN APPEARANCE WERE RECIPIENTS OF UCL RECONSTRUCTION – APPROXIMATELY ONE IN EVERY NINE PITCHERS.

METHODOLOGY OF THE SURGICAL PROCEDURE

The basic idea behind the UCL reconstruction is to replace the damaged ligament with a donor tendon. This tendon can come from many places. If the donor tissue comes from the patient's own body, it is called an autograft.

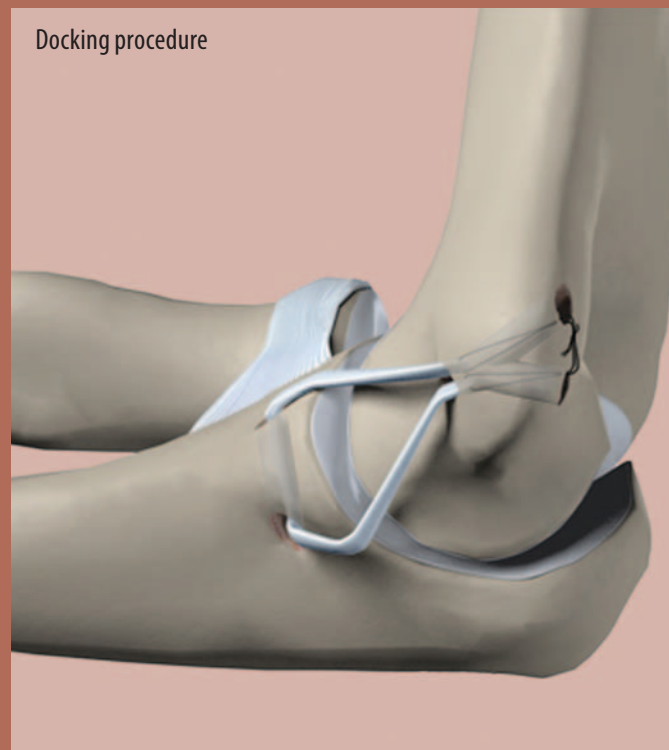
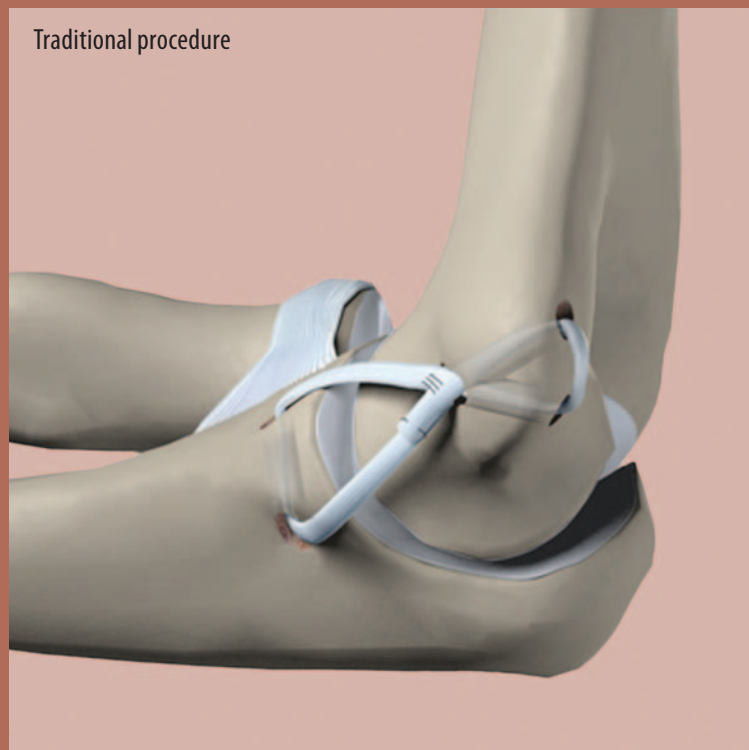
The ideal scenario is to harvest the *Palmaris longus* tendon from the forearm of the patient's operative arm. However, approximately 10-25 percent of the population lack this extra tendon, with an additional percentage whose tendon is too small to sufficiently replace the damaged UCL.⁵ When the *Palmaris longus* is absent or insufficient, the *gracilis*, *plantaris*, toe extensor tendons or a medial strip of the Achilles tendon are viable autograft options.⁶

Several advancements have been made since the procedure was first performed in 1974. At the time the surgery was pioneered, there was no precedent for UCL reconstruction surgery in the elbow. When Frank Jobe, MD, first performed the experimental procedure, he detached the major muscles

of the forearm to reach the bone. The damaged ligament was then completely detached and removed to make room for the replacement tendon. In addition, the ulnar nerve was moved out of the way and, in some cases, re-routed in order to protect it.⁷ Nevertheless, complications with the nerve were not uncommon in early procedures. Postoperative nerve damage can result in numbness and tingling in the ring and small fingers.

In the "traditional" procedure that Jobe pioneered, the replacement tendon is woven, in a figure-eight pattern, through two pairs of holes—two drilled in the medial epicondyle, and two in the ulna—and then sutured to itself.⁸

More recently, however, David Altchek, MD, who serves as medical director for Major League Baseball's New York Mets, has modified the procedure to be less traumatic than the traditional procedure. His "docking" technique differs from the traditional procedure in several ways. Access to the bone is gained using a muscle-splitting technique that gently pries apart the muscle fibers.⁷ The major muscles are not detached and,



in most cases, the nerve is left intact, which reduces the chances of postoperative nerve damage.

Altchek's procedure also minimizes the holes drilled into the bone, reducing the risk of postoperative bone fracture. Unlike the traditional, figure-eight procedure, the graft in the docking technique relates closer to an "elongated D."⁷ The graft enters the humerus bone, but never exits. Instead, sutures secure the tendon and exit the bone through much smaller exit punctures.⁷

According to Gordon Singer, MD, another disadvantage of the traditional technique is that the graft loses a lot of its tension when the tendon is looped through two bone tunnels and sutured to itself. The docking procedure is able to maintain greater tension on the graft because the two ends of the tendon are pulled taut with the attached sutures, which are then tied together.

In a study presented at a special session of the American Shoulder and Elbow Surgeons, held during the American Academy of Orthopedic Surgeons annual meeting, the docking technique is shown to be superior to the traditional method

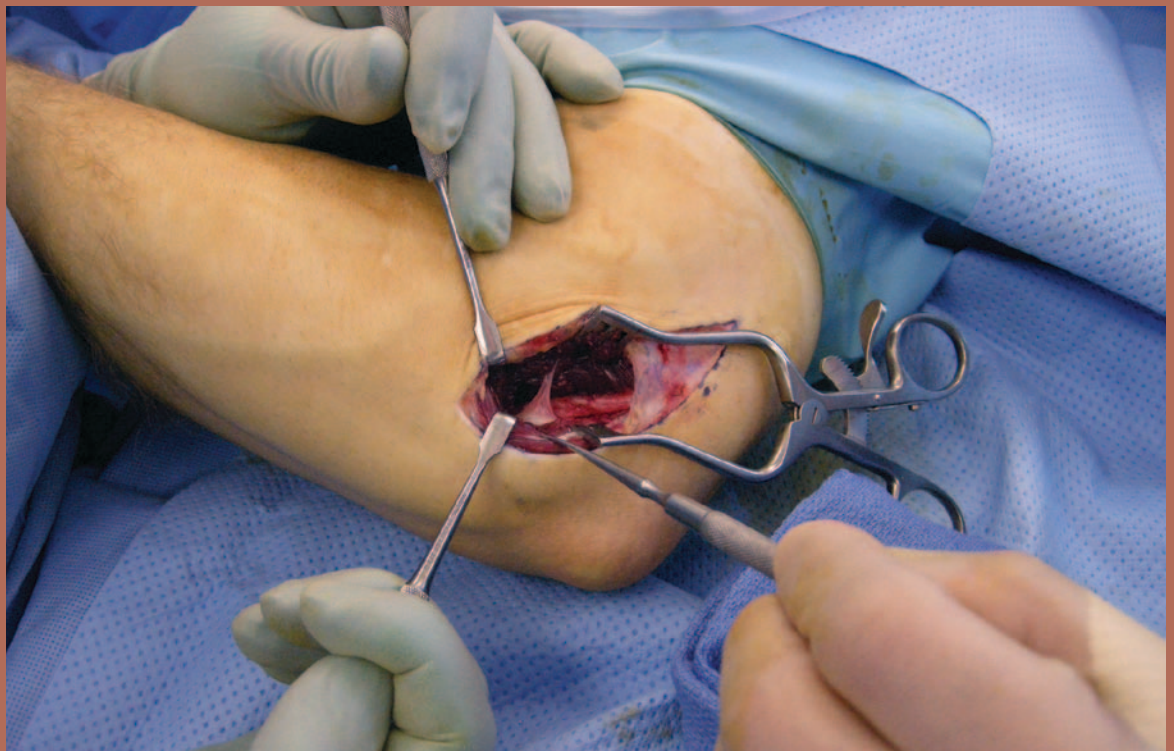
for UCL reconstruction. The study appeared in the December 2006 issue of the *American Journal of Sports Medicine*.

According to the study of 100 athletes (average age 22) who underwent ulnar collateral reconstruction using the docking technique, with an average follow-up of three years, 90 percent had an excellent result (returned to the same or higher level of competition) and 7 percent had a good result (able to compete at a lower level for more than 12 months). Only 3 percent had postoperative nerve complications. With the traditional procedure, studies have shown that only 68 percent of elite-level throwers return to either their prior or a higher level of throwing and 20 percent have nerve complications.⁷

THE PROCEDURE⁹

The patient is taken to the operating room placed in the supine position with the head in alignment. Both arms are extended and the legs are straight. The head and legs are supported by pillows. A safety strap is used for the body, and an

The incision:
Retractors hold the
ulnar nerve out of the
operative area.



arm board, pads and safety strap are used to support the nonoperative arm. The operative arm is positioned on a hand table.

A peripheral nerve block is administered at the surgeon's request for postoperative pain management. In this case, the nerve block is administered with ultrasound guidance. Two grams of cefazolin is administered intravenously, and general anesthesia is also given. A tourniquet is placed on the operative upper arm and the operative upper extremity is prepped and draped in sterile fashion.

In this particular procedure, the patient is receiving an allograft donor tendon. In the event that an autograft tendon is to be used, the extraction site is prepped and draped at the same time as the reconstruction site. The donor tendon is harvested only after the surgeon deems the replacement tendon necessary.

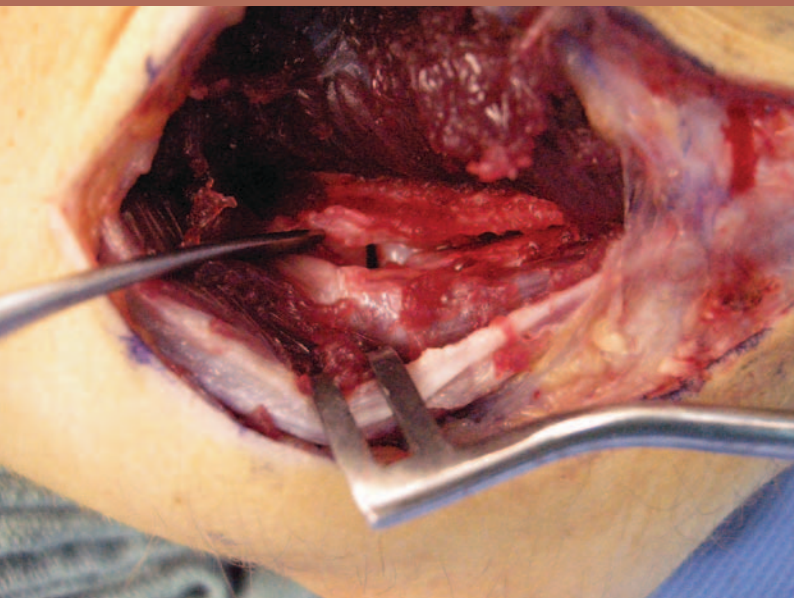
After Esmarch exsanguination, the tourniquet is inflated to the level prescribed by the surgeon.

The procedure is performed under Loupe magnification. A medial incision is made just anteroinferior to the prominence of the medial epicondyle

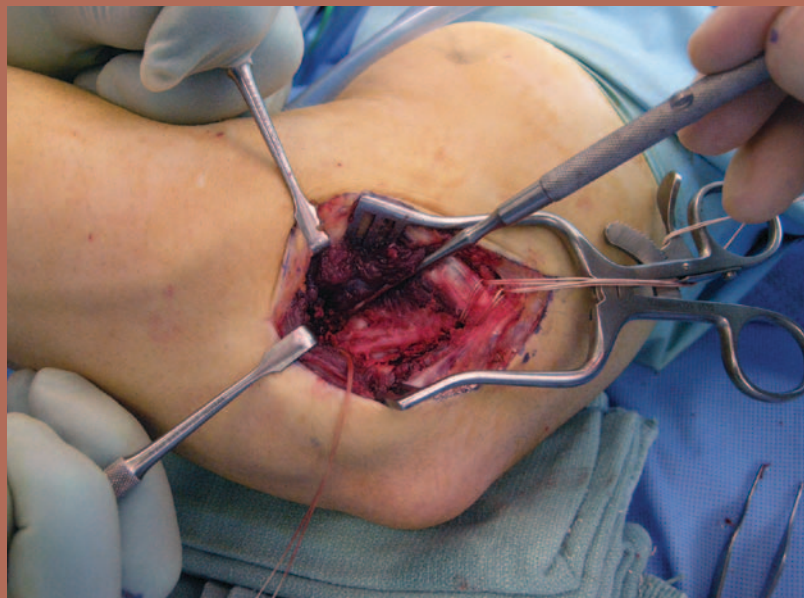in a setting from just above the medial epicondyle to just distal to the ulnar tubercle. The incision is carefully carried through the skin only, in order to avoid injuring any branches of the medial brachial cutaneous nerve. The fascia is identified, split along the flexor pronator area, and slipped down back to the medial epicondyle. The ulnar nerve, first identified through a more posterior split (for location), is then moved more anterior.

The dissection is carried down to the proximal ulna and, specifically, the sublime tubercle, which is located just distal to the joint and is the point of insertion for the ulnar collateral ligament. The sublime tubercle is identified and examined to locate the ulnar collateral ligament. The ulnar nerve, located just inferior to the tubercle, is carefully protected, but not retracted.

Using a small burr, holes are drilled just above and below the tubercle to allow for a bone tunnel. A 26-gauge wire is then used to pass a 0 polyglactin suture through the bone tunnel. The proximal tunnels are then made. A 4.5 mm drill bit is used at the origin, a specific point on the medial



The exposed joint capsule:
The surgeon is indicating the
damaged ligament.



Polyglactin is threaded through the humerus,
indicating the location of the bone tunnels above and
below the tubercle. The polyglactin threaded through
the ulna indicates the location of the bone tunnel.

epicondyle to which the ligament is attached, to create a bone tunnel about a centimeter in depth. A 2.0 drill bit is then used, aiming into the tunnel for two anterior holes, distal and proximal to each other. Then, using 26-gauge wire, additional polyglactin suture is used to pass through these bone tunnels. This is for the docking procedure.

The tendon graft is then opened onto the sterile field. The graft is kept in a frozen moist environment until it is needed, at which time it is thawed and prepared for use. It is identified with regards to its thickest portion, and, using a #2 FiberWire®, a four passes with polyglactin-type lead is made and the graft is trimmed with regards to its width.

Adjustments to both the thickness of the graft and the size of the tunnel may be required; a bone curette is used to increase the size of the tunnel. The tendon is attached to the bone tunnel distally, and brought out through one of the tunnels proximally. This allows the surgeon to measure the length of the tendon. A second #2 FiberWire is placed. The graft is secured with a similar weave, cut to length and passed through the tunnel.

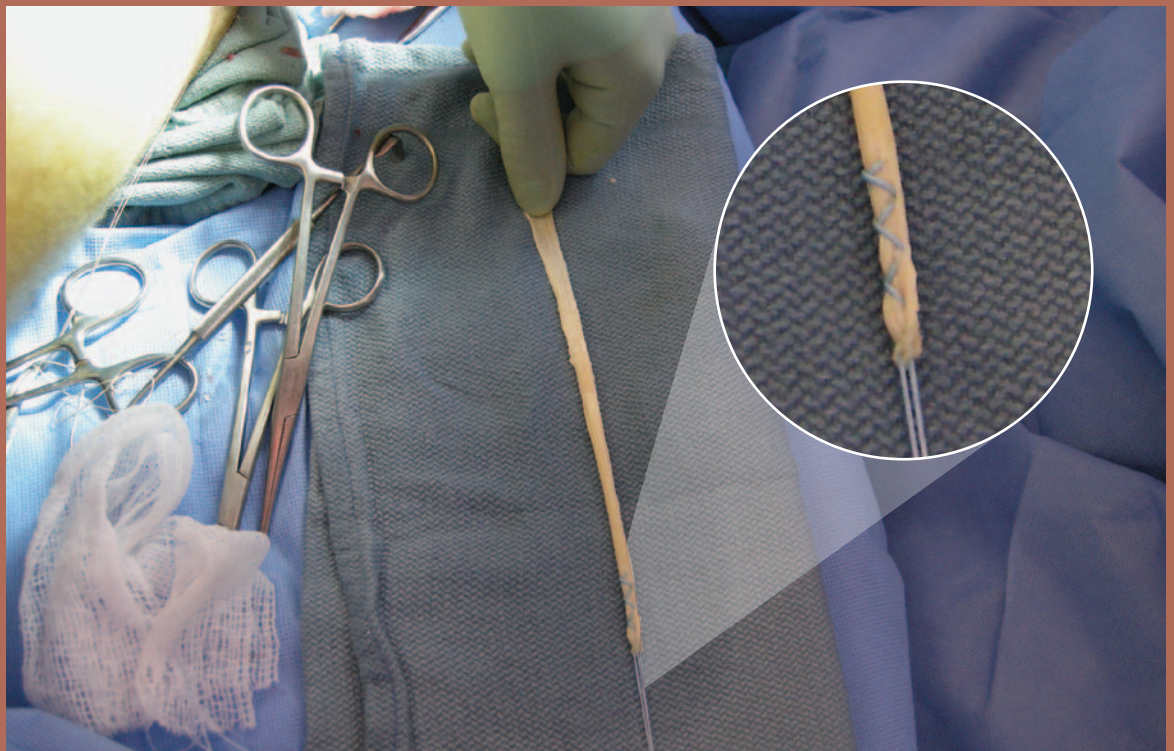
The tendon's position is checked with the elbow in both flexion and extension in order to position it as closely as possible to its normal location, given the appearance of the native ligament. The graft should be as symmetric as possible and significantly tight. The graft is tied in place with the elbow in mild varus.

The wound is irrigated and closed in layered fashion. 0 polyglactin is used to reapproximate the graft within itself to create a single bundle, and the pronator fascia is closed with 0 polyglactin as well. The skin is closed with 3-0 poliglecaprone. Xeroform and a dry dressing is applied. The dressing is composed of sterile gauze (4x4), a sterile cast pad and a fiberglass splint, which is secured with an ACE wrap. The patient is then transferred to the recovery area.

POSTOPERATIVE TREATMENT AND REHABILITATION¹⁰

Though the surgical procedure itself has been refined, James Andrews, MD, contends that the major advancements in the procedure have come

The allograft tendon is ready to be fitted and trimmed to size.



in the postoperative rehabilitation stage. “We’ve learned how much you can accelerate them and how much you can’t,” he said in an interview with *Baseball Digest*.⁴

The body is essentially converting the grafted tendon into a ligament, which includes getting it to carry blood again and training it to start functioning as a ligament.

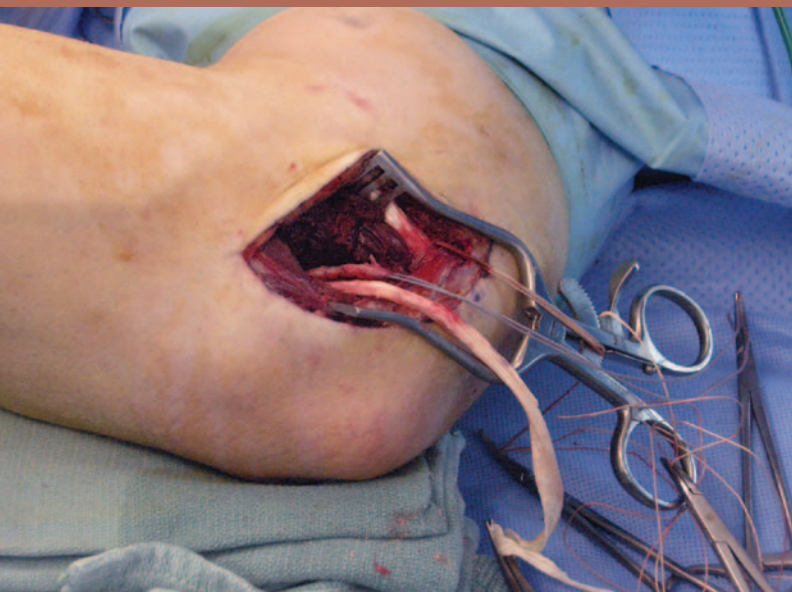
Immediately after the surgery, the affected arm is immobilized in a long-arm splint for 10-14 days. During this time, the wrist is not immobilized and the patient should work on conservative wrist and finger flexion and extension exercises. Grip strengthening is allowed, using putty or a ball. Submaximal bicep isometrics and shoulder isometrics can be initiated, but no external rotation of the shoulder is permitted.

After the splint is removed, the arm is placed in a functional brace, which helps protect the elbow from valgus stress, and limits motion to the prescribed range of flexion and extension. At this time, the patient can begin submaximal wrist isometrics and elbow flexion and extension isometrics.

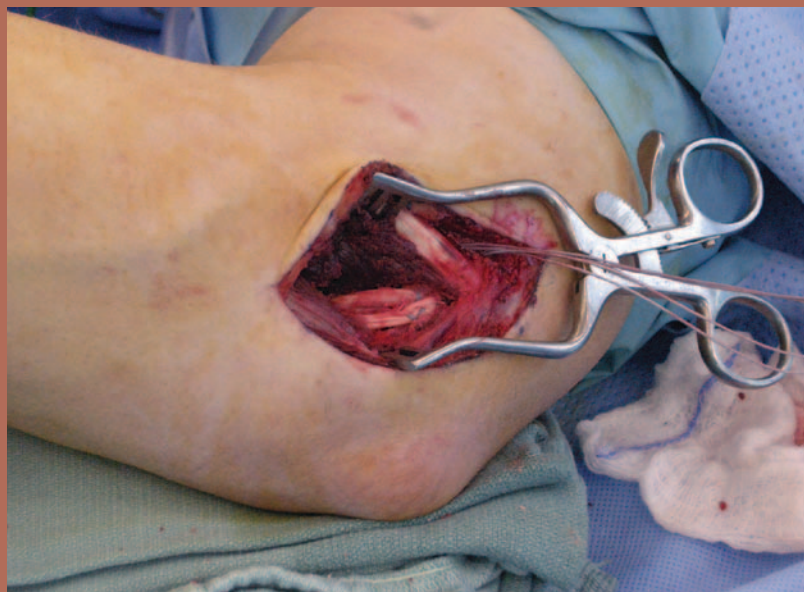
The functional brace is slowly adjusted over time to increase the range of flexion and extension as the graft becomes more stable. During the second week, the brace restricts motion to 30 degrees flexion and 100 degrees extension. At week three, the brace is opened to allow 15/110 degrees of flexion/extension. Week four allows the patient 10/120 degrees of flexion/extension. This is increased to 0/130 degrees of flexion/extension by week six, and the brace is discontinued after the sixth week.

During weeks four through eight, the patient can begin light resistance exercises, including wrist flexion and extension, forearm pronation and supination, elbow flexion and extension, and a progressive shoulder-strengthening and rotator-cuff program. External rotation of the shoulder should be avoided until week six.

The primary goal of weeks 8-12 is to achieve full range of motion. The patient can begin more eccentric elbow flexion/extension exercises and progress the shoulder and elbow flexion/extension isotonic. The patient can also begin a light, bilat-



The tendon is threaded through the ulna and is now ready to be measured and cut.



The tendon is secured and tied in place with polyglactin, which is knotted and clipped.

eral plyometric program. By week 11, the patient can begin a sports-specific training regimen.

At week 20, the patient can begin an interval throwing program. In the beginning stages, however, this program is more accurately described as a light tossing program. Three times per week, for 15 minutes at a time, the patient can toss a ball 30 feet—half the distance between a regulation pitcher's mound and home plate. The distance is increased at a rate of 10 feet per month. A return to normal throwing occurs at approximately nine months.

While a full return is possible within a year, most pitchers need an additional six months to a year to regain their pre-injury form, especially in regards to regaining their stamina and the ability to locate their pitches.

For patients who try to take shortcuts in the rehabilitation process, or return to throwing too quickly, there is a substantial risk of re-injuring the arm. In some cases, this may result in a temporary setback that will allow the patient to return to the rehab program after a short layoff. For others, however, it may result in a second surgery.

The success rate for a second procedure is significantly less encouraging. From 1994-2005, James Andrews, MD, performed 1,169 UCL reconstructions. Of those, only 12 were players that were returning for their second surgery. Andrews estimates that of those 12, only two or three—20 percent—had a chance at returning to their pre-surgery level of baseball.¹⁵

The poster child for multiple UCL reconstructions is, without a doubt, Jose Rijo. The Dominican-born pitcher underwent Tommy John surgery five times in his career,¹⁵ and returned to pitch at the Major League level after each injury, including winning World Series Most Valuable Player honors in 1990, and being named to the All Star team in 1994.¹⁶

GROWING CONCERN IN THE WAKE OF GROWING SUCCESS

The future of Tommy John surgery is both bright and daunting. While innovations to the original procedure, such as the improvements made in the docking technique, continue to increase the success rate of the surgery, more and more surgeries are being performed. The most startling statistic, however, is the frequency of this procedure being performed on patients under the age of 18.

Speaking at the 2008 American Orthopaedic Society for Sports Medicine Annual Meeting, E Lyle Cain, MD, fellowship director for the American Sports Medicine Institute, Andrews Sports Medicine and Orthopaedic Center, expressed concern over this trend.

“Before 1997, this surgery was performed on only 12 of 97 patients who were 18 or younger,” said Cain, who co-authored a study that was released at the conference. “In 2005 alone, 62 of the 188 operations performed were on high school athletes—one third of the surgical group.”¹¹

The overall increase in surgical numbers is amazing. From 1996-99, James Andrews, MD performed the operation on 164 pitchers—19 of whom were high-school aged or younger. From 2004-07, that number jumped to 588 pitchers, with 146 presenting as high school or youth-league players, including some as young as 14-years old.¹²

The increased number of UCL reconstructions in minors can be attributed to several factors. On the medical front, improved diagnostic techniques, heightened awareness of the injury and a high-percentage chance of a positive outcome with surgical intervention are all factors. However, many believe the dramatic increase has a direct correlation with the overuse of young throwing arms.

According to Cain, “In the past 10 years, year-round baseball leagues have proliferated, so the best young pitchers are throwing many more pitches and learning to throw more difficult pitches [such as curve balls and sliders]. It's great that the surgery is successful, but prevention of the injury should be the goal.”¹¹ Implementing pitch counts on young pitchers is one way to prevent over-use. While most Little League organizations limit the number of innings a pitcher can

WHILE A FULL RETURN IS POSSIBLE WITHIN A YEAR, MOST PITCHERS NEED AN ADDITIONAL SIX MONTHS TO A YEAR TO REGAIN THEIR PRE-INJURY FORM, ESPECIALLY IN REGAINING THEIR STAMINA AND THE ABILITY TO LOCATE THEIR PITCHES.

throw in a week, these rules do not govern players who may also pitch in travel leagues or school programs. The combined pitch count can significantly increase the probability of damaging the arm. Another way to reduce stress on young arms is for coaches and parents to encourage their players to focus on learning less-strenuous pitches, such as a change-up as opposed to a curve ball, until their arms have matured. From a baseball perspective, a good change-up can often be more effective than a good curve ball, so perfecting it early can benefit a pitcher's developing repertoire.

Among the most frequently-cited reasons for athletes seeking the surgery is a desire to throw harder. One of the most common misconceptions about the procedure is that pitchers will come back with greater velocity than they had prior to the surgery. In fact, in some instances, young pitchers and their parents have inquired about having the surgery performed on a healthy arm in an effort to add a few more miles per hour to a fastball.¹³ Others, who have been told that their arm did not require surgery by one physician, have played up their symptoms and undergone the operation at the hands of a second.¹³

According to several prominent orthopedists interviewed for a 2007 article in *The New York Times*, there is no evidence that the surgery has been performed on a completely healthy arm, however, "It's something we all worry about," says Andrews.¹³

According to Brian J Sennett, MD, director of sports medicine for the University of Pennsylvania Health System in Philadelphia, "There's nothing in the literature that you throw harder when you come back."¹³

Force and motion are produced by the contraction of muscles. Ligaments do not make the body move. They are rope-like devices that connect bones and stabilize joints, but they do not have any spring-like function. Tommy John surgery relieves pain, but does not provide an increased ability over a healthy, natural ligament to transfer energy from the body to the ball.¹³

Doctors have suggested several theories behind the claims of increased velocity. Among them are the possibility that pitchers are com-

paring their post-surgical results to the velocity from their injured arm; the fact that young pitchers begin to throw harder as they mature; and that pitchers often correct and improve their mechanics (windup, delivery and follow-through) during the rehabilitation phase, while also working to make their bodies stronger.¹³

"[The surgery's ability to improve velocity] isn't always true by any stretch of the imagination," says Andrews. "For the ones that do it, the reason is all the hard work—all the throwing exercises and the development from all the exercises they'd probably never done before."⁴

Therefore, in theory, a pitcher can maximize his natural abilities without surgery simply by adhering to the rigorous rehabilitation routine prescribed to post-Tommy John patients. Substantial focus on strengthening the shoulders and rotator cuff regions are the biggest difference-makers, and the most likely areas to be overlooked in a typical workout routine.

As far as the future of the procedure is concerned, anything is possible.

"We may be able to develop gene therapy," Andrews hypothesizes, "so that we'll be able to inject a substance into a young kid's ulnar collateral ligament and develop it twice as strong as mother nature would. We would hope that we could grow ulnar collateral ligaments in the lab—and exchange parts."¹⁷

CONCLUSION

Ulnar collateral reconstruction surgery has forever changed the landscape of sports medicine. The procedure has resurrected the careers of scores of professional athletes and revitalized the dreams of thousands of others. As innovations continue to improve the success rate, it will undoubtedly continue to grow in popularity. Thanks to the persistence of Tommy John and the ingenuity of Frank Jobe, MD, the "dead arm" is a thing of the past.

IN THEORY, A PITCHER CAN MAXIMIZE HIS NATURAL ABILITIES WITHOUT SURGERY SIMPLY BY ADHERING TO THE RIGOROUS REHABILITATION ROUTINE PRESCRIBED TO POST-TOMMY JOHN PATIENTS.

References

1. Tommy John. 2005. Accessed: January 16, 2009. Available at: <http://www.tommyjohn.net/bio.htm>
2. Wheelless Clifford R. "Medial Collateral Ligament of the Elbow." *Wheelless' Textbook of Orthopaedics*. 2009. Available at: http://www.wheelessonline.com/ortho/medial_collateral_ligament_of_the_elbow. Accessed: January 20, 2009.
3. Kacprowicz Robert F. Chumbley Eric. "Ulnar Collateral Ligament Injury." *emedicine*. September 26, 2007. Available at: <http://emedicine.medscape.com/article/97451-overview>. Accessed: January 22, 2009.
4. Dodd Mike. "Tommy John' surgery: a career-saving procedure for many pitchers." *Baseball Digest*. May 2004. Available at: <http://www.articlearchives.com/sports-recreation/sports-recreation-facilities-venues/1547411-1.html>. Accessed: February 6, 2009.
5. Wheelless Clifford R. "Palmaris Longus." *Wheelless' Textbook of Orthopaedics*. 2009. Available at: http://www.wheelessonline.com/ortho/palmaris_longus. Accessed: February 10, 2009.
6. Elattrache N; Harner C; Mirzayan R; Sekiya J. *Surgical Techniques in Sports Medicine*. Lippincott Williams & Wilkins. 2007. Available at: http://books.google.com/books?id=GCf15nk86FQC&pg=PA279&lpg=PA279&dq=alternatives+to+palmaris+longus&source=web&ots=DV_ZCJMhAs&sig=xwzR_ccWRyGkWXWH7kpU-LbfVso&hl=en&ei=8rGMSf0_J8yL-gbZvsrCw&sa=X&oi=book_result&resnum=8&ct=result#PPA233,M1
7. Hospital for Special Surgery. "Modifications to 'Tommy John Surgery' Improve Outcomes for Baseball Pitchers, Other Athletes." February 2007. Available at: http://www.hss.org/newsroom_15527.asp. Accessed: February 6, 2009.
8. eOrthopod. "Ulnar Collateral Ligament Reconstruction (Tommy John Surgery)" July 2008. Available at: http://www.eorthopod.com/public/patient_education/9633/ulnar_collateral_ligament_reconstruction_tommy_john_surgery.html. Accessed: February 12, 2009.
9. Singer Gordon. Surgeon's dictation. Filed October 31, 2008, 15:40.
10. Lowe Walter. Ulnar Collateral Ligament Reconstruction Protocol. Available at: <http://www.drwaitlowe.com/pdfs/elbow/UCLProtocol.pdf>. Accessed: February 17, 2009.
11. American Orthopaedic Society for Sports Medicine. "Dramatic Increase in Tommy John Surgery in Young Patients Cause for Concern." Press Release. 2008. Available at: <http://www.sportsmed.org/tabs/newsroom/AOSSMPressReleaseDetails.aspx?DID=525>. Accessed: February 17, 2009.
12. Kahn Sam. "Tommy John surgery prevalent among high school pitchers." *Houston Chronicle*. April 22, 2008. Available at: <http://www.chron.com/disp/story.mpl/sports/hso/5719377.html>. Accessed: February 17, 2009.
13. Longman Jere. "Fit Young Pitchers See Elbow Repair as Cure-All." *The New York Times*. July 20, 2007. Available at: <http://www.nytimes.com/2007/07/20/sports/baseball/20surgery.html>. Accessed: February 17, 2009.
14. Carroll Will; Gorman Thomas. 2004. "Inside Tommy John Surgery: Thirty Years of Fixing Pitchers." *Baseball Prospectus*. Available at: <http://www.baseballprospectus.com/article.php?articleid=3486>. Accessed: February 18, 2009.
15. Paulling Daniel. "Tommy John surgery: Few can cut it twice." *USA Today*. July 18, 2007. Available at: http://www.usatoday.com/sports/baseball/2007-07-18-tommy-john_N.htm. Accessed: February 18, 2009.
16. Wikipedia. "Jose Rijo." 2009. Available at: http://en.wikipedia.org/wiki/Jose_Rijo. Accessed: February 18, 2009.
17. Stark Jayson. 2003. "Tommy John surgery: Cutting edge to commonplace." *ESPN.com*. Available at: http://sports.espn.go.com/mlb/columns/story?columnist=stark_jayson&id=1594725. Accessed: February 18, 2009.

Fiber Wire is a registered trademark of Arthrex.

Fast Pitch:

A personal journey through Tommy John surgery

TOM BORAK

I have been playing baseball since I was old enough to pick up a bat. Some of my earliest memories are playing wiffle ball in the backyard with my dad. However, as the oldest of four boys, I was never pushed into organized sports, so I came to the game much later than many kids. I joined my first team with the local YMCA program when I was 10 years old and decided that I wanted to be a pitcher.

In addition to seasonal baseball leagues, my brothers and I played wiffle ball in the backyard just about every day of every summer. We would occasionally all get together for a two-on-two tournament, but most of the time it was my youngest brother, Mark, and I, playing one-on-one. Of course, when it's one-on-one, there is no relief pitcher. Each of us would throw that plastic ball as hard as we could for hours on end, day after day.

I first noticed pain in the elbow of my throwing arm in 1998, my sophomore year of high school. It was toward the end of the season, and because I was also experiencing pain in my knees, I attributed the elbow pain to a growth spurt. The pain was manageable, so I played through it.

I did not play ball in college, opting to focus on academics instead. This time off gave my arm four years of rest.

After I graduated, I took up baseball again in a weekly men's league. I did not factor the four-year layoff into my pre-season workout, and when I started pitching, I was throwing as hard as I could right from the start. About five games into the season, my arm was hurting to the point that I could not throw at all.

I saw a physical therapist, who poked around my elbow a little bit and told me that I had likely torn part of the ligament away from the bone. This assessment was given without any form of diagnostic imaging, such as MRI. She used some gel and an ultrasound machine for therapy treatment and gave

me a brace to wrap around the elbow when throwing. I took another year off from pitching to work on rehab and a training program that focused on core and shoulder strength.

When I started pitching again, my velocity had improved significantly and I had the best season of my life. During the break between the summer and fall seasons, I tried to stay in shape by throwing a couple times a week. During one of these sessions, before which I had not adequately warmed up, I felt a pop in my elbow. I tried to ignore it, but there was



definitely something wrong. In my first start of the fall season, a chilly September morning, my arm felt more fatigued than normal, and I wasn't locating my pitches the way I had a month before. After the third inning, I could not bend my elbow back to pull my jacket over my head. That's when I knew that I was really hurt.

The MRI showed a partially torn ulnar collateral ligament. The doctor I saw, however, recommended rest and therapy. He did not think surgery was necessary to repair my arm. I spent

the prescribed six months in the gym, working my way back. The following season, however, the velocity was gone and after two brief outings, I was designated to the outfield. By the end of the season, however, I could not even make *that* throw. It eventually got to the point that I could not even go to the gym without experiencing discomfort in my elbow due to the instability of the joint.

My appointment with Gordon Singer, MD, was very business-like. I gave him my injury history, my MRI from the previous fall and told him I wanted to throw competitively again. We discussed the risks and benefits associated with the surgery and the very real possibility that I may never get back to my pre-injury level. I assured him that it was a risk that I was willing to take.

Singer explained that he would use the docking technique as opposed to the traditional figure-eight method, citing its success rate and less-invasive nature. We also discussed the source of the donor tendon. I do not have the *Palmaris longus*, so my options were my own hamstring or a cadaver. After weighing the pros and cons of each, I decided on the cadaver in order to avoid dealing with multiple surgical sites and rehab routines.

I underwent surgery on Friday, October 31, 2008. The procedure lasted approximately two hours and there were no complications. The pain was negligible, compared to what I was expecting, after talking to another Tommy John recipient, who had experienced postoperative nerve damage. By Sunday evening, I was only taking Ibuprofen for the pain. I went back to work the following Wednesday, though I was limited in my movement by a hard splint that kept my right arm at a 90-degree angle.

When the hard splint came off, 10 days postoperatively, I began working towards achieving full range-of-motion while confined to the adjustable brace. As scheduled, I was free after six weeks of progressive range of motion increases and had achieved full range of motion two weeks after that. Now, five months since my surgery, my elbow is feeling stronger. The most difficult part of the process for me has been slowly easing my way back into the gym and my throwing program, and trying not to do too much too quickly. It is easy to gain false confidence on days when my arm is pain-free, however, it still lets me know when I am pushing the limits and need to back down.

My goal is a full recovery and a pain-free return to a very active lifestyle, which will ideally include a return to competitive pitching. Thanks to this surgery, I'm almost halfway home.