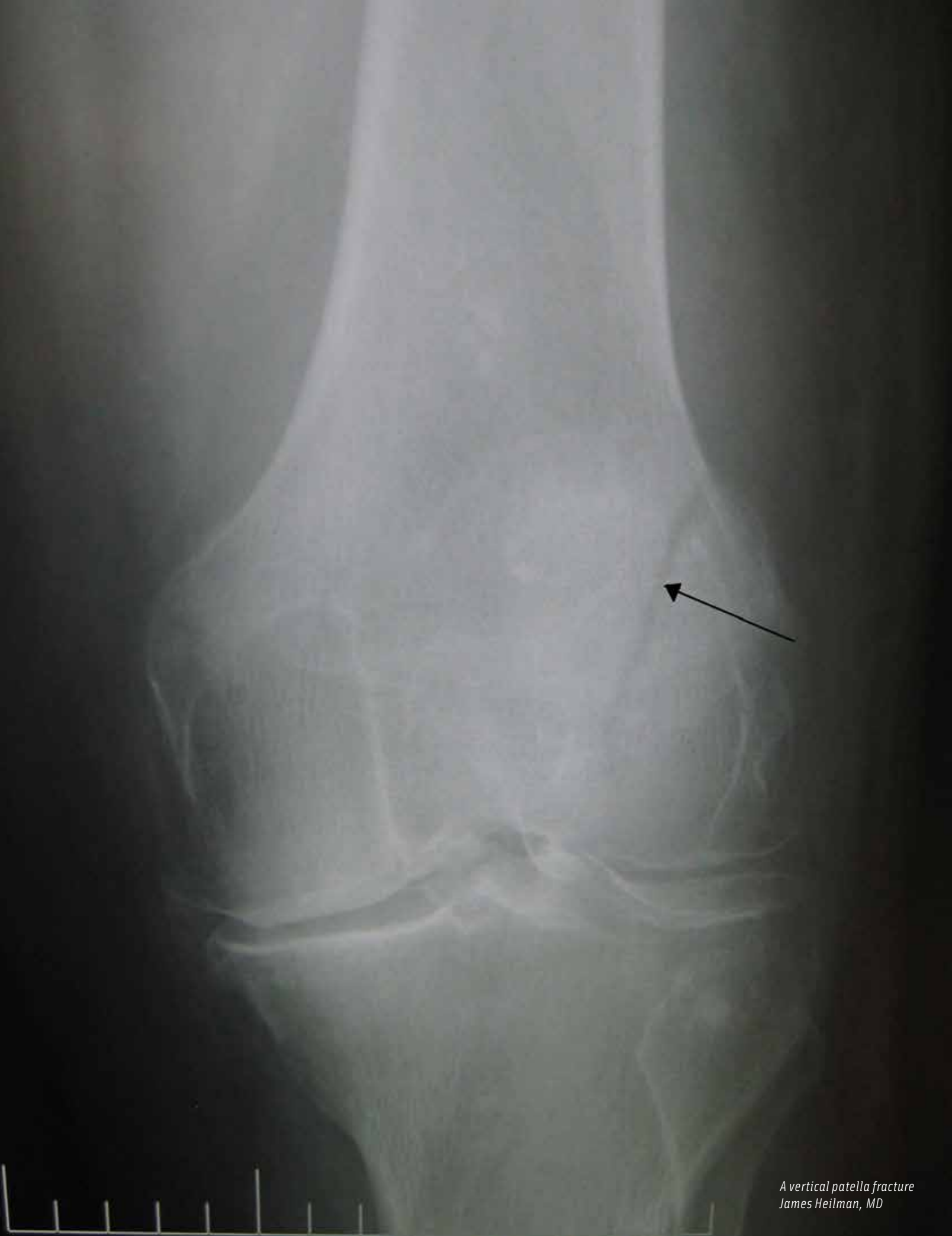



*A vertical patella fracture
James Heilman, MD*

The Surgical Repair of Transverse Patella Fractures

ANGELA MILLER, CST

Patella fractures constitute about 1% of all fractures, and are mostly caused by direct trauma to the front of the knee.¹ There are many types of patella fractures: comminuted, open, nondisplaced and displaced. This article will focus on the about 50% to 80% of patellar fractures that are transverse,³ and requires the surgical treatment using Kirschner wires, also known as K-wires and tension-band wiring.

ANATOMY AND PHYSIOLOGY

The patella is the largest sesamoid bone in the human body. Sesamoid bones are not connected to other bones; instead, they are connected by tendons or are embedded in muscle tissue. The patella bone can be found in the quadriceps tendons. The function of sesamoid bones is to provide a smooth surface over which the tendon can slide, and increases the ability of the tendons to transmit muscle forces.² The patella bone is located anterior to the knee joint, and the posterior surface articulates with the femur. It is attached proximally to the femoral condyles, and attached distally to the condyles of the tibia and upper ends of the fibula.⁵

POSITIONING

During transverse patella fractures a patient will be placed in the supine position, with their arms are placed at each of their sides and

LEARNING OBJECTIVES

- ▲ Learn about the use of K-wires for treatment of this fracture
- ▲ Review the anatomy related to this procedure
- ▲ Recall the patient preparation specific to this operation
- ▲ Examine the role of the surgical technologist during a transverse patella fracture
- ▲ Read about studies comparing the use of metallic versus nonmetallic implants

tucked by the draw sheet. Special padding can be used to support irregular curvatures and prevent hyperextension. Foam or a gel pad is used for the patient's head, and a safety strap is placed across the middle thigh.⁶ Since patient safety is always the number one priority, the surgical technologist can ensure safety by communicating with the team members during positioning, and anticipate unforeseen changes in positioning while table adjustments, or any other body adjustments are being made. If assistance is unavailable, a leg holder device may be attached to the bed during positioning for aid in skin prep. It is important for the registered nurse and surgical technologist to proactively prevent further patient injury by making sure all aspects of the device are attached properly to the bed, and the leg is positioned properly in the device itself.

SKIN PREPARATION AND DRAPING

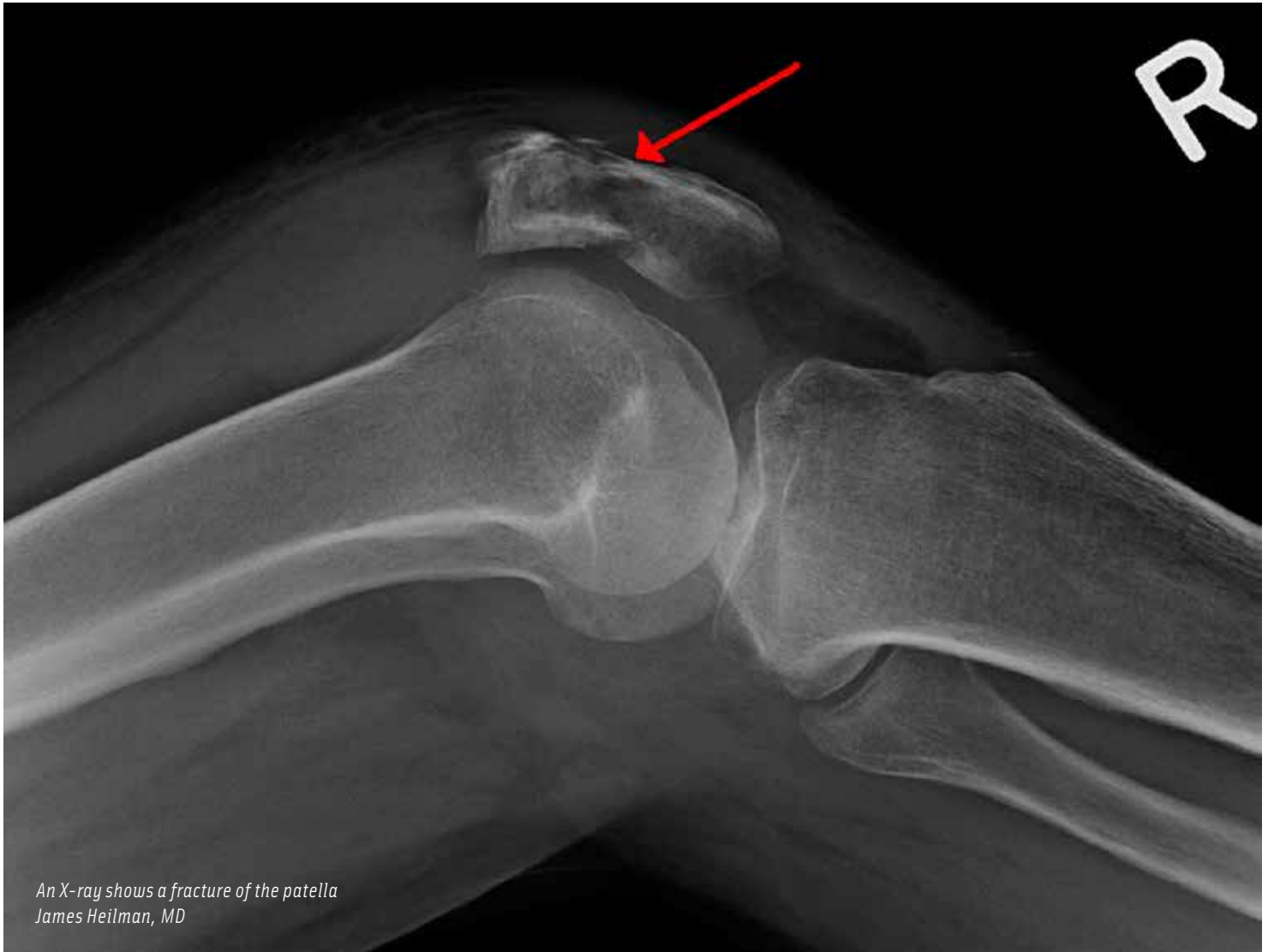During skin preparation, the surgical technologist should help the registered nurse assess the surgical site for any skin lesions or disruptions on the skin. The surgical technologist may also suggest a separate cleanse if they feel the surgical site needs more attention. A betadine soap and paint solution, mixed with sterile water, will be used, and can be sterilely prepared by the CST. Directions for solution measurements should be followed by the manufacturer's recommendation. The extremity will be elevated, and the skin preparation will begin. For knee surgery, the entire extremity will be prepped from the ankle to groin, beginning at the knee moving outward.⁶ If a tourniquet is used, skin prep will be from the ankle to the tourniquet. The surgeon can request to prep the foot as well, but it should remain unexposed and draped separately in a stockinet. It is important for the surgical technologist to watch the solution being applied to prevent the solution from leaking under the tourniquet if one is used. A blue sterile towel will be draped around the tourniquet to protect it from the solution, and to separate the non-sterile device from the sterile field. Once the skin preparation is complete, an impervious sheet, or a split U-drape will be placed under the limb before lowering it to the table. The foot also will be sterilely covered before lowering the limb. At this time, if another sterile personnel is available, the extremity can remain elevated by holding onto the outside sterile portion of the stockinet, while the rest of the drapes are being placed. A lower extremity drape, or two orthopedic split drapes, will be used for this procedure. If

the surgical technologist does not take part in the draping process, it is important they watch the team members who are, and ensure that aseptic technique is properly used. Throughout the procedure, radiographic imaging will be used, so a sterile drape for the machine will be needed. The surgical technologist, along with the registered nurse should pay special attention to the X-ray machine, for it will come into, and leave the sterile field often.

PROCEDURE

During the procedure, the surgical technologist will need to have any special instruments requested by the surgeon along with an orthopedic tray and/or knee tray, a high-speed power drill, drill bits, chucks, any other accessories pertaining to the power source and K-wires that are sharp on both ends.⁷ If the K-wires provided are only sharp at one end, the surgical technologist can sharpen the K-wire by using a K-wire cutter, cutting the blunt end at an oblique angle. Before the incision, general or spinal anesthesia with IV sedation will be administered, and a nerve block may be performed. A time out will follow.

The incision will be made with a #20 blade, and then switched to a clean blade for further dissection. The patella will be exposed, and any debris will be flushed and cleared away with an irrigation solution.⁷ The patella fracture will be reduced using sharp reduction forceps. Extra reduction forceps need to be readily available so they be needed. After the fracture has been reduced, the K-wires are inserted using one of two techniques: the "outside in" or "inside out" technique. Surgeon preference will dictate which technique will be used. When using the "outside in" technique, the first K-wire is placed in an axial direction, and drilled through both of the reduced fragments. The second k-wire will be placed parallel to the first. When using the "inside out" technique, the first K-wire will be positioned at one of the fracture's surface and drilled upward with one end of the K-wire exiting the fragment superiorly. That fragment will be aligned with the other fractured surface. Using the same K-wire, it will be drilled through the other fragment, exiting inferior; hence, the importance of the K-wire being sharp at both ends. The second K-wire then will be inserted parallel. The "inside out" technique may require more adjustments in reduction, but is preferred by most surgeons because the placement of K-wires is less challenging and more exact. Before the surgeon continues with the procedure, the K-wire placement will be checked via X-ray. The K-wire placement



*An X-ray shows a fracture of the patella
James Heilman, MD*

should be more articular than anterior in the patella bone.

The next step of the procedure will be to insert the tension band wire. Even though the K-wires reduce and hold the fragments in place, the added supports of the tension bands will provide extra bone compression. The band will be passed through the quadri-

ceps tendon, closely along the angle of the bone and K-wires. If the surgeon has difficulty passing the band, the surgical technologist will recommend using a large bore needle to help insert and guide the tension band through

The “inside out” technique may require more adjustments in reduction, but is preferred by most surgeons because the placement of K-wires is less challenging and more exact.

the muscle tissue. Placement of the K-wires will determine the shape of the tension band around the patella bone. If the placements of the K-wires are closer together, the surgeon will have the band wrap around the patella bone in a figure

zero. If the K-wires are placed further apart, the surgeon will place the band around the patella bone and K-wires in a figure eight. After the tension band is placed and stable, it will be tightened by pulling away from the patella, and twisting the band at least five times, to prevent them from becoming loose. After the bands are tightened, the ends will be cut and buried into the muscle layer. Once the tension band process is complete, the sharp ends of the K-wire pins will be trimmed, leaving a little exposed in case the pins need to be removed in the future. The surgical technologist and the surgeon will need to communicate when the K-wires have been cut, or trimmed, so small fragments of the wires are not left in the surgical wound.¹ Final X-ray images will be taken before closure.

When using nonmetallic implants, patients experienced less pain and irritation, and using nonmetallic implants does not affect bone union. Since patients weren't experiencing pain, there was no need to surgically remove the nonmetallic implants ...

The incision will be closed with the suture of the surgeon's choice, and skin staples may be used. Before the patient is transferred onto the stretcher from the operating room bed, the repaired knee should be immobilized in a brace or splint to help stabilize the repair while they are in transport. Once the patient is safely transferred to the stretcher, they will be sent to the post-anesthesia care unit. The surgical technologist then must ensure that all disposable items are disposed of correctly; and any sharp instruments are easily detected in the case cart before it is sent to the sterile processing department.

POST-OPERATIVE CARE

After surgery, pain management drugs may be administered by the doctors' orders. Short- and long-term pain management will be discussed between patient and doctor through-

out the recovery process. The severity of the fracture will determine when weight bearing and other activities can be resumed. Rehabilitation is essential to the recovery process. If the patient keeps the knee immobilized too long after the surgery, the muscles may become weak and stiffness may occur.⁴ Exercises directed by their doctor will help strengthen the quadriceps muscle and their range of motion. Physical therapy may be suggested by the physician to help aid in the recovery process.

POSSIBLE COMPLICATIONS

Short-term complications after surgery may include infection and pain. If an infection develops, antibacterial drugs or steroids will be provided. The patella bone and the knee joint are vulnerable after repair, and all measures should be taken so the infection does not spread to those areas. Over time, pain and irritation can develop from the metallic implants due to possible migration of the K-wires or hardware failure. If this occurs, the implants may have to be surgically removed.³ If the patella bone fails to heal properly, or the union of the fragments fail to occur, the thigh muscles that are attached to the top of the patella can pull the broken pieces out of place during the healing phase, which may lead to further surgical repair.⁴

Long-term complications may include arthritis and muscle weakness. Since the patella bone lies in front of the knee joint, if damage has occurred to the patella it most likely will affect the articular cartilage as well. Severe arthritis occurs in about one out of every four to five patients after patella damage. Permanent muscle weakness also can be a long-term complication after surgery, and although it does not permanently immobilize the joint, some range of motion may be lost.⁴

METALLIC VERSUS NONMETALLIC IMPLANTS

Some studies have been conducted regarding the use of nonmetallic implants for transverse patella fractures instead of metallic ones. The metal tension band is replaced with a non-absorbable braided polyester suture, along with absorbable screws and/or plugs. Although the data collected from these studies were poor, some conclusions and advantages have been discovered. When using nonmetallic implants, patients experienced less pain and irritation, and using nonmetallic implants does not affect bone union. Since patients weren't experiencing pain, there was no need to surgically remove the nonmetallic implants, which is ultimately more

cost effective. Some studies observed a mix of nonmetallic and metallic implants, but there was no significant difference in the outcome reported.³




ABOUT THE AUTHOR

Angela Miller is a Certified Surgical Technologist, who specializes in orthopedic surgery. She graduated from the College of DuPage in Glen Ellyn, Illinois, with an associate's degree in surgical technology. Angela would like to give special recognition to the hard working and dedicated operating room staff at Adventist Glen Oaks Hospital. As a former workplace for her, it was there that she gained extensive knowledge in her specialty, and received most of her trainings. She would also like to thank her family and friends for their unconditional love and support, and her former teachers at the College of DuPage, for giving her the skills that has created many opportunities for her. Angela currently works at Johnson Memorial Hospital, in Franklin, Indiana, and is very proud to become a team member to a hospital that provides excellent patient care.

REFERENCES

1. Gebhard, F; Kregor, P; Oliver, C. Patella; Open Reduction; Tension Band Wiring. Patella. Ed. Colton, C. AO Surgery Reference, nd. Accessed April 10, 2015. https://www2.aofoundation.org/wps/portal/surgery?showPage=redfix&bone=Knee&segment=Patella&classification=34-C1.1%2F2&treatment=&method=ORIF+-+Open+reduction+internal+fixation&implantstype=Tension+band+wiring&approach=&redfix_url=1285238823367&Language=en
2. Sesamoiditis-OrthoInfo - AAOS. Sesamoiditis-OrthoInfo - AAOS. American Academy of Orthopaedic Surgeons, nd. Accessed April 10, 2015. <http://orthoinfo.aaos.org/topic.cfm?topic=A00164>
3. Heusinkveld, M; Den Hamer, A; Traa, W; Oomen, P; Maffulli, N. Treatment of Transverse Patellar Fractures: a Comparison between Metallic and Non-metallic Implants. Treatment of Transverse Patellar Fractures: A Comparison between Metallic and Non-metallic Implants. British Medical Bulletin, March 25, 2013. Accessed April 10, 2015. <http%3A%2F%2Fbmb.oxford-journals.org%2Fcontent%2Fearly%2F2013%2F04%2F24%2Fbmb.ltd013.full>
4. Patellar (Kneecap) Fractures-OrthoInfo - AAOS. Patellar (Kneecap) Fractures-OrthoInfo - AAOS. American Academy of Orthopaedic Surgeons, nd. April 10, 2015. <http://orthoinfo.aaos.org/topic.cfm?topic=A00523>
5. Alexander, EL; Rothrock, JC; Alexander, SM. Orthopedic Surgery. Alexander's Surgical Procedures. St Louis, MO: Elsevier/Mosby, 2012. 437. Print.
6. Fuller, JR. Surgical Technology: Principles and Practice. St Louis, MO: Saunders Elsevier, 2010. 182+. Print.
7. Goldman, MA. Orthopedic Surgery. Pocket Guide to the Operating Room. Philadelphia: FA Davis, 2008. 599-601. Print.



Earn CE Credits at Home

You will be awarded continuing education (CE) credits toward your recertification after reading the designated article and completing the test with a score of 70% or better. If you do not pass the test, it will be returned along with your payment.

Send the original answer sheet from the journal and make a copy for your records. If possible use a credit card (debit or credit) for payment. It is a faster option for processing of credits and offers more flexibility for correct payment. When submitting multiple tests, you do not need to submit a separate check for each journal test. You may submit multiple journal tests with one check or money order.

Members this test is also available online at www.ast.org. No stamps or checks and it posts to your record automatically!

Members: \$6 per credit

(per credit not per test)

Nonmembers: \$10 per credit

(per credit not per test plus the \$400 nonmember fee per submission)

After your credits are processed, AST will send you a letter acknowledging the number of credits that were accepted. Members can also check your CE credit status online with your login information at www.ast.org.

3 WAYS TO SUBMIT YOUR CE CREDITS

Mail to: AST, Member Services, 6 West Dry Creek Circle Ste 200, Littleton, CO 80120-8031

Fax CE credits to: 303-694-9169

E-mail scanned CE credits in PDF format to:

memberserv@ast.org

For questions please contact Member Services - memberserv@ast.org or 800-637-7433, option 3.

Business hours: Mon-Fri, 8:00a.m. - 4:30 p.m., MT

The Surgical Repair of Transverse Patella Fractures

#392 August 2016 1 CE credit \$6

1. Sesamoid bones are connected by _____.
 - a. Muscles
 - b. Arteries
 - c. Bones
 - d. Tendons
2. If a tourniquet is used, skin prep will be from the _____ to the tourniquet.
 - a. Groin
 - b. Thigh
 - c. Foot
 - d. Ankle
3. _____ provide extra bone compression.
 - a. K-wires
 - b. Suture
 - c. Tension bands
 - d. Staples
4. Once the skin preparation is complete, a _____ will be placed under the limb before lowering it to the table.
 - a. Split U-drape
 - b. Orthopedic split drapes
 - c. Incision drape
 - d. None of the above
5. The initial incision will be performed with a _____ blade.
 - a. #14
 - b. #20
 - c. #21
 - d. #10
6. The patella bone is located _____ to the knee joint.
 - a. Posterior
 - b. Interior
 - c. Anterior
 - d. Proximal
7. A sharp reduction forceps will be used to reduce the _____.
 - a. Patella
 - b. Fracture
 - c. Tibia
 - d. Spinal tibia
8. For the surgical repair of a transverse patella fracture, the patient will be placed in the _____ position.
 - a. Lateral
 - b. Prone
 - c. Supine
 - d. Supine with arms overhead
9. Which technique is preferred by most surgeons?
 - a. Inside out
 - b. Outside in
 - c. Lateral to anterior
 - d. Anterior to posterior
10. Following the placement and stability of the tension band, the band will be twisted at least _____ times to prevent them from becoming loose.
 - a. 3
 - b. 4
 - c. 5
 - d. 6

THE SURGICAL REPAIR OF TRANSVERSE PATELLA FRACTURES #392 August 2016 1 CE CREDIT \$6

NBSTSA Certification No. _____

AST Member No. _____

My address has changed. The address below is the new address.

Name _____

Address _____

City _____ State _____ Zip _____

Telephone _____

Check enclosed Check Number _____

Visa MasterCard American Express

Credit Card Number _____

Expiration Date _____

	a	b	c	d
1	<input type="checkbox"/>	<input type="checkbox"/>	<input type="checkbox"/>	<input type="checkbox"/>
2	<input type="checkbox"/>	<input type="checkbox"/>	<input type="checkbox"/>	<input type="checkbox"/>
3	<input type="checkbox"/>	<input type="checkbox"/>	<input type="checkbox"/>	<input type="checkbox"/>
4	<input type="checkbox"/>	<input type="checkbox"/>	<input type="checkbox"/>	<input type="checkbox"/>
5	<input type="checkbox"/>	<input type="checkbox"/>	<input type="checkbox"/>	<input type="checkbox"/>
6	<input type="checkbox"/>	<input type="checkbox"/>	<input type="checkbox"/>	<input type="checkbox"/>
7	<input type="checkbox"/>	<input type="checkbox"/>	<input type="checkbox"/>	<input type="checkbox"/>
8	<input type="checkbox"/>	<input type="checkbox"/>	<input type="checkbox"/>	<input type="checkbox"/>
9	<input type="checkbox"/>	<input type="checkbox"/>	<input type="checkbox"/>	<input type="checkbox"/>
10	<input type="checkbox"/>	<input type="checkbox"/>	<input type="checkbox"/>	<input type="checkbox"/>

Make It Easy - Take CE Exams Online

You must have a credit card to purchase test online. We accept Visa, MasterCard and American Express. Your credit card will only be charged once you pass the test and then your credits will be automatically recorded to your account.

Log on to your account on the AST homepage to take advantage of this benefit.