

# Abdominal Aortic Aneurysm Resection: Transperitoneal Approach

Tracey A Ross CST, MEd

The term aneurysm originates from the Greek *aneurysma* meaning, “a widening.” An aneurysm is a localized, abnormal dilation in an artery, resulting from the mechanical pressure of blood on a vessel wall weakened by biochemical alterations.<sup>8</sup> As the vessel wall becomes progressively weaker, the aneurysm gradually enlarges, and the risk of spontaneous rupture increases. An aortic aneurysm can also be described as a local dilation of the aorta, involving a minimum 50% increase in diameter.<sup>6</sup>

Abdominal aortic aneurysm (AAA) resection is the surgical obliteration of an aneurysm that may or may not include the iliac arteries, with the insertion of a synthetic prosthesis to re-establish functional continuity.<sup>7</sup> The majority of AAAs begin below the renal arteries and may extend to involve the bifurcation and common iliac arteries.<sup>27</sup>

Approximately 200,000 new AAA cases are diagnosed each year, and 40,000 surgical repairs are performed.<sup>1</sup> Thirty percent of AAAs will rupture, leading to an 80% mortality rate and 9,000 US deaths annually.<sup>14</sup>

There are essentially three surgical approaches to AAA repair:

- traditional invasive surgical intervention, involving an abdominal (transperitoneal) approach
- retroperitoneal approach
- AAA repair utilizing the endovascular graft

This article focuses on the traditional approach to AAA repair, utilizing the transperitoneal approach during elective surgical intervention.

## Historical perspective

Aneurysms have been identified since 2000 BCE when the Ebers Papyrus, one of the earliest known medical texts, described traumatic aneurysms of the peripheral arteries.<sup>22</sup> Antyllus, who reported the first elective operation for treatment of an aneurysm in the second century, recommended ligating the artery above and below the aneurysm, incising the sac, evacuating the contents, and closing the aorta by granulation.<sup>22</sup>

The 16th century anatomist Andreas Vesalius documented one of the first descriptions of an abdominal aortic aneurysm.<sup>17</sup> Alexis Carrel (1873-1948) demonstrated in animals that a segment of aorta could be replaced with a piece from

another artery or vein and successfully anastomosed to other blood vessels. His contributions helped establish modern techniques of blood vessel anastomosis and suturing techniques that would be linked to successful vascular surgery.

In 1888, Rudolph Matas (1860-1957) developed the surgical technique of endoaneurysmorrhaphy, which involved clamping above and below the aneurysm, opening it, ligating the branches, and then buttressing the wall with imbricated sutures.<sup>28</sup> Meanwhile, other clinicians were attempting to induce thrombosis of AAAs by inserting intraluminal wires.<sup>25</sup> Matas performed the first successful aortic ligation in a patient with an AAA in 1923.<sup>19</sup>

In 1948, C E Rea wrapped cellophane around the neck and over the antero-lateral surface of an aneurysm to induce a fibrotic reaction and limit expansion of the aneurysm.<sup>26</sup> In 1949, Rudolph Nissen utilized Rea's surgical technique to treat Albert Einstein's symptomatic AAA. Einstein survived six years before succumbing to eventual rupture.<sup>3</sup>

It was not until March 29, 1951, that Charles DuBost published the first account of successful replacement of an aneurysm with a freeze-dried homograft.<sup>4</sup> Additional advances in vascular surgery would come in 1957 when DeBakey and colleagues introduced knitted Dacron® grafts, providing the first effective synthetic vascular graft material.<sup>12</sup>

## Anatomy

The aorta is a large artery which is the main trunk of the systemic arterial system. It originates from the left ventricle as the thoracic aorta and ends at the left side of the body at the level of the fourth lumbar vertebra, where it divides to form the right and left common iliac arteries. The aorta is comprised of the ascending aorta, the aortic arch, and the descending aorta, which is divided into the thoracic aorta and the abdominal aorta<sup>5</sup> (Figure 1).

Aneurysms are defined as a focal dilation at least 50% larger than the expected normal arterial diameter. A common definition of the AAA is a transverse diameter of at least 3 cm and, for

**FIGURE 1:**  
Structure of  
the aorta.

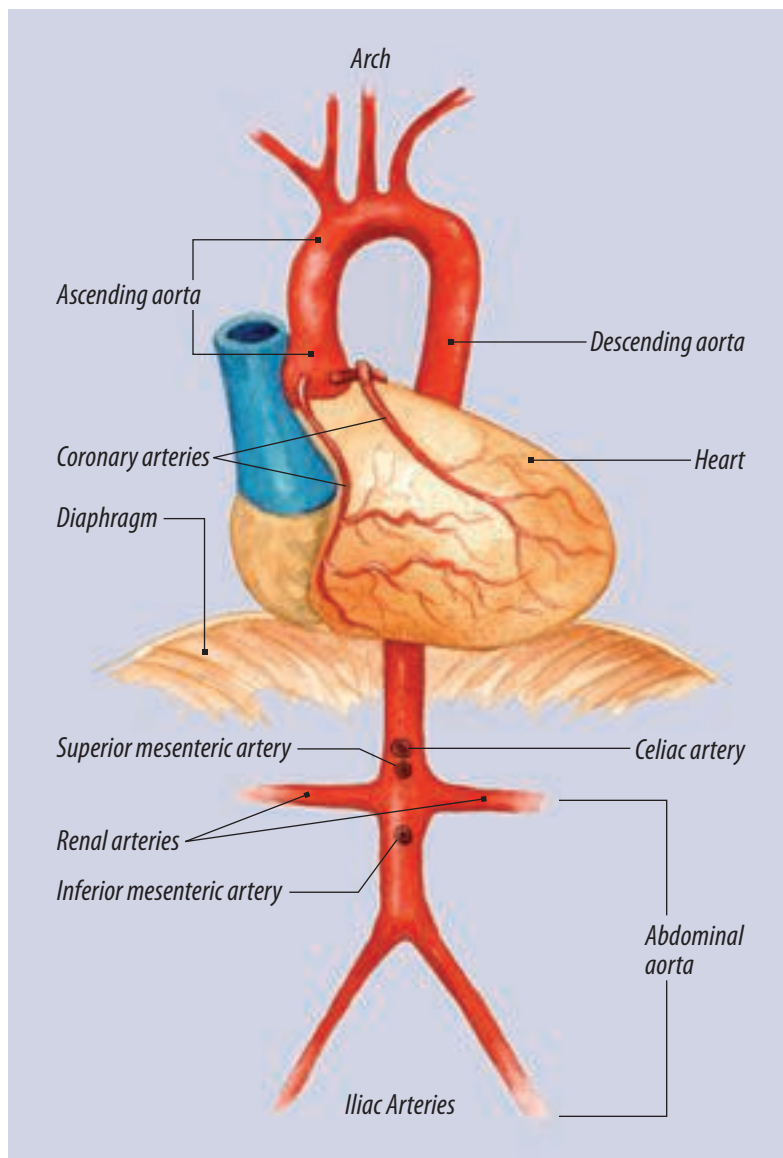


TABLE 1. **Branches of the abdominal aorta**<sup>31</sup>

Branch of the abdominal aorta	Organ supplied
Inferior phrenic arteries	Diaphragm
Celiac arteries: hepatic artery, left gastric artery, splenic artery	Liver, stomach and esophagus, spleen, pancreas
Superior mesenteric artery	Small intestines, cecum, ascending and transverse colon
Suprarenal arteries	Adrenal glands
Renal arteries	Kidneys
Gonadal arteries	Testes or ovaries
Inferior mesenteric artery	Transverse, descending and sigmoid colon and rectum

a common iliac aneurysm, a transverse diameter of at least 1.8 cm.<sup>24</sup> Pearce and colleagues documented that normal aortic diameter gradually decreases from the thorax (28 mm in men) to the infrarenal location (20 mm in men). At all levels, normal aortic diameter is approximately 2 mm larger in men than in women and increases with age and increased body surface area.<sup>24</sup>

Several arteries branch off of the abdominal aorta, distributing blood to various organs (Table 1). The aorta is critical to normal circulatory function.

### Pathophysiology/pathogenesis/classification

Aneurysms are typically classified according to their location, size, shape, and etiology. They are most likely to form at bifurcations, where the artery is subject to frequent bending with physical activity and is not well supported by muscle. In response to intraluminal pressure, the weakened vessel may balloon out on one side (saccular aneurysm) or may enlarge circumferentially in a spindle shape (fusiform aneurysm)<sup>11</sup> (Figure 2). The third type of aneurysm is a dissecting aneurysm, which occurs when a small tear of the inner arterial wall allows blood to form a pathway between layers of the arterial wall.

Saccular, fusiform, and dissecting aneurysms are known as “true aneurysms.” By definition, aneurysms represent a dilation of all layers of the arterial wall.<sup>28</sup> Some confusion exists in refer-

ence to the definition of a false aneurysm or *pseudoaneurysm*. Pseudoaneurysms have often been described as an aneurysm that does not involve all layers of the arterial wall.<sup>28</sup> False aneurysms (pseudoaneurysms) are not arterial aneurysms, as they do not contain any layers of the arterial wall. Pseudoaneurysms are contained hematomas that result from localized arterial trauma, such as that which occurs during angioplasty.

The shape of an aneurysm is commonly described as saccular versus fusiform. In general, saccular aneurysms are believed to have a higher risk of associated rupture.<sup>32</sup>

Aneurysm size is described by diameter and length, with diameter being the critical risk factor for rupture. AAAs enlarge slowly over the years at an approximate rate of 0.2-0.5 cm per year.<sup>15</sup>

Evidence suggests that AAAs are not caused by atherosclerotic disease, but an aorta with atherosclerosis may be more prone to aneurysm. An early hypothesis that hypertension causes AAAs has not been adequately proven.<sup>14</sup> Smoking and advanced age are the risk factors most strongly associated with AAA.<sup>15</sup>

Lifestyle factors commonly believed to increase the risk of AAA development are the same as those believed to increase the risks of other forms of arterial disease, such as peripheral vascular disease and coronary artery disease. Risk factors for AAA include the following: smoking, diabetes, high cholesterol, family history of AAA, gender

(higher incidence in men), and age (men over the age of 55, women over the age of 70). Other risk factors include uncontrolled hypertension and high blood cholesterol levels.<sup>9</sup>

A genetic tendency has been shown to be associated with the development of AAA.<sup>29</sup> Screening recommendations are currently being reviewed to facilitate diagnosis of asymptomatic AAA, so that elective repair can be undertaken prior to rupture.<sup>33</sup> Other inheritable causes of AAA are connective tissue disorders, such as Marfan's syndrome and the Ehlers-Danlos syndrome.

### **Epidemiology**

AAAs are generally perceived to be a disease of elderly white males. AAAs increase steadily in frequency after 50 years of age, are five times more common in men than in women, and are 3.5 times more common in white rather than African American men.<sup>13</sup> The reported incidence of AAA varies from three to 117 per 100,000 persons.<sup>33</sup> In men, AAAs reach a peak incidence near 80 years of age. In women, AAA onset is delayed until an estimated 60 years of age, with a continuing rise in incidence.<sup>33</sup>

### **Clinical manifestations**

AAAs are usually asymptomatic and may be discovered on routine physical examination. Some AAAs are detected when the patient undergoes diagnostic testing for other conditions, such as an ultrasound examination for urological problems.

Symptoms of AAA are often vague and non-specific but usually center around back pain and abdominal pain. The intact aneurysm is asymptomatic until it becomes large enough to be detected as a pulsating mass creating pressure on surrounding organs.<sup>11</sup> The severity of symptoms will intensify as the aneurysm increases in diameter. Intravenous pyelogram, CT scan, abdominal X-ray, and ultrasonography are several diagnostic procedures that will detect the enlarged arterial wall and identify the location and size of the AAA.<sup>18</sup>

Severe back pain, shock, distal vascular insufficiency and symptoms of hypotension usually indicate rupture and represent a true surgi-

cal emergency. Pain is usually the most consistent finding in an impending rupture, and the patient may describe pain in the abdomen, back, flank, or pain radiating to the chest, groin, or legs.<sup>20</sup> Hypotension may be absent when a leaking or ruptured aneurysm has been contained in the retroperitoneum.

Less common symptoms present when the aorta ruptures into the duodenum (GI bleeding) or inferior vena cava (lower extremity edema, and congestive heart failure). AAA symptoms may mimic more common disorders such as renal colic, disk disease, myocardial infarction, and other acute abdominal conditions.<sup>20</sup> When an aortic rupture is suspected or actually occurs, the primary consideration of the surgical team should always be hemorrhage control.

### **Diagnosis**

Medical management is indicated for the AAA that is less than 4 cm in diameter. Medical management of AAA would include periodic size measurements of the aneurysm, encouraging smoking cessation and, if present, the aggressive control of hypertension. "Despite initial promising results from retrospective analyses, beta blockers have not been shown to slow the rate of growth of AAA in subsequent randomized trials, but doxycycline seems more promising."<sup>37</sup>

If medical management is unsuccessful in controlling the diameter of the aneurysm and it increases in size, surgical repair is recommended at 5 cm or greater.<sup>30</sup>

Ultrasonography is utilized to confirm the presence of the AAA and to track aneurysm enlargement without exposing the patient to radiation. Computed tomography (CT) may be used to screen patients and to also detect factors that may contribute to the planning of the AAA surgery. CT scanning can provide accurate size determination and also information regarding the proximal and distal extent of disease. Spiral CT scanning is a more rapid method of CT scanning that provides excellent resolution, three-dimensional reconstruction, and user-friendly images, all of which facilitate more accurate measurement for graft sizing.<sup>28</sup>

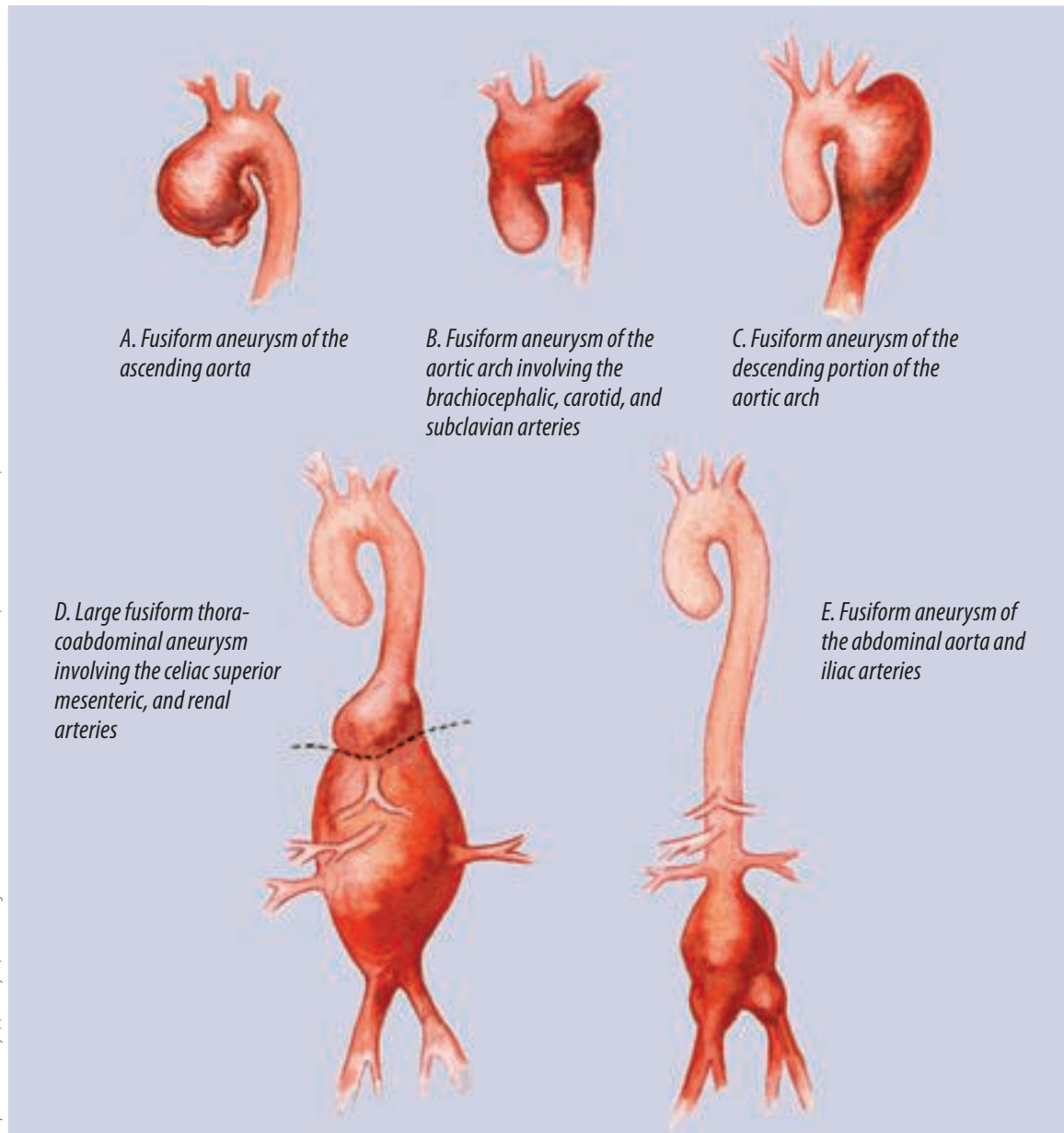
Magnetic resonance imaging (MRI) is comparable in accuracy to CT scanning without radiation exposure. MRI provides valuable information in reference to renal and mesenteric involvement. Arteriography may also be used as a method of diagnosis and is beneficial in evaluating any obstruction of the iliac and femoral arteries.

### Preoperative preparation

Hemodynamic monitoring is imperative in the accurate assessment of the patient's circulatory status. Monitoring devices may include central

venous pressure monitoring as a guide for fluid replacement, an arterial line for blood pressure management and arterial blood gas analysis, and a Swan-Ganz pulmonary artery catheter to assess pulmonary artery pressures, cardiac output, and left ventricular function. Oxygenation of the patient's arterial blood is monitored by pulse oximetry.

Typed and cross-matched blood should be readily available prior to the start of an elective AAA repair. Autotransfusion (Cell Saver®) can be used intraoperatively to allow autologous trans-



**FIGURE 2:**

Most frequent sites of aneurysms of the aorta and major arteries.

fusion and is essential if massive hemorrhage is encountered, such as with a ruptured AAA.

The hyper-hypothermia unit should be utilized to maintain the patient's core body temperature during the surgical intervention. A Foley catheter is inserted preoperatively to monitor urinary output and renal function.

An audible Doppler device is routinely used to assess blood flow through a vessel, especially when the pulse cannot be palpated manually. Blood flow in the extremities should be checked for embolic or occlusive problems preoperatively and postoperatively.<sup>8</sup> The exact location of the pedal and dorsalis pedis pulses may be identified and marked with a surgical marking pen to facilitate an intraoperative pulse check upon the surgeon's request.

### **Patient preparation**

The patient is placed in the supine position for the transperitoneal approach with both arms extended and secured on arm boards. The skin is prepped from the axilla to the knees and bilaterally as far as possible to accommodate a midline abdominal incision.

An alternative method of surgical skin preparation may require that both of the patient's legs be prepped circumferentially to allow for the possibility of lower extremity arterial exploration and bypass. This alternative method of the surgical skin preparation may be utilized for patients at high risk for distal embolization.

The surgical draping routine is performed according to institutional policy and surgeon preference. The surgical drapes must be positioned to allow access to the patient's groin region for possible exploration of the femoral arteries.

### **Surgical Intervention<sup>2,20</sup>**

1. A midline abdominal incision is made from the xiphoid process to the symphysis pubis. Hemostasis is achieved and the abdominopelvic cavity is explored to confirm the extent of the aneurysm. The cavity is also explored to assess the condition of the organs and to detect any other pathology.
2. The transverse colon and omentum are reflected superiorly. The small intestine and

ascending colon are delivered outside of the abdomen to prevent injury and to increase exposure. Warm, moist laparotomy sponges may be used to cover and protect these structures during the surgical intervention. A Lahey (bowel) bag may also be utilized.

3. An abdominal self-retaining retractor is inserted to retract the intestines and to provide exposure for the surgical team. Moist laparotomy sponges should be used to protect the wound edges from the retractor components such as malleable and right-angle blades.
4. The retroperitoneal space is opened by an incision through the posterior parietal peritoneum, beginning at the Ligament of Treitz and carried inferiorly over the bifurcation and beyond the origin of the iliac arteries. Long Metzenbaum scissors and DeBakey forceps are commonly requested.
5. The inferior mesenteric artery is isolated and secured with a vessel loop.
6. The internal and external iliac arteries are exposed to allow vascular clamp placement. If the common iliac artery is aneurysmal, then only the external iliac arteries are mobilized. Atraumatic vascular clamps are used to occlude the iliac artery.
7. The aorta is exposed above the aneurysm utilizing blunt and sharp dissection. The aorta is mobilized up to the level of the renal arteries and exposed to permit the placement of a large right-angle vascular clamp. The ureters are identified and avoided.
8. A knitted Dacron® vascular graft is selected after sizing, and blood is drawn from the vena cava to preclot the graft. Preclotting is not necessary if the surgeon selects a woven polyester or PTFE graft.
9. The patient is given systemic heparin (the optimal dose being 70-100 U/kg of body weight for immediate effect) and the drug is permitted to circulate for three minutes prior to clamping.
10. Vascular clamps are applied to the internal and external iliac arteries bilaterally (or to the common iliac arteries).

11. An aortic clamp, such as a Fogarty, Satinsky, or DeBakey, is applied to the aorta, above the aneurysm.
12. The aneurysm is opened longitudinally along the anterolateral wall by utilizing a scalpel or electro-surgical blade and heavy scissors. Thrombotic and atheromatous material is removed from the interior of the aorta and lumbar vessels are oversewn. The medial sacral and inferior mesenteric arteries may be sutured at this time if not ligated previously.
13. A T-shaped extension is cut into the proximal border of the aneurysm, and the anterior aneurysm wall is opened and irrigated with copious amounts of heparinized saline to flush small thrombus fragments from the wall of the aorta.
14. A prosthetic vascular graft is prepared for insertion. Graft size can be determined by direct measurement or by visual estimate. If the aneurysm does not involve the aortic bifurcation, a straight (tubular) graft is used. In most cases, a bifurcated (Y-shaped) graft will be utilized.
15. The aortic graft is irrigated with heparinized saline solution, and all fibrotic plaque is removed in preparation for anastomosis. Double-armed vascular suture is placed through the aortic cuff and the graft to create the proximal anastomosis.
16. It is imperative to communicate with the anesthesiologist prior to the release of the proximal vascular clamp. A large Fogarty clamp is placed on the proximal portion of the graft, and the proximal aortic clamp is released to test the anastomosis. The two ends of the double-armed vascular suture are tied together, and the proximal anastomosis is completed. Additional vascular sutures may be required if any leaks are observed at the anastomosis. Pledged suture may also be utilized to contain leaks at the anastomosis.
17. The distal portion of the aorta is inspected for back bleeding. The right limb of the vascular graft may be flushed with heparinized saline and brought down to the common iliac bifurcation. The right limb of the graft is cut to the correct length.
18. An arteriotomy is performed on the right common iliac vessel, and the graft limb is anastomosed in an end-to-side fashion, using double-armed vascular suture.
19. Prior to completion of the iliac anastomosis, the distal and proximal clamps are opened for flushing. The ends of the suture are tied and circulation is restored.
20. The same process is repeated for the left limb of the vascular graft, and the anastomosis is completed.
21. The anterior wall of the aneurysm sac is sutured over the proximal aortic graft.
22. The abdominal wound is closed in layers, and dressings are applied according to surgeon preference.
23. The surgical instruments and supplies should remain sterile until the patient has been transported to the PACU or SICU.

### Potential complications

Unfortunately, a number of complications can occur following AAA repair. Risks associated with AAA repair include injury to the ureters, myocardial infarction, spinal cord ischemia, renal failure, massive hemorrhage, and death.

Mortality ranges from 0%-3% for patients with elective repair to uncomplicated aneurysms to more than 80% for patients with rupture, hypotension, and oliguria.<sup>27</sup> Many patients requiring aortic surgery also have coronary artery disease and are at a greater risk of perioperative myocardial infarction.<sup>10</sup>

Perioperative bleeding can occur due to an uncontrolled vessel, a leaking anastomosis or a coagulopathy. Postoperative hemorrhage can occur in any patient, and hemodynamic instability and evidence of continued blood loss should indicate early abdominal re-exploration.

Acute ischemia of the lower limbs is an additional potential complication following AAA repair. This occurs when emboli or atheromatous debris pass down the arteries in the leg from the site of the AAA repair. Occlusion of the larger iliac and femoral arteries can be treated by embolectomy. If the tiny blood capillaries are affected, this leads to reduced tissue perfusion and may

necessitate amputation. Other less common complications following AAA repair include bowel infarction, impotence, graft infection, spinal cord ischemia, and paralytic ileus.

### Summary

An aneurysm is a local dilation of a blood vessel that gradually enlarges and weakens the wall of the blood vessel. As this occurs, the risk of spontaneous rupture increases. The most common form of aneurysm, AAA, is usually asymptomatic and is often discovered during routine physical examination.

The goal of AAA repair is the resection and replacement of the diseased portion of the abdominal aorta with a prosthetic vascular graft. Insertion of the prosthetic vascular graft relieves symptoms, prevents rupture, and restores arterial continuity.

### About the author

Tracey A Ross, CST, MEA, is currently the surgical services staff educator at Lancaster General Hospital in Lancaster, PA. She has worked both as a CST and a surgical technology educator. Ross has served on the Core Curriculum Revision Committee and is a current member of the AST Education and Professional Standards Committee. In this capacity, she is helping research and author a comprehensive set of surgical technology standards, and is part of the team working on the third edition of *Surgical Technology for the Surgical Technologist: A Positive Care Approach*.

### References

1. Brewster DC. Presidential Address: What Would You Do if it Were Your Father? Reflections on Endovascular Abdominal Aortic Aneurysm Repair. *Journal of Vascular Surgery*. 2002; 33: 1139-1147.
2. Caruthers B, et al, eds. *Surgical Technology for the Surgical Technologist: A Positive Care Approach*. Clifton Park, NY: Delmar Thompson Learning; 2001.
3. Cohen JR, Graver LM. The Ruptured Abdominal Aortic Aneurysm of Albert Einstein. *Surgery Gynecology & Obstetrics*. 1990; 170:455.
4. DuBost C, Allary M, Deconomos N. Resection of an aneurysm of the Abdominal Aorta: Reestablishment of the Continuity by a Preserved Human Arterial Graft With Result After Five Months. *Archives of Surgery*. 1952; 64:405.
5. Dirckx JH, ed. *Stedman's Concise Medical Dictionary for the Health Professions*. 4th ed. Philadelphia, PA: Lippincott, Williams & Wilkins; 2001.
6. Ernst CB. Abdominal Aortic Aneurysm. *New England Journal of Medicine*. 1993; 328 (16), 1167-1172.
7. Fellows E. Abdominal Aortic Aneurysms: Warning Flags to Watch For. *American Journal of Nursing*. 1995; 95(5) 26-33.
8. Fortunato N. *Berry and Kohn's Operating Room Technique*. 10th ed. St. Louis, MO: Mosby, 2000.
9. Franks, et al. Risk Factors for Abdominal Aortic Aneurysms in Smokers. *European Journal of Vascular and Endosurgery*. 1996; 11(4) 487-492.
10. Galland RB. Problems Associated with Aortic Surgery. *Care of the Critically Ill*. 1998; 14(2): 51-55.
11. Hansen M. *Pathophysiology: Foundations of Disease and Clinical Intervention*. Philadelphia, PA: WB Saunders; 1998.
12. Hollier LH, Wisselink W. Abdominal Aortic Aneurysm. In: H Haimovici ed. *Vascular Surgery: Principles and Techniques* (pp.797-827). Cambridge, MA: Blackwell Science; 1996.



13. LaMorte WW, Scott TE et al. Racial Differences in the Incidence of Femoral Bypass and Abdominal Aortic Aneurysmectomy in Massachusetts: Relationship to Cardiovascular Risk Factors. *Journal of Vascular Surgery*. 1995; 21:422.
14. Lederle FA, Johnson GR, Wilson SE et al. Prevalence and Associations of Abdominal Aortic Aneurysms Detected Through Screening. *Annals of Internal Medicine*. 1997; 126: 441-449.
15. Lederle FA, Simel DL. Does this Patient Have Abdominal Aortic Aneurysm? *JAMA*. 1999; 281: 77-82.
16. Lederle FA, Wilson SE. Preventing Rupture of Abdominal Aortic Aneurysms. *Patient Care*. January 15, 2002.
17. Leonardo R. *History of Surgery*. New York, NY: Froben Press; 1943.
18. Lewis SM, Heitkemper MM, Dirksen SR. *Medical-Surgical Nursing: Assessment and Management of Clinical Problems*. St Louis, MO: Mosby; 2000.
19. Matas R. Ligation of the Abdominal Aorta: Report of the Ultimate Result, One Year, Five Months and Nine Days After the Ligation of the Abdominal Aorta for Aneurysm of the Bifurcation. *Annals of Surgery*. 1925; 81:457.
20. MacVittie BA. *Mosby's Perioperative Nursing Series: Vascular Series*. St Louis, MO: Mosby; 1998.
21. Moore W. *Vascular Surgery: A Comprehensive Review*. Philadelphia, PA; WB Saunders, 2002.
22. Osler W. Aneurysm of the Abdominal Aorta. *Lancet*. 1905; 2: 1089.
23. Osler W. Remarks on Arterio-Venous Aneurysm. *Lancet*. 1915; 2:949.
24. Pearce WH, Slaughter MS, LeMaire S et al. Aortic Diameter as a Function of Age, Gender, and Body Surface Area. *Surgery*. 1993; 114:691.
25. Power DA. The Palliative Treatment of Aneurysms by "Wiring" with Colt's Apparatus. *British Journal of Surgery*. 1987; 1:29.
26. Rea CE. The Surgical Treatment of Aneurysm of the Abdominal Aorta. *Minnesota Medicine*. 1948; 31:153.
27. Rothrock J. *Alexander's Care of the Patient in Surgery*. 12th ed. St Louis, MO: Mosby; 2003.
28. Rutherford RB. *Vascular Surgery*. 5th ed. Philadelphia, PA; WB Saunders; 2000.
29. Salo JA, et al. Familial Occurrences of Abdominal Aortic Aneurysm. *Annals of Internal Medicine*. 1999; 130(8) 637-642.
30. Thelan LA, Urden LD, Lough ME, et al. *Critical Care Nursing: Diagnosis and Management*. St Louis, MO: Mosby; 1998.
31. Titora GJ, Grabowski SR, et al. *Principles of Anatomy and Physiology*. 10th ed. Indianapolis, IN: John Wiley & Sons; 2002.
32. Vorp DA, Raghavan ML, Webster MW. Mechanical Wall Stress in Abdominal Aortic Aneurysm: Influence of Diameter and Asymmetry. *Journal of Vascular Surgery*. 1998; 27:632.
33. Wilmlink ABM, Hubbard CS, Quick CRG. The Influence of Screening for Asymptomatic Abdominal Aortic Aneurysms in Men Over the Age of 50 on the Incidence of Ruptured Abdominal Aortic Aneurysms in the Huntington District. *British Journal of Surgery*. 1997; 84 (Suppl 1):11.
34. Wilmlink TB, et al. The Influence of Screening on Incidence of Ruptured Abdominal Aortic Aneurysm. *Journal of Vascular Surgery*. 1999; 30(2) 203-208.
35. Price P, et al, eds. *Surgical Technology for the Surgical Technologist: A Positive Care Approach*, 2nd ed. Clifton Park, NY: Thompson Delmar Learning; 2004.
36. Phillips NF. *Berry and Kohn's Operating Room Technique*, 10th ed. St Louis, MO: Mosby; 2004.
37. Rutherford RB, ed. *Vascular Surgery*, 6th ed. Vol II. Philadelphia, PA: Elsevier/Saunders; 2005: 1424.