



Photo courtesy of the US Navy

Mass Casualty on Deck

After a Routine Fighter Jet Landing Goes Awry, a Sailor is Rushed to the Ship's OR for an Emergency Amputation

V/R HM1 (SW/AW) Daniela M Dietsch, CST

One hundred miles off shore, during a night recovery training session, a fighter jet was approaching the aircraft carrier USS Kitty Hawk. The aircrew stationed in the tower observed the incoming aircraft while the landing signal officer stood by on a platform to help guide the jet on to the deck. The crew determined that the in-bound aircraft was an F/A-18 Super Hornet Jet. This information was immediately forwarded to the arresting-gear officer. The sailors below deck, in the engine room, were notified to activate the mechanism controlling the arresting gear. For a Super Hornet Jet, the four thick, strong wires are required to safely stop the aircraft. But, on that day, something went wrong.

As the Super Hornet's tail hook snagged the wire and landed, the wire continued to stretch and tore, whipping back and wrapping itself around a helicopter. The tip of the wire continued across the deck and struck six sailors working nearby. The aircraft was lost to sea, and one sailor's leg was wounded so gravely that it would have to be amputated. "Mass casualty on deck" was announced over the intercom and the entire crew responded to their stations. Hospital corpsman reported to the scene and immediately transported the patients to the medical department where the operating room was located.^{1,6,7}



LEARNING OBJECTIVES

- ▲ Learn how to prep skin for an above-the-knee amputation
- ▲ Identify what tools are necessary for this procedure
- ▲ Review the possible complications associated with any type of amputation
- ▲ Examine the surgical technologist's role in an above-the-knee amputation
- ▲ Define phantom pain and how it relates to limb removal

INITIAL CARE AND TRANSPORT

The medical response team was on the scene less than a minute after the alarm was sounded. The hospital corpsman who assisted the sailor with the leg injury immediately applied gauze to reduce the bleeding, as the rest of the team attended to other casualties. While the medical officer was radioed and informed of the possible surgery, stretcher-bearers ran across the flight deck to help the corpsman transport the patient to the medical department. The patient was strapped down to a rigid stretcher, stabilizing the leg and making sure not to cause further injury. The two sailors that took on the responsibility of stretcher-bearers safely maneuvered their way through passageways and down steep ladder wells to the medical department. Once they arrived, the patient was immediately transferred to a gurney and prepped for surgery. He was put on oxygen via a face mask, changed into a patient gown and had IVs started. The sailor was covered with warm sheets and blankets to maintain his temperature within normal levels.

PREOPERATIVE PATIENT CARE

The circulator transported the patient to the operating room and then assisted with transferring him to the operating table. The anesthesia provider was at the patients' head, monitoring the patient and maintaining the airway; the circulating nurse stood on the right side of the operating table to receive the patient; one of the surgical technologists was on the left side of the gurney to help lift the patient onto the table; and the surgeon was at the patients' feet, protecting the injured leg. A minimum of four people are required to transfer a patient to the operating table. Once anesthesia was induced, the patient was placed in the supine position with both arms extended (palms facing upward and the angle of the armboard less than 90 degrees) and secured on padded arm boards. The safety strap was placed over the unaffected extremity only (2 inches proximal to the knee), as to not impede surgery on the affected leg. The chart was checked for any patient sensitivities and allergies, which included food, latex and medications. The dispersive electrode for the



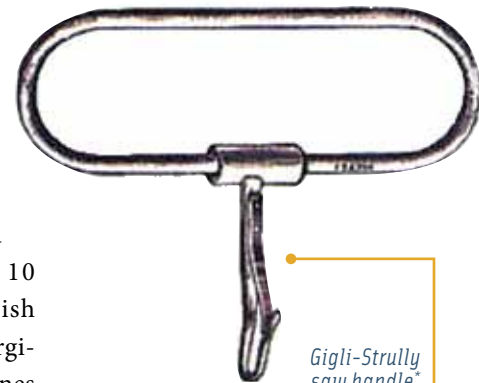Liston amputating knife*

electrosurgical unit was applied to the skin on the unaffected thigh; the pad should never be applied over bony prominences, joints, implants, tattoos or scars. Hair removal occurs if it interferes with the incision. In this case, hair needed to be shaved so there would be good contact with the skin. The technique for shaving depends on the thickness and density of hair on the leg. Some surgeons may request a circumferential shave prep. If this type of shave occurs, an assistant may be needed to elevate the leg.⁷ After the shave, the skin needs to be cleaned so there is good contact. The pad should be placed as close to the surgical site as possible.

INSTRUMENTATION, EQUIPMENT AND SUPPLIES

A basic orthopedic set was needed along with an electrically or pneumatically powered oscillating saw. Some ships may be equipped with nitrous oxide or battery operated power saws, but that is not standard. A Gigli saw or the Satterlee bone saw needs to be available in case the power saw fails. If power is used, the surgical technologist must test the instruments in advance to ensure proper function. All accessory items need to be available and checked for the correct fit. An orthopedic pack, basin set, extra #10 blades and an electrosurgical pencil need to be opened to start the case.³

A forced-air warming blanket is used to cover the parts of the body not involved in the surgery. Trauma patients' temperature needs to be stabilized to decrease the risk of hypothermia and the risk it can have on the heart and post-operative healing. A pneumatic tourniquet is applied to the affected limb to reduce blood loss during surgery. Inflation time of the tourniquet needs to be annotated and tracked. The surgical technologist or circulator should notify the surgeon once the tourniquet has been on for an hour. Inflation time should not exceed one and a half hours at 300-350 mmHg on a lower extremity. If the surgery takes longer, the site should be covered and the tourniquet deflated for approximately 10 minutes to re-establish blood flow. Electrosurgical and suction machines



Gigli-Strolli saw handle*

* From ASSOCIATION OF SURGICAL TECHNOLOGISTS. Surgical Technology for the Surgical Technologist, 3E. © 2008 Delmar Learning, a part of Cengage Learning, Inc.

also will be used during the case to coagulate vessels and maintain good visualization of the operative field during the procedure.

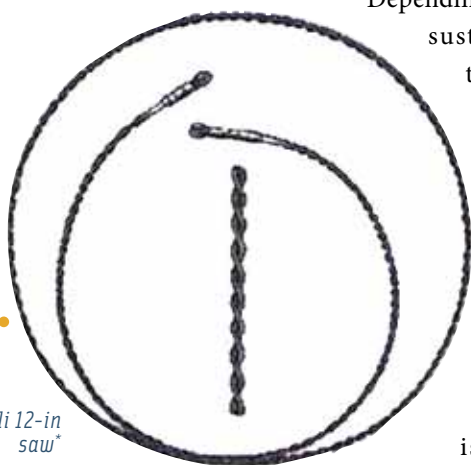
SKIN PREP AND DRAPING

For this specific procedure, the tourniquet is applied first around the thigh; stretchable cotton material will be needed to separate the skin from the tourniquet. Contaminants should be washed out of the wound with sterile water before starting the skin prep. The prep area may extend from mid-abdomen to the ipsilateral side and down to where the leg was injured; this area may change according to the surgeon's preference. While prepping the skin, a sponge used on the affected area should never be taken back over a clean area.² Prep should extend from the incision site to the toes, including the foot. A circumferential motion should be used when prepping the leg.² In order to prevent damaging the skin and a starting a fire, preparation solutions should not be left to pool under the tourniquet or patient. While draping, the extremity is carefully abducted and the foot and leg are covered with a stockinette. An impervious large sheet is draped over the end of the table, covering the unaffected leg. A split sheet is placed under the affected thigh and wrapped around to the top. A towel folded into thirds, lengthwise, is placed around the top of the stockinette and fastened with a towel clip. The U-drape is then draped proximally to the thigh. The leg is passed through a fenestrated extremity drape to complete the draping sequence. If available, an extra Mayo stand cover can be used to contain the amputated portion of the leg.

PROCEDURE

The patient will be in the supine position and a bump can be placed under the hip to control rotation of the limb.

Depending on the patient's sustained injuries, the limb may be exsanguinated using Esmark before inflating the tourniquet. As a safety measure, time out is called before



Gigli 12-in saw*

A basic orthopedic set was needed along with an electrically or pneumatically powered oscillating saw. Some ships may be equipped with nitrous oxide or battery operated power saws, but that is not standard. A Gigli saw or the Satterlee bone saw needs to be available in case the power saw fails.

the surgery begins and the entire surgical team confirms the patient and the procedure to be performed.

After the time out check list is completed, the surgeon uses a #10 knife blade to make a V-shaped incision in the anterior-posterior plane above the distal femur to get the greatest skin length possible. This flap will provide for easy coverage and tension-free closure of the stump. The surgical technologist should have lap sponges available to keep the site clear of fluids and decrease the risk of exposure.² To control bleeding, the electro-surgical pencil will be used to coagulate open vessels. Sharp and blunt dissection is carried down to the muscular layer. The posterior, lateral and anterior muscle compartments are identified and isolated to create musculocutaneous flaps for coverage of the femoral stump. The distal adductor canal is entered and the superficial femoral artery, vein and saphenous nerve are all ligated and divided separately. Tying vessels separately prevents arteriovenous fistulas or aneurysms from forming. The surgical technologist should have clamps and nonabsorbable ties available for the surgeon to doubly clamp, ligate and cut the identified vessels. Muscles are further transected circumferentially with a #10 blade. The sciatic nerve is held with a Schnidt clamp, cut and ligated with the electro-surgical



Satterlee bone saw*

pencil. The femoral periosteum is then elevated with either a #10 knife blade or a key elevator. To transect the bone the surgeon can use the Gigli saw, Satterlee bone saw, or, if available, a power saw.² Bone edges can be smoothed with a Putti-bone rasp. The wound is then irrigated with copious

A pneumatic tourniquet is applied to the affected limb to reduce blood loss during surgery. Inflation time of the tourniquet needs to be annotated and tracked.

amounts of normal saline with or without antibiotics. Once hemostasis has been established, wound closure can begin. A myoplasty, where antagonistic muscle and fascia groups are sutured together, is used to cover the distal end of the femur. A closed wound drainage system, such as the Hemo-vac, may be used to remove blood, fluids and air from the site. Utilizing a drainage system prevents edema as well as dead space within the surgical wound from forming.

COMPLICATIONS

There are physical risks with any amputation that include, but are not limited to, heart complications such as a heart attack or heart failure; infection at the site of the amputation; pneumonia; blood not being restored to the affected area; and phantom limb pain.⁷ Studies have shown that emergency amputations that result from a traumatic injury have fewer complications than planned amputations. This is because many planned amputations are the result of diabetes not being managed, so the patient may already be in poor health. Many emergency amputations occur in relatively healthy younger patients, who may have a better chance of recovering from the physical trauma of removing a limb.⁸

Psychological impacts after an amputation are also prevalent and should be taken into consideration. Many amputees say it is common to experience negative thoughts and emotions after the procedure. This may be especially true for those who had an emergency amputation, as they did not have time to mentally prepare themselves for the loss of a limb or body part. Other psychological effects can include depression, anxiety, denial, grief and suicidal feelings. Most of these issues can be helped with antidepressants or counseling.⁸

POST-OP

Amputation wounds are covered with bandages or plaster dressings and a tube may be placed under the skin to drain away excess fluids from the affected area. Bandages usually remain in place for a week post-op to reduce risk of infection. Painkillers are usually administered to help with pain as many amputees report considerable pain following the surgery. In the weeks following the surgery, amputees continue to meet with multiple health professionals to learn how to cope with the changes to their body. It is normal to be transferred from the surgical ward to another part of the hospital to assist in recovery. Amputees will meet with an occupational therapist to arrange a home visit to identify what aids the patient will need to make their home more accessible. Many amputees will meet with professionals to learn more about prosthetic limbs.⁸

Stump care is extremely important to make sure patients reduce their risk of infection. Stumps should be washed frequently with an antibacterial soap and dried completely and carefully. Some doctors will suggest using an unmedicated talcum powder to help reduce sweat around the stump. Patients caring for the stump need to regularly check for signs of infection including warm, red and tender skin; discharge or fluid or pus; and swelling of the skin.⁸

In this specific case, a bulky, soft dressing with a pressure wrap was applied to the stump. The soft-tissue dressings with compression wrap required an even distribution of pressure to avoid possible limb strangulation. Once the dressing was applied and the patient was extubated, the anesthesia provider and circulating nurse transferred the patient to a gurney. Since the security of the airway is the anesthesia provider's responsibility, he or she will indicate when the patient can be moved. Due to the limited staffing on the ship, the circulating nurse and a hospital corpsman recovered the patient and prepared him for the flight to a hospital. Once the patient's vital signs were stable and his pain was under control, a helicopter flew him to Naval Hospital in Yokosuka, Japan. A flight nurse and corpsman, who were specialized in respiratory therapy, accompanied the patient during the flight to monitor his vital signs and make the transfer as easy as possible. He spent a few days in the Intensive Care Unit in Yokosuka before he was transferred to the United States.⁶

ABOUT THE AUTHOR



HM1 (SW/AW) Daniela M Dietsch, USN, CST, joined the US Navy on October 3, 2001, graduated from bootcamp in December 2001 and then went to HM School. She graduated from Hospital Corpsman Basic at Naval Hospital

Corps School Great Lakes in April 2002. Daniela's first duty station was Naval Hospital Yokosuka, Japan, from May 2002 to July 2005. She graduated the Surgical Technology Program at the Naval School of Health Sciences (NSHS) in March 2006. She then was stationed at Naval Hospital Guantanamo Bay from April 2006 to October 2007, and transferred to United States Naval Ship (USNS) Mercy, TAH-19, homeport San Diego, California, where she was stationed from October 2007 to October 2010. Daniela has participated in two humanitarian missions, Pacific Partnership 2008 and 2010 while stationed on USNS Mercy. She is currently stationed at the Naval Medical Training Center, Medical Education and Training Campus, in Fort Sam Houston, Texas.

REFERENCES

1. Associated Press Worldstream. "Six US sailors injured during fighter jet training on USS Kitty Hawk." 2005.
2. Association of Surgical Technologists. Patient Skin Prep Charts for the Surgical Technologist. 2010;42-43.
3. Association of Surgical Technologists, Inc. Surgical Technology for the Surgical Technologist: A positive care approach Third Edition. 2008;869.
4. Ertl, J. Prosthetic Primer: Pain and the Inactive Residual Extremity Syndrome. 2000;10(5) <http://www.stumps.org/ertl.html>. Accessed September 2011.
5. Gittler, J. Investigators piece together what caused Kitty Hawk jet accident, Stars and Stripes. 2005. <http://www.stripes.com/news/investigators-piece-together-what-caused-kitty-hawk-jet-accident-1.31074>. Accessed September 2011.
6. Gittler, J. Pilots, sailors recount F/A-18's plunge into sea from flight deck of Kitty Hawk. Stars and Stripes. 2005. <http://www.stripes.com/news/pilots-sailors-recount-f-a-18-s-plunge-into-sea-from-flight-deck-of-kitty-hawk-1.31072>. Accessed September 2011.
7. Goldman, M A. Pocket Guide to the Operating Room, Third Edition. 2008; 636-637.
8. NHS. Amputation. November 2011. <http://www.nhs.uk/Conditions/Amputation/Pages/Introduction.aspx>. Accessed October 5, 2011.



MAY 23-27, 2012
HILTON WASHINGTON
WASHINGTON, DC

AST returns to the nation's capitol!

Register for the premier educational event of the year for surgical technologists and surgical assistants in this national treasure. AST has reserved a block of rooms at a very special conference rate, \$150 single or double occupancy; \$160 triple occupancy and \$170 quadruple occupancy. To take advantage of these special rates, reserve your room early. Reservations are now currently being accepted, and the deadline is April 15, 2012. Log into the AST or ASA website and click on the conference logo to register.

FULL CONFERENCE REGISTRATION (includes social events)

	Advance Postmarked by March 31	Onsite After March 31
AST Member Package	\$350	\$390
ASA Member Package	\$350	\$390
AST Nonmember ¹	\$480	\$520
ASA Nonmember ²	\$550	\$590
Student Member/Nonmember ¹	\$99/\$144	\$99/\$144
Active Military Member/Nonmember ¹	\$175/\$255	\$175/\$255
Guest ³	\$50/\$100	\$50/\$100

¹ Includes one year AST Membership

² Includes one year ASA membership and AST value-added membership

³ Guest registration is intended for family members or significant others. CSTs and other healthcare professionals must register for package options. Guests may choose to purchase a ticket to the Friday or Sunday social events for \$50 per ticket.

For more on preconference workshops, visit www.ast.org.

Unraveling Phantom Pain

ONCE THOUGHT AS A PSYCHOLOGICAL PROBLEM,
STUDIES HAVE SHOWN PAIN IS REAL

JODI B FARMER, AST EDITOR

Phantom Pain

This term is usually associated with people who have lost an extremity such as an arm or a leg and the pain comes from a body part that no longer remains.⁴ But it can also occur to other body parts including the breast, penis, eye or tongue after they are surgically removed. At one time it was thought that this post-amputation phenomenon was just a psychological problem. But now doctors believe that these are real sensations that originate in the spinal cord and brain. For some people, phantom pain improves over time. For others, it will always remain a challenge.



ing World War I and II as well as Vietnam where landmine explosions were common. Today, many amputees experi-

ence some kind of phantom sensation, whether the sensations are painful or not.

Characterizing the Pain

Most people who have had a body part removed, report that they feel that it is still there. The following include characteristics of phantom pain: onset within the first few days of amputation; tendency for the pain to come and go; seeming to come from the part of the limb farthest from the body; be described as shooting, stabbing, boring, squeezing, throbbing or burning; and may be triggered by weather changes, pressure on the remaining limb, emotional stress or stump irritation.² Also of note is that phantom pain may be relative to whether a person had a body part removed because of a traumatic injury or for a vascular condition, such as diabetes. One study showed that vascular amputees showed more pain between pre-amputation pain and phantom pain in the first two years after the amputation, whereas traumatic amputees' phantom pain only appeared directly after the amputation.³

Mixed signals of the brain may partially explain why amputees have the sense of phantom pain. Studies have shown that during imaging scans, specific portions of the brain show activity when the person feels phantom pain. After a limb or body part is removed, the spinal cord and brain lose input from the missing part and tries to adjust to this detachment. It results in tangled sensory wiring that sends signals to a remaining body part.

Other theories of what causes phantom pain includes decreased blood flow to a particular area, muscle spasms, damaged nerve endings, scar tissue left over from the amputation, illness, pressure on the stump or removed area and physical memory of pre-amputation pain.¹ The peripheral theory is based off the result of nerve endings forming around the stump that generate electrical impulses that the brain then interprets as pain. The central theory

History

Although the official term "phantom limb" wasn't coined until 1871, it is believe that the first description of the post-amputation sensation was used by a French military surgeon in the 1500s. This surgeon noticed that many of his amputee patients complained of pain in the missing limb following the surgery.³ During the decades to follow, more doctors, noted that their patients mentioned that they had pain in the place of the amputated limb. Traumatic amputations were seen dur-

states that the brain has “memory” of the amputated limb or removed body part. The symptoms of pain are recreated from memory, but fail because the brain does not receive the feedback it was expecting. The spinal theory is based off the lack of sensory input from the removed body part that then causes chemical changes in the central nervous system.

A series of mechanisms may be involved in generating phantom pains. It is suspected that “the unraveling of neuroplastic changes in periphery, spinal cord and brain are also reflected in many of the features seen in phantom pain phenomena.”³ Cerebral reorganization may play a large part in the sense of phantom pain. Magnetoencephalographic techniques have tracked cerebral reorganization as there has been a linear link between pain and

electroconvulsive therapy are various ways to alleviate stump pain. Electrical stimulation of the spinal cord, deep brain structures and motor cortex has shown to relieve phantom pain as well, although the effect may decrease over time.³

Mental imagery may offer the best non-medical solution. Relating to the central theory of phantom limb pain, mental exercises may prove to be effective to send the brain the feedback it is looking for. Studies have shown that if patients spent time imagining using their phantom limb, such as bunching up their toes, they experienced a reduction in pain.⁵

Surgical treatment for phantom pain has been attempted, although many times it is unsuccessful at fully reducing pain in the affected areas, and many times often reappears.

Surgical treatment for phantom pain has been attempted, although many times it is unsuccessful at fully reducing pain in the affected areas, and many times often reappears.

Benefit of Phantom Pain

Believe it or not, some experts feel that phantom pain should be viewed as an ally to the human body. Some say that phantom pain can be used to help detect other imbalances in one's health and well-being. By focusing on where

the degree of reorganization. Researchers also found a subcortical connection as techniques were used to define pain patterns and noticed that an unusually large thalamic stump representation.³

Treatment

Treatment for phantom pain is classified in three categories: medical, non-medical and surgical. Certain medications can help block pain or relieve nerve injury pain. Lidocaine has been shown to be effective in controlling neuropathic pain.³ A number of other oral medications are still being studied including carbamazepine. This drug was created to treat epilepsy and it is thought that it can help decrease stump pain as signals coming from nervous system activity are reduced.⁵

Non-medical treatments can be combined with non-invasive techniques to help reduce pain in affected areas. Transcutaneous electrical nerve stimulation (TENS), vibration therapy, acupuncture, hypnosis, biofeedback and

the phantom pain is located, a connection may be made to an imbalance with an internal organ such as a kidney or spleen. Some people also have found phantom pain useful when using a prosthetic limb as the pain alerts them to any issues with the limb.¹

References

1. Durham, J. Phantom Pain. 2004. <http://www.transitiontoparenthood.com/janelle/energy/PhantomPain.htm>. Accessed October 4, 2011.
2. Jacques, E. Spotlight on Phantom Pain – Why Phantom Limb Pain Occurs, and How to Treat It. 2009. http://pain.about.com/od/typesofchronicpain/a/phantom_pain.htm Accessed October 4, 2011.
3. Jensen, T S; Nikolajsen, L. Phantom Limb Pain. *Br J Anaesth*. 2001. 87(1): 107-116.
4. Phantom Pain. Mayo Clinic. 2009. <http://www.mayoclinic.com/health/phantom-pain/DS00444> Accessed October 4, 2011.
5. NHS. Amputation. November 2011. <http://www.nhs.uk/Conditions/Amputation/Pages/Introduction.aspx>. Accessed October 5, 2011.