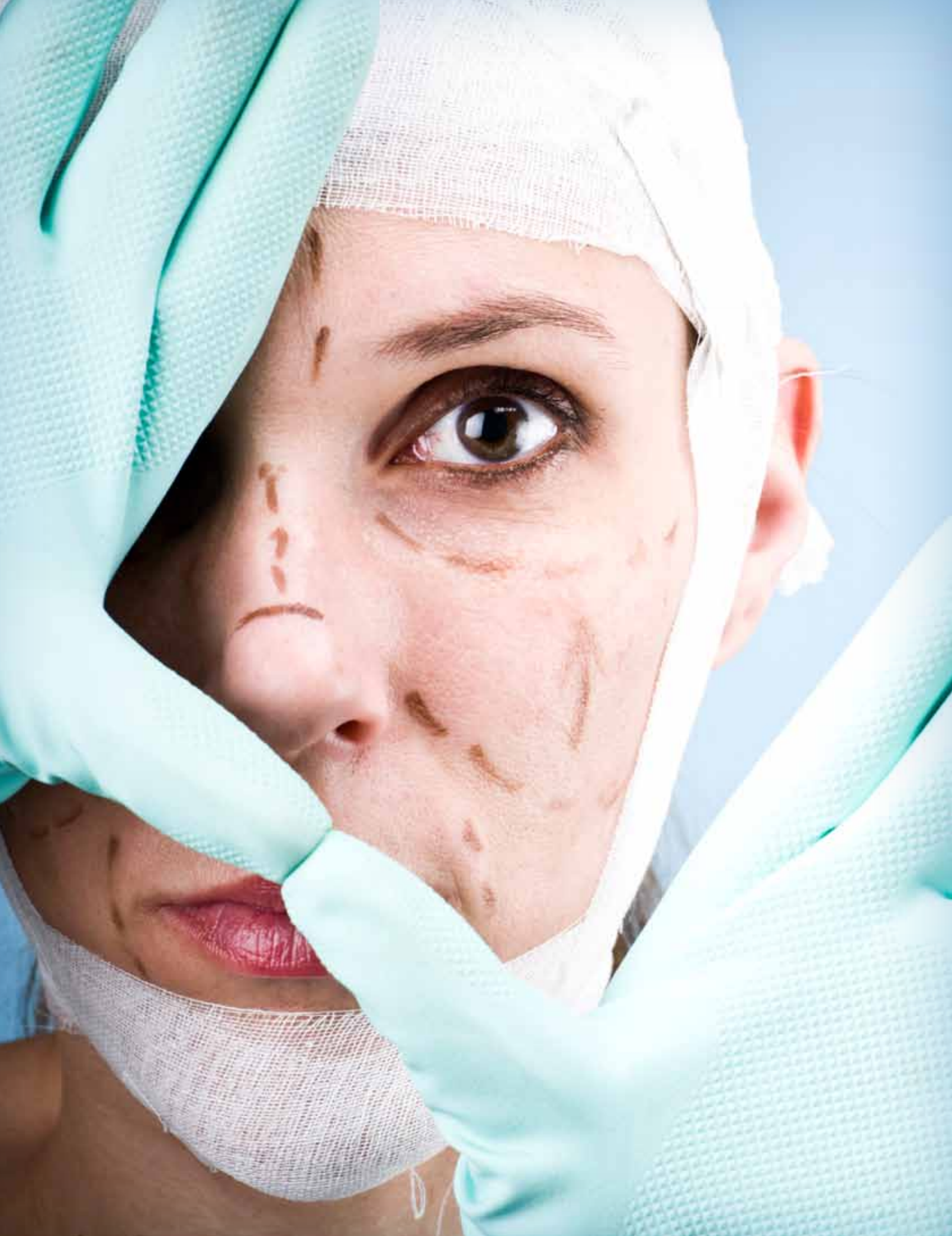



A Facial Rejuvenation

Short-scar face-lift/simple MACS: Minimal Access Cranial Suspension

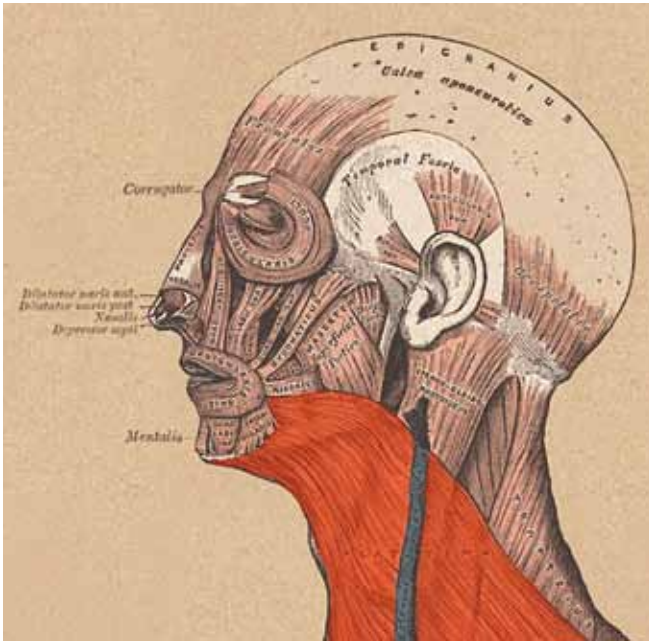
NYDIA I MORALES, CST

An increase in age demonstrates the process of nature. When it comes to the face – sagging skin, wrinkles, fat deposits and folds begin to evolve in the area of the neck, nose, jawline and mouth. Other contributing factors include general health issues: excessive weight gain, smoking and heredity. Rhytidectomy helps wrinkles disappear via plastic surgery, a procedure known as a face-lift.³

The traditional rhytidectomy encompasses the initial incision in the temporal region; in front of the ear and extending downward to follow the contour in a continuous dissection, then upward behind the ear and into the hairline and then onto the mandible bone. The short-scar face-lift/MACS — minimal access cranial suspension — eliminates the extensive dissection around the ear and into the hairline. The use of this technique minimizes the incision to the front of the ear only.³ This technique is relatively new. It was modified in 1999 from the traditional rhytidectomy. It reduces extensive dissection by using two strong permanent purse-string sutures that are woven into the SMAS tissues in a vertical U-shape and an oblique O-shape (extended MACS Lift) via a strong anchorage in the deep temporal fascia on the helical crus. The superficial musculoaponeurotic system is a gliding membrane that aids in reattachment when the three major facial muscles are tightened via an uplifting pull to the zygomatic arch. When the sutures are tied they produce a smooth vertical readjustment of the drooping facial features that rest on the jowls and upper neck.⁴

LEARNING OBJECTIVES

- ▲ Define the difference between a traditional rhytidectomy and a simple MACS procedure
- ▲ Identify what instrumentation is needed for this type of face-lift surgery
- ▲ Examine the role a surgical technologist plays in a short-scar face-lift
- ▲ Evaluate the alternatives to this operation
- ▲ Review the anatomy affected by this procedure



ANATOMY OF MAJOR MID AND UPPER FACIAL MUSCLES

The large muscle that is known as epicraniius, is divided into two parts: the occipitalis and the frontalis portions. The occipitalis section covers the occipital bone and connects to the frontalis. The occipitalis draws the scalp backward, whereas the frontalis draws the scalp forward. The orbicularis oculi covers a path around the eye. The buccinator, levator labii and the zygomaticus major also play critical roles in the anatomy of the face. On the lateral region of the face, the buccinator muscle lies between the maxilla and the mandible. It is a thin quadrilateral muscle and its function is to pull back the angle of the mouth and soften the cheek. The buccinator's muscle also holds

In general, the MACS lift is an anti-gravitational lifting procedure that suspends the soft tissues of the face and neck along with the skin jointly in a vertical pull and resets it to its original facial placement.

the cheek to the teeth when active in chewing, whistling and smiling. Infants also use it in sucking. The levator labii lifts the upper lip and the lateral rounded part of the nostril. It is attached to the frontal area of the maxilla.

It produces a snarl, a facial gesture made famous by Elvis Presley. The zygomatic major muscle controls the facial expression via the angular pull of the mouth as in a smile. The muscle extends from the zygomatic arch to the corners of the mouth joining with the orbicularis oris.⁷

SIMPLE MACS LIFT TECHNIQUE

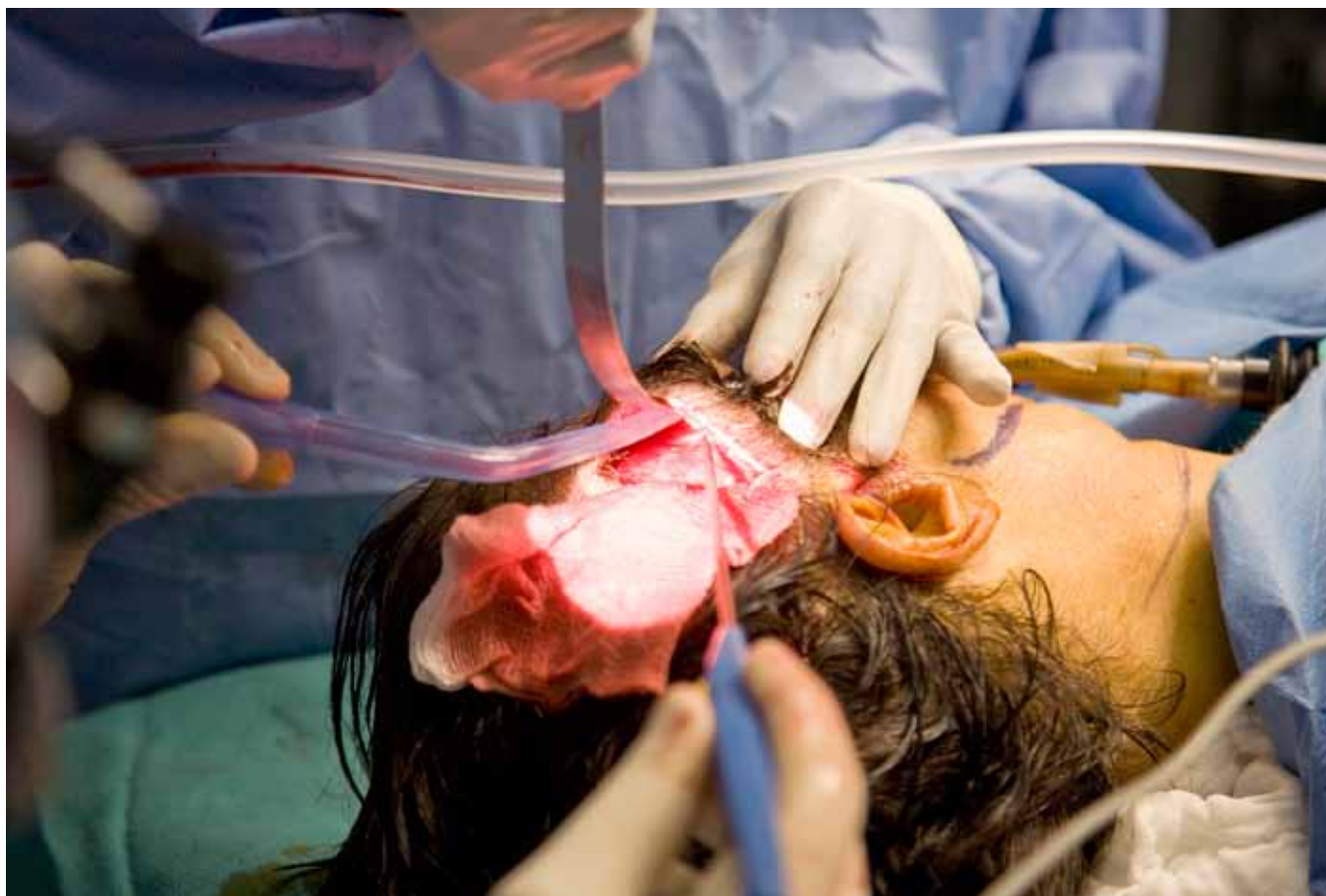For the purpose of simplicity, this article will feature the MACS lift technique. This technique is strictly for patients with early jowls, primary facial aging and marionette grooves. Patients with intensive facial ptosis require deep plane manipulation. Extended MACS lift targets the nasolabial grooves and lifts the malar fat pad on the midface. The incision is extended on the temporal hairline. In general, the MACS lift is an anti-gravitational lifting procedure that suspends the soft tissues of the face and neck along with the skin jointly in a vertical pull and resets it to its original facial placement. This enhanced process delivers a facial rejuvenation. There is no injury to the facial nerve branches, nor vascular compromise since they are deep to the SMAS facial muscle layer. The osseocutaneous ligaments support the skin and facial structures against the force of gravity. On the face-lift flap, they must be released to adhere to its stretch in movement.⁴

PREOPERATIVE PREPARATION

The patient is required to cease smoking and consuming alcohol for two weeks prior to the procedure. This helps ensure healing post operatively. In addition, aspirin should not be taken preoperatively as it can cause bleeding. The patient should wear loose comfortable clothing during and after the procedure to facilitate nonrestrictive circulation. Baggy clothing or a sweatsuit is encouraged. An ace bandage

will be wrapped around the head and chin after the procedure. Therefore, the patient should bring a scarf or hat to cover the head and neck, or a hooded sweatshirt. The surgeon will review the procedure with the patient, as well as take his or her complete medical history. Photos of the patient are

taken before and after to provide a comparison. The surgical technologist remains in the OR suite for the duration of the procedure to monitor the patient at all times. There



A face-lift operation is performed

is no circulating nurse or anesthesiologist present. Prior to the procedure, the surgical technologist witnesses that the consent form has been signed and counter signs it. He or she also reviews all medical entries at this time. Vital signs, including blood pressure and pulse oximeter readings, are recorded and close attention is given to any irregularities, such as cardiac dysrhythmia, that could indicate a potential medical risk.

The choice of anesthetic will vary depending on several factors, including the patient's overall health, medications the patient is currently taking and the number of procedures and length of time of each procedure. The patient and surgeon also may state a preference for anesthesia. A short-scar face-lift can be performed under general anesthesia, with IV sedation or local anesthesia. Most cases are done in-office and are performed under local anesthesia. The local anesthetic for this procedure is a tumescent solution: a combination of 400 ml of normal saline, 90 ml one percent of lidocaine without epinephrine, 10 ml 8.4 percent

bicarbonate and one ml of epinephrine 1:1000. Preoperative antibiotics also are administered to reduce the risk of bacterial infections. In some cases, a sedative is used. Five to 10 mg of diazepam is administered sublingually to treat anxiety in patients who request it. The sedative is used based on patient preference; however, the surgeon will dictate the dose to be administered.

The patient is placed in the supine position. The surgeon then outlines the planned incisions with a marking pen on the temporal region in front of the ear. The local anesthetic is administered by injection into zygomatic arch of the surrounding areas of the buccinator, levator labii and zygomaticus major muscles.¹ The surgical technologist places a surgical cap on the patient, sweeping all hair strands away from the incision site and secures it in a tight knot. The patient's temporal and zygomatic region is then cleaned with a scrub cleaner. The patient's thoracic region is draped in order to create and maintain the sterile field during the procedure.

**THE SURGICAL TECHNOLOGIST
PREPARES THE MAYO STAND
WITH THE FOLLOWING
INSTRUMENTATIONS:**

2 #15 knife blades and #3 knife handle
2 Senn retractors
2 Army Navy
2 Adson forceps with teeth
Mayo-Negar needle holder
Curved and straight Metzenbaum scissors
Mayo scissors
Small mosquito (placed to the side in case it is needed for hemostasis)
4x4 gauze sponges
2-0 polydioxanone sutures
2 5-0 nylon sutures
2 3-0 chromic gut

PROCEDURE

A 4x4 gauze sponge is cut into a short-end strip and rolled into a ball. Using Adson forceps, the ball is placed into the ear of the patient to prevent fluid from entering the ear canal from the incision site. The surgeon positions the patient's head to the side. An incision is made with a #15 blade along the hairline angle (or a zig-zag pattern is used to facilitate new hair growth) and continues downward to the auricle lobule. An Adson is used to pick up the initial skin. The dissection continues with Metzenbaum scissors. In an open and closed spreading motion it separates the subcutaneous fat layer, to create a flap. The skin over the tragus is elevated with 2 Senn retractors (one on each side of the flap ends) and an electro-surgical pencil is used to control bleeding. It protects facial nerves and maintains the correct plane. The dissection further continues superiorly until the lateral edge of the orbicularis oculi muscle is reached and the dissection continues onto the superior region of the platysma muscle. This is made visible with the surgeon's magnified glasses. The zygomatic arch is identified. With the use of the Metzenbaum scissors, the tissue is spread to the deep temporal fascia. The electro-surgical pencil is used as needed. A 2-0 polydioxanone suture is used as the suspen-

sion suture. An interrupted purse-string stitch encompasses the superficial musculoaponeurosis and jointly the buccinator, levator labii and zygomaticus major muscles. The suture is returned to the starting point (O-shaped) under exerted force and tension with an uplifting pull to the zygomatic arch and is tied with four square knots. A small amount of the parotid fascia in the cranial part and the platysma in the caudal part is captured in every stitch with the needle. This vector elevates the jowls and corrects marionette grooves and upper neck. It is anchored at the fascia of the platysma muscle, at the angle of the mandible.⁵ A customized skin excision from the flap is resected and sutured subcutaneous with polyglactin 910. The preauricular and hairline incision is sutured with minimal tension with 5-0 chromic gut. The skin flap by the earlobe is customized and cut as well, and set without tension to secure a normal setting. It is also sutured with a polyglactin 910.⁵ The identical procedure is repeated on the other side of the face.

POST-OPERATIVE CARE

An elastic wrap — snug from the chin to the head, but not tight and comfortable to wear all day — should be worn for five days following the operation, removing it only for a shower and meals. The incision should be gently cleaned with 50-50 combination of hydrogen peroxide and warm water for the first three days. An antibiotic cream can be applied on the incision line for as many as seven days. Drainage from the incision four to five hours after surgery is common and may occur as long as 24 hours after the operation. Should bleeding occur, a gauze bandage should be applied with pressure. If there is no remedy, call the doctor immediately.

For the first 24 hours, ice packs should be applied on face, cheeks and under the chin for 15 to 20 minute intervals. After two days, ice packs should be applied every three to four hours for 15 to 20 minutes each. The head needs to be elevated with at least two pillows during sleep to minimize swelling for three to four nights. The patient is required to take antibiotic medication for the completion of seven days in order to prevent infection. Patients should not take aspirin or ibuprofen as it may cause bleeding. Prescription pain medication can be prescribed or the patient can take extra strength acetaminophen as needed.

RISKS AND COMPLICATIONS

A family history of bleeding problems yields extensive pre-operative evaluation. Patients on anticoagulants (and vitamin E) must cease taking the medication, both pre- and post-operative. Smoking will compromise vascularity and healing. Taking multivitamins and vitamin C may be recommended to help healing. Swelling, bruising, pain and discomfort are normal after surgery. Scarring will occur and is made to minimize its appearance. Skin heals differently for every patient and it may be noticeable, large, raised, hypertrophic or a keloid can evolve, and it may require more treatment. Other complications may include hematoma and infection.

Tissue and/or skin loss is possible during healing. Additional surgery of skin grafts or wound debridements may be needed. Facial asymmetry of the neck, lip and nose may be temporary or permanent. Also, additional surgery may be needed as a touch-up procedure to correct problems.³ Follow-up visits are scheduled for one week post-surgery, two weeks post-surgery and four weeks post-surgery. Photographs are then taken to compare the before and after images at four weeks progress. A follow-up visit is scheduled six months afterward the operation.

ALTERNATIVES

Skin resurfacing (chemical peel, dermabrasion or laser resurfacing), fillers or botulinum toxin injections, as well as liposuction and blepharoplasty are all possible alternatives to a face-lift. All of these procedures or alternatives can produce a youthful appearance and target a specific area of the face.

ABOUT THE AUTHOR



Nydia I Morales, CST, was an elementary school teacher before entering the medical field. She graduated from New York University Langone Medical Center's surgical technology program in New York

City and passed the National Board Certification exam in September 2007. She has written two other plastic surgery articles for *The Surgical Technologist*: "Autologous Fat Grafting," November 2009, and "Platysmaplasty: A Resolve for the Turkey Neck," July 2010.

THE HISTORY OF THE RHYTIDECTOMY IN THE 20TH CENTURY:

- 1916** – Lexer: Consisted of limited skin excision and elevation.
- 1968** – Skoog: Sub platysmal dissection in the neck, rising simultaneously the skin and platysma muscle.
- 1976** – Mitz and Peyronie: SMAS (superficial musculoaponeurotic system) in rhytidectomy techniques.
- 1979** – Tessier: Vertical lift to the soft tissue (remodeling and repositioning). Tessier, Santana and Psilakis extended subperiosteal dissection of mid face, jawline and neck.
- 1990** – Hamra: Deep-plane rhytidectomy to reposition malar fat pad.
- 1992** – Hamra: Additional modification to include oricularis oculi muscle into the flap.⁶
- 1999** – Saylan: S-lift The suspension of sagging facial feature via a strong purse-string suture.
- 1999** – Tonnard, Verpaele, Monstrey, Landuyt, Blondeel, Hamdi and Matton, MD: MACS, adopted S-lift and modified incision, purse-string anchorage site and direction and shape of the skin excision.⁴

REFERENCES

1. Jafri KS, MD. Facial Plastic and Reconstructive Surgery/Craniofacial-Skull Base Surgery. www.custom-lift.com
2. Lickstein DL, MD. FACS Cosmetics & Reconstructive Surgery. www.healthline.com
3. Tabers Cyclopedic Medical Dictionary, p1913.
4. Tonnard P, MD. Minimal Access Cranial Suspension Lift: A Modified S-Lift. *Plastic Reconstr Surg J.* 2002; 109(6): 2074-86.
5. Tonnard P, MD. Short-Scar Face-Lift, Operative Strategies and Techniques. Quality Medical Publishing, Inc. 2007. p82-90.
6. Whitaker E, MD. Emedicine, Facelift: Rhytidectomy, Composite. November 2009. <http://freetechbooks.com/ebook-2011/emedicine-page6.html>.
7. Rhytidectomy. <http://en.wikipedia.org/wiki/Rhytidectomy>

INTEGUMENTARY SYSTEM REVIEW

Teri Junge, CST, CSFA, FAST, MA

Please note: This article is intended as a brief overview of the integumentary system and serves as an introduction for surgical technology students, a review for practicing surgical technologists, and an exam preparation tool for individuals planning to take the national certification exam. It is not a comprehensive review.

The term integument means covering. The integumentary system consists of the skin and its appendages. The skin is considered a membrane because it is a thin layer of tissue that covers the entire body. The skin is the largest organ of the human body containing three of the four main types of tissue (epithelial, connective and nervous).

What are the names of the two main layers of the skin?

The epidermis is the outer layer of the skin and consists of five sub-layers or “strata.” The epidermis does not contain any blood vessels and contains only epithelial cells. The epidermis is constantly reproducing and shedding. It takes approximately five weeks for a new skin cell to make it way to the surface to be sloughed. The five sub-layers of the epidermis from outer to inner are:

- ▲ Stratum corneum which is the leathery outer layer that is made up of dead skin. The stratum corneum consists of approximately 20 layers of cells in various stages of disintegration. As the cell dries and becomes scaly, the keratin remains. The cells of the stratum corneum are pressed tightly together; as they reach the body surface they are shed or sloughed.
- ▲ Stratum lucidum, which is clear, consists of flat transparent cells. The stratum lucidum is especially prominent in thick skin areas such as the palms of the hands and soles of the feet.
- ▲ Stratum granulosum that contains granular shaped cells which are active in keratinization (the process of becoming hard and spiny). Keratin is a hard, fibrous, waterproof protein that is found in the hair, nails and epidermis. As the spiny cells from the layer below move toward the outer surface of the body, they begin to flatten and take on a granular shape.
- ▲ Stratum spinosum that is made up of polyhedron-shaped cells (spiny/prickly in appearance) containing desmosomes which are a specialized type of epithelial

cell that anchors cells to one another. The stratum spinosum receives the daughter cells produced by mitosis in the stratum basale.

- ▲ Stratum germinativum, which is also known as the stratum basale, is the most important layer because it is the reproductive layer (cells divide by mitosis). The stratum germinativum derives its nourishment by diffusion from the capillaries of the dermis and contains melanin which is the pigment responsible for skin and hair color.

The dermis, also called “the true skin” is the innermost layer of the skin and consists of two main divisions. Blood vessels and nerves are found in the dermis. The two main divisions of the dermis are the:

- ▲ Papillary layer (named for its papilla or projections), which are the groundwork for fingerprints. This layer is directly beneath the epidermis.
- ▲ Reticular layer, which is the thick, deep layer that provides collagen for strength and elastin for pliability of the skin. This layer is directly above the subcutaneous layer.

1 SQUARE CENTIMETER OF SKIN CONTAINS:

- ▲ 15 sebaceous glands
- ▲ 1 yard of blood vessels
- ▲ 700 sweat glands
- ▲ 3,000 sensory cells at the end of nerve fibers
- ▲ 4 yards of nerves
- ▲ 25 pressure apparatus for the perception of tactile stimuli
- ▲ 200 nerve endings to record pain
- ▲ 2 sensory apparatuses for cold
- ▲ 12 sensory apparatuses for heat
- ▲ 3,000,000 cells
- ▲ 10 hairs

How would you describe the subcutaneous tissue?

The subcutaneous layer contains loose (soft) connective tissue, particularly adipose tissue, as well as blood vessels and nerves. This layer is also called the superficial fascia and provides insulation, protection to the structures beneath and anchors the skin to the underlying tissue.

What are the names, locations and functions of the accessory structures of the skin?

The accessory structures of the skin may also be referred to as the appendages. The appendages include the sudoriferous and sebaceous glands as well as the hair and nails. Most of the accessory structures are located in the dermis and some may extend into the subcutaneous layer.

The sudoriferous glands are also known as the sweat glands. Sweat glands are found in most regions of the body with the exception of the nipples, lips and portions of the external genitalia. There are two types of sudoriferous glands. The first type is called the eccrine glands (sometimes called merocrine glands), which are found throughout the body and are activated by heat or emotional stress. Eccrine glands secrete primarily water and some salts. The second type is called the apocrine glands which are found only in the axillae, areola of the breast and the groin. Apocrine glands become active during puberty and are activated by pain, after sexual arousal and emotional stress. Apocrine glands secrete water, salts and organic compounds such as fatty acids and proteins.

Sebaceous glands produce an oily substance called sebum that lubricates the skin. Sebaceous glands are found along the walls of hair follicles.

Additionally, there are three types of modified glands that include the ceruminous glands found in the ears that produce cerumen (ear wax), the mammary glands found in the breasts that produce milk, and the ciliary glands (glands of Moll) that are associated with the eyelashes.

Hair and nails consist of keratin which is a hard protein. The function of nails in the human is not fully understood; however, they are thought to protect the delicate fingertips. Hair is important in heat regulation and acts to trap warm air near the body.

What are the three principal functions of the skin?

The three main functions of the skin are protection, regulation and reception.

1. Protection – the skin provides protection of deeper tissues against drying (dehydration) and against invasion by pathogenic organisms and/or their toxins.
2. Regulation - body temperature is regulated by dissipation of heat to the surrounding air.
3. Reception – the skin receives information about the environment by means of the many nerve endings found throughout the skin.

Are there any other functions of the skin?

The skin also has some additional functions. It helps to preserve fluid balance, absorbs substances such as medications and sunlight, excretes fluid and waste products and synthesizes vitamin D (necessary for calcium absorption).

References

- Cohen, B. (2005). *Memmler's the human body in health and disease* (10th edition). United States: Lippincott Williams & Wilkins.
- Frey, K., et al. (2008). *Surgical technology for the surgical technologist: A positive care approach* (3rd edition). United States: Cengage Learning.

CE REFRESHER

Define the term integument. _____

List and identify the structures of the integumentary system and describe the function of each. _____

Identify the layers of the skin. _____

List the appendages of the integumentary system and describe the function of each. _____

Describe the functions of the integumentary system. _____

**Pages 216 and 217 are for the reader's benefit only. Please do not submit these pages to AST. The CE exam follows on 218.*

Write the meaning of each word element in the space provided.

Word Element	Definition
1. adip/o	
2. caut/o	
3. cutane/o	
4. derm/o	
5. dermat/o	
6. erythr/o	
7. hidr/o	
8. ichthy/o	
9. kerat/o	
10. leuk/o	
11. lip/o	
12. melan/o	
13. myc/o	
14. onych/o	
15. pil/o	
16. scler/o	
17. squam/o	
18. trich/o	
19. xanth/o	
20. xer/o	

Find the answers online at <http://www.ast.org/publications/journal.aspx>