

Continuing Education Independent Study Series



SUPERFICIAL PAROTIDECTOMY FOR PAROTID GLAND TUMORS

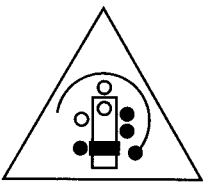
MARY KENNEDY, CST/CFA

ENT-HEAD AND NECK SURGERY

**SHANDS HOSPITAL AT THE UNIVERSITY OF FLORIDA,
GAINESVILLE, FLORIDA**

Association of Surgical Technologists

*Publication made possible by an educational grant provided by
Kimberly-Clark Corporation*



ASSOCIATION
OF SURGICAL
TECHNOLOGISTS

*AEGER PRIMO -
THE PATIENT FIRST®*

Association of Surgical Technologists, Inc.


7108-C S. Alton Way, Suite 100

Englewood, CO 80112-2106

303-694-9130

ISBN 0-926805-20-7

Copyright© 1997 by the Association of Surgical Technologists, Inc. All rights reserved. Printed in the United States of America.
No part of this publication may be reproduced, stored in a retrieval system, or transmitted, in any form or by any means, electronic, mechanical, photocopying, recording, or otherwise, without the prior written permission of the publisher.



PREFACE

“Superficial Parotidectomy for Parotid Gland Tumors” is part of the AST Continuing Education Independent Study Series. The series has been specifically designed for surgical technologists to provide independent study opportunities that are relevant to the field and support the educational goals of the profession and the Association.

Acknowledgments

AST gratefully acknowledges the generous support of Kimberly-Clark Corporation, Roswell, Georgia, without whom this project could not have been undertaken.

INTRODUCTION

Purpose

The purpose of this module is to acquaint the learner with parotid gland tumors and superficial parotidectomy. Upon completing this module, the learner will receive 2 continuing education (CE) credits in category 3 (applicable to CFA certification).

Objectives

Upon completing this module, the learner will be able to do the following:

1. Describe the anatomy of the parotid gland, including its relationship to surrounding nerves that must be preserved during the parotidectomy.
2. Discuss the sequence of steps involved in the superficial parotidectomy procedure.
3. Describe the benign and malignant tumors that may afflict the parotid gland.
4. Discuss the factors that are considered in order to determine the appropriate treatment for a specific type of tumor, including tumor staging.

Using the Module

1. Read the information provided, referring to the appropriate figures.
2. Complete the enclosed exam without referring back to the text. The questions are in a multiple choice format. Select the best answer from the alternatives given.
3. Mail the completed exam to AST, CEIS Series, 7108-C S. Alton Way, Suite 100, Englewood, CO 80112-2106. Please keep a copy of your answers before mailing the exam. You must return the original copy of the answer sheet; this exam may not be copied and distributed to others.
4. Your exam will be graded, and you will be awarded continuing education credit upon achieving a minimum passing score of 70%. If you are an AST member, your credits will be automatically recorded and you do not need to submit the credits with your yearly CE report form.
5. You will be sent the correct answers to the exam. Compare your answers with the correct answers to evaluate your level of knowledge and determine what areas you need to review.

Studying Technical Material

To study technical material, find a quiet place where you can work uninterrupted. Sitting at a desk or work table will be most conducive to studying.

Having a medical dictionary available as you study is very helpful so you can look up any words with which you are unfamiliar. Make notes in the margins of any new definitions so that you can review them.

The ultimate test of how well you learn this material is your ability to relate your knowledge to what is happening in the surgical field. Apply your knowledge to what you observe during surgery.

SUPERFICIAL PAROTIDECTOMY FOR PAROTID GLAND TUMORS

The **parotid gland** is the largest of the salivary glands, weighing between 0.5 oz. and 1.0 oz. The paired glands lie directly in front of the ears and function in the production of saliva, which serves as a lubricant to aid in swallowing and begins the process of food digestion through the breakdown of carbohydrates. In addition, saliva is the mechanical cleanser of the mouth and aids in immunologic defense of the body by serving as the medium through which antibodies, blood-group reactive substances, iodine, and viruses are excreted. In some animals, the parotid gland serves as a defense mechanism by producing and storing venom, which is also used to disable prey.

Tumors of the parotid gland account for less than 5% of all head and neck cancers; however, cancer of the parotid is the most common of the malignancies affecting the salivary glands.¹ Treatment of these tumors is controversial, resulting in many differing opinions on the subject. Currently, **superficial parotidectomy** is the treatment of choice for benign lesions; total parotidectomy is the preferred treatment for malignant lesions, with concurrent neck dissection for the treatment of high-grade lesions or metastatic disease found in the lymph nodes of the neck. The need for palliative neck dissection is widely debated, and the decision to conduct this procedure is made by the surgeon based on the specific disease process. Studies have shown that postoperative radiation increases survival rates, although the outcome depends on the type of tumor involved and whether metastasis is present. Most surgeons agree that the successful performance of superficial parotidectomy with minimal postoperative complications is dependent on thoroughly understanding the pertinent anatomy and obtaining excellent exposure in the operative site.

Anatomy of the Parotid Gland

Situated in front of and slightly below the ears, the parotid glands are palpable between the ramus of the mandible and the mastoid process (Figure 1, p 3). The lateral surface of the gland is covered with skin, and the medial or deep portion is bordered by the styloid process and its muscles (the stylohyoid, styloglossal, and stylopharyngeal muscles) and the carotid sheath containing the internal carotid artery, internal jugular vein, and cranial nerves IX, X, and XII. At the superior border of the gland is the zygomatic arch, and its inferior border is the oblique anterior border of the sternocleidomastoid muscle. Although the parotid gland often is described as having both superficial and deep lobes, the pattern of lobulation is still debated. Most experts agree that the plane between the lobes is the **facial nerve** (cranial nerve VII), which supplies motor innervation to the muscles providing facial expression. Preservation of this nerve is crucial when a superficial parotidectomy is performed in the treatment of masses without nerve involvement. A constant landmark for locating the facial nerve is the **stylomastoid foramen**, where the nerve exits the base of the skull, entering the parotid gland on its posteromedial surface.

The site of the facial nerve's entry into the gland can be found by referring to the cartilaginous pointer of the tragus. The normal distance from skin surface to the stylomastoid foramen is approximately 25 mm, but if the nerve is displaced by a large tumor, its location must then be identified by tracing one of its branches (usually a lower branch) from the gland to the skull base.

Upon exiting the skull base, the nerve divides into two main branches, the **temporofacial division** and the **cervicofacial division**, which further divide to create five branches that traverse the gland: these are the **temporal, zygomatic, buccal, mandibular** (also called the "marginal mandibular") and **cervical**

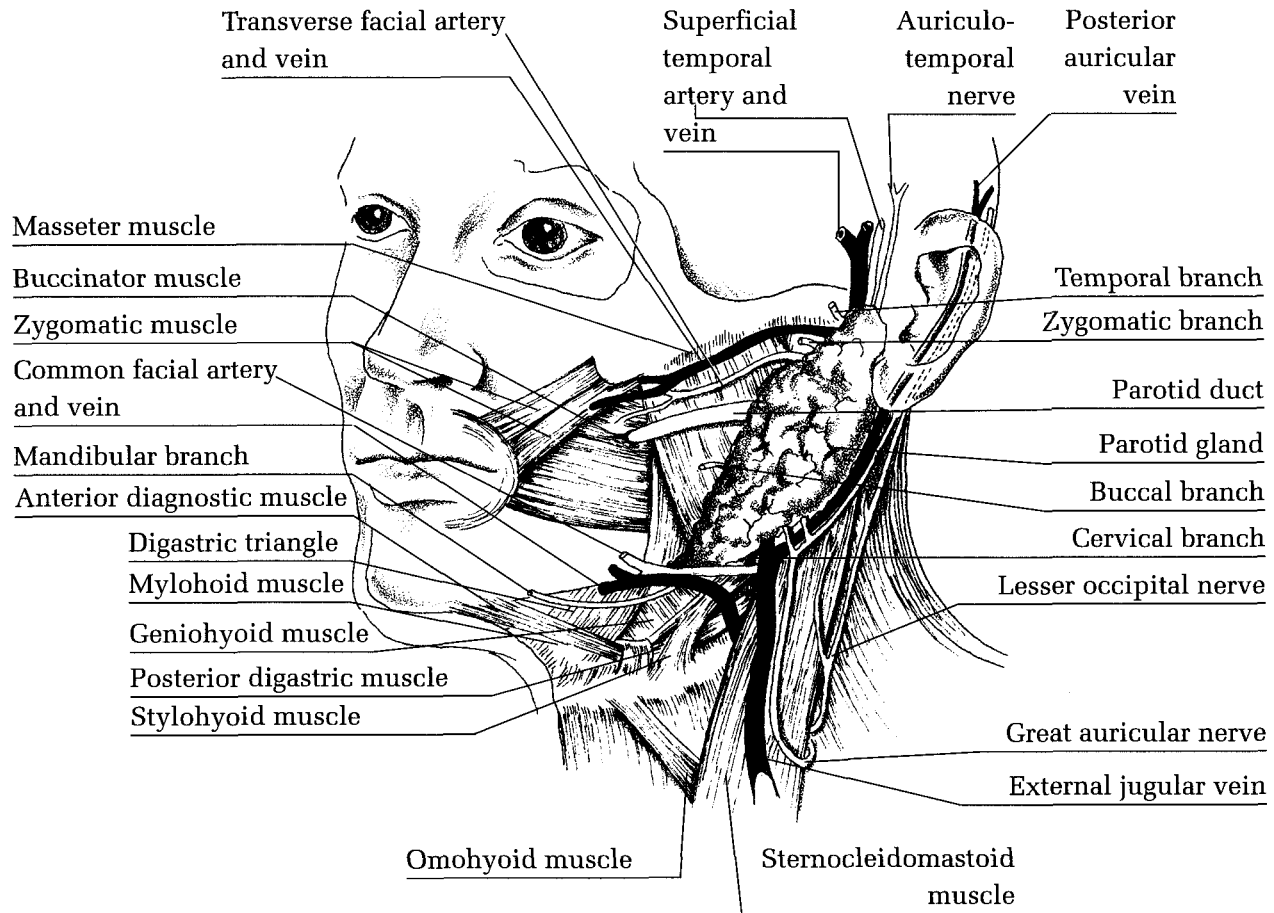


Figure 1. Anatomy of parotid gland and surrounding area. (Adapted from Cummings.³)

branches. The site at which this division takes place is the *pes anserinus* (or “goose’s foot”). The temporal branch raises the eyebrows, and the zygomatic branch closes the eyelids; thus, if these nerve branches were severed, such measures as placing a gold weight in the eyelid to allow it to close and performing a brow-lift procedure may be necessary to compensate for loss of nerve function. The buccal branch moves the nose and the mandibular branch lifts the corners of the mouth into a smile. The cervical branch innervates the platysma muscle, which in humans is neither large nor active, but in horses can twitch sufficiently to ward off flying insects. If the facial nerve is severed but can be partially repaired, the branches most often repaired are the temporal, zygomatic, and mandibular.

The **parotid duct** (or “Stensen’s duct”) appears to originate from the superficial lobe of the gland, but has been described as arising from a varied pattern of extraglandular ductules that may arise from both lobes. The duct traverses the surface of the masseter muscle and crosses the mandible at a point approximately 1 fingerbreadth below the zygomatic arch. There, it abruptly turns medially to pierce the buccinator muscle and the buccal fat pad to enter the oral mucosa approximately at the level of the second maxillary molar.

Superficial Parotidectomy

The most commonly used incision in superficial parotidectomy is the **modified Blair incision**. It begins anteriorly in the pretragal area of the ear and extends inferiorly to the ear lobule, where it gently curves approximately 1 cm over the mastoid tip before tracing the anterior border of the sternocleidomastoid muscle to a point 2 fingerbreadths below the mandible. Some surgeons use the alternate **facelift incision**, which extends superiorly in the postauricular crease and crosses at a level above the point at which the auricle meets the hairline, descending either adjacent to or just within the hairline for approximately 6 cm (Figure 2).² Regardless of the type of incision made, of key importance is that appropriate exposure is achieved to permit removal of the gland without damage to the facial nerve.

The skin flap is elevated from the zygomatic arch to the midportion of the posterior belly of digastric muscle, taking care to leave the parotid capsule intact. The surgeon then carefully dissects the gland off the cartilage of the external auditory canal, taking care not to dissect into a hole. The anterior border of the sternocleidomastoid muscle is released, which enhances exposure. The skin flap and lobule of the ear may be tied back using sutures. The surgeon then goes back along with ear canal to find the cartilaginous pointer of the tragus. The facial nerve lies inferior and slightly deeper and, once found, should be stimulated to ensure it is the whole nerve and not merely a branch. The trunk of the nerve is traced anteriorly using small hemostats. Once the branches are located, they are traced by creating tunnels above them with the hemostats, and gland tissue is clamped, cut, and tied, thus freeing it from the nerve. At this time, the assistant places the gland under moderate traction to facilitate these actions. Each of the branches is traced in this fashion until the gland is removed. If the facial nerve can not be found at the level of the stylomastoid foramen, location can be accomplished by following the course of the mandibular branch, which can be found and traced reliably. After the gland is removed, the nerve is stimulated again to ensure that all of the branches are functional.

Several complications may arise in superficial parotidectomy: among them are **facial nerve paralysis** or paresis, **salivary fistula**, and **Frey's syndrome**. The incidence of facial nerve paralysis is nominal, although postsurgical weakness of the nerve may occur. If the facial nerve is cut during surgery, it should be repaired immediately for optimal preservation of nerve function. The greater auricular nerve, which usually can be found within the surgical field, can be used as a cable graft. In the case of a salivary fistula, saliva may drain through the incision, but this circumstance can be expected to resolve in 2 to 3 weeks.

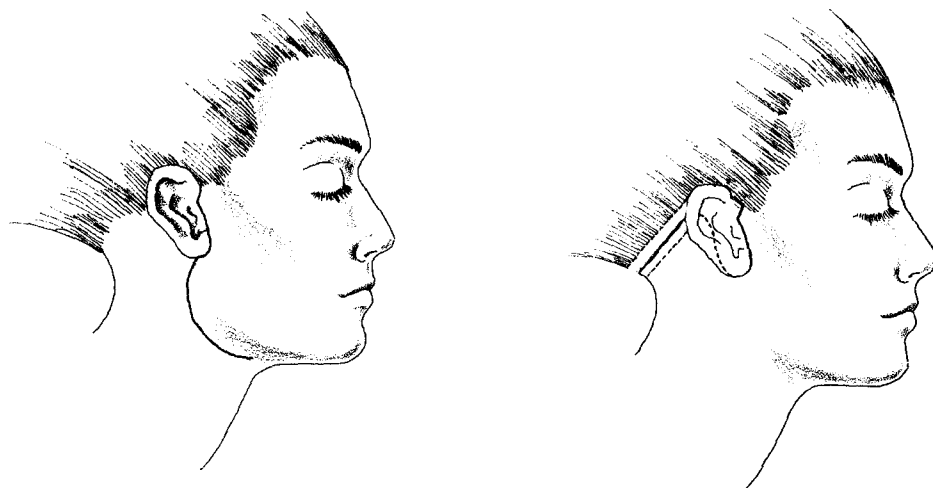


Figure 2. Modified Blair incision (left) and alternate facelift incision (right). (Adapted from Terris et al.²)

Frey's syndrome ("gustatory sweating") is a more complicated disorder in which the patient will sweat while eating. This condition usually affects older women whose skin is paper-thin or those patients in whom an overly thin skin flap was made. The phenomenon of gustatory sweating occurs as follows: The parotid gland is innervated by the glossopharyngeal nerve (cranial nerve IX), which is under control of the parasympathetic nervous system. When the flap is dissected during parotidectomy, the nerve fibers—which have no structured organization within the parotid—consequently are cut. During the regeneration process, some of these fibers may eventually innervate the sweat glands, which are controlled by the sympathetic nervous system. In the sympathetic nervous system the postganglionic neurotransmitter is norepinephrine except for the sweat glands in which the neurotransmitter is acetylcholine. This is logical since the sympathetic system governs the "flight-or-fight" response, and one does not sweat immediately during that response. In the parasympathetic nervous system, the postganglionic neurotransmitter is acetylcholine; therefore, following superficial parotidectomy, when the regenerated nerve fibers innervate the sweat glands, gustatory sweating is a resulting condition. Currently, no treatment method exists for patients suffering from Frey's syndrome.

Parotid Tumors and Associated Treatment Methods

Benign Tumors

Pleomorphic adenomas (benign mixed-cell) are the most common of the parotid neoplasms, originating in epithelial and connective tissues. Patients are usually in their 40s or 50s and have a painless, slow-growing mass that usually is found incidentally in the cheek or near the angle of the mandible. Approximately 90% of these tumors arise superficially to the facial nerve; if located within the deep lobe, the tumor is considered a parapharyngeal-space mass. The latter type causes intraoral swelling as well as medial displacement of the tonsil and lateral pharyngeal wall. Such masses are firm and mobile and rarely involve the great vessels.

On gross examination, a pleomorphic adenoma is a solitary, firm, round tumor with a capsule that is thin, delicate, and incomplete; through this capsule extend projections of the tumor known as "pseudopods." This type of tumor generally does not recur if resected adequately; most cases of recurrence can be attributed to failure to remove the pseudopods when excising the mass. Removal of a cuff of normal parotid-gland tissue along with the mass is recommended to prevent recurrence. Recurrent tumors tend to be nodular, because of the pseudopods. The color of the tumor may be white, gray, or pale yellow. Superficial parotidectomy or the excision of a parapharyngeal-space tumor is the treatment of choice for pleomorphic adenomas. Malignant transformation in these normally benign tumors may occur in long-standing masses, although such events are rare. Radiation therapy has a questionable role in the treatment of recurrent pleomorphic adenoma, but is used when surgery is no longer feasible; chemotherapy does not have a role in the treatment of such tumors.

Monomorphic adenomas are benign salivary-gland tumors that arise from ductal epithelium. Affected patients are usually in their 60s or older. These tumors are asymptomatic, slow-growing masses in which facial-nerve involvement is rare. Two types of monomorphic adenomas are discussed here: basal cell and clear cell.

Basal cell adenomas are the predominant tissue type found in monomorphic adenomas. They occur in patients whose average age is 60. This type of tumor usually occurs in the parotid gland and the small salivary glands of the upper lip. Basal cell adenomas are solid, well-circumscribed tumors having a gray-

white, gray-red, or pink-brown surface. These tumors are encapsulated, and they often are clinically misdiagnosed as enlarged lymph nodes, sebaceous cysts, lipomas, or pleomorphic adenomas.

Clear cell adenomas are slow-growing, asymptomatic, solid, and well-circumscribed and tend to have a gray-white or yellow color. Conflicting reports exist on the behavior of clear cell adenomas: Some experts regard these tumors as low-grade carcinomas. The treatment for clear cell adenoma is surgical excision in the form of superficial parotidectomy.

A **Warthin's tumor** is a papillary cystadenoma lymphomatosum (or "adenolymphoma"). These tumors occur almost exclusively in the parotid gland and represent the second most common of the parotid neoplasms, accounting for nearly 10% of all parotid tumors. These tumors usually have a unilateral focal involvement, but can be bilateral in nearly 10% of cases. Most patients are males usually in their 50s or 60s; the tumor is rare in African Americans. Warthin's tumor most often occurs in the superficial lobe of the parotid gland, near the angle of the jaw, but also has been reported to occur in the parapharyngeal space. The tumors are encapsulated with a smooth, lobulated surface; they have papillary cysts and also may contain a mucoid, brown fluid that resembles motor oil. The treatment for Warthin's tumor is superficial parotidectomy with preservation of the facial nerve. The tumor may recur either because of inadequate resection or the multicentricity of the tumor itself.

Hemangiomas are the most common salivary-gland tumor occurring in children. Most hemangiomas occur in the parotid gland and may be present at birth, but usually appear several days or weeks postnatally. The tumor experiences a rapid growth phase between the child's first through sixth months of life; following this, the tumor tends to involute while the child is between 1 and 12 years of age. Hemangiomas may grow to an extreme size and cause complications such as excessive bleeding and heart failure. The standard treatment for hemangiomas consists of steroids (2 to 3 mg/kg per day), with a 40% to 60% response rate. These tumors are dark red, lobulated, and nonencapsulated; the masses are asymptomatic, unilateral, and compressible. Surgical excision and laser treatment are used in selected patients.

Malignant Tumors

Many factors influence the survival rate of patients diagnosed with a malignant tumor of the parotid gland, as well as the treatment modalities appropriate for specific types of tumors. These factors are the histopathological diagnosis of the tumor; whether lymph-node metastasis is present (usually occurring in the affected side of the neck); the presence of pain, facial nerve paralysis, or skin involvement; the stage and location of the tumor; whether the tumor is recurrent; the presence of distant metastases; and the radiation sensitivity and chemosensitivity of the tumor. Malignancies of the parotid gland are classified as either high or low grade, and the treatment selected may be dependent on the gradation determined. Most surgeons will perform a **prophylactic neck dissection** on the affected side only for high-grade tumors or if metastasis in the lymph nodes of the neck has been identified through computed tomography (CT) scan. The need for such dissection is a matter of controversy: One opinion is that neck dissection is advised if a 25% risk of nodal metastasis is determined; another opinion is that delaying dissection until nodal metastasis occurs does not affect patient outcomes adversely.^{3,4} A consensus exists, however, that if the nodes in the neck are positive for metastatic disease, neck dissection should be performed.

The many different types of parotid-gland malignancies can be graded. Mucoepidermoid carcinoma is considered either high grade or low grade, whereas adenoid cystic carcinoma is high grade and acinic cell carcinoma is low grade. Adenocarcinomas are grouped as either high grade or low grade; the former group includes adenocarcinoma, ductal carcinoma, and oncocytic malignancy. Ductal carcinoma is noted for a 50% rate of nodal and distant metastasis and a 2.5-year mean survival rate.^{3,4} A patient can die of a

high-grade adenocarcinoma long after 5 years. Low-grade adenocarcinomas include mucous-producing adenopapillary or nonpapillary carcinoma, clear cell carcinoma, epithelial or myoepithelial carcinoma of intercalated ducts, and terminal duct carcinoma.

A carcinoma may arise from a pleomorphic adenoma or a malignant, mixed tumor, which are considered high-grade. Squamous cell carcinoma of the parotid gland is high grade. Undifferentiated carcinomas, sebaceous carcinomas, melanomas, and carcinomas arising from lymphoepithelial lesions may be either high or low grade. A parotid tumor may also be a hybrid basal cell adenoma/adenoid cystic carcinoma, which usually is considered high-grade because of the adenoid-cystic component. The parotid gland may be the site of a metastatic carcinoma or a melanoma or squamous cell carcinoma.

The decision to perform a prophylactic neck dissection may be influenced by the stage of the parotid malignancy. Spiro, in 1975, described patients with stage I tumors as having a 1% risk of neck-node metastasis; those with stage II tumors had a 14% risk, and patients with stage III tumors had a 67% risk of metastasis in the neck nodes.³ He concluded that smaller tumors represented a lesser risk of nodal metastasis. The initial occurrence of lymph-node metastasis tends to take place in the periparotid area; such diseased tissue would be removed with the tumor, and any occult metastasis can be controlled with postoperative radiation therapy.

Pain is not a criterion for parotid malignancy, but it correlates with a poor prognosis in patients with a known malignancy. Facial nerve paralysis associated with a parotid mass usually indicates a malignancy with a dismal prognosis. The incidence of facial nerve involvement in parotid tumor patients is estimated at 12% to 14%; however, this rate varies according to the specific histology of the tumor; adenoid cystic carcinoma and undifferentiated carcinoma are the tumor types having the highest rate of nerve involvement. Facial nerve paralysis occurring in the presence of a parotid mass indicates a malignancy, high likelihood of neck-node metastasis, and a poor prognosis for most patients. Treatment most often consists of total parotidectomy that includes excision of the facial nerve as well as temporal bone dissection. Cable nerve graft is performed if indicated, but the placement of a gold weight in the affected eyelid as well as the later performance of facial reanimation surgery (such as a temporalis sling) are the treatment methods more likely chosen. Again, the treatment selected is dependent on the type of carcinoma identified, and the patient's prognosis and personal preferences. Skin involvement is rare; if present, it tends to indicate an advanced malignancy and poor survival for the patient. The tumors that most commonly involve the skin are melanomas and squamous cell carcinomas, which usually are large tumors that cause facial nerve paralysis. Treatment includes en bloc resection of the tumor, followed by such repair procedures as nerve graft or flap coverage of the area.

Tumor staging represents a significant factor in determining survival rates and treatment choices. In tumor staging, the size of the primary tumor is of greatest importance. The tumor is assigned to a "T-class" and "N-class." The T-class is determined by the size of the primary tumor and the N-class represents the site of nodal metastasis and the number and size of nodes involved. The staging of a tumor correlates well with the incidence of distant metastasis and risk of recurrence. The staging of mucoepidermoid carcinoma correlates extremely well with distant metastasis, lymph node metastasis, recurrence, and overall survival rate.

The "T-class" staging is as follows:

T₀ = unknown primary

T₁ = 0 cm to 2 cm

T₂ = 2 cm to 4 cm

T₃ = 4 cm to 6 cm

T₄ = greater than 6 cm

T_x = primary tumor cannot be assessed (usually due to biopsy, etc.)

The "N-class" of staging is as follows:

N₀ = no lymph node metastasis

N₁ = single lymph node, less than 3 cm, on the same side as the tumor

N_{2a} = single lymph node, 3 cm to 6 cm, on the same side

N_{2b} = multiple lymph nodes, none greater than 6 cm, on the same side

N_{2c} = bilateral or opposite-side lymph nodes, none greater than 6 cm

N₃ = metastasis in a lymph node greater than 6 cm

N_x = nodes cannot be assessed

Conclusion

A thorough knowledge of the pertinent anatomy is vital to the success of surgery on the parotid gland in which the facial nerve is to be preserved. The facial nerve is to be preserved in all patients in whom the tumor does not involve the nerve. The occurrence of facial nerve paralysis associated with a parotid tumor suggests a poor prognosis for the patient. Many factors influence the survival rates of patients with parotid malignancy: The most important of these is the stage of the disease, which is dependent on the size of the tumor and whether neck-node metastasis is present. Smaller tumors are associated with decreased risk of neck-node metastasis, whereas larger tumors or high-grade tumors such as mucoepidermoid carcinoma, squamous cell carcinoma, or ductal carcinoma have higher rates of metastasis to the neck nodes. Controversy surrounds whether prophylactic neck dissection should be performed on patients with a parotid malignancy. Most surgeons will perform a prophylactic neck dissection on patients with a high-grade tumor, and all surgeons will perform a neck dissection on patients in whom neck-node metastasis is present.

The treatment of choice for most parotid neoplasms, benign or malignant, is surgical excision of the tumor. All other treatment modalities are dependent on the type of tumor involved, the surgeon's preferences, and the patient's wishes.

Bibliography

1. Roberson DW, Chu FWK, Yarrington CT. Parotid cancer: Treatment and results. *ENT J*. 1993;72:787-793.
2. Terris DJ, Tuffo KM, Fee WE. Modified facelift incision for parotidectomy. *J Laryngol Otol*. 1994;108:574-578.
3. Cummings (ed): *Otolaryngology - Head and Neck Surgery*. 2nd ed. St Louis, Mo: Mosby-Year Book; 1993:vol 2.
4. Lee KJ, ed. *Essential Otolaryngology Head and Neck Surgery*. 6th ed. Norwalk, Conn: Appleton and Lange; 1995.

Suggested Readings

Buchman C, Stringer SP, Mendenhall WM, et al. Pleiomorphic adenoma: Effect of tumor spill and inadequate resection on tumor recurrence. *Laryngoscope*. 1994;104:1231-1234.

Kun A, Dao-Yi Q, Li-Min W. Functional superficial parotidectomy. *J Oral Maxillo Surg.* 1994;52:1038-1041.

Yoo GH, Eisele DW, Askin FB, et al. Warthin's tumor: A 40-year experience at The Johns Hopkins Hospital. *Laryngoscope.* 1994;104:799-802.