HEMILAMINECTOMY WITH LUMBAR DISKECTOMY

ARTICLE BY BOB L. CARUTHERS, CST

Lumbar disk herniation is a relatively common pathological condition. Such herniations produce a classic clinical picture that may be treated through conservative therapy, surgical intervention, or both. The hemilaminectomy with diskectomy is the preferred surgical procedure. The hemilaminectomy with lumbar diskectomy is a relatively common procedure performed by a neurosurgeon or an orthopedic surgeon to relieve pressure on the cauda equina or a given nerve root as a result of the herniation of a lumbar disk. The anatomy, pathology, surgical method, and postoperative results of this procedure are described in this article.

Anatomy

The spinal column normally consists of thirty-three vertebrae. These vertebrae are categorized according to the anatomical position they occupy: cervical (seven), thoracic (twelve), lumbar (five), sacral (five), and coccygeal (four). Each vertebra consists of two essential components: anteriorly, the body and, posteriorly, the neural arch. The individual vertebrae are stacked one upon the other to form the spinal column (Figure 1).

Between each pair of vertebral bodies, the intervertebral disk serves as a specialized symphysis, a type of joint in which two bony surfaces are united by a fibrocartilage. The intervertebral disk consists of two tissue types, the nucleus pulposus and the annulus fibrosus. The nucleus pulposus makes up the central portion of the disk. The nucleus pulposus is surrounded by a dozen or so concentric rings of the tough annulus fibrosus. An image of a jelly doughnut may help to visualize the structure of the disk. The nucleus pulposus is represented by the jelly and the annulus fibrosus by the dough part of the doughnut.

The column part of the spinal column is formed by a stack of vertebral bodies and disks. From an anterior view, one can see the column-like formation clearly. A lateral view shows that the column contains four curves, two convex and two concave. The functions of these curves are (1) to increase the length of the column, (2) to assist in the maintenance of balance, (3) to assist in shock absorption, and (4) to help protect against fracture. A posterior view presents a more complex image of spinous processes and laminae. The lamina extends from the posterolateral portion of the vertebral body and with the pedicle forms a roof over the spinal cord or *cauda equina*. One way to remember the basic structure is to imagine a strange-looking house (Figure 2). The house has three basic parts: the foundation, the walls, and the roof. The spinal cord structure has three similar parts: the vertebral body (foundation), the pedicles (walls), and the lamina-spinous process (roof). The lamina might be imagined as the roof proper and the spinous process as a chimney. Removal of the building materials of the walls of the attic shows an opening that is protected on one side by the house proper and on the other side by the roof. This opening is analogous to the spinal canal. Imagine some windows near the junction of the roof and the walls that are analogous to the anterior intervertebral foramina that allow nerve roots and blood vessels to pass through. Longitudinal ligaments, one anterior and one posterior, extend from the base of the skull to the sacrum. What we see in the structure of the spinal column is the construction of a well-protected passageway through which the spinal cord and nerve roots pass. These are surrounded by a shiny white tissue called the *dura* and bathed in spinal fluid (Figure 2).

Pathologic Condition

The pathologic condition that brings a patient to the operating room for a hemilaminectomy with lumbar diskectomy is a herniated lumbar disk. The term *herniation* refers to an abnormal protrusion of a body structure through a defect or natural opening in a covering membrane. Hernia-

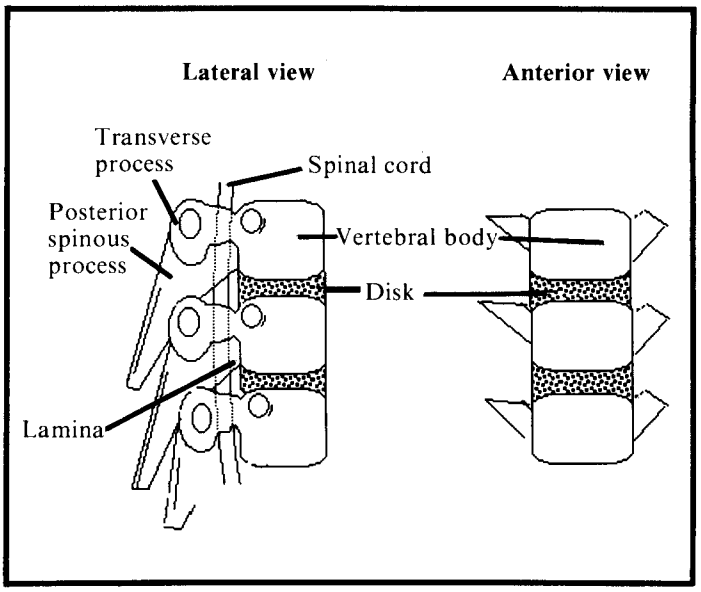

Figure 1. Basic anatomical relationships.

Bob L. Caruthers, CST, is program director of surgical technology at Austin Community College and a doctoral candidate in curriculum and instruction at the University of Texas at Austin.

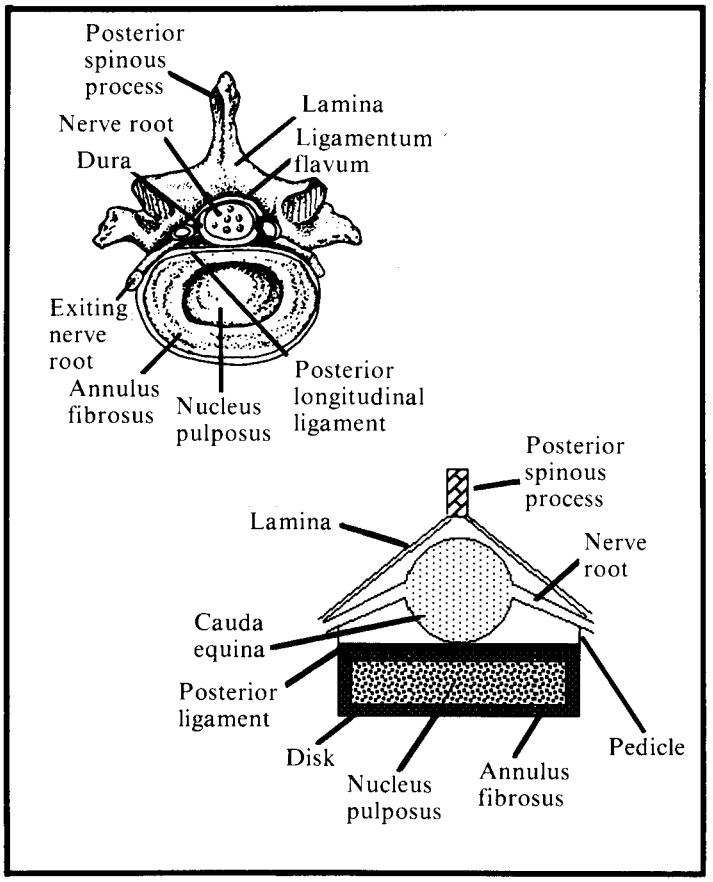

Figure 2. The spinal cord's house.

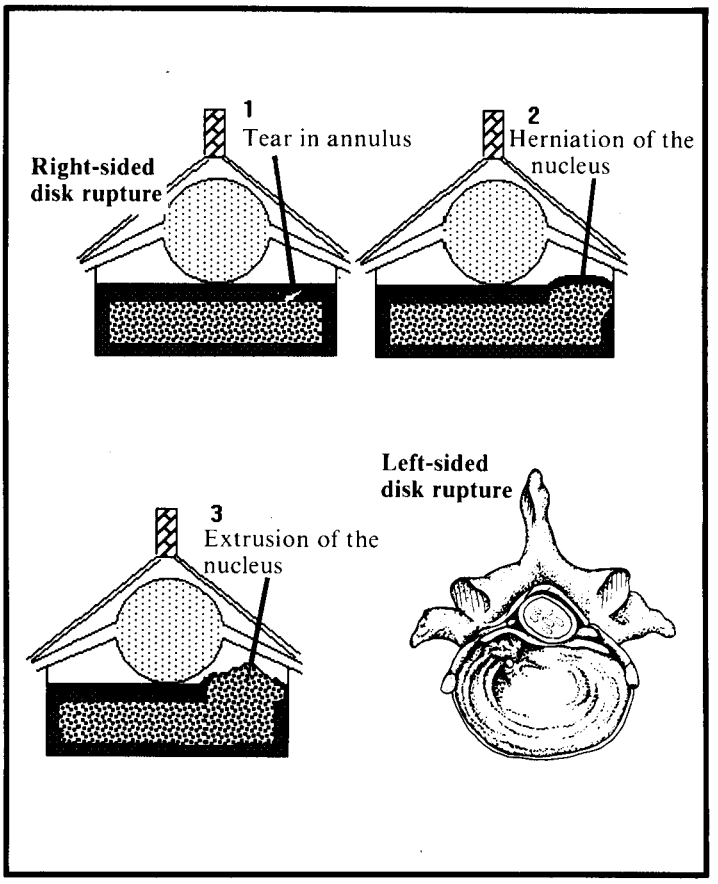

Figure 3. Stereotypical phases in disk rupture.

tion of the nucleus pulposus of a lumbar disk is a protrusion of the nucleus pulposus into the spinal canal through a defect in the surrounding annulus fibrosus.

The nucleus pulposus has the texture of crabmeat, and that allows it to function as a shock absorber, while the annulus fibrosus is a tough, elastic tissue. In the healthy disk, the toughness allows the annulus fibrosus to hold the softer nucleus pulposus in place. The elasticity allows the annulus fibrosus and the nucleus pulposus to adjust to the compressional forces placed upon them. The disks between the fourth and fifth lumbar vertebrae (L_{4-5}) and between the fifth lumbar and first sacral vertebrae (L_5-S_1) typically receive the greatest compressive force during normal activity. While lumbar disks may herniate at any of the levels, the most common sights are the L_{4-5} and L_5-S_1 disks.

The nucleus pulposus may or may not be damaged before the annulus fibrosus; however, the structure of the disk is such that as long as the annulus fibrosus is strong and intact no herniation occurs (Figure 3). If the annulus fibrosus weakens or tears, the nucleus pulposus will protrude or may even become a fragment in the disk space (an extruded disk). The pathologic process is usually progressive. For example, in the first stage the annulus fibrosus is weakened or torn by some mechanical strain, often occurring when the back is flexed. The weakened annulus fibrosus allows greater movement on the part of the softer nucleus pulposus. Under compression, the nucleus pulposus now exerts more pressure in an internal to external vector against the weakened annulus fibrosus forming a bump or herniation. In some cases, the nucleus pulposus may exert enough force to tear the annulus fibrosus. Fragments of the nucleus pulposus may work their way out of the disk proper and become extruded fragments trapped between the annulus fibrosus and the posterior longitudinal ligament. During this process, the posterior longitudinal ligament is also weakened. The stretching of this ligament is thought to be the primary cause of the back pain associated with the herniated disk. At times the ligament may tear and allow the disk fragments to become free in the spinal canal. The tearing of the ligament is often associated clinically with a sudden loss of pain, the tear being less painful than the stretching of the tissue. Both the extruded disk and the free fragment may migrate, usually caudally.

Two important facts about disk herniation must be understood. The first is that a disk, at least theoretically, can herniate in any direction. The second is that the problem to be corrected is a mechanical one whose nature is vice-like. These two factors produce the clinical picture that sometimes brings a patient to the operating room. In the case of the lumbar disk, the anterior longitudinal ligament is very strong while the posterior is relatively weak. Furthermore, most injuries occur when the back is flexed thereby directing the shearing forces posteriorly. Disk herniations, therefore, are more or less posteriorly situated. They may be posterocentral or posterolateral. Looking at Figure 2, it is easy to see that a central herniation is likely to exert pressure on several nerve roots and possibly the entire cauda equina while the lateral herniation is likely to exert pressure on a single nerve root. The disk, protruding posteriorly, is like the movable jaw of a vice. The lamina above forms the immovable jaw. Caught between these two is a nerve root. It is important to visualize the problem in this

way to understand the clinical signs and the possible treatment modalities. The problem is mechanical in nature. There is a given amount of space for the nerve root. If that space is reduced too much by disk, bone, tumor, or foreign object, pressure will be exerted on the nerve root. Pain and possible loss of function result. Since the nerve root itself can not be removed, the possible solutions are to either move the movable jaw of the vice (in our case, the disk) or to remove the immovable jaw (the lamina).

Given these options, the various surgical interventions, not limited to disk problems, are logical and easy to understand. To facilitate understanding, recall the house image example (Figure 4). The problem is to reduce pressure somewhere in the attic (spinal canal/foramen). One option is to remove the entire roof, a lumbar laminectomy. Another option, if the pressure is on one side of the attic, is to remove the roof on that side, a hemilaminectomy. If the pathologic situation causes pressure that is discrete enough (disk herniation) it may be conveniently removed using the second option, eg, a L_{4-5} right hemilaminectomy with diskectomy.

Clinical Presentation

Diagnosis and treatment of back problems is a complicated process. Symptoms and signs are only part of an overall evaluation performed by the physician. It is the total clinical picture that leads to a particular diagnosis and treatment.

The typical patient with a herniated lumbar disk has a well-known set of symptoms. The patient usually describes a "catchy," low back pain that is aggravated by certain mechanical factors such as twisting, bending, coughing, or lifting. Pain may be described as isolated in the back, buttock, or leg, possibly extending to the toes. The pain commonly improves with bedrest and worsens with sitting or standing. Recalling the anatomy and pathologic process described, it is easy to see that sitting and standing cause maximal force to be exerted in a vector up and down the spinal column, thereby increasing pressure on the disk space. The prone position minimizes this pressure. The patient may or may not complain of tingling or numbness in the distal distribution of the affected nerve root. Muscle spasms are a relatively common complaint; and muscle weakness is relatively rare. The symptoms usually occur intermittently. In the case of disk herniation, the onset of symptoms is not commonly correlated with a particular traumatic event. Patients will often state, "I have no idea what happened."

Patients with diverse back problems exhibit several common signs. The back is usually held rigid, and the patient may list to one side. Pain often results from any movement, so the patient moves gingerly. Muscle spasm and tenderness may be obvious upon palpation. Several signs are more specific to a herniated lumbar disk. Disk patients often complain only or mostly of leg pain. This pain is intensified by raising the leg with the knee extended and sometimes by raising the opposite leg. There may be demonstrable losses in sensation and reflex activity. Muscle weakness and even atrophy may occur. In severe midline herniations, para-anesthesia, loss of sphincter control, or paraplegia may exist. The following signs resulting from pressure on either the L_4, L_5, or S_1 nerve roots respectively may be present: (1) a diminished or absent patella reflex, (2) the presence of a foot drop or inability to dorsiflex the great toe with strength, and (3) a diminished or absent ankle jerk.

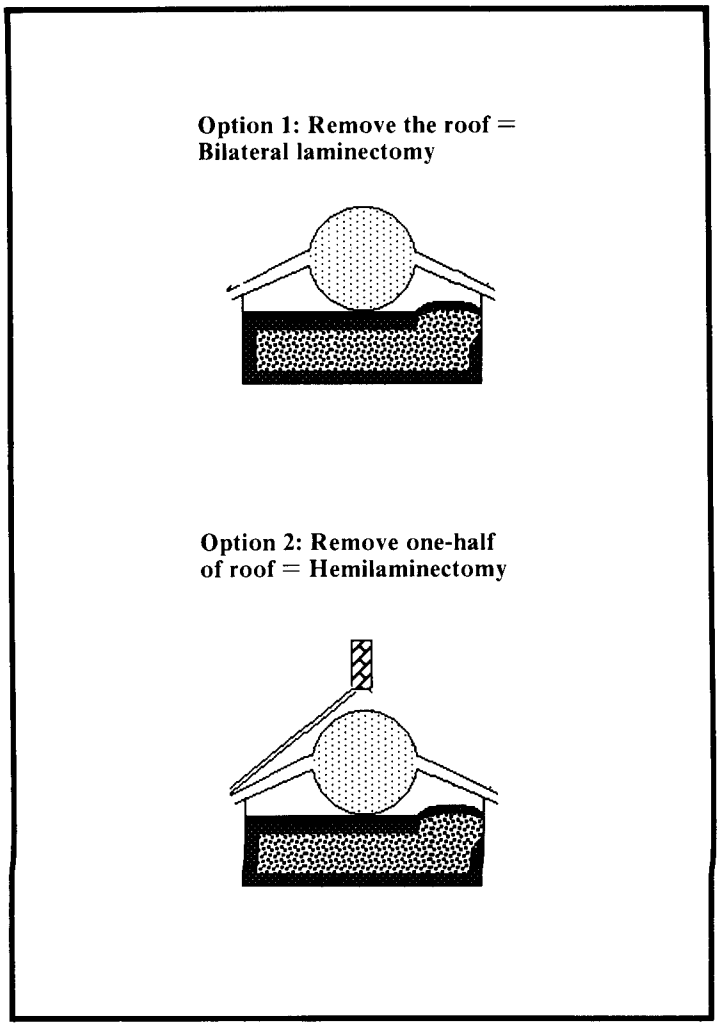

Figure 4. Surgical options to reduce presure.

In addition to the history and physical, several diagnostic tests may be used to determine the need for surgery. Three common diagnostic tests are the electrical myogram, the myelogram, and computerized tomography. The electrical myogram is used to test electrical conduction in a given nerve root distribution. The myelogram is the classic diagnostic procedure for herniated disks. It consists of a series of x-ray films of the spinal canal following injection of a contrast medium into the subarachnoid space via spinal tap. Computerized tomography produces a series of polaroid-like pictures based on density measurements through a computer-assisted body section roentgenography.

The symptoms, signs, and tests produce the data that the physician and patient use to determine the best treatment mode for the patient. Usually a conservative approach consisting of bed rest, pain medication, muscle relaxers, and traction are tried first. If these treatments fail or other factors take precedence, then the patient may be brought to the operating room.

Operative Procedure

Lumbar diskectomies are performed with the patient in a prone position with flexion at the level of the iliac crest. Knees are flexed, and hands are usually placed above the

head with arms on angled arm rests. Cylindrical pads are placed bilaterally at the iliac crest and the axillae to allow the abdominal viscera to fall anteriorly, minimizing abdominal venous obstruction and distention of the epidural veins. Elbows should be padded to protect the ulnar nerve. Weight should not be on the knees. The patient is grounded in the normal manner. Because the procedure is performed with the patient prone, all perioperative personnel should be especially careful to orient themselves to the patient's right or left. A procedure should be in place to ensure that the x-ray films or tomograms, the patient's history, and the surgeon's notes agree as to the side on which the hemilaminectomy is to be done.

The first phase of the procedure begins with draping and ends with the exposure of the nerve root and disk space. After routine preparation and draping, a midline incision is made and carried down to the lumbodorsal fascia over the spinous processes at the level of the herniation. Hemostasis is secured with electrocoagulation or by eversion of the skin. A self-retaining retractor is placed to provide clear access to the fascia. An incision is made into the lumbodorsal fascia and the tendinous attachments. A periosteal elevator, or osteotome, is used to expose the spinous processes for a subperiosteal dissection. Sponges are usually packed around the exposed bony structures to aid in visualization and hemostasis. The freed paraspinous muscles are moved laterally and held with a self-retaining retractor. At this point, the surgeon should have good visualization of the lamina on the operative side. The surgeon verifies that the proper disk space is exposed by palpation, x-ray films, or both. The lamina edges are exposed with a currette. A rongeur is used to remove the inferior aspect of the superior lamina. Bone wax is applied for hemostasis. The ligamentum flavum is now visualized and ready for excision. Excision is accomplished with toothed tissue forceps and a no. 15 blade. A currette or rongeur may be used to secure maximum exposure. Cottonoids may be placed to protect the dura.

The second phase of the procedure begins with an extradural exploration of the disk space and nerve root and ends with the removal of the damaged disk. The operating microscope may be placed at this time and used continuously until closure is begun. The extradural exploration is accomplished with a blunt nerve hook and a probing instrument, perhaps a Crile dissector or a Freer elevator. The disk space is identified and the nerve root inspected. Free fragments, should they exist, are removed with a pituitary rongeur. Cottonoids may be used for hemostasis and/or to protect the nerve root. A circular incision is made in the annulus fibrosus and posterior longitudinal ligaments with a no. 11 blade. The nucleus pulposus then is removed with straight and angled currettes and pituitary rongeurs. As much as possible of the nucleus pulposus will be removed to guard against recurrence.

The final phase of the procedure begins with a second extradural exploration and ends with the application of a sterile dressing. If the nerve root is not sufficiently mobile following the removal of the disk, a foramenotomy may be done. Cottonoids are removed. Hemostasis is secured with gelatin sponges, bone wax, and/or electrocoagulation. The wound is thoroughly irrigated and a sponge count done. Wound closure is by anatomical layer. For the fascia, 2-0 silk is generally preferred and 3-0 silk for the subcuticular layer. Silk or nylon sutures are used for the skin.

Postoperative Results

Postoperative results generally are very good. Since the problem being corrected is mechanical in nature, better results are often obtained in cases of more severe pathology. Patients usually return to work within 60 to 90 days with some restrictions on lifting. Some patients continue to have intermittent symptoms that are treated with conservative therapy. A few patients report no change or even a worsened condition. Eighty percent of patients report complete pain relief or intermittent pain controlled by mild pain relievers. Considering that the surgery is performed for pain relief, a highly complicated psychosomatic phenomenon, these results are quite acceptable. □

Glossary

cauda equina: literally, horse's tail: refers to the sheaf of lower spinal nerve roots that descend from the spinal cord and exit from the lower spinal canal.

computerized tomography: computer-assisted body section roentgenography, a diagnostic procedure.

foramen: a natural opening or passage. The anterior intervertebral foramen allow nerve roots and blood vessels to pass through.

herniation: an abnormal protrusion of a body structure through a defect or natural opening in a covering membrane; **herniation of the nucleus pulposus:** protrusion of the nucleus pulposus into the spinal canal through a defect in the surrounding annulus fibrosus.

intervertebral disk: the layer of fibrocartilage, consisting of the nucleus pulposus and annulus fibrosus, between adjoining vertebral bodies.

lamina: a thin, flat plate or layer; **vertebral lamina:** one of the paired bony plates constituting part of the neural arch.

laminectomy: surgical excision of the posterior arch of a vertebra.

myelography: roentgenography of the spinal canal following injection of a contrast medium into the subarachnoid space, a diagnostic procedure.

symphysis: a type of joint in which two bony surfaces are united by a fibrocartilage.

symptom: a describable change in the physical or mental status of the patient; the change may or may not be perceptible to others.

vertebra: one of the separate segments composing the spine (vertebral column); each vertebra consists of two essential components—anteriorly, the body and, posteriorly, the neural arch.

Bibliography

Association of Operating Room Nurses: Recommended practices: Positioning the surgical patient. *AORN J* 1990; 52:1035-1038.

Caruthers BL: Lumbar diskectomy. *OR Tech* 1976; 8:24-28,39.

Seemes RE: *Ruptures of the Lumbar Intervertebral Disc.* Springfield, IL, Charles C. Thomas, 1964.

Tippett P: Neurosurgery, in Ballinger WF, Treyball JC, Vose AB (eds): *Alexander's Care of the Patient in Surgery.* ed 9. St Louis, CV Mosby Co, 1991.

Tortora GJ, Anagnostakos NP: *Principles of Anatomy and Physiology.* ed 4. New York, Harper and Row, 1984.