The Liver: An Overview

Bob Caruthers, CST, PhD
AST Deputy Executive Director

Following the concavity of the diaphragm, the liver occupies much of the right upper abdominal quadrant. The largest gland in the body, the liver represents approximately one-fortieth of adult body weight. At its most superior point, the liver lies behind the fifth rib in the right mammary line. The liver's left edge terminates just below the apex of the heart, approximately 8 cm to the left of the median line. The liver's inferior border cuts diagonally and at the median line passes approximately midway between the xiphoid process and the umbilicus. The inferior border reaches the right costal margin at the ninth costal cartilage and continues downward and posteriorly. [1]

The liver's diaphragmatic surface is divided into superior, anterior, right, and posterior sections. The heart produces a shallow fossa—the cardiac impression—where it lies on the liver. The posterior and right parts of the diaphragmatic surface are in contact with the diaphragm and the ribs. The posterior surface contains a sulcus through which the inferior vena cava passes. The falciform ligament subdivides the anterior and superior surfaces, with the anterior surface lying against the diaphragm, costal margin, xiphoid process, and abdominal wall. The liver's visceral surface is separated from the superior section by the inferior border. Posteriorly, the border is rounded and blunt, while anteriorly, it is narrow and sharp. The ligamentum teres notches the inferior border just to the right of the median plane. The fundus of the gallbladder rests in another shallow fossa farther to the right. The visceral surface, which holds the gallbladder and is indented by the inferior vena cava posteriorly, relates to the other abdominal structures, which project into the right upper quadrant. They include the right suprarenal gland, right kidney, and the right flexure of the colon, duodenum, and stomach. Hepatic arteries, veins, and ducts enter and exit in the portal region, near the midline of the visceral surface.[1] The liver can be subdivided into various anatomical and functional parts. Its lobes and segments are shown in Figure 1 on page 32. The lobule—the basic functional unit of the liver—will be discussed later. [1,2]

In the adult, the liver's peritoneal reflections include the ventral mesogastrium to the anterior abdominal wall and diaphragm, and to the stomach and the duodenum. These reflections produce the falciform ligament, the coronary ligament, and the left and right triangular ligament.[1]

The left gastric artery may have a hepatic branch, which passes to the left lobe of the liver. The common hepatic artery runs along the upper border of the pancreas and passes from behind the peritoneum of the posterior body wall into the lesser omentum at the upper edge of the duodenum. Branches of this artery include the gastroduodenal, proper hepatics, and infrequently, the right gastric. The proper hepatic artery is a continuation of the common hepatic, which follows the gastroduodenal branch. It typically lies to the left of the common bile duct, which is located anterior to the portal vein. Branches of this

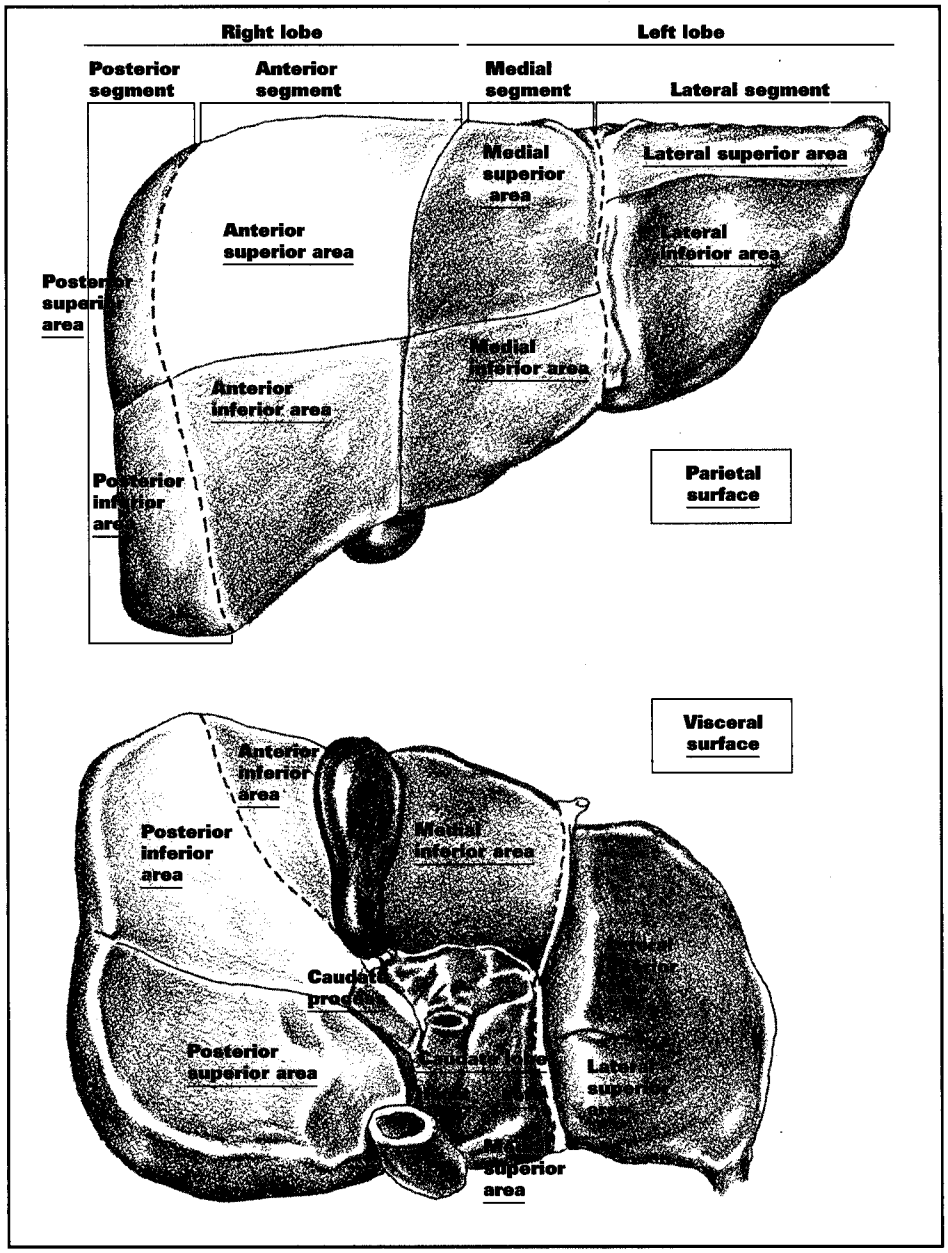

Figure 1—The lobes, segments, and areas of the liver's parietal and visceral surfaces. The liver is the largest gland in the body and is a metabolic powerhouse; however, metabolic activity renders the liver a common site for diseases, many of which require surgical intervention.

artery include the right gastric and the right and left hepatic arteries. The right hepatic artery usually passes behind the common hepatic duct to the right end of the liver hilum, where it branches to enter the right lobe of the liver. The left hepatic artery is longer and smaller than the right, and it runs to the left end of the porta hepatis. Branches reach the caudate and, occasionally, the quadrate lobe. (Figure 2 on page 33 shows the anatomical variations of the hepatic arteries.) Venous drainage is accomplished through short hepatic veins that open into the inferior vena cava.[1]

The portal vein carries blood to the liver from the gastrointestinal tract and typically follows the same distribution as the arteries in the liver. The portal blood contains products of digestion that serve as the raw chemical materials on which the liver acts. Approximately 1.45 L of blood per minute flow through the liver via a portal vein entrance and a hepatic vein exit. Cirrhosis causes blockage of the portal vein system. In the normal liver, total blood volume is 450 ml, equaling 10% of the total blood volume in the body. High pressure in the heart's right atrium causes backup pressure in the liver, which can expand as much as 1 L under some conditions. Increased liver pressure can cause fluid transudation from the liver and portal capillaries, leading to a condition known as ascites.[1,3,4] Figure 3 on page 34 shows liver vessel and duct distribution.

Bile ducts follow the distribution of the arteries and portal vein. However, the hepatic bile ducts do not cross the division between the liver's right and left lobes. Exiting from the liver, the right and left hepatic ducts join to form the common hepatic duct. The common hepatic and cystic ducts then meet to form the common bile duct that empties into the duodenum.[1]

The functional unit of the liver—the lobule—was mentioned previously. The human liver consists of between 50,000 and 100,000 individual lobules. Each lobule is cylindrical in structure, several millimeters in length, and between 0.8 mm and 2 mm in diameter. Each lobule surrounds a central vein that empties into a hepatic vein. Lobules are composed of hepatic cellular plates radiating from the central vein. Each hepatic plate is one or two cells thick, with small bile canaliculi separating the adjacent cells. These bile canaliculi empty into bile ducts, which lie in the fibrous septa that separate the lobules. The fibrous septa also contain portal venules and hepatic arterioles. The

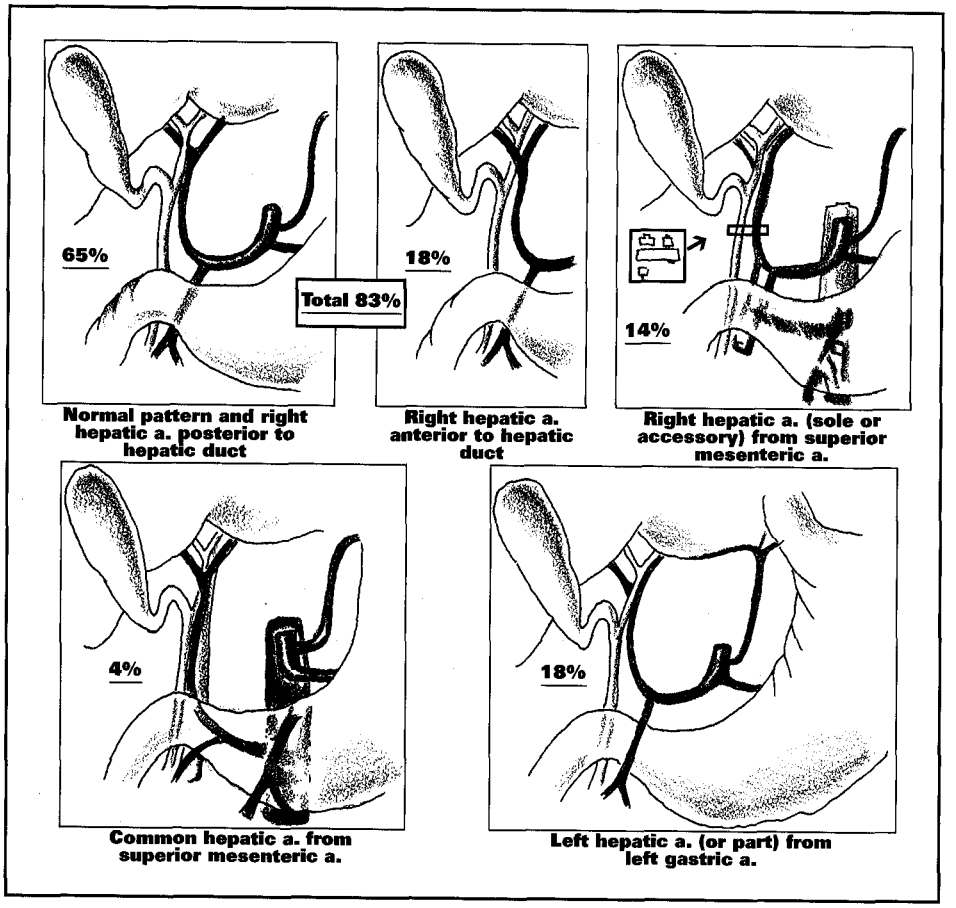

Figure 2—The anatomical variations in hepatic arteries, and the occurrence of each variation (expressed in percentage) in the general population.

Table 1

METABOLIC FUNCTIONS OF THE LIVER	
Carbohydrate Metabolism	1. Storage of glycogen 2. Conversion of galactose and fructose to glycose 3. Gluconeogenesis 4. Formation of chemical compounds from carbohydrate metabolism
Fat Metabolism	1. Oxidation of fatty acids 2. Formation of most of the lipoproteins 3. Synthesis of cholesterol and phospholipids 4. Conversion of carbohydrates and proteins to fat
Protein Metabolism	1. Deamination of amino acids 2. Formation of urea 3. Formation of plasma proteins 4. Interconversions among amino acids
Storage of Vitamins	A, D, and B_{12}

portal venules supply the liver cells with a continuous supply of portal venous blood. The hepatic arterioles supply the septal tissues with blood.[2] Figure 4 on page 34 shows the structure of the liver lobule.

The liver is a metabolic powerhouse; however, metabolic activity makes the liver a common site for diseases, many of which require surgical intervention. Surgery of the biliary system and the liver is the most common in the US. The liver's metabolic functions are summarized in Table 1.[2]

Pathologic conditions of the liver include portal hypertension, with its attendant hemorrhage of esophageal varices. Viral hepatitis (A, B, and D) is a systemic disease that primarily affects the liver (see the feature CE article in this issue). Cirrhosis, a leading cause of death in the US, is an inflammatory disease of the liver that is often associated with alcohol abuse. Cirrhosis is categorized according to cause: alcoholic, Laennec's, portal, fatty, biliary, postnecrotic, and metabolic cirrhosis. The liver is also subject to abscesses, neoplasms, and cysts. Benign liver tumors include hemangiomas, hepatic adenomas, or focal nodular hyperplasia. Metastatic lesions, which are common to the liver, are found in other organs in approximately 95% of patients who have metastatic liver lesions.[3,4] ▲

REFERENCES

1. Woodburne RT, Burkel WE. *Essentials of Human Anatomy*. 8th ed. New York, NY: Oxford University Press; 1988.
2. Guyton AC. *Textbook of Medical Physiology*. 8th ed. Philadelphia, Pa: W.B. Saunders Co; 1991.
3. Lawrence PF. *Essentials of General Surgery*. 2nd ed. Baltimore, Md: Williams and Wilkins; 1992:303-314.

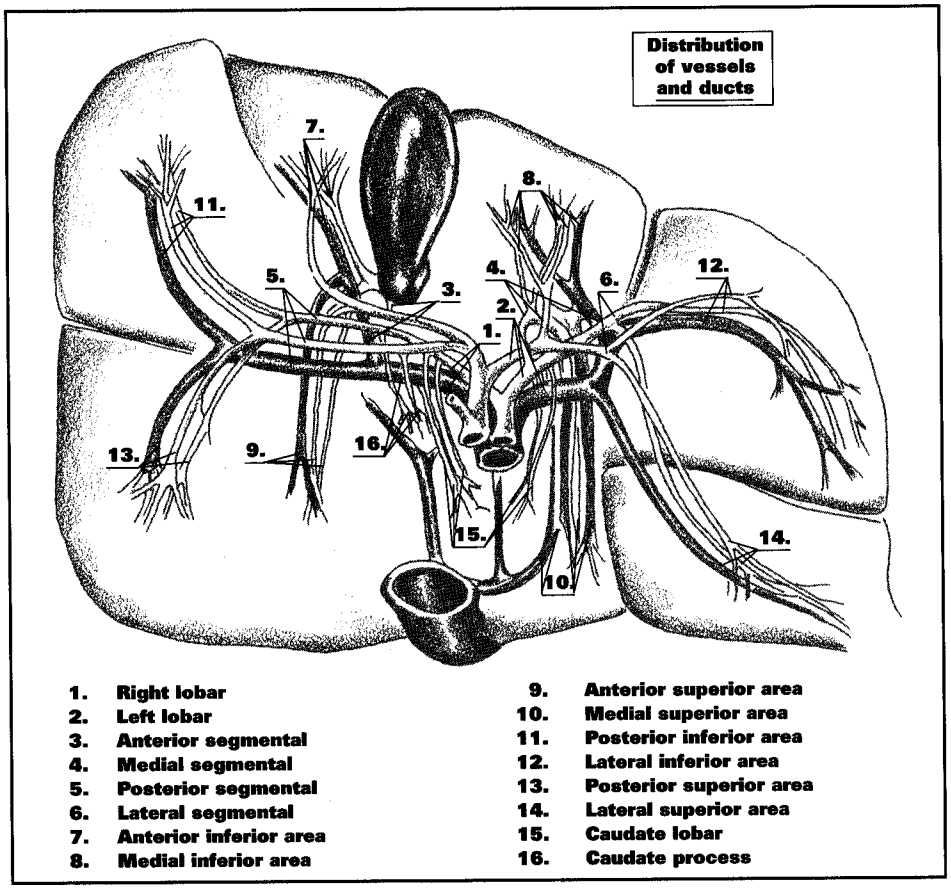

Figure 3—The distribution of hepatic vessels and ducts. Increased liver pressure resulting from pathological conditions can cause fluid transudation from the liver and portal capillaries, leading to the development of ascites.

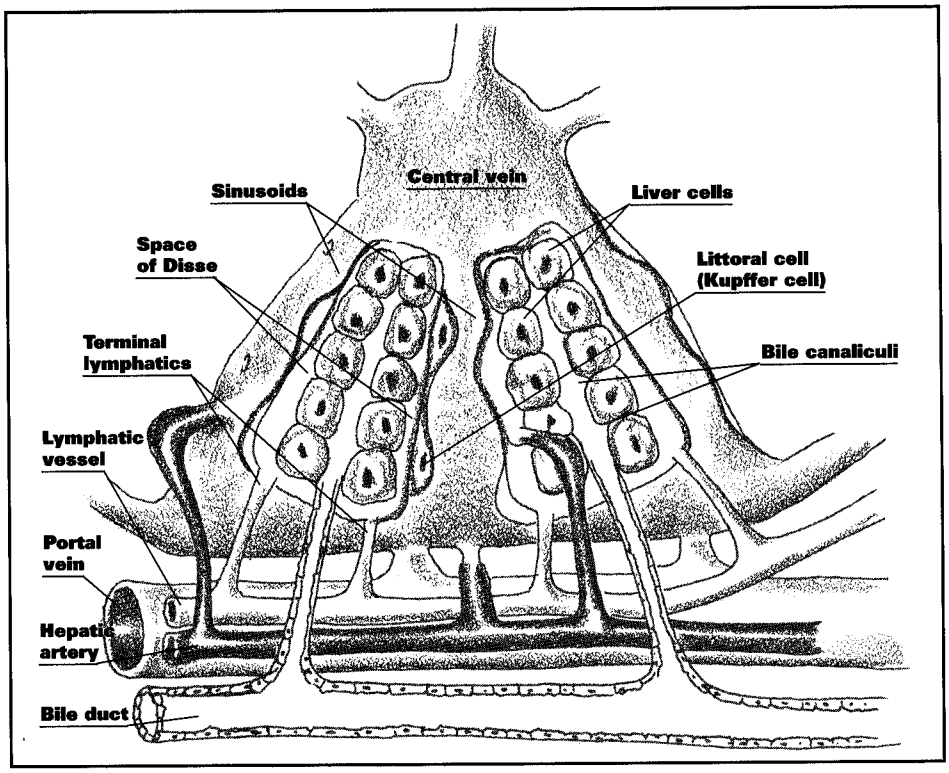

Figure 4—The structure of the lobule, which is the functional unit of the liver. Between 50,000 and 100,000 individual lobules are contained within the human liver.

4. McCance KL, Huether SE. *Pathophysiology: The Biologic Basis for Disease in Adults and Children*. St. Louis, Mo: C.V. Mosby Co; 1990:1238-1265.