CE Examination
Category 3

The Vagus Nerve

Bob Caruthers, CST, PhD

INTRODUCTION TO CRANIAL NERVES

There are 12 pairs of cranial nerves. They are commonly referred to by name or by number. Two of the 12 pair, the olfactory peduncle and the optic nerve, are not true nerves but neural fiber tracts. The spinal accessory nerve is partially derived from the upper cervical segments of the spinal cord. The nine other pair are directly related to the brainstem—midbrain, pons or medulla. Typically, the cranial nerve is related to the brain stem level at which the nerve emerges from or enters the brain stem. The efferent motor fibers of the cranial nerves arise from groups of motor nuclei lying deep within the brain stem. These motor nuclei are homologs to the anterior horn cells of the spinal cord. The afferent sensory fibers of the cranial nerves find their cells of origin outside the brain stem. The cells of origin are typically ganglia that are homologs to the dorsal root ganglia of the spinal nerves. In this case, secondary sensory nuclei lie within the brain stem. The cranial nerves with parasympathetic function are the oculomotor, facial, glossopharyngeal and vagus.[2,3,5]

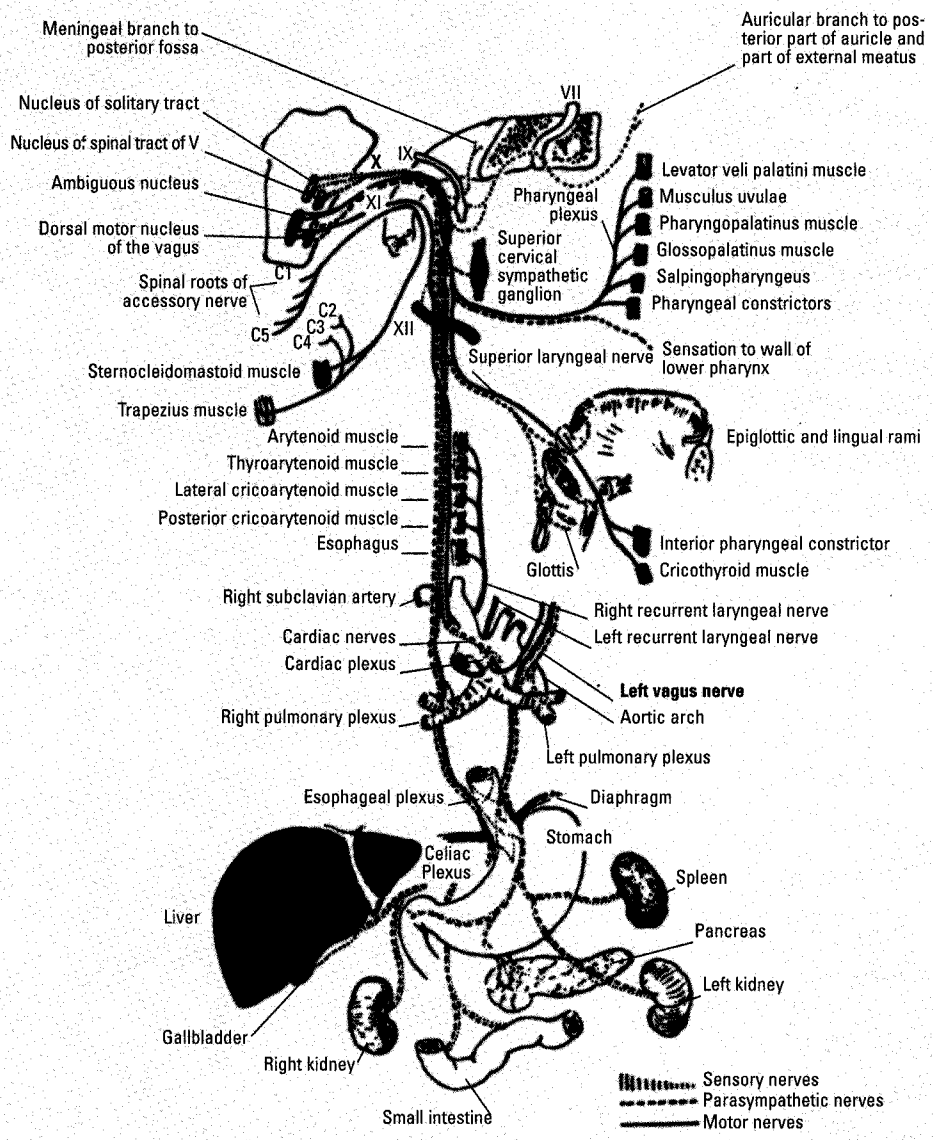

FIGURE 1—The components of the functional anatomy of the vagus nerve are complex.

In total, there are six types of nerve fibers, three efferent and three afferent types, responsible for the functional component of the cranial nerves. Somatic efferent fibers innervate somatic striated muscles that contribute to movement of the eyes and tongue. Branchial or special visceral efferent fibers are also somatic efferent fibers. These fibers innervate muscles that evolved from the gill (branchial) arches and contribute to facial expression, chewing, swallowing, turning the head and sound production. Visceral efferent fibers are preganglionic parasympathetic parts of the cranial division. These fibers innervate the smooth muscles of the inner eye, salivatory and lacrimal glands, the parotid gland and muscles of the heart, lung and bowel involved with movement and secretion. Visceral afferent fibers carry impulses from the heart, vessels, lungs, alimentary tract and tongue (taste). Somatic afferent fibers carry sensation impulses from the skin and mucous membranes of the head. Special sensory fibers are found in some nerves and are involved with smell, vision, hearing and equilibrium. The fiber types that exist in each cranial nerve are specified in Table 1. Depending on the types of fibers contained in a cranial nerve, it may be purely motor, purely sensory, or a mixture of functions. The mixed nerves, with the exception of the Trochlear nerve, all exit the brain stem from a ventral or ventrolateral position.[2,3,5]

The cranial nerves are important to neurological diagnosis. Because the origin, passage and function of each nerve is known, clinical changes reflect specific pathologies. This article will take a more in-depth look at one of the 12 pairs of cranial nerves, the vagus nerve.

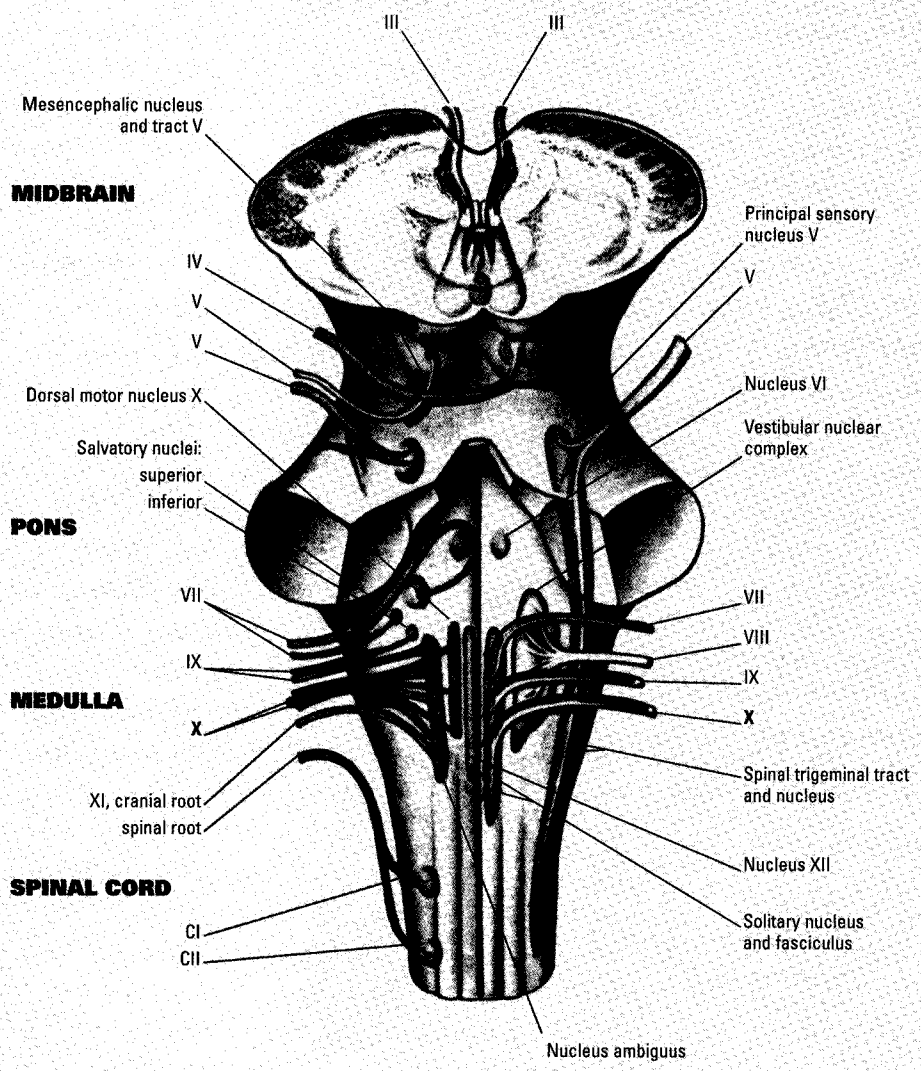

FIGURE 2—A view of the cranial nerves showing their nuclei of origin and termination and their course through the medulla. Note nerve X, the vagus nerve.

THE VAGUS NERVE

Basic Anatomy

The vagus nerve is a complex mixed cranial nerve. It contains branchial efferent, visceral efferent, visceral afferent and a few somatic afferent fibers (Figures 2 and 3).

The ambiguous nucleus is a column of visceral efferent motor cells in the reticular formation, which rest in the ventrolateral portion of the medulla. The ambiguous nucleus is found approximately halfway between the spinal trigeminal nucleus and the inferior olive. The ambiguous nucleus extends from the level of the medial lemniscus decussation to the rostral third of the inferior olive and is comprised of multipolar lower motor neurons. The ambiguous nucleus contributes motor fibers via the glossopharyngeal, bulbar accessory and vagus nerves. The ambiguous nucleus has both cortical and reflex connections. Cortical connections occur with the corticobulbar tract. The reflex connections are from the extrapyramidal and

tectobulbar tracts and with the nucleus of the solitary tract. The corticobulbar tract is the part of the pyramidal tract that descends to and terminates in the motor nuclei of the brain stem. The fibers of the tectobulbar tract originate and travel with the fibers of the medial tectospinal tract. However, the tectobulbar fibers supply the motor nuclei within the brain stem. The tectum is the so-called roof of the midbrain, and it is comprised of the superior and inferior colliculi. The superior and inferior colliculi exist as a rounded elevation on the dorsal surface of the midbrain that lies in the caudal portion of the tectum on either side of the midline. The inferior colliculus is associated with the auditory system. The tectobulbar system is part of cranial parasympathetic system. The neurotransmitter for this system is acetylcholine. The extra pyramidal system consists of neurons that arise in the cortex and terminate in the motor nuclei of the brain stem and spinal cord. Neurons in this system usually have synapses with the basal ganglia.[1,2,3,4]

Visceral afferent fibers from the vagus, glossopharyngeal and the intermediate branch of the facial nerve contribute to the solitary fasciculus. Fibers conveying gustatory information from the anterior two-thirds of the tongue (chorda tympani) and from the poster one-third of the tongue (glossopharyngeal nerve) enter rostral segments of the solitary fasciculus and terminate in rostral portions of the solitary nucleus. The solitary nucleus is itself subdivided into two parts. The medial portion lies dorsolateral to the dorsal motor nucleus of the vagus nerve. The medial portion of the solitary nucleus receives general

TABLE 1—Cranial Nerve Composition

NERVE	FUNCTIONAL COMPONENT	NERVE	FUNCTIONAL COMPONENT
I	SS	VII	BE, VE, VA (taste), (SA)*
II	SS	VIII	SS
III	SE, BE	IX	BE, VE, VA, (SA)*
IV	SE	X	BE, VE, VA, (SA)*
V	SA, BE	XI	BE
VI	SE	XII	SE

EFFERENT (MOTOR)	AFFERENT (SENSORY)
SE-somatic, general SE	VA-visceral, general VA, special VA
BE-branchial, special VE	SA-somatic, general SA
VE-visceral, general VE	SS-special sensory

*Most Nerves with SE components have a few SA fibers for proprioception.

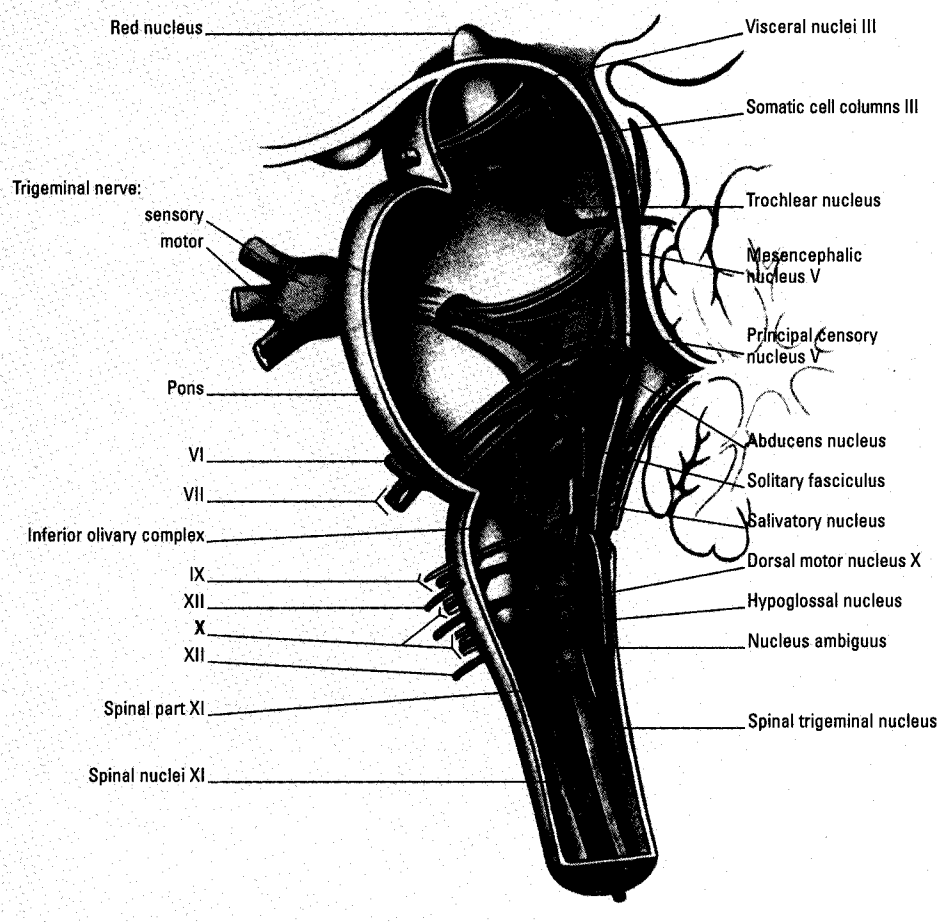

FIGURE 3—A midsagittal view of the medulla showing the intramedullary course of the cranial nerves and their nuclei.

The cranial nerves are important to neurological diagnosis. Because the origin, passage and function of each nerve is known, clinical changes reflect specific pathologies.

visceral afferent fibers. A lateral portion is found along the lateral edge of the solitary fasciculus. Cells from the medial portion extend rostrally and join the corresponding cell collum on the opposite side to form the commissural nucleus of the vagus nerve. The lateral portion surrounds and parallels the solitary fasciculus. The cells are more prominent in their rostral projection and this enlarged rostral portion of the solitary nucleus is the recipient of special visceral afferents related to taste.[1,2,3,4]

Branchial fibers arise from the ambiguous nucleus, which contributes fibers to the cranial component of the spinal accessory nerve, also. These fibers in the spinal accessory nerve exit the skull with the spinal accessory but rejoin the vagus nerve outside the skull via the recurrent laryngeal nerve. The branchial efferent fibers innervate the muscles of the soft palate, pharynx and, with the fibers from the spinal accessory, the intrinsic muscles of the larynx. Visceral efferent fibers pass to the thoracic and abdominal viscera. These pathways have postganglionic fibers arising from terminal ganglia that lie in or near the viscera innervated. Unipolar cells from the superior ganglion send fibers via the auricular branch of the vagus nerve to the external auditory meatus and portions of the earlobe and via the meningeal branch to the dura of the posterior fossa. Central branches travel with the vagus nerve to the brainstem and terminate in the spinal tract of the trigeminal nerve and its corresponding nucleus. Unipolar cells of the inferior ganglion send visceral afferent fibers to the pharynx, larynx, trachea, esophagus, and thoracic and abdominal viscera. A few special sensory fibers innervate the epiglottis and travel through the inferior ganglion to the gustatory nucleus of the brain stem.[1,2,3,4]

Other components of the functional anatomy of the vagus nerve are equally complex (Figure 1). Through the pharyngeal plexus, the levator veli palantini, musculus uvulae, pharyngopalatinus, and glossopalatinus, salpingopharyngeus and pharyngeal constrictors are innervated. The glottis, epiglottic and lingual rami, inferior pharyngeal constrictor and cricothyroid muscle are reached by fibers traveling in the superior laryngeal nerve. The recurrent laryngeal nerve supplies the arytenoid, thyroarytenoid, lateral cricoarytenoid, and posterior cricoarytenoid muscles and the esophagus. Other branches of the vagus nerve innervate the heart, pulmonary plexus, esophageal plexus, cardiac plexus, diaphragm, celiac plexus, stomach, liver, gall bladder, spleen, pancreas and small intestine.[1,2,3,4]

CLINICAL CORRELATIONS

Lesions of the vagus nerve may be found intramedullary or peripheral. Lesions affecting the vagus nerve that lie near the base of the skull often involve the glossopharyngeal and spinal accessory nerves and may involve the hypoglossal nerve. A unilateral lesion of the vagus nerve produces ipsilateral paralysis of the soft palate, pharynx and larynx. This paralysis produces hoarseness of voice, dyspnea (difficulty breathing) and dysphagia (difficulty swallowing). Bilateral lesions constitute an emergency situation. Bilateral lesions produces complete paralysis of the pharynx and larynx. Death, secondary to asphyxia, is imminent unless an emergency tracheostomy is performed. Bilateral lesions also produce paralysis atonia of the esophagus and stomach, increased and irregular heart rate, and severe dysphagia and dysarthria (disturbance of articulation of speech).[1,2,5]

BIBLIOGRAPHY

1. Carpenter, MB. *Core Text of Neuroanatomy*, 2nd edition. Williams and Wilkins: Baltimore, MD, 1978.
2. DeGroot, J. *Correlative Neuroanatomy*, 21st edition. Appleton & Lange: Norwalk, CT, 1991.
3. Guyton, AC. *Textbook of Medical Physiology*, 8th edition. WB Saunders Co.: Philadelphia, PA, 1991.
4. Purves, D, Augustine, GJ, Fitzpatrick, D, Katz, LC, LaMantia, AS and McNamara, JO. *Neuroscience*. Sinauer Associates, Inc, Pub: Sunderland, MA, 1997.
5. Snyder M. *A Guide to Neurological and Neurosurgical Nursing*, 2nd edition. Delmar Publishers Inc: Albany, NY 1991.
6. Wingard LB, Brody, TM, Larner,J and Schwartz, A. *Human Pharmacology: Molecular-to-clinical*. Mosby Year Book: St. Louis, MO, 1991.