Free Fibula Graft to the Hip for Avascular Necrosis

ARTICLE BY GAIL S. BOYD, CST/CFA

Free fibula grafting to the hip is contemplated as treatment for avascular necrosis (AVN) of the femoral head. AVN is a condition in which blood flow to the bone is restricted, causing that portion of the bone to die. Pain and decreased range of motion (ROM) may result. Although there are several methods of treatment for AVN, none is completely satisfactory or constantly successful. The purpose of this surgery is to decompress the femoral head, aid in structural stability, and place healthy, vascularized bone in the area of femoral head necrosis, thus preserving the femoral head rather than replacing it with an artificial joint.

This article will provide surgical technologists with a better understanding of the disease process of AVN as well as the free fibula vascularized grafting procedure performed as a method of treatment.

Discussion

Bone grafts revascularized by microvascular anastomosis were done as experimental studies in the early to mid 1970s.

Our facility, The Center for Hip and Knee Surgery, has been performing this procedure since October 1991. We flew to Duke University to observe James Urbaniak, MD, who started performing this procedure in 1979.

As Dr Keating's first assistant, I not only accompanied him to Duke University, but I also acquired the necessary information for our hospital to begin performing this procedure. The information included additional equipment, medications used in the procedure, instrumentation, sutures, etc. I gave inservices to all OR personnel and hospital staff nurses who would be assisting in the patients' postoperative care in the hospital.

During Dr Urbaniak's first 5 years doing free fibula grafts on 50 patients, he reported having three patients whose disease progressed enough to warrant total hip arthroplasty, and three more patients with progressive or further collapse of the femoral head.

Since we began free fibula grafts in October 1991, we have performed 14 grafts. Of these, we have revised one to a total hip (Note: the patient continued his alcohol intake postoperatively, which was the probable contributing cause for his disease). We have also had one major postoperative complication. Our patient was on his crutches 2 weeks postoperatively when he got one of his crutches tangled up in something, causing him to fall. He fractured his femur just distal to the graft insertion site. We reduced the fracture and placed a cobra-type plate and screws for fixation to try to preserve the graft. Time and future x-ray films will reveal the success or failure.

Close monitoring of all free fibula graft patients will ultimately determine the success ratio of this proce-

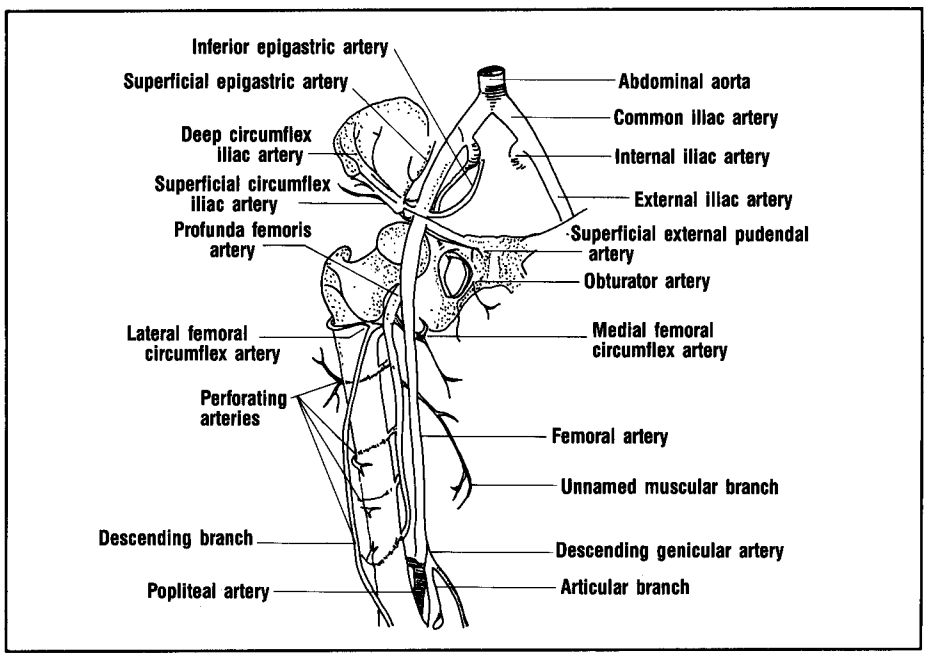

Figure 1. Hip vessels (anterior view). (Reprinted with permission from The Center for Hip & Knee Surgery, Mooresville, Indiana and adapted from: Grant JCB. *Grant's Atlas of Anatomy.* 5th ed.)

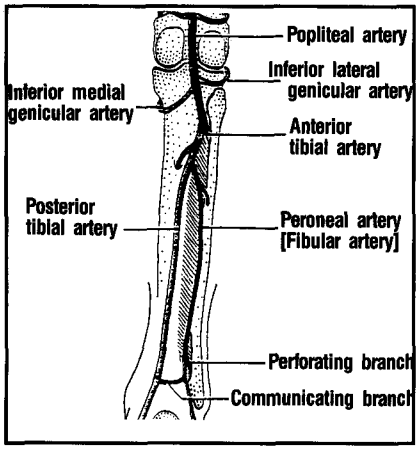

Figure 2. Fibular vessels (posterior view). (Reprinted with permission from The Center for Hip & Knee Surgery, Mooresville, Indiana and adapted from: Grant JCB. *Grant's Atlas of Anatomy.* 5th ed.)

dure. Theoretically, it seems to be the best treatment currently available and is offered to select patients with AVN of the femoral head.

Anatomy and Blood Supply
The hip joint is formed between the head of the femur and the acetabulum. The large head of the femur fits snugly into the deep acetabular socket of the coxa. Both the proximal and distal aspects of the femur are large, with the proximal head offset from the shaft and joined to it by the neck.

Blood is supplied to the femur through a branch of the obturator artery (Figure 1) that enters the femoral head through the ligament of the head of the femur and supplies a variable, but generally small, portion of the bone adjacent to the fovea.

The head and neck of the femur are supplied predominantly by branches of the medial and lateral femoral circumflex arteries (see Figure 1). These branches pass proximally along the neck of the femur, where they are tethered to the bone by the synovial portion of the joint capsule. During the grafting process, the lateral or possibly the medial femoral circumflex arteries and veins are used for anastomosis.

Although the bones of the lower leg include both the tibia and the fibula, the tibia bears nearly all of the weight transmitted from the thigh to the foot. The fibula provides muscle attachment and participates in the formation of the ankle. Blood is supplied to the fibula through the peroneal artery (Figure 2). The fibula graft is procured with the peroneal artery and veins.

Patient Selection
Patient selection for this procedure is influenced by several factors:

1. Age. Patients under 50 years of age may be considered for this procedure, whereas the treatment of choice in patients over 50 may be a total hip arthroplasty.

2. Progression of the Disease. Determining how far the disease has progressed is important in deciding the best treatment for a patient. The progression of femoral head involvement is classified in stages using the Steinberg criteria for staging avascular necrosis (Table 1). Stages II, III, and possibly early stage IV may benefit from this procedure.

3. Patient Symptoms. Patients should have pain and decreased ROM. Asymptomatic patients as of now are not generally offered this procedure.

4. Contributing Causes. Causes of this disease include alcoholism, steroid use, previous trauma to the area, or a systemic disease that involves the vascular system (eg sickle cell disease, collagen vascular disease, or Gauchers' disease). Patients with such systemic diseases would not be considered good candidates for the free fibular grafting procedure. Of the patients diagnosed with AVN of the femoral head, 20% to 25% have no history or known contributing causes.

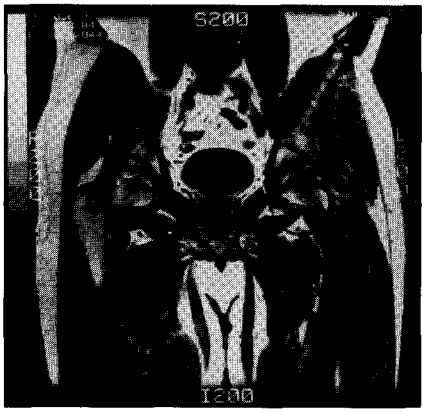

Figure 3. Magnetic resonance imaging (MRI).

Patients with steroid use as the contributing cause of their disease may have had an idiosyncratic reaction to one dose of steroids, as small as one pill from a methylprednisolone dose pak, often given for treatment of poison ivy, or one injection of cortisone for a knee or shoulder problem. High-volume steroids used in cancer treatment may also cause AVN.

In athletes diagnosed with AVN, the contributing cause of the disease is as likely to be previous trauma to the area as it is to be steroid use.

Patient Evaluation and Preparation
Magnetic resonance imaging (MRI) is done to define the extent of the

Table 1. Criteria for Staging Avascular Necrosis*

Stage	Criteria
0	Normal or nondiagnostic x-ray film, bone scan, and MRI
I	Normal x-ray film, abnormal bone scan, and/or MRI
II	Abnormal x-ray film (cystic and sclerotic changes in the femoral head without collapse)
III	Subchondral collapse (crescent sign) without flattening of articular surface
IV	Flattening of femoral head without joint narrowing or acetabular involvement
V	Joint narrowing and/or acetabular involvement
VI	Advanced degenerative changes

*Reprinted with permission from Steinberg ME, Steinberg DR. Evaluation and staging of avascular necrosis. *Seminars in Arthroplasty.* Philadelphia, Pa: WB Saunders Co; 1991; 2(No.3).

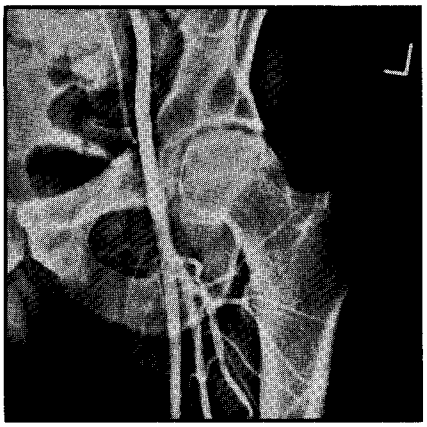

Figure 4. Hip angiogram.

involvement and changes in the femoral head, not only for the hip displaying symptoms, but for the other hip as well, since there is at least a 50% chance that the other asymptomatic hip is already involved or will become involved in the disease process within the next few months. Involvement of the knees or shoulders has also been recorded in 10% to 15% of the patients with AVN.

MRI will reveal changes in the femoral head earlier than regular x-ray films (Figure 3), which will allow for proper staging of the disease. Angiograms are also done on the operative lower extremity because the vascular anatomy is variable in this region (Figures 4 and 5).

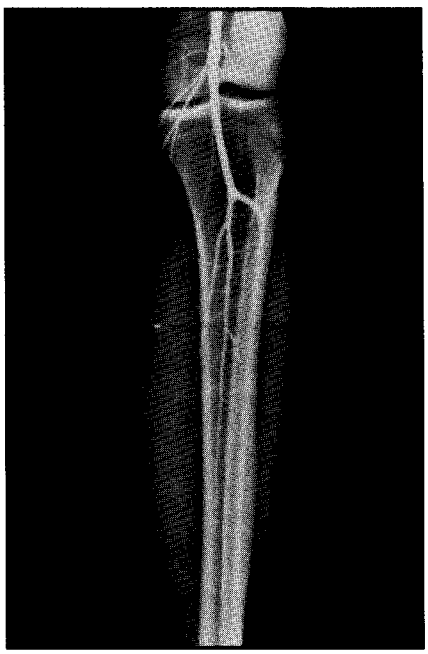

Figure 5. Lower leg angiogram.

Autologous blood donation is discussed with the patient. Approximately 80% of our surgery patients donate their own blood if postoperative transfusions are expected. Blood loss for this procedure is approximately the same as for a patient undergoing a total hip replacement. Normally, the patient donates 2 units of blood.

Patients who smoke must be advised to stop smoking during the first 3 weeks after the graft.

If alcohol is a contributing cause of disease in a patient, it must also be determined if this patient will continue to abuse alcohol. If so, the patient would be at higher risk for an unsuccessful outcome since the revascularized hip would probably suffer the same effects and would fail, requiring additional surgery (total hip replacement).

Preoperative Preparation

Operating room personnel prepare preoperatively by ensuring the necessary special equipment and drugs are available. Some of the special items required may include the following, depending on the surgeon's preference:

- C-arm radiographic imager and draping for both arms
- Custom-made reamers and ball reamers (Figure 6)
- Sterile tourniquet
- Microscope
- Headlight
- Power equipment (saws, drills, reamers)
- Vascular setup
- Major ortho setup
- Two electrosurgical machines
- Bipolar unit
- Two suction units
- UV lighting: All protective gear required (long-sleeved jackets, eyewear, sunscreen, gloves, etc). Lighting is determined by the facility or surgeon's preference.
- Heparinized saline
- Radiopaque dye/saline (50/50 mixture)
- Papaverine
- Absorbable gelatin sponge and thrombin
- 0.25% bupivacaine HCI with epinephrine

The patient is placed in the lateral decubitus position (Figure 7). Two grounding pads are placed and the patient is prepped from waistline to toes circumferentially. The patient is then draped, with the leg draped free and the foot and ankle wrapped. Steri-drapes are applied to both incision sites. A sterile tourniquet is placed just above the knee. A sterile Esmarch bandage is used to exsanguinate the leg, and the tourniquet is inflated. The C-arm is draped sterile (both ends) and brought in from the anterior side of the patient (see Figure 7). UV lights are turned on as soon as the patient is draped.

Operative Procedure

The entire procedure takes approximately 6 hours. Two surgical teams operate simultaneously during much of the case; one team will harvest the fibula graft along with the vascular pedicle, while the other team prepares the hip to receive the graft.

The most important attribute for an assistant or a scrub person during this procedure is the ability to work as a team member. Confusion may result when two to four surgeons operate on one patient at the same time. Being flexible and quick to respond to stated or unstated needs at either incision site can make a long and potentially difficult case a smooth experience for all involved.

Preparing the Hip

A Watson Jones incision is made over the hip. A tract or bed is made with careful dissection to provide protection to the vessels to be anastomosed. This tract will usually utilize the interval between the tensor fasciae latae muscle and the rectus femoris (Figure 8). With careful dissection, the lateral femoral circumflex artery and vein are identified and exposed to later serve as the anastomosis site. The lateral cortex



Figure 6. Reamers and ball tips.

Figure 7. Lateral decubitus position and fleurs.

of the femur is then perforated with a drill bit just distal to the greater trochanter. A guide wire is then passed into the femoral neck and head under fluoroscopic imaging, taking care not to penetrate the articular cartilage. With the guide pin in proper location, the special cannulated reamers (see Figure 6) are reamed over the pin, creating a core approximately 3/4 inch in diameter (depending on the patient's size). The reamers are 16 mm, 19 mm, 21 mm, or 23 mm in size. The ball-tipped reamers (see Figure 6) are then used to remove or burr out the necrosed area in the femoral head. Radiopaque dye mixed equally with injectable saline is used to check the reamed tract for the graft. After irrigating and suctioning for dye removal, cancellous bone chips, which have been saved throughout the case, are packed into the area of previously excised necrotic bone. The hip is now ready to receive the graft.

Procuring the Fibula Graft

As the hip team works, the vascular team prepares the graft. A longitudinal lateral incision is made over the midportion of the fibula. The peroneal nerve is identified and carefully retracted to prevent any damage to the nerve. The peroneal artery and vein are identified, as well as the posterior tibial artery. Approximately a 12- to 15-cm (5- to 6-inch) midthird section of the fibula is carefully dissected free. Two osteotomies are made, again identifying the peroneal artery and vein. The fibula is elevated from soft tissue, leaving little to no tissue attached to the fibula except around the vascular pedicle. The peroneal artery and vein are preserved with the graft, maintaining as long a vascular pedicle of artery and vein as can possibly be harvested (usually 4 to 6 mm) (Figure 9). Patency of the graft is checked. After the graft and vessels are dissected free, the tourniquet is deflated and the fibula graft site may be closed. During closure, 0.25% bupivacaine with epinephrine is injected subcutaneously. A drain is utilized.

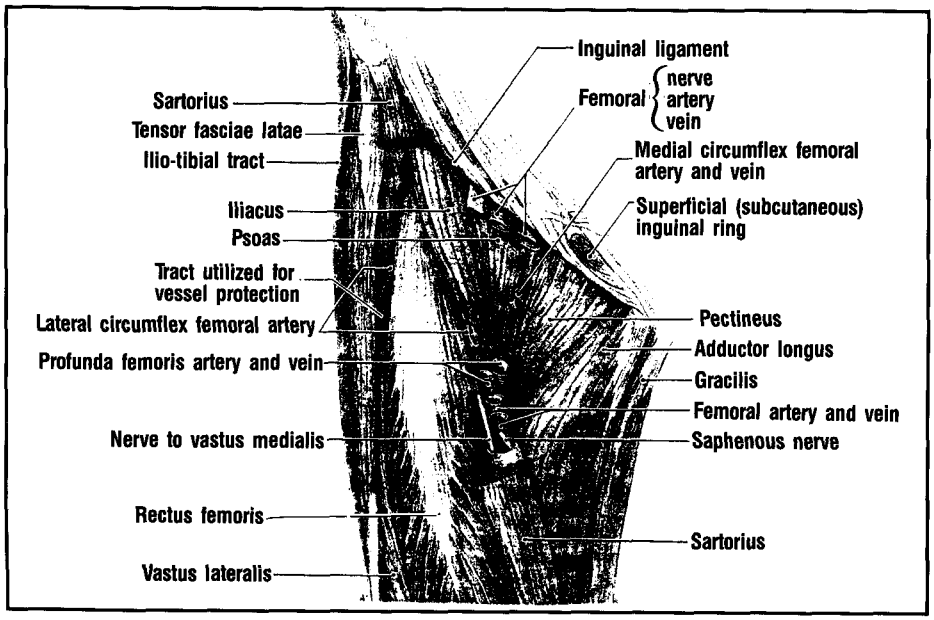

Figure 8. Muscularature of the hip. (Reprinted with permission from The Center for Hip & Knee Surgery, Mooresville, Indiana and adapted from: Grant JCB. *Grant's Atlas of Anatomy.* 5th ed.)



Figure 9. Fibular graft.

Graft Placement and Anastomosis

The fibula with its vascular pedicle is trimmed to appropriate length. A notch may be taken from the cortex of the femur with a rongeur and smoothed at the graft insertion site if needed to prevent any compression of the vascular pedicle. With the use of fluoroscopic imaging, the graft is inserted and a .062 K-wire is placed through the graft and proximal femur to prevent migration of the graft, as can be seen in postoperative films (Figure 10).

The microscope is then brought into the field. The UV lights are turned off to protect the surgeons' eyes who are using the microscope. An end-to-end anastomosis is performed between the peroneal vessels and branches of the femoral circumflex vessels using the operating microscope and usually 9-0 nylon suture. After anastomosis is complete, the peroneal artery should pulsate and the fibula graft should bleed, indicating a successful and patent anastomosis.

The hip wound is then ready for closure. A drain is optional. During closure, 0.25% bupivacaine HCI with epinephrine is injected subcutaneously.

Complications

As in any surgical procedure, the possibility of complications exists. Possible complications for this procedure include the following:

1. Penetration of the femoral head or neck during reaming.

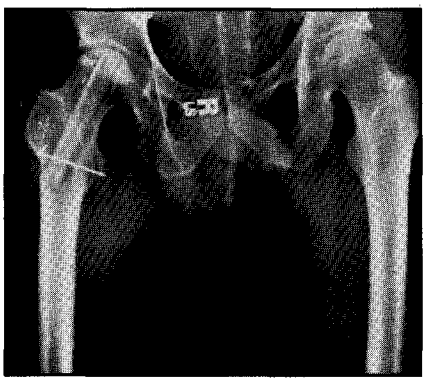

Figure 10. Postoperative x-ray film showing k-wire.

Penetration should be avoided because of the use of fluoroscopic imaging during the reaming.

2. Infection. Postoperative infection may be treated with antibiotics; however, good sterile technique, the use of prophylactic antibiotics, and the use of UV lights should eliminate most infection.

3. Femoral fractures at distal graft insertion site. Fractures should only occur as a result of a trauma (ie, a fall or a physical blow) to insertion site, due to changed structural integrity of the bones following surgical procedure.

4. Deep vein thrombosis. This is due to length of procedure and manipulation of vascular structures in the leg.

5. Wound breakdown. Wound breakdown could be caused by disruption of blood supply after resection of peroneal artery and vein.

6. Peroneal nerve injury. Injury occurs when nerve is stretched, roughened, or lacerated during surgery. Nerve damage should be avoided by careful protection throughout the case.

Dressings

A regular hip dressing is used. The patient's entire extremity is wrapped with elastic bandages and a knee immobilizer, and a space boot (a type of short leg splint) (Figure 11) is applied.

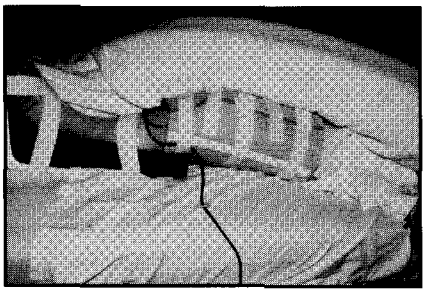

Figure 11. Postoperative dressings.

Postoperative Care

Low molecular weight dextran, 40 mg is given, 500 cc in 8 hours, for 5 days postoperatively to help prevent deep vein thrombosis. The patient is hospitalized for approximately 7 days and is seen 3 weeks postoperatively (2 weeks after hospital discharge) in the office. The patient is seen again at 3 months, 6 months, 1 year, and every 2 years thereafter for x-ray films and examination. The patient is foot-flat weightbearing on the affected hip for at least 3 months postoperatively and then full weightbearing is attained gradually.

Summary

A free fibula graft consists of removing dead bone with a lack of blood supply from the hip and replacing it with healthy vascularized bone from the lower leg (Figure 12). It is hoped that this procedure will prevent the necrosis of the femoral head from progressing to the point of collapse and will restore vascularization and new bone formation. Δ

Acknowledgments

The author would like to thank E. Michael Keating, MD, for his assistance with this article, and Linda Clem, Mary Ann McDaniel, and Carol Hubbard for their help with typing and illustrations.

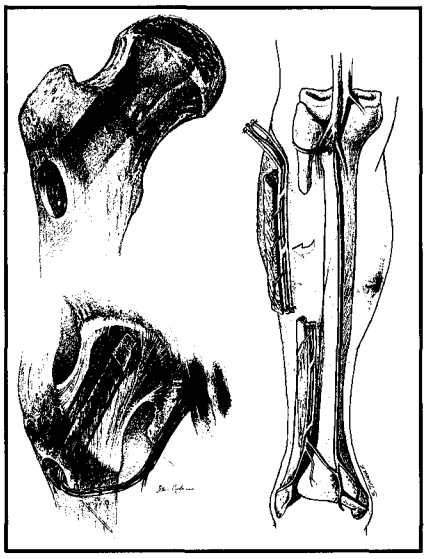

Figure 12. Location of fibular removal and graft to the hip. (Reproduced from Urbaniak JR, MD. *Free Vascularized Fibular Graft for Avascular Necrosis of the Hip.* Durham, NC: Duke University Medical Center.)

Bibliography

Grant JCB. *Grant's Atlas of Anatomy.* 5th ed. Baltimore, Md: Williams and Wilkins Co; 1962.

Ostrup LT, Fredrickson TM. Distant transfer of a free, living bone graft by microvascular anastomosis: An experimental study. *Plast Reconstr Surg.* 1974;52:274-285.

Richards RR. Bone grafting with microvascular anastomosis in osteonecrosis of the femoral head. *Seminars in Arthroplasty.* Philadelphia, Pa: WB Saunders Co; 1991;2(No. 3).

Steinberg ME, Haykem GD, Steinberg DR. A new method for evaluating and staging of avascular necrosis of the femoral head. In: Arlet J, Picat P, Hungerford DS, eds. *Bone Circulation.* Baltimore, Md: Williams and Wilkins Co; 1984.

Steinberg ME, Steinberg DR. Evaluation and staging of avascular necrosis. *Seminars in Arthroplasty.* Philadelphia, Pa: WB Saunders Co; 1991;2(No. 3).

Taylor GI, Miller GDH, Ham FJ. The free vascularized bone graft. A clinical extension of microsurgical techniques. *Plast Reconstr Surg.* 1975;55:533.

Urbaniak JR, ed. Aseptic necrosis of the femoral head treated by vascularized fibula graft. *Microsurgery for Major Limb Reconstruction.* St Louis, Mo: Mosby; 1987.

Urbaniak JR. Avascular necrosis of the femoral head treated by vascularized fibula graft. Orthopaedic Transactions. *J Bone Joint Surg Am;* 1985.

Yoo MC, Chung DW, Hahn CS. Free vascularized fibula grafting for the treatment of osteonecrosis of the femoral head. *Clin Orthop.* Philadelphia, Pa: JB Lippincott Co; 1992; 277.

Gail S. Boyd, CST/CFA, *has been a CST since 1985 and worked in a hospital operating room for 5 years. For the last 2-1/2 years she has been employed as a private assistant for E. Michael Keating, MD, an orthopedic surgeon at The Center for Hip & Knee Surgery in Mooresville, Indiana.*