Meniscal Repair in the Knee

ARTICLE BY GARY J. ALLEN, CST

This article is intended as an overview of a procedure that is rapidly gaining popularity within the orthopedic community: meniscal repair in the knee. In the course of this presentation, the following will be discussed: relevant anatomy, types of meniscal injuries, considerations for repair, the patient's interoperative experience, repair techniques, complications, and rehabilitation. Although meniscal repair is commonly performed in conjunction with reconstruction of the anterior cruciate ligament, the latter will not be discussed. A general knowledge of anatomy, arthroscopy, and medical terminology is assumed of the reader.

The relatively brief history of the arthroscope has proven it to be an invaluable tool, and its application to many techniques involving the knee are well documented. With its limited intervention, arthroscopy has virtually replaced open arthrotomy for the resection of damaged menisci and is now being employed to repair, rather than remove, the fibrocartilage in the hopes of maintaining the integrity of the joint. This conservative approach is gaining recognition and is indicative of the dynamic nature of surgery, of which surgical technologists should be aware.

Historical Background

Prior to the advent of arthroscopy in 1975, the standard treatment of meniscal injuries entailed open arthrotomy and total menisectomy. This approach was rationalized by the belief that meniscal tissue, like the appendix, was an evolutionary remnant, presumably of muscular origin, which served no function. Its excision, therefore, was regarded as proper therapy. It was not until 1948 when W. Fairbanks reported poor results following total menisectomies that this avenue of thought began to change.[1]

The arthroscope provided excellent diagnostics without extensive surgical intervention. Its versatility was immediately evident and concurrent developments in prosthetics drew attention to the importance of the menisci's design. Early arthroscopic techniques focused on simple procedures (eg, removing loose bodies, resecting meniscal cartilage, and releasing constraining ligaments), but in the past decade attention has turned to more complicated tasks, such as anterior ligament reconstruction. Today, this continuing trend includes repair of damaged menisci.

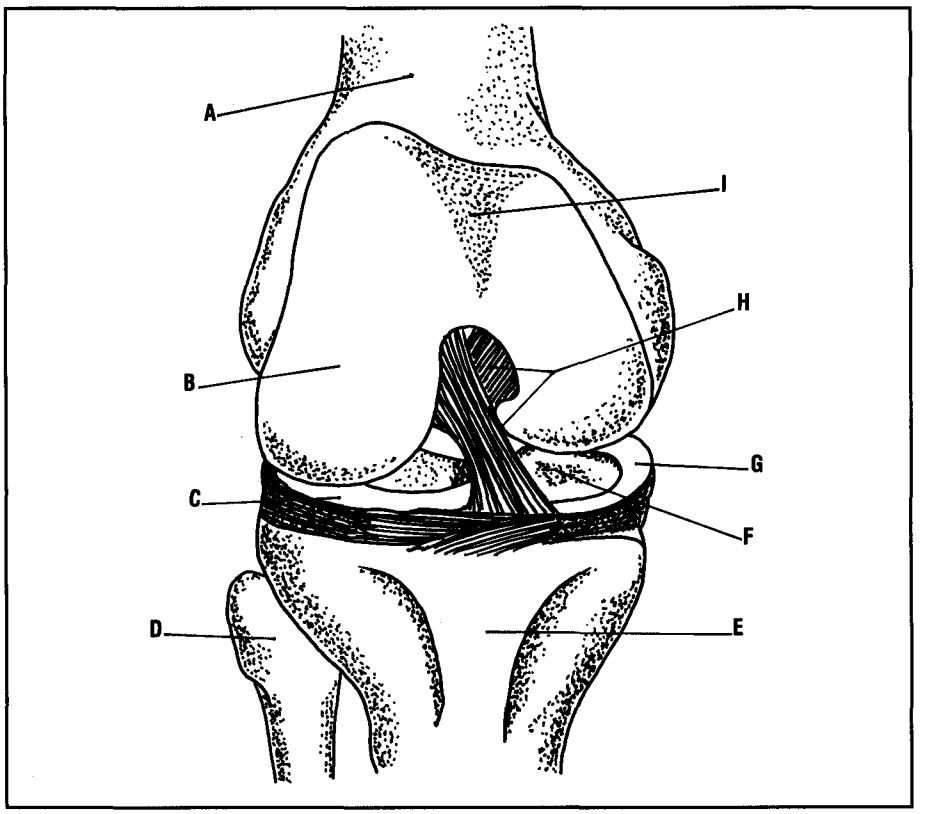

Figure 1. Anterior view of knee (patella removed). **A**, Femur; **B**, Femoral articular surface; **C**, Lateral meniscus; **D**, Fibula (extra-articular); **E**, Tibia; **F**, Tibial articular surface; **G**, Medial meniscus; **H**, Cruciate ligaments; and **I**, Patellar surface.

Anatomy of the Knee
The knee, or tibiofemoral joint, is the largest articulation in the body and is a hinge-type joint that allows for movement along a single plane. The knee's role in weight-bearing subjects it to a considerable amount of stress, and aberrant motion will frequently cause injury to the joint's supportive structures.

Bones. The convex surfaces of the medial and lateral femoral condyles sit upon the somewhat flat surface of the tibial plateau, forming two compartments that are separated by the tibial spine (intercondylar eminence). Likewise, the convex undersurface of the patella glides over a slight concavity in the anterior femur (patellar surface). This interaction results in the creation of three joint surfaces: the lateral tibiofemoral, the medial tibiofemoral, and the intermediate patellofemoral.[2]

Soft Tissues. Strength and stability in the knee are conferred by ligaments and tendons that join the tibia and femur medially, laterally, and posteriorly and the patella anteriorly. A thick capsule, lying inferior to these structures, is lined with a soft, vascular synovium. The synovium gives rise to the menisci, which will be discussed shortly, and also produces fluid that nourishes and lubricates the internal structures. The cruciate ligaments (anterior and posterior) insert along the tibiofemoral midline. Their "X" configuration controls the femoral "rollback" on the tibia surface, lending primary joint stability (Figure 1).

Menisci. The two menisci are fibrocartilagenous structures that are contiguous with the synovium and lie between the femur and tibia. Crescent-shaped to follow the outer curve of the tibial plateau, these pads lie medial and lateral to the tibial spine.[2] There are boney attachments to the midline of the tibia at the anterior and posterior poles (Figure 2). In cross-section, each meniscus looks like a wedge, with its base lying at the synovial junction and a sharp inner edge forming the apex. A normal meniscus is whitish-yellow, smooth in texture, fibrous, and pliant. Its blood supply, the extent of which is an important consideration in meniscal repair, is mainly dependent upon the synovium.[3]

Meniscal Function
The meniscal "remnant theory" was first disputed by A. Fick, in 1910, who perceived that the menisci provided joint stability.[1] In 1936, D. King supported this view with experiments on canine menisci that displayed measurable protection from articular cartilage degeneration.[3] He also proposed that there was both a lubricating and shock absorption quality to the meniscus.[3]

Prosthetic trials in the 1970s showed that the menisci give stability to the joint by maintaining the position of the femur atop the tibia. This was evidenced by the failure of early implants, which mimicked the flatness of the tibial plateau, to retain knee integrity. Under load the femur was inclined to slide across the tibia (shear) and rapid surface breakdown occurred. Once the wedge shape of the meniscus was incorporated into the design of the plastic tibial insert the full value of joint replacement was appreciated.

Today it is acknowledged that the menisci perform all of these functions, as well as the redirection of femoral pressure upon the tibia.[1] Known as "hoop stress," this pressure acts upon the knee much like the contents of a barrel does upon its staves. Barrel hoops maintain an equilibrium, so a break in one results in an uneven displacement of pressure and a bulging of the underlying stave in response. The menisci act like the hoop and ensure an even, radial distribution of femoral pressure. This lessens the impact upon and the consequent wear of the tibia.

Meniscal Tears
Meniscal tears are caused by a tibiofemoral interaction that results in shearing and compression.[2] Examples of such movement are rotation and femoral subluxation, which are both exhibited during sports-related activities. Tears may be of partial thickness or extend through both its superior (femoral) and inferior (tibial) surfaces. Tears within the peripheral third of the meniscus are more likely to heal due to the excellent vascularity in that area. Another factor to consider prior to initiating repair is the type of defect.

Radial. Radial tears are divisions of the meniscal fibers on a perpendicular or vertical plane and generally arise from the tapered edge and extend towards the periphery (Figure 3, A). Repair of these defects is not common; however, attempts have been made to reunite the ends in an effort to retain meniscal integrity rather than subject the joint to cushioning loss.

Horizontal. These tears develop along a horizontal plane and give the appearance of meniscal layering called "fish mouthing" (Figure 3, B).[4] Horizontal tears are treated by resecting flagellate tissue and abrading between the layers to encourage healing.

Longitudinal. Referred to as "bucket handles," these tears arise

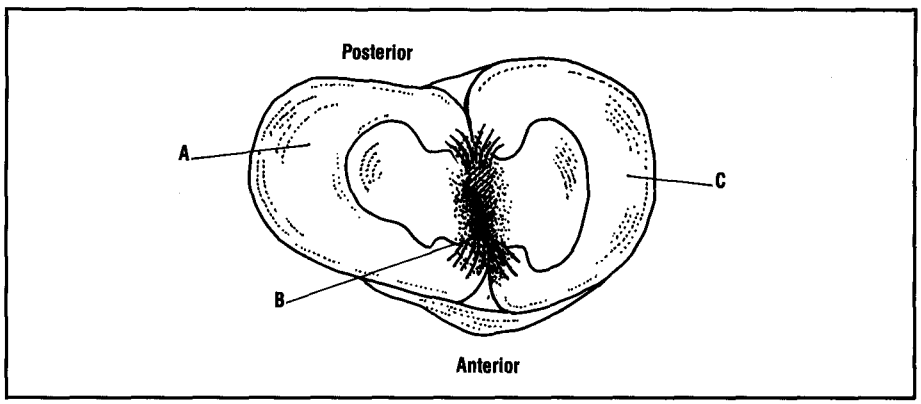

Figure 2. Superior view of tibia. (Note anterior and posterior attachments.) **A**, Lateral meniscus; **B**, Intercondylar eminence; **C**, Medial meniscus.

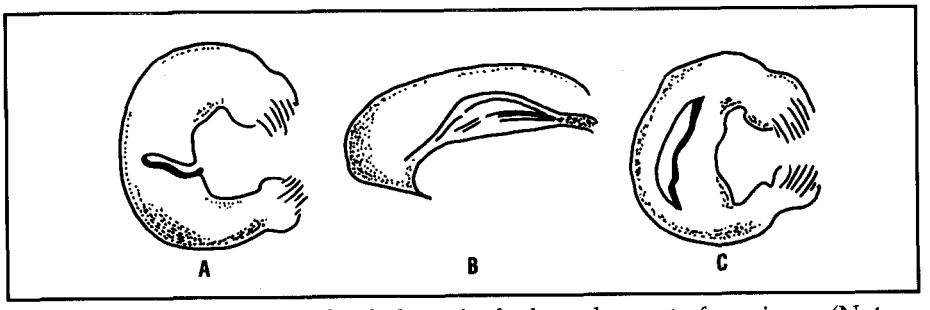

Figure 3. A, Superior view of radial tear in the lateral aspect of meniscus. (Note defect's perpendicular plane.) **B**, Anterior view of horizontal posterior horn tear demonstrating "fishmouthing" effect; and **C**, Superior view of longitudinal tear of posterolateral aspect of meniscus demonstrating "bucket handle" effect.

along the curve of the meniscus and separate rather than divide the fibrocartilagenous fibers (Figure 3, C).[4] This condition and their usual proximity to the nourishing synovium make these tears the best candidates for arthroscopic suturing techniques.

Due to shearing and the menisci's configuration, medial compartment tears are predominantly longitudinal, whereas those in the lateral compartment are usually radial.[5]

Indications for Repair

Clinical indications suggest that damaged menisci that cannot be left alone (as seen with short radial or partial thickness tears) or repaired should be prudently resected to lessen the impact of its loss on the joint. Otherwise suturable defects that exhibit tissue loss or further deformity due to wear are also treated in this manner. The age of the tear is not a major consideration in regard to healing; however, its long-term effect upon the articular cartilage is a concern.

Although open repairs were first documented by T. Annadale in 1885 and have been vigorously attempted since 1976, the arthroscopic technique has only gained popularity since the mid-1980s.[3] Longitudinal defects greater than 7 mm can usually be treated arthroscopically, unless occurring in the anterior portion of the meniscus. This area's location creates a technical challenge that is best solved by arthrotomy since ideal arthroscopic suturing requires perpendicular traction.

Diagnosis

The patient generally exhibits pain in the lateral or medial aspect of the knee, corresponding to the damaged meniscus, accompanied by tightness or clicking within the joint upon flexion. Swelling may also be present due to the synovial response to injury. The use of magnetic resonance imaging (MRI) makes effective diagnosis awkward, as it may interpret a natural wrinkle in the meniscus as a tear. The once popular arthrography is now rarely used.

Arthroscopic Meniscal Repair

For this discussion, a longitudinal tear in the peripheral posterior horn of the right medial meniscus is assumed to exist.

Preoperative Preparation. Preoperative protocol for arthroscopic meniscal repair follows the same format as arthroscopy including same-day admittance, charting, and site preparation, followed by transfer to the operating room. There the patient is placed in the supine position and inducted with general anesthesia.

A tourniquet is applied to the right thigh and a leg holder is secured to the frame of the table and placed against the extremity at a point adjacent to the pneumatic cuff. This acts as a fulcrum against which the leg is manipulated to open the knee's medial and lateral compartments for proper examination.

The entire extremity is prepped and draped free both to facilitate repair and to decrease contamination. All required lines (light cord, in-/out-flow tubings, monitor camera, electrodriven chondrotome, and cautery) are secured to the field and joined to their respective equipment. One device, a pump, can regulate both irrigant flow and internal joint pressure, an asset in arthroscopy because good visualization is essential. Steady flow keeps the distention medium clear and pressure monitoring helps reduce tissue extravasation.

Arthroscopic Examination. A thorough arthroscopic examination is made of the knee to assess the suspect tear and inspect other tissues for damage or degeneration. When meniscal repair is anticipated, the arthroscope is usually introduced through a portal in the affected (ipsilateral) compartment, in this case the medial compartment. The probe (used to test meniscal integrity and determine a tear's extent) and repair instruments, are manipulated through a portal in the opposite (contralateral) space (lateral). Outflow is via a suprapatellar portal.

A 30° arthroscope normally provides a good anterior view of the entire joint, but a 70° lens, passed through the intercondylar notch, is best for evaluating posterior tears. A constant joint pressure of 35 mm to 40 mm of mercury is desired and, in general, tears less than 1.5 cm in length are not repaired. However, all tear surfaces, regardless of other treatment are rasped to encourage revascularization and healing.[1]

Meniscal Repair. After evaluation, the surgeon selects the appropriate repair cannula (Figure 4). The cannula is curved to accommodate the anatomic contours of the knee with fluted distal ends to provide better visualization during suturing. The proximal tip is covered with a rubber cap that allows passage of the needle yet retards irrigant loss. The curve also dictates the use of a needle that is flexible yet has a high "memory" for repeated usage. The illustrated needle (Figure 5) is reusable (one per case) and requires the use of nonabsorbable free ties. Other suturing material includes swagged-on, single-use needles that are seemingly less cost-effective.

Location of the tear in the posterior horn of the medial meniscus necessitates the creation of a posteromedial incision in order to retrieve the needle and repair sutures. The incision is 2 in long and is dissected to the fascia with particular attention

given to avoid damage to the nearby saphenous neurovascular bundle.

The surgeon inserts the repair cannula through the lateral portal and positions it against the superior surface of the inner meniscal fragment (Figure 6). The knee is now flexed to provide the proper angle and the loaded needle is passed slowly through the cannula and meniscus and into the back of the knee. A retractor is placed in the posteromedial incision to protect the nerve and serve as a stop. An assistant retrieves the needle and guides it and the nonabsorbable suture out of the joint. The cannula is then repositioned radially to a point on the meniscus 2 mm to 3 mm from where it was first placed and the other end of the strand is passed on the needle in the same manner. When both suture ends exit the wound they are tagged, and the process is repeated until enough sutures have been passed to effect a secure repair.

Ideally, the first stitch is positioned at the most anterior aspect of the tear with subsequent sutures spaced 3 mm to 4 mm apart, the last one lying at the most posterior end of the tear (Figure 7).[3] Unfortunately, tears that extend to the posterior meniscal attachment to the tibia still present a repair problem, as suture placement is limited by the neurovascular structures in this area. Proper suturing may require the use of more than one meniscal cannula to effectively bypass the tibial spine.

The distance between the insertion points of each stitch is dependent upon both the location of the tear and the overall width of the meniscus. Alternating sutures may be placed along the inferior meniscal surface, as the peripheral width allows. This technique serves to counteract the "cupping" that superior surface placement alone can exhibit. The surgeon must also avoid placing the sutures too close to the apex, as traction can result in the tapered edge curling under the inferior meniscal surface.

Once all sutures are passed, they are tied together over the fascia and the repair is inspected arthroscopically. If satisfied, the surgeon removes the arthroscope and flushes the knee with antibiotic solution. Equipment is removed from the field, and the incisions are closed and dressings applied.

Postoperative Care. After removal of the drapes, the patient is extubated and transferred to recovery, where he/she remains for about 2 hours. The knee is immobilized and crutches are provided for the patient's use. A follow-up visit is normally scheduled 7 to 10 days postoperatively.

Complications

The general complications of arthroscopy include articular damage caused by the introduction of instrumentation; infection, which is uncommon and mostly attributed to improperly sterilized equipment; burns by light cords and sterilizing solutions; and neurovascular injury, caused by injudicious portal placement. During lengthy procedures, irrigant extravasation may also occur.

Complications particular to meniscal repair are generally related to saphenous or peroneal neurovascular damage during dissection of the retrieval incision. Repair failure is usually attributed to a lack of vascularity within the tear's surfaces. Recurrence has shown to be reduced when compared with resection.

Rehabilitation

Clinical studies reveal that 80% to 90% of all repairs in the peripheral third of the meniscus are successful.[5] This is true of both open and closed approaches and is indicative of the role that vascularity plays in healing. High success rates are also due to proper rehabilitative efforts.

All patients are advised to limit activity for 4 to 6 weeks . The most important factor in healing is avoidance of full weight-bearing in flexion or squatting, as both movements put direct pressure on the meniscus. Light exercise can begin in 2 months, but strenuous motion should be avoided for up to 4 months. Meniscal healing has been observed as soon as 8 weeks postoperatively.

Other Repair Techniques

Limited meniscal vascularity has prompted the attempt to encourage vessel infiltration by drilling holes in the cartilage. Fibrin clots are also used as a means to promote healing.[5]

A method of open meniscal replacement entails cadaveric allografts. Each graft is harvested in accordance with criteria set by the American Association of Tissue Banks and includes the taking of tibial bone plugs at the anterior and posterior ends of the meniscus. Once implanted, these offer an immediate blood supply. The periphery and synovium are also



Figure 4. Concept Zone Specific™ cannula set. (Photo courtesy of Linvatec Corp, Largo, FL)

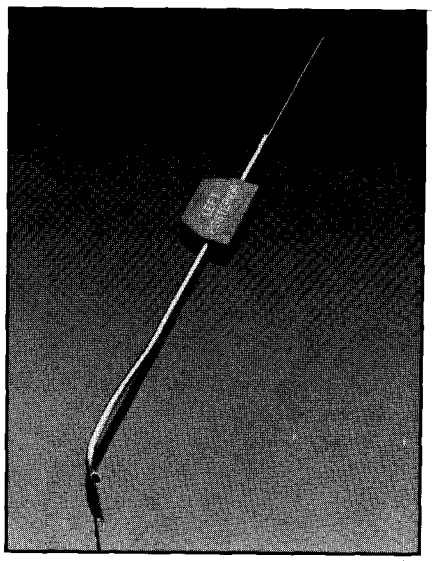

Figure 5. Flexible eye meniscal repair needle in Concept™ cannula. (Photo courtesy of Linvatec Corp, Largo, FL)

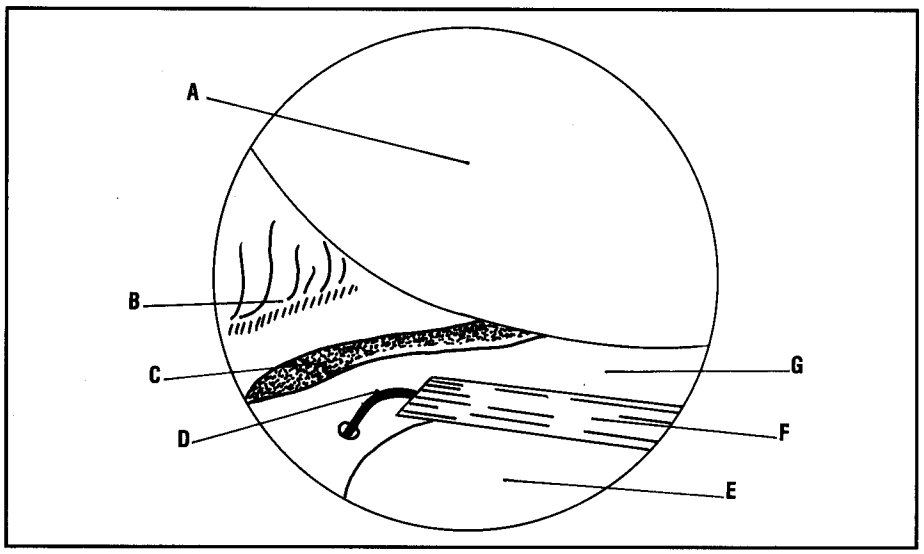

Figure 6. Arthroscopic view of cannula positioning. **A**, Medial femoral condyle; **B**, Synovial junction; **C**, Meniscal defect; **D**, Repair suture; **E**, Tibial surface; **F**, Cannula; and **G**, Medial meniscus.

abraded and sutured together. Cadaveric grafts are cryopreserved, but a fresh graft can be used within 4 to 6 hours. However, many conditions contribute to failure including rejection, infection, insufficient cellular viability, and degeneration. Results currently await compilation.[3]

Conclusion

The patient benefit derived from this approach to meniscal salvaging exceeds anything ever realized with the menisectomies of old. Likewise, patient morbidity from arthroscopy is virtually nonexistent and cosmesis is markedly improved when compared with open arthrotomy. Meniscal loss can end a sports career, as well as cause an early onset of articular degeneration. These and many other reasons warrant the effort to salvage damaged menisci.

As with any evolving surgical procedure, acceptance depends upon greater numbers of clinical applications. Although the early focus has been on tears in the peripheral third of the meniscus, recent findings indicate that healing also occurs in defects extending two-thirds of the meniscal width.[3] This is very encouraging. The surgical technologist should take note that operations similar to these ensure arthroscopy's expanding role in corrective treatments of knee injuries.Δ

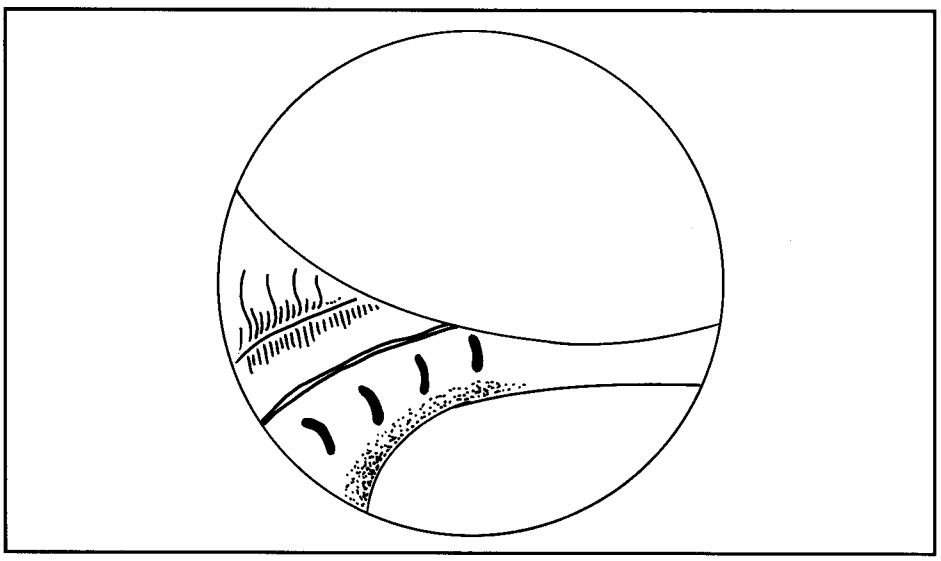

Figure 7. Arthroscopic view of repair. (Note four sutures and closed defect.)

Acknowledgements

The author gratefully acknowledges Joseph Sklar, MD, of New England Orthopaedic Surgeons, in Springfield, Massachusetts, without whose guidance and input this paper would not have been possible. He would also like to acknowledge the cooperation of Kris Gamble and Brian Salle of Linvatec Corporation, Largo, Florida, for providing photographs of and information on their Concept™ line of meniscal repair products.

References

1. Mow VC, Arnoczky SP, Jackson DW. *Knee Meniscus, Basic and Clinical Foundations.* New York: Raven Press; 1982.
2. Tortora GJ, Anagnostakos NP. *Principles of Anatomy and Physiology.* 5th ed. New York: Harper & Row Publishers; 1983.
3. Marzo J, et al. Arthroscopic meniscal repair. *Am J Knee Surg.* Fall 1991.
4. Gruendemann BJ, Meeker MH. *Alexander's Care of the Patient in Surgery.* 7th ed. St Louis, Mo: C.V. Mosby Co; 1989.
5. Rosenthal E. New repairs for torn knee cartilage. *New York Times.* November 11, 1992.



Gary Allen, CST, *is employed by Baystate Medical Center in Springfield, Massachusetts. He has been a member of AST for 7 years and earned his associate degree in surgical technology from Springfield Technical Community College. Mr Allen specializes in orthopaedic, thoracic, and vascular procedures. He won first place in this year's Writer's Award and was the third place winner in both 1990 and 1991.*