Bone Grafting in Fracture Management

ARTICLE BY GARY J. ALLEN, CST

This paper is intended as an overview of current bone grafting applications, with special attention given to fracture management, and as such assumes a certain knowledge by the reader of anatomy and medical terminology. Fracture management is one of the oldest medical concerns and was the precursor of many modern orthopedic procedures. Improper fracture management can affect one's livelihood and overall health.

The text of this article will encompass a brief history of fracture management and bone grafting, basic anatomy of bone, types of fractures, types of bone grafts, indications for and complications of bone grafts, the healing processes of bone, and alternatives to bone grafting.

Bone grafting is a frequent part of orthopedic procedures especially those involving traumatic injury. Pain relief is also frequently remedied, though in a radical manner, by bone graft incorporation in arthrodesis. In this light, surgical technologists will benefit from an understanding of the role that bone grafts play in these pursuits.

Introduction

Bone graft augmentation is used in many surgical applications, including interarticular fusion, total joint arthroplasty, and especially fracture management. Bone grafting techniques have been used with increasing frequency since the turn of the century, with an estimated 250,000 graft procedures performed each year in the United States alone.[1] In every application, however, the primary goal of graft incorporation remains the same: to promote bone healing in order to realize certain orthopedic benefits, such as the restoration of mechanical function.

History

Prior to the dawn of the modern "metallurgic age" of orthopedics, the basic concepts of bone grafting had long been established. Orthopedics itself reflects the early medical practice of treating crippled children with a regimen of rest, braces, and exercise, its name being derived from the Greek words *ortho* (straight) and *pais* (child).[2] In this regard, fracture management could be called one of the field's nourishing roots.

The earliest records concerning fracture management date to Egypt in 2500 BC, where drawings depict people walking with a form of artificial support (eg, a cane), and mummies are found with intact splints of wood and glue-impregnated linen.[2] Hippocrates wrote extensively on fracture management in his book *On Fractures*, which described traction and countertraction techniques, splinting, joint immobilization, and treatment of compound fractures.[2] Unfortunately, much of his work was either ignored or forgotten for centuries.

It was not until a renewed interest in crippling diseases of the eighteenth century that modern orthopedics began to evolve and, with the discovery of x-rays in 1895 by Wilhelm Conrad Roentgen, the visualization of bone became possible. This latter development was combined with a concurrent growth in knowledge pertaining to bone growth to create a new awareness in fracture management.

Bone grafting is one of the oldest known types of organ transplantation; the first successful bone graft is said to have been implanted in 1688.[3] In 1907, G. Axhausen performed a series of bone transplants and through them determined that the periosteum played a significant role in graft survival.[3] This was considered a crucial point, since most bone grafts prior to this time were taken without regard for the periosteal covering. However, in 1914, D. B. Phemister put forth the "creeping substitution" theory to describe the apparent phenomenon of the graft replacement by newly formed bone.[3] The acceptance of this theory as fact led to a new direction for bone grafting.

In the 1950s, Sir John Charnley, famous for the development of joint prostheses, was the first to use prophylactic bone grafts, applying such practice to the management of tibial fractures.[4] Shortly thereafter, P. R. Harrington introduced his instrumentation for holding the spine rigid during fusion. Their individual successes supported bone grafting's new place in fracture management: that of a temporary and porous agent of osteogenesis, requiring rigid fixation to accomplish its task.

In the 1960s, C. S. Venable and W. G. Stuck performed a series of tests that confirmed this thought, and it was they who are credited for advancing the idea of fixation for the sole purpose of promoting osteogenesis.[3] This new understanding in fracture management altered

the approach of many techniques and stands today as the basis for all bone graft incorporation.

Anatomy

A typical long bone (eg, femur) is not only a supportive structure and a producer of blood cells, it is also the framework of movement. Fracture management is primarily concerned with the structural importance of bone, which ultimately reflects upon its other functions. Bone also serves as a depository for mineral salts, particularly calcium carbonate and calcium phosphate (known as hydroxyapatite). The presence of these salts not only accounts for bone's hardness, but ultimately defines its difference to other connective tissues.[3]

Bone consists primarily of two components: cortical, or the hard, dense outer support structure, and cancellous, the soft, spongy matrix inside the bone that provides nourishment and has the ability to manufacture blood (Figure 1). Without the nourishing cancellous matrix, the cortical structure would not have the supply of nutrients to grow. Likewise, without the cortical rigidity, the cancellous matrix would be unable to provide sufficient strength to function. Consequently, both components are needed for proper bone integrity.

Types of Fractures

Fractures may be described by the angle and extent of the break in the bone's continuity (eg, transverse, longitudinal, comminuted, impacted), by the effect upon other tissues (as with "open" fractures), and by the underlying cause (eg, traumatic, pathologic).[4] Initial reduction bone grafting is considered when there is enough bone loss to inhibit proper reunion of the fragments, as is often seen with gunshot injuries. Grafts supply the tissue needed to span the void while encouraging the healing process by providing a porous path for vascular ingrowth and pressure contact between the two fracture ends.

Bone Healing

Many surgeons have humbly admitted that a doctor can resect, remove, and repair, but only the body and God heals. In the case of bone, the body offers a considerable amount of aid, so much so that bone healing has become more properly termed bone regeneration.

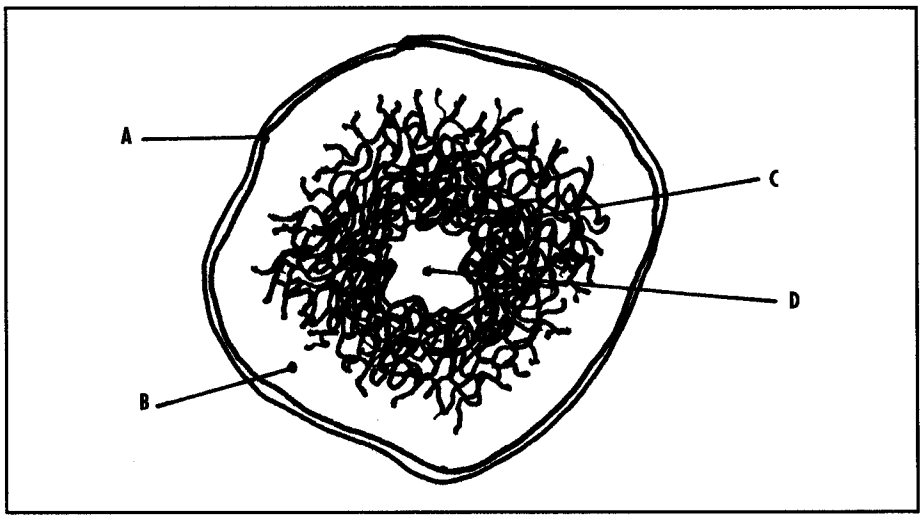

Figure 1. Cross section of typical long bone. **A,** Periosteum; **B,** Cortical zone; **C,** Cancellous matrix; and **D,** Intermedullary canal.

Soft tissues heal by the permanent fibrous scarring together of the opposing edges, but the fractured bone works immediately and diligently to repair, replace, and reshape itself. Several models of this activity have been set forth, most notably by J. Hunter in the 1830s, who described four essential stages of bone regeneration (inflammation, soft callus, hard callus, and remodeling) in his paper titled "Bone Repair."[4] Later models expanded to five stages (hematoma, granulation, callus, consolidation, and remodeling), which will be discussed here, and more recently a sixth stage was named (which adds the stress upon the bone at the moment of fracture in the theory that the force itself initiates bone regeneration).[4]

Hematoma, in this instance, is clot formation around the fracture site, the rapidity and extent (inflammation) of which is dependent upon the vascularity of the bone involved. Blood seeping from the ends of the broken bone into the surrounding soft tissues provides a nutrient base that supports the ensuing stage. The clot remains for several days as vascular ingrowths establish themselves around the fracture and within the hematoma (Figure 2).

Granulation tissue now invades the clot making it more fibrous. This lends temporary support and provides the foundation for further regeneration. After several days, cartilaginous deposits begin to appear within the granulation tissue and a fibrocartilage (soft callus) forms about the fracture site. This stage will develop over 2 to 3 months, and may be reflected in a modicum of clinical stability (see Figure 2).

Callus (hard callus) formation occurs as the cartilage and fibrous tissue are replaced by calcium from the mineral salt deposits (ossification). This is in effect true bone replacement, which can be confirmed by x-ray film (see Figure 2).

Consolidation of the calcium deposits occurs both within and around the fracture site as the remaining cartilage is replaced and the hard callus grows more dense. This persists for several months until a bony bridge fuses the fractured ends. At this point, the bone will not only demonstrate significant clinical stability, it will also appear as a solid unit on roentgenograms (see Figure 2).

Remodeling of the callus to resemble the original shape of the bone is the final phase, during which dead bone fragments are also

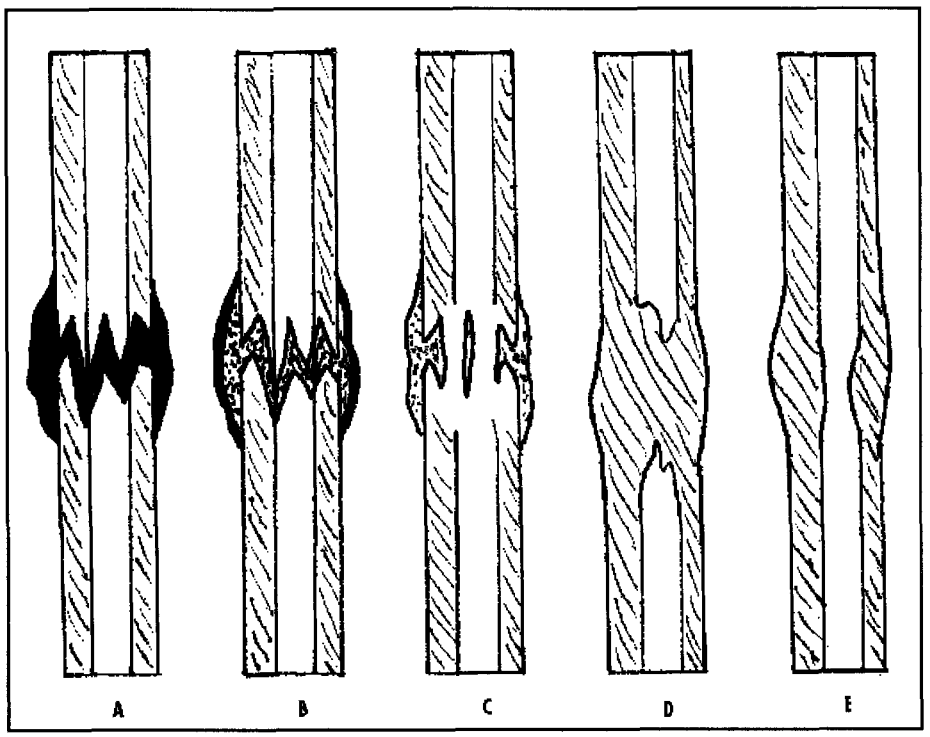

Figure 2. Stages of bone regeneration. **A,** Hematoma formation; **B,** Granulation; **C,** Callus; **D,** Consolidation; and **E,** Remodeling. (Note: Reestablishment of intermedullary canal.) (Adapted from *Campbell's.*)

reabsorbed. Ultimately, the intermedullary canal will be reestablished (although usually narrower than its original size) and a continuity of the structural cortical bone (which is usually more broad than it was originally) will be realized (see Figure 2). (Note: There is also a direct form of bone healing that occurs only with fractures that are anatomically reduced and stably fixated [eg, plate and screws] in which the bone begins remodeling from the onset. Although a callus may form about the metal implants as a reaction to the presence of a foreign body, this direct process is an indication of the important roles that proper alignment of the fractured ends, compression, and rigid fixation play in bone healing.)[4]

The entire regenerative process may take years depending upon the age and overall health of the individual and is never assumed to be complete until so verified under radiologic examination. A number of factors, such as infection, poor reduction, and concurrent disease, can undermine the bone's attempt to regenerate. Thus, a fracture may heal poorly (malunion), over a substantially prolonged period of time (delayed union), or not at all (nonunion).[4] In each of these instances, a bone graft may be required to affect regeneration. This involves surgical intervention, during which the fracture site is debrided of soft tissue and extraneous callus, the fracture line is liberally curetted to encourage vascularity between the bone ends, and the graft is packed in the defect.[3] It is at this point that the periosteum plays its role in bone healing. After the bone graft is packed in the defect, the periosteum is closed around it, thereby setting a physical limit to radial callus growth.

Types of Bone Grafts

In fracture management, there are three categories of bone grafts, each of which carries its own particular cautions and uses. The first category, autogenous, refers to the harvesting of the patient's own bone (usually from another site but preferably from the immediate fracture area) for implantation in the defect. Common autogenous donor sites are the iliac crest, fibula, and proximal tibia. Autogenous bone grafts, by virtue of their origin, have a greater chance of survival. Since they are "live" bone autografts, they provide not only structural support but encourage osteogenesis on the cellular level as well.[3]

Homogenous grafts, also known as allografts, are those from other people or cadavers. Cadaveric harvests are dead bone grafts that are processed for implantation in accordance with the guidelines established by the American Association of Tissue Banks.[3] These types of grafts add only structural soundness to the fracture, either by way of cortical rigidity or cancellous porosity. In many cases, this may be all that is required to support proper regeneration. Cadaveric allografts are commonly prepared as femoral heads, long bone shafts, tricortical plugs, and "croutons" (small cubes of cancellous bone) (Figure 3). Homogenous bone grafts can also be harvested live, and are usually done so from a sibling or other close relative. The most common form of this graft is that of bone marrow. Percutaneous in their administration, marrow transplants target not the supportive or osteogenic roles of bone grafts, but rather are directed at improving the bone's blood manufacturing capabilities.[4]

The third type of bone grafting material is synthetic bone supplements. One that has recently been developed by Zimmer and Collagen Corporation is known as collagraft.[5] Collagraft is not bone but rather porous beads consisting of 60% hydroxyapatite, and 40% tricalcium phosphate ceramic and fibrillar collagen.[5] Although it was not developed to replace bone, and in fact is applied as a biologic augmentary substance to bridge gaps in a fracture during the regenerative process, its make-up has been found to actually encourage osteogenesis. Collagraft is mixed with bone marrow prior to use, according to criteria set forth by Zimmer and Collagen Corporation, and its granular form allows for utilization in a variety of grafting situations. Another type of synthetic graft is used in

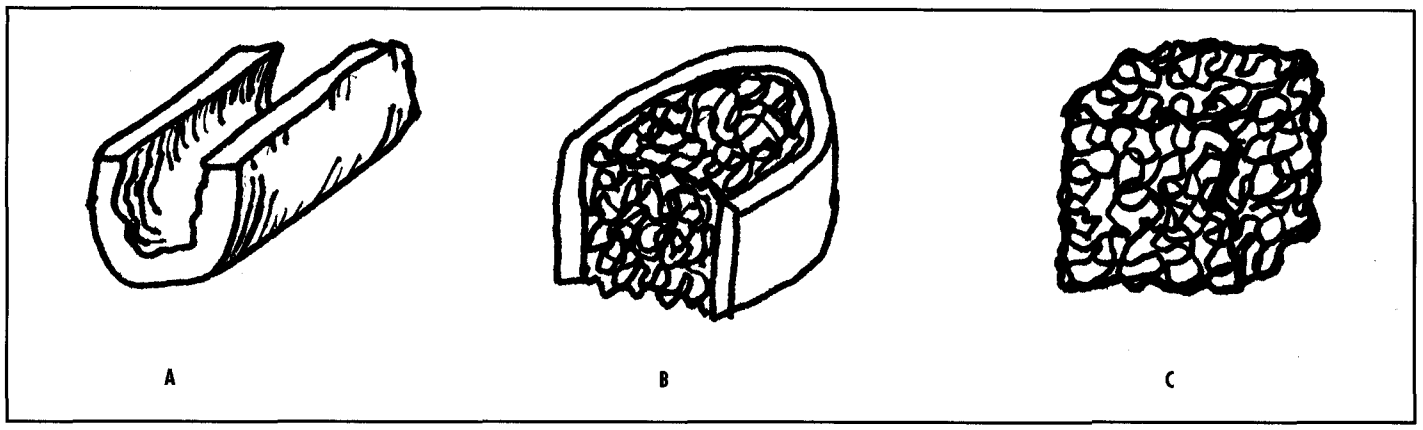

Figure 3. Types of bone grafts. **A,** Diaphyseal shaft; **B,** Tricortical plug; and **C,** Cancellous crouton.

basically the same fashion as collagraft, but is instead derived from processed sea coral.

Heterogenous grafts, such as porcine heart valves, have been a boon to many surgical fields; unfortunately, they have not found favor in orthopedics. In repeated experiments these grafts have proven unsatisfactory for any purpose other than simple splinting. Heterogenous bone grafts do not stimulate osteogenesis and are frequently subject to foreign body reactions such as infection and rejection. However, porcine bones are used as a source of collagen, from which other grafting products and hemostatic agents are produced.[6]

Uses of Bone Grafts

Both homogenous and autogenous bone grafts may be used in several ways. Onlays are cortical bone grafts specifically employed as splints for structural support, and as such must be secured in place with either screws or cerclage wire, to be effective. Generally, a flattened surface will be prepared to accept the graft, or the natural contour of say, a femoral diaphysis, may be incorporated onto that of the underlying fractured bone. Onlays may also be used as prophylactic grafts in total hip arthroplasty by acting as a reinforcement onlay for the trochanteric region, thereby reducing the incidence of fracture that can occur during femoral rasping and reaming.[3]

Cancellous inserts are autologously harvested cancellous grafts, generally taken from the ilium or tibia. As spongy matter, cancellous grafts can be easily shaped and/or morselized to fill any bony defect. They are often used in fracture management for this purpose, as well as in total arthroplasty procedures when cysts or other articular surface defects exist.[3] Cancellous grafts are also used as an underlying "packing" to restore depression fractures (ie, ocular orbit, tibial plateau), or, more recently, to reinforce the integrity of articular surfaces as seen with chondromalacia of the femoral condyle.

Homogenous croutons are also used as packing in instances of bone loss or disease, but as they are freeze-dried they require some form of reconstitution to soften them prior to use.[3] This may be accomplished by soaking the cubes in normal saline or, preferably, in the patient's blood. They may also be morselized and mixed with marrow before implantation to increase the chance of success, but again, homogenous inserts are not as desirable as their autogenous counterparts.

Tubular grafts are usually in the form of autogenous whole fibular grafts for radial or ulnar supplementation.[3] In use, the shattered bone's diaphysis is excised by clean transection both proximal and distal to the fracture site and the fibular diaphysis is implanted. Obviously, this requires substantial compression fixation and alignment to succeed and, in this particular case, the salvaging and reclosure of the periosteum over the graft is essential. Cases have been documented in which cadaver femoral shafts were used as tubular inserts for femoral diaphysis lengthening; however, these results have been less successful.

Doweling, or the use of cylindrical plugs, was once a common grafting technique used specifically for the promotion of osteogenesis, but it too has waned in use.[4] Dowels are taken by using hollow core drills, in much the same way that bone biopsy specimens are obtained, which provide a bone graft with an intact cortical surface attached to a length of cancellous matrix.

Indications for Bone Grafting

Primarily, bone grafts are used in instances where there is substantial bone loss significant enough to inhibit proper union, and when a reduced fracture is delayed or blocked from its union. Generally, bone grafting is performed at the time of primary reduction or at about 6 to 12 weeks after the wound has been stabilized.[4] This later precaution, long the standard for bone grafting usage in nonunions, is taken with the risk of infection firmly in mind. In any case, restoration of function (as with fractures) and/or elimination of pain (as seen with spinal fusion and arthrodesis) are the main objectives. As a rule, where fixation is required a cortical graft is used, and when there is a need to encourage osteogenesis, cancellous grafts are the choice.

Complications of Bone Grafting
The invasive harvesting of autogenous bone causes a certain low, but significant, degree of morbidity as well as contributing to interoperative blood loss. Harvesting can further lead to donor site fractures, hernias, nerve impairment, and acute pain, besides adding anesthesia and operating time to a procedure.[1]

Bone quality is also a factor. A disease that may have initiated the fracture can be present in other areas of the body, thereby rendering a proposed graft site useless. Studies have also shown that there is a greater chance of graft failure when the bone is harvested from a site far from the fracture. This is unfortunate, in that often the need for a bone graft in fracture management is precipitated by the lack of available tissue at the injury site.

Homogenous grafts, although available in readily usable forms, have come under more scrutiny recently with the advent of certain infectious diseases. There is a growing concern that viral transmission is possible due to the organism's unique reproductive nature.[5]

Bone grafts in general can fail. Graft failure may necessitate additional surgery to correct the problem, which may be further complicated by necrosis or sloughing of the overlying soft tissues. Infection is also a concern, particularly with autogenous donor site grafts. (It should be further noted that the treatment of open fractures carries a strong concern for infection from debris, which can lead to graft failure. They also allow the blood that normally forms the hematoma to leave the fracture site, in effect delaying the regenerative process and undermining graft efforts.[4])

Collagraft, although not free from the effects of resorption or malunion seen with grafts, has demonstrated lower infection rates and higher percentages of union. However, collagraft has been shown to be less effective in cases involving pathologic fractures or bone disease, and is cautioned against usage where surgical intervention is not warranted (ie, a simple fracture that can be satisfactorily reduced in a closed manner) or when the interval from injury to operative reduction is greater than 30 days.[5]

Other Developments in Fracture Management
Biodegradable implants have been developed with the hope that future removal of the implant will not be warranted, and too, that the transfer of the "load" from the hardware to the bone itself, is more gradual and therefore less traumatic to the patient and healing bone. Unfortunately, the materials are not as yet strong enough to provide the initial support that is essential while the bone regenerates, so use has dropped dramatically.[4]

Electric and electromagnetic stimulation to encourage bone regeneration for nonunions is a technique that has been used for some years. Various configurations of electrodes and wave forms have all shown effectiveness in this regard, with results approaching 80% in cases when applied for more than 3 hours per day.[4]

There are three avenues of current delivery via the placement of conductive electrodes: noninvasive (percutaneous implantation of electrode ends), and invasive (which entails surgical implantation of the conductive surfaces at a point under the skin directly over the target area). Despite the differences in these approaches, results seem to be comparable, and this form of encouragement for bone regeneration has proven to be beneficial for up to 10 years after the initial fracture treatment and nonunion. It has also shown effectiveness with, or rather ambiguity for, infection. However, the prolonged immobilization necessary to obtain good results often proves to be counterproductive to rehabilitative efforts.

Conclusion
Fixation and osteogenesis are the keys to current fracture management techniques aimed at the proper alignment and ultimate regeneration of the broken bone, and commonly it is a bone graft supplement that aids in the realization of these goals. The body knows what to do, and as fracture management techniques concentrate on aiding the body in doing its job, bone regeneration will occur more readily and with a higher rate of success. Recent advancements in biotechnology, as seen with collagraft, are geared to this goal also, and with greater numbers of applications and successes these supplements may find a growing niche within which a solution to graft harvesting, storage, and morbidity may be found.

Acknowledgement
The author wishes to express his appreciation for the efforts of Dick Loftus of Zimmer, Inc., in the preparation of this paper. Δ

References
1. Younger EM, Chapman MW. Morbidity at bone graft donor sites. *J Orthop Trauma.* 1989;3(No. 3):192-195.
2. LJ Atkinson. *Introduction to Operating Room Technique.* 7th ed. St Louis, Mo: Mosby-Year Book; 1992.
3. Crenshaw AH. *Campbell's Operative Orthopaedics.* 8th ed. St Louis, Mo: Mosby-Year Book, Inc; 1992;1:12-20,317,320,331,337.
4. Crenshaw AH. *Campbell's Operative Orthopaedics.* 8th ed. St Louis, Mo: Mosby-Year Book, Inc; 1992;2:725,735-736,776,1300-1301.
5. Zimmer. *Highlights of Safety and Effectiveness Studies for Collagraft Bone Graft Matrix.* Zimmer and Collagen Corp. Zimmer, Inc. May 1993.
6. Cornell C, Chapman MW, et al. Multicenter trial of Collagraft as a bone substitute. *J Orthop Trauma.* 1991;5(No. 1):1-8.

Gary Allen, CST, *is an 8-year member of AST and earned his associate degree at Springfield Technical Community College. He is employed at Baystate Medical Center in Springfield, Massachusetts, and specializes in orthopedic and thoracic surgery. Mr Allen has had several articles published in the journal. He won second place in this year's Writer's Award and first place in the 1993 Writer's Award.*