Bilateral Patellar Tendon Rupture

ARTICLE BY RONALD ALSTON, CST

I am a 34-year-old black male who considers myself to be in the best of health, a very active participant in most recreational sports, and a competitive bodybuilder. At this time, I am not taking any medication and have no prior knee injuries.

In an instant, my life changed. On Thursday, September 16, 1993, during a recreational touch football game, I attempted to jump for a ball thrown to an opposing player and felt immediate pain in both knees before hitting the ground. This pain lasted approximately 20 minutes and was localized in both knees just below the patella. I was unable to ambulate but could move both feet and had numbness in both of my knees. I was removed from the playing field about 25 minutes later by four teammates and waited to be transferred by ambulance to a nearby emergency room, not knowing the extent of my injury. The pain had now subsided. After being seen by the physician on-call for orthopedic trauma, the admitting physical examination showed bilateral patella alta (high riding kneecap) with palpable infrapatellar soft tissue defect and localized swelling (Figure 1). There was no active knee extension and no other ligamentous laxity of the knee. Both my legs were neurovascularly intact.

This article will aquaint the reader with the surgical procedure of bilateral patellar tendon repair as well as postoperative responses and rehabilitation from the unique perspective of a patient as well as a CST.

Radiologic Examination and Immediate Treatment

X-rays films were taken and read by the on-call radiologist who reported both knees with patella alta with some bony deposits and no bony fragments. Despite the unremarkable x-ray film, there was severe injury to both of my knees. Both of the patellar tendons had ruptured, making active knee extension impossible. The treatment for bilateral patellar tendon rupture is surgical repair of the patellar tendon disruption with bilateral application of plaster splints. Full-leg Robert Jones dressings were applied to both legs to keep them immobile. Surgery was scheduled for the next morning and medication was given for pain.

Two years prior to this injury, I had been diagnosed with Osgood-Schlatter disease or "jumper's knee." Treatment included ice and rest, which seemed to alleviate the problem. Partial rupture of the patellar ligament, known as jumper's knee, is a repetitive overload lesion at the bone-tendon junction at the lower patellar pole. Found mainly in athletes, it is caused either by microrupture or partial macrorupture of the proximal part of the tendon with degeneration and devitalized tissue at the insertion of the patellar tendon. Peripatellar tendinitis affecting either the quadriceps tendon or the patellar tendon insertion onto the patella is most commonly seen in athletes involved in jumping-related sports. Patellar and quadriceps ten-

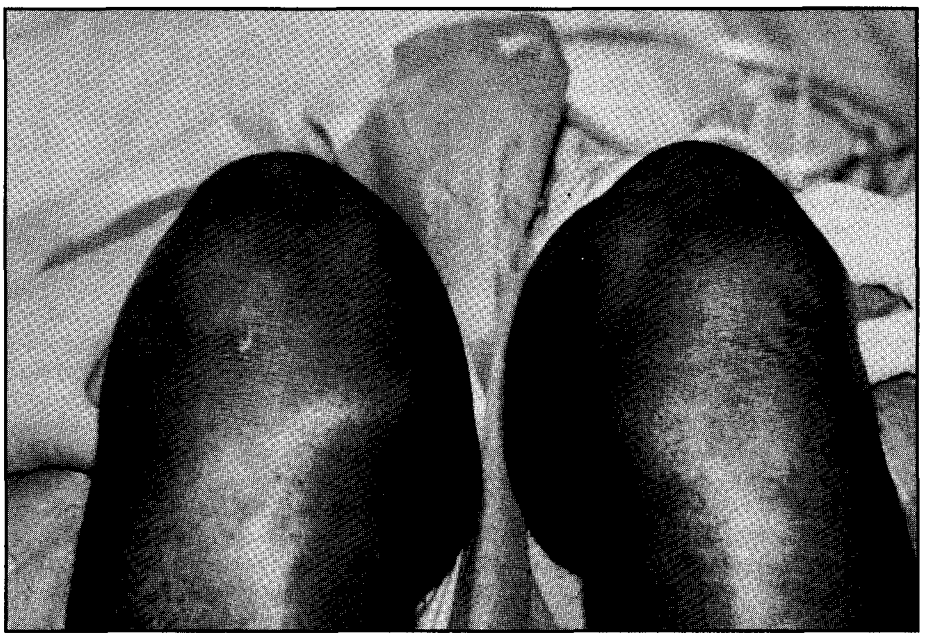

Figure 1. Anterior view of both knees showing defects inferior to both patellae.

don ruptures from indirect injury in athletes may represent the end stage of jumper's knee and result from repetitive microtrauma. Many athletes involved in sport activities place repetitive stress on the extensor mechanism of the knee, causing microtrauma concentrated at the superior or inferior pole of the patella. Volleyball seems to be the most common sport involved, as well as basketball, a sport in which I frequently participate. As a result of patellar trauma, a critical degree of tendon degeneration may have occurred prior to rupture. The overloading of the knees leads to degeneration of the patellar tendons, plus decreased elasticity, degenerative changes in collagen fibrils, and decreased vascular supply. In this case, the major factor leading to the tendon ruptures was degeneration from repetitive microtrauma that represents end stage jumper's knee. My age was also a factor since the tendons had undergone more wear and tear than would be found in a younger athlete.

Bilateral patellar tendon rupture is a very rare injury seen in approximately five patients a year in the United States with approximately 20 reported cases in English literature. Mine was only the second such procedure ever performed at the Mayo Clinic. The majority of these cases occurred in patients with systemic diseases such as systemic lupus erythematosus, rheumatoid arthritis, or renal failure. Rupture of the infrapatellar tendon in healthy athletes, as well as those diagnosed with jumper's knee, is extremely rare. In this case, the injury occurred as the tendons snapped at the lower pole of the patella by the strong force of jumping, thus causing the quadriceps to contract and fire with an extreme amount of force causing both patellae to retract superiorly into the region of the thigh. Bilateral patellar tendon rupture precludes the patient from ambulation or extension of either leg. Rupture of the patellar tendon requires immediate surgical attention. Excellent function usually follows repair of patellar tendon ruptures when surgery is performed early and care is taken to restore normal patellar tendon length. Delayed surgery may cause technical problems in repair. If not repaired soon after injury, patellar tendon shortening may occur.

Figure 2. Anterior view of both knees showing disruption of both patellae tendons.

Operative Procedure

On September 17, 1993, I was brought to the orthopedic anesthesia block room and placed under epidural anesthesia. I was then taken to the operating room where my lower extremities were prepared and draped in the usual fashion. Tourniquets were applied to the thighs. The limbs were exsanguinated and the tourniquets were inflated to 300 mm of mercury. The repair of the patellar tendons was carried out simultaneously as follows. An incision was made centered over the patella from the superior pole to the medial aspect of the tibial tuberosity and approximately 1 cm distal to this point. This incision was carried down through the suprapatellar bursa and the tendon sheath was incised and the patellar tendon exposed. Immediately upon reaching the level of patellar tendon, it was noted that both patellar tendons were disrupted completely from the inferior pole of the patella with no significant stump on the inferior pole (Figure 2). Both sides had complete disruption of the patellar retinacula, both medially and laterally. The joints were inspected and the cartilage was found to be free of damage. The medial and lateral menisci of both knees were intact as were the anterior cruciate ligaments. Attention was then turned to the repair, which was performed with a No. 1 polybutilate (Ethibond) suture in a Krakow stitch in each patellar tendon medially and laterally. A Krakow stitch is a weaving stitch that makes it easier to obtain better fixation of the tissue. Three drill holes were placed in the patella after the bed was prepared using a burr. The No. 1 polybutilate suture was then carried up through these drill holes. A drill hole was placed in each tibia just above the level of the tibial tuberosity through which a No. 5 uncoated polyester fiber (Mersilene) suture was passed. The sutures were then carried circumferentially through the retinaculum and quadriceps tendon and tied tightly with the knee in 30° flexion. Following this, the No. 1 polybutilate suture was carried through the patella and tied tightly (Figure 3). Good apposition of the patella to

Figure 3. Intraoperative repair of tendon showing sutures.

the patellar tendon was achieved and my knees were able to be flexed 90° without disruption of the repairs. The retinacula were closed using interrupted 0 polybutilate sutures and the remaining frayed edges of the patellar tendons were tacked down using 0 uncoated monofilament polyglactin 910 sutures. The tourniquets were released and hemostasis obtained with electrocautery. The wounds were irrigated and closed over a drain with interrupted 2-0 uncoated monofilament polyglactin 910 sutures subcutaneously and interrupted 2-0 polypropylene sutures in the skin. Sterile dressings were applied, followed by long-leg Robert Jones dressings with medial and lateral plaster splints. I was taken to the recovery room in good condition.

Postoperative Care

9/20/93: Three days after surgery, I was taken to the cast room. My dressings were removed, exposing intact wounds without erythema or drainage. Long-leg Robert Jones dressings with medial and lateral plaster splints were placed and I was returned to my room. On September 21, 1993, I was released from the hospital and was sent home with pain medication.

9/24/93: I was brought back to the cast room for removal of the Robert Jones dressings. My wounds were intact even though I had been having some fever previously. The incisions were nontender and had absolutely no drainage or erythema, thus my sutures were removed and 1/2 in adhesive strips were placed over the wounds. I was then placed in Ortho-Tech Rehab III braces with the knees locked in full extension.

During the first 2 weeks after surgery, I went through both mental and physical changes despite the fact that I knew what was ahead. During my recovery period, the seriousness of my injury and extent of my surgery had not yet set in. Being as active as I had been and never experiencing any injury that had disabled me for a significant time period, losing the use of both lower extremities was devastating to say the least. The rupture of a single patellar tendon is rare and I felt it would never happen to me. The possibility of bilateral patellar tendon rupture is merely impossible, at least that is what I kept telling myself despite the fact that such surgery had been performed. Both legs were in braces and the only mobility I had was through the use of a wheelchair with the help of my wife. Depression really set in as I went from a very active, independent young man to a totally dependent one. The days during this healing process grew longer. I was unable to walk or play with my 3-month-old daughter and, for a short period of time, I stopped eating. Yet, I really didn't believe it was happening to me. Before my injury, I spent much of my free time in the gym lifting weights. I worked very hard at developing my body. But despite all my efforts, I saw my legs atrophying before my eyes.

Time helped me work through the pain though it was not always easy to keep a positive attitude. I dug deeply into myself and once my acceptance was put into perspective, the real healing began.

10/22/93: I returned to the cast room where my wounds were clean, dry, and intact. I began motion from 0° to 30° and was scheduled for physical therapy (PT) to start October 22, 1993, in the Sports Medicine Department. I would be assessed in 3 weeks.

10/29/93: My knee motion was increased to 60°, but I still had to remain non-weight-bearing as I had been since I entered the hospital.

11/15/93: I was seen by my physician as an outpatient to check the motion as well as the strength of my repair. The ability to actively extend my legs was intact.

Rehabilitation

10/22/93: 45-minute therapeutic exercise (TE) and measured for a platform walker with height of 45 in. Increased the Ortho-Tech hinge brace from 0° to 30° to 0° to 60° bilaterally and then progress to 90° and crutches within 3 weeks.

11/10/93: 30 minutes TE. Doing well, easily achieved 60° range of motion (ROM). The brace was increased to 90° and crutches were added using a four-point gait for walking. Next session in 2 weeks and increase brace to 120°.

11/19/93: 30 minutes TE. Now have 0° to 70° ROM. Will proceed with daily PT to increase ROM and increase brace to 120°.

11/22/93: 45 minutes TE. Passive motion now at 0° to 80°. Will attempt to use Biodex machine, which is used to flex and manipulate the knee to increase available passive motion. Continue on a daily basis.

11/23/93: 45 minutes TE. Used hot packs. Biodex used for ROM passive mode using 12.5 in on leg extension and 4 in on the seat. Was able to achieve 73° flexion bilaterally using Biodex scale.

11/24/93: 45 minutes TE. Hot packs and Biodex machine for passive motion not at 80° bilateral passive motion parameters as above. Continue on a daily basis.

11/26/93: 45 minutes TE. Hot packs and Biodex machine for passive motion to 85°. Ice was applied following exercise.

11/29/93: 45 minutes TE. Hot packs, passive motion to 90°.

11/30/93: 45 minutes TE. Hot packs, PT as above. Ten minutes upper body ergometer (UBE) machine approved by physician to

begin strengthening.

12/1/93: 45 minutes TE. Hot packs and Biodex for passive motion. Continue daily.

12/2/93: 45 minutes TE. Hot packs and Biodex for passive motion to 92°. Continue daily.

12/6/93: 45 minutes TE. Hot packs and Biodex for passive motion. UBE for 10 minutes. The UBE is being used for cardiovascular work.

12/7/93: 45 minutes TE. Hot packs and Biodex for passive motion 0° to 93°.

12/9/93: Same as 12/7/93.

12/10/93: 30 minutes TE. Bilateral flexion 90° to 95°.

12/14/93: 45 minutes TE. Passive motion bilaterally to 100°.

12/15/93: Added leg press, three sets of 15 repetitions, level six to continue 3 to 4 times a week.

12/17/93: 45 minutes TE and Biodex and will proceed with leg press at the YMCA. Three sets of 10 to 15 repetitions.

12/21/93: Doing well. Biodex to 105° bilaterally. Will increase leg press to level 8 doing three sets, 2 to 3 times a week.

12/22/93: 45 minutes TE. Hot packs and Biodex up to 105° on the left and 107° on the right. Add hamstring curls and toe raises.

12/27/93: 45 minutes TE. 108° on the left and 105° on the right.

12/28/93: 45 minutes TE. Same as previous day.

12/29/93: 45 minutes TE. 110° bilaterally. Add leg press, hamstring curls, toe raises, added hamstring stretching due to discomfort in the medial distal hamstring. Continue as able.

1/5/94: 45 minutes TE. 110° on the left and 105° on the right. Ice post-exercise. Continue with Biodex until maxed out. Proceed with total gym.

1/6/94: 45 minutes TE. 110° on the left, 108° on the right. Continue with leg press, hamstring curls, toe raises on own time, as well as three times a week in Sports Medicine Department.

1/7/94: 45 minutes TE. 111° on the left, 110° on the right. Continue as able. Total gym trial next week.

Rehabilitation continues on a daily basis and will throughout the next 3 to 4 months. Expected ROM bilaterally 130° to 135°. I should be able to resume all activities with no complications.

Summary

As CSTs, we are integral members of the surgical team working with the surgeons, nurses, and anesthesia providers, as well as the patient. Our job duties require us to perform a number of tasks, the most important being to provide the best patient care possible. In order to perform these responsibilities, we attend accredited surgical technology programs. These programs assure us of the essentials needed to carry out these responsibilities. As a CST, I feel my training has been the best. We CSTs work hard to uphold our position. We sharpen our skills each day we work in the operating room. We are truly professionals. In the article, I shared a personal experience with you and, with this experience, I learned some things that we do not and can not see through the eyes of the patients to whom we provide surgical care each day. This lesson can not be taught in the classroom, during our clinicals, or in our everyday practice. This is the traumatic effect that major surgery has on our patients after they leave the operating room. Most are faced with days and weeks of pain, uncertainty, and unanswered questions.

My misfortune has given me an unwanted opportunity to experience the most difficult part of a patient's surgical experience. As a patient, I endured what I would consider the worst. Surgery was easy and painless—postoperatively is when the debt is finally paid. I have lost a lot as a result of my injury and my surgical experience as a patient resulted in inactivity, mental imbalance, and the uphill battle of fighting each day to feel normal again. My pain has endured through the course of my rehabilitation. Learning to walk again has not been easy. I thought that through rehabilitation it would become easier. I was wrong; it becomes harder and continues until you are whole again. Rehabilitation will continue for many months. Through it all, a valuable lesson has been learned; as a CST, the care I give to a patient once they enter the operating room until the time they leave will never be enough. I have experienced their pain and frustration and from the time they leave the operating room, it is the start of a new beginning for most of them. Δ

Acknowledgements

I would like to thank Robert Trousdale, MD, Department of Orthopedic Surgery, Mayo Clinic, for performing my surgery and for his assistance with this manuscript and Michael J. Stuart, MD, head of the Sports Medicine Center, Department of Orthopedic Surgery, Mayo Clinic, for his help during my recuperation. Special thanks to Peter Lohman, my physical therapist, for putting up with me during the tough times, and for his continued help and support on a regular basis, and to my wife, Jane, for her support and care during this difficult time.

Bibliography

Delee JC, Craviotto DF. Rupture of the quadriceps tendon after a central third patellar tendon anterior cruciate ligament reconstruction. *Am J Sports Med.* August 1991;19;4:415.

Karlsson J, Lundin O, Wigerstad-Lossing I, Peterson L. Partial rupture of the patella. *Am J Sports Med.* August 1991;19;4:402.

Rupture of the patellar tendon. *South Med J.* March 1988;81;3:376.

Webb LX, Toby EB. Bilateral rupture of the patella tendon in an otherwise healthy male patient following minor trauma. *J Trauma.* November 1986;26;11:1045.

Kelly DW, Carter VS, Jobe FW, Kerlan RK. Patellar and quadriceps tendon ruptures: Jumper's knee. *Am J Sports Med.* Sept-Oct 1984;12;5:375.

Ronald Alston, CST, *has been employed as a surgical technologist with the Mayo Clinic in Rochester, Minnesota, for 8 years. He currently works in general surgery with an emphasis on colon and rectal procedures.*