Small Joint Scopes and Distal Radial Fractures

ARTICLE BY NANCY LOTZ, CST

Small joint scopes provide some advantages in the treatment of comminuted distal radial fractures. Use of a small joint scope during the reduction of this type of fracture reduces the chance of misalignment of the articular surface of the distal radius.

Distal radial fractures are usually caused by a fall on an outstretched hand.[1]

The comminuted displaced distal radial fracture is one of the more difficult fractures to reduce. For years, the only way to determine if the articular surface had been reduced was through radiology or under direct observation.

Recently, the small joint arthroscope has been used during the reduction of the fracture to ensure that the continuity of the articular surface is maintained.

Anatomy

The normal distal radius articulates with the scaphoid and lunate bones and the head of the distal ulna (Figure 1). The distal radius has a slightly concave articular surface. The normal angulation radiates from the central distal radius to the distal ulna at a 16- to 28-degree angle (Figure 2).[2]

In the lateral view, the distal radius exhibits what is referred to as a palmer tilt, which is characterized by an angle between zero and 22 degrees. The angle is calculated using a line placed in the center of the distal radius. A line is placed at the angle of the articular surface of the radius. A third line is then placed perpendicular to the central radial line (Figure 3).[2]

A comminuted distal radial fracture is a fracture that has more than two fragments (Figure 4). The words "displaced" and "depressed" are synonymous. When the distal radius is displaced, the medial fragments are pushed down into the radial bone. Such a displacement is also referred to as a die-punch depression. This displacement leaves the radius shortened.

Instruments and Equipment

Whether the distal radius is reduced, closed, and pinned with Kirschner wires (K-wires), or opened at the fracture site and reduced, the arthroscope can still be used to check the interarticular surface.

Before setting up the case, surgical technologists must check the nonsterile arthroscopy equipment to ensure that it is in working order. While setting up the procedure, the scrub person must also check all sterile items to be used.

The following equipment is needed to perform this procedure:

Hand instruments: soft tissue and bone

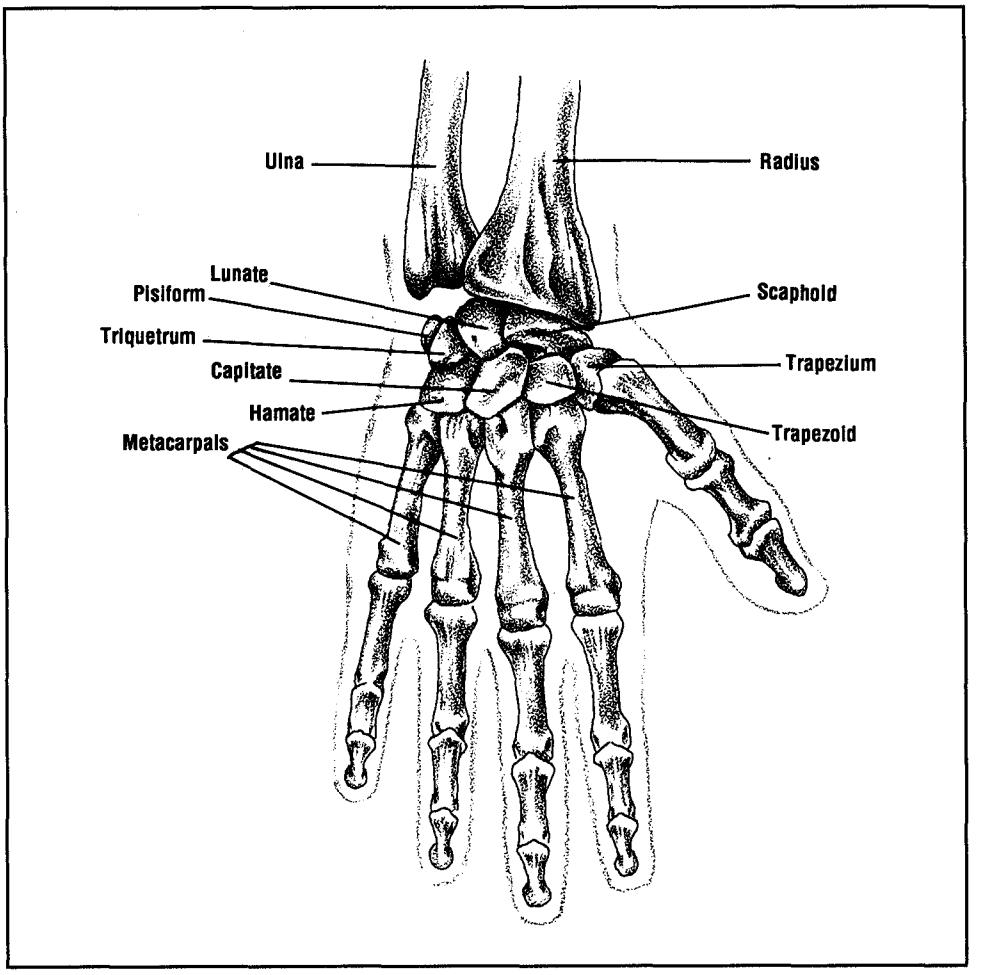

Figure 1. Posterior view of the bones of the wrist and hand. (Adapted from Tortora GJ, Grabowski SR. *Principles of Anatomy and Physiology.*)

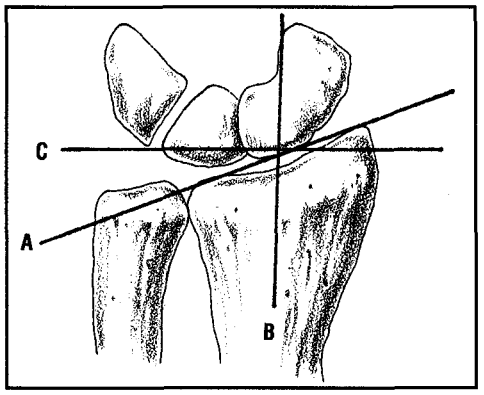

Figure 2. Normal angulation of distal radius. **Line A,** Joins the tip of the radial styloid and the corner of the ulna; **Line B,** Central axis of the radius; **Line C,** Perpendicular to line B (angle between lines A and C normally measures between 16 and 28 degrees).

Instruments for taking a bone graft
K-wire driver and/or drill
Sterile finger traps (2 sets)
Small joint wrist scope (2.7 mm) with cannulas and trocars
Fiberoptic light cord for scope
Right-angle probe for small joint
IV extension tubing
IV extension tubing with stopcock
Plating system for wrists
K-wires
Suction tubing
Knife blades (No. 11 and/or No. 15)

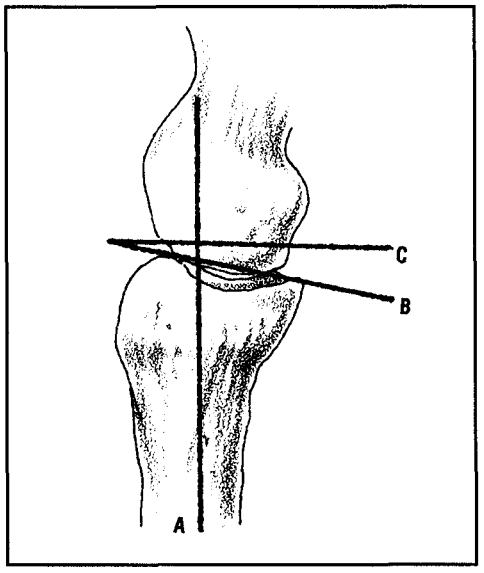

Figure 3. Lateral view of angulation of distal radius. **Line A,** Central distal radius; **Line B,** Articular surface; **Line C,** Perpendicular to central radial line.

Marking pen
Four-ply crinkled gauze bandage (Kerlix)
External fixator
Weights (10 lbs.-15 lbs. and 10 lbs.-12 lbs.) (2 sets)
Video camera
Scope cart, light source, monitor, and camera receiver
Shoulder boom
IV pressure bag
IV macro drip tubing
One-liter IV normal saline

Patient Preparation

The anesthesia of choice is an axillary block or general anesthesia if a bone graft is necessary.

The patient is placed in the supine position with the affected arm extended at 90 degrees to the body on an arm table. A tourniquet is then applied to the upper arm. The arm is prepped along with the iliac crest. Draping consists of a hand drape that provides exposure to the iliac crest.

After the patient is prepped and draped, the arm is exsanguinated and the tourniquet is inflated. Finger traps are placed on the index and long fingers (Figure 5). A loop of traction rope joins the finger traps and is attached to a hook on the shoulder boom. The area beneath the hook attachment is sterile. On the other end of the cable of the shoulder boom, a hanger with 12 lbs. to 15 lbs. of weight is applied. The four-ply crinkled gauze bandage (Kerlix) is unrolled. The loose ends are allowed to drop off of either side of the hand table. The center of the bandage is placed over the upper arm. The loose ends are knotted together under the table. A hanger with 10 lbs. to 12 lbs. of weight is hung on the bandage for countertraction. The arm now forms a 90-degree angle at the elbow.

The intravenous (IV) extension tubing and the IV extension tubing with the stopcock are connected together. The stopcock should be placed at the middle connection. The IV extension tubing is then passed out of the sterile field and is spiked to the macro drip IV tubing that is already spiked into a one-liter IV bag of normal saline. The IV bag is placed in a pressure bag and inflated to 150 mm Hg. The air is cleared out of the IV line and shut off at the stopcock by the scrub person. Suction is passed off along with the cord for the K-wire driver.

The Mayo stand is brought up to the end of the hand table with the following instruments:

No. 11 or No. 15 blade (1)
Scissors for dissecting (1 pair)
Pickups (2)
Mosquito clamp (1)
Camera with 2.7-mm scope attached
Fiberoptic cord
Right-angle scope probe

The scope cart is placed as close as possible to the Mayo stand. The camera and light cord are connected.

Using a No. 11 or No. 15 blade, a stab incision is made in the wrist for placement of the trocars and cannulas. The IV

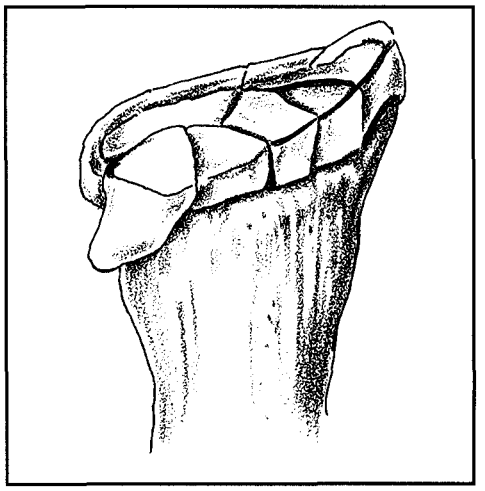

Figure 4. Comminuted displaced distal radial fracture.

tubing is connected to one cannula and suction is attached to another. The wrist joint is irrigated using IV saline. At times, a third trocar and cannula are placed. The scope is inserted through the cannula. The suction should be placed on low and the pressure bag should be checked for 150 mm Hg. The wrist joint is checked for damage to the ligaments and the articular surface.

The scope is removed and the distal radius is manipulated. Anterior-posterior and lateral x-ray films are taken to ensure proper alignment. K-wires are then placed and x-ray films are again taken. The scope is reinserted to check the articular surface. At this time, if all fractures are aligned and the radius has been reduced to its original length, the cannulas are removed. Incisions are closed. K-wires are cut, bent, and buried beneath the skin. The tourniquet is released and dressings are applied along

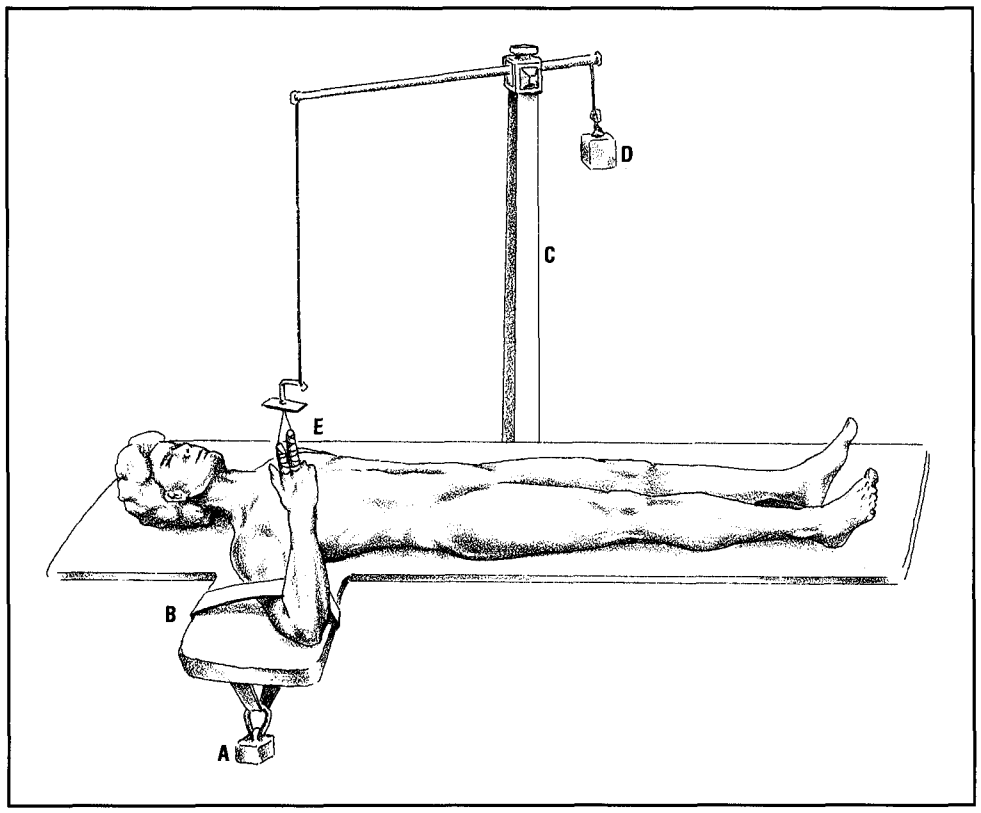

Figure 5. Patient positioning with special equipment. **A,** Weights of 10 lbs. to 12 lbs.; **B,** Four-ply crinkled gauze bandage; **C,** Shoulder boom; **D,** Weights of 12 lbs. to 15 lbs.; **E,** Finger traps.

with a long-arm cast.

If the criteria for the repair of the fracture or the articular surface are not met, then further action is taken. The patient's fingers are released from the finger traps. The weights and shoulder boom are removed from the operative field. The arm is extended on the hand table and the second set of finger traps are applied. Weights of 10 lbs. to 15 lbs. are placed on the traction rope, which is looped on the finger traps.

With the arm extended and tourniquet pressure still inflated, the surgeon makes an incision over the fracture on the dorsum of the wrist and identifies and preserves the structures. The periosteum is then cleaned off the bone. The fracture is evaluated under direct vision allowing the surgeon to make a decision on the best type of fixation. A plate is used to hold the larger fragments together. K-wires may also be used to hold smaller fragments in place. If the fracture is severely displaced, an external fixator may also be applied. The external fixator will stretch the muscles, tendons, and ligaments to length, while holding the radius in proper alignment. Relative bone loss may occur due to impaction of the radius, making an iliac bone graft necessary. During the fixation, the wrist scope is still used to check the articular surface alignment. Saline is not needed because the joint is open and there is no need for joint distension. At this point, final x-ray films of the anterior-posterior and lateral views of the radius are taken. All incisions are closed. The ligamentous tissues are held together with 3-0 or 4-0 braided polyester suture. The skin is closed with 4-0 or 5-0 monofilament nylon suture. Drains are placed where needed and dressings are applied. The arm is placed in a long-arm splint. A long-arm cast may be applied later.

Postoperative Care

The length of the patient's stay is determined by the extent of surgery. Closed pinning may be treated as an outpatient procedure, whereas open reduction may be treated as a 23-hour admission to ensure that swelling does not compromise the median nerve in the carpal canal. Open reduction with iliac graft necessitates a 1- or 2-day hospital stay, usually to control pain and to watch for swelling on the median nerve. Patients are sent home with pain medication and antibiotics. Followup office visits are scheduled 5 to 10 days postoperatively.

Possible postoperative complications include swelling, which causes the median nerve to be compressed; traumatic arthritis may also occur. In addition, medial fragments may again become displaced.

Prognosis is favorable with hand exercises and therapy after the fracture is healed.

Conclusion

Any time a fracture extends into a joint there is the possibility of developing traumatic arthritis. When the articular surface of the radius is off by as little as 2 mm, the likelihood of resulting traumatic arthritis increases. By using the arthroscope, the continuity of the articular surface is monitored. Optimally, this leads to a less painful joint after the fractures have healed. Δ

Acknowledgements

The author would like to thank Phillip Higgs, MD, Randall Scott, RN, CNOR, and my fellow co-workers for their assistance and encouragement in writing this article.

References

1. Rockwood CA, Green DP, Bucholz RW. *Rockwood and Green's Fractures in Adults.* 3rd ed. Philadelphia, Pa: JB Lippincott Co.; 1991:586.
2. Melone CP. Distal radius fractures: Changing concepts of management. *Orthopedic Clinics of North America.* 1993;24;2:217-227.

Bibliography

Atkinson LJ. *Berry & Kohn's Operating Room Technique.* 7th ed. St Louis, Mo: Mosby-Year Book; 1992.

Nancy Lotz, CST, graduated from the surgical technology program at Blessing Hospital in 1978. She is currently employed at Barnes-Jewish Hospital in St Louis, Missouri, where she specializes in plastic and reconstructive surgery.