Carotid Endarterectomy

ARTICLE BY ERIC J. ZELINSKAS, BA

Carotid endarterectomy is a widely accepted procedure for cerebrovascular insufficiency. The first carotid endarterectomy was performed 40 years ago by Michael DeBakey and reported in the *Journal of the American Medical Association.*[1] It is an operation that has stood the test of time and, for properly selected patients, is an established valuable surgical procedure.

There are many variations in the step-by-step performance of the operation due to the preferences of the surgeon, anesthesiologist, and others responsible for patient care, but the basic steps remain the same. Cerebral protection during carotid cross-clamping is a matter of primary concern. Different methods of dealing with this have evolved in different localities. Some surgeons prefer the security of local anesthesia with an awake patient, monitoring the adequacy or inadequacy of cerebral perfusion by the conscious state of the patient. Other surgeons believe that general anesthesia allows for better maintenance of proper oxygen saturation of the blood, blood pressure control, and management of cardiac arrhythmias or other physiologic disturbances that may occur during the course of the operation. Each method has its supporters and its advantages; the decision depends upon the experience of the operating team with particular emphasis on the preference of the surgeon.[2]

Disclaimer Statement: The opinions or assertions contained in this article are those of the author and are not construed as official or reflecting the views of the United States Air Force.

Circulatory Routes

The circulatory system consists of numerous arteries and veins organized into specific routes to circulate blood throughout the body. One of the basic circulatory routes through which blood travels is the cerebrovascular circulatory system.

Oxygenated blood is pumped by the heart (left ventricle) through the ascending aorta to the innominate artery, the first branch off the aortic arch.

The innominate artery breaks off into two major branches: the right common carotid artery and right subclavian artery. The left common carotid artery and left subclavian artery are the second and third branches that arise from the aortic arch. Unlike the right side, they originate independently (Figure 1).

Each common carotid artery divides into an external carotid artery and an internal carotid artery at the mid-cervical region. The

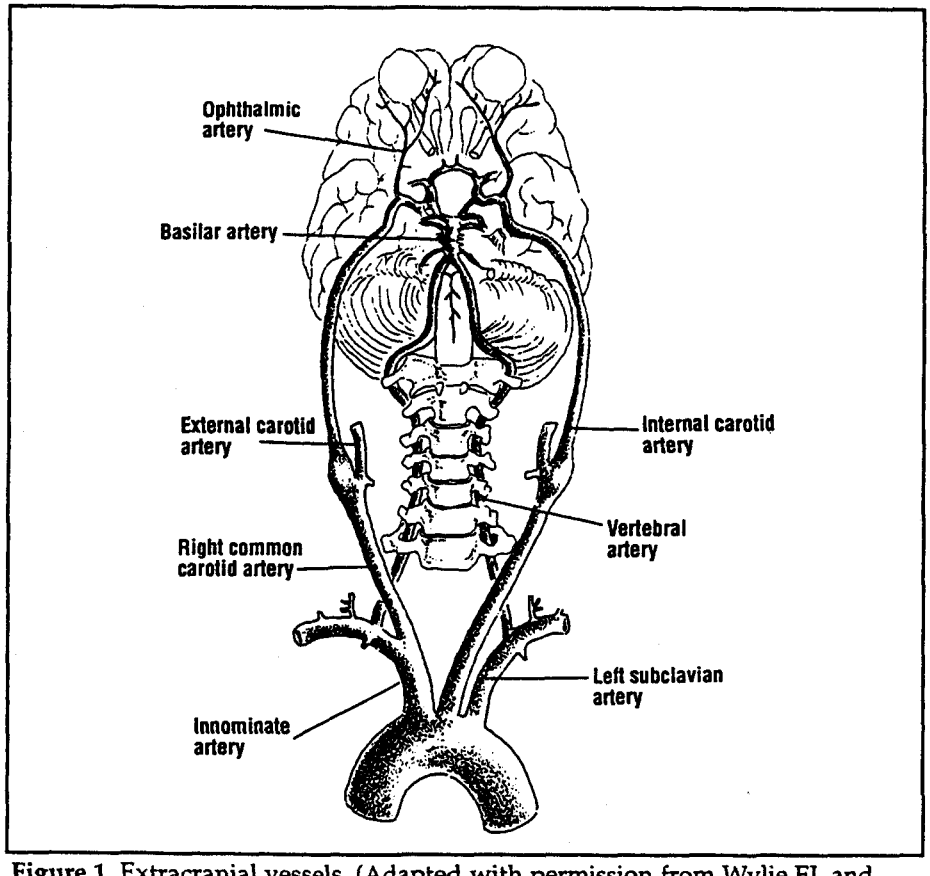

Figure 1. Extracranial vessels. (Adapted with permission from Wylie EJ, and Ehrenfeld WK. *Extracranial Occlusive Cerebrovascular Disease.* Philadelphia, PA: W. B. Saunders Co.; 1970.)

internal carotid artery continues to the base of the skull and enters it through the carotid canal of the petrous bone. The internal carotid artery gives off the ophthalmic artery and posterior communicating artery. The internal carotid artery then bifurcates into the middle cerebral and anterior cerebral arteries. The internal carotid artery is the major conduit for blood supply to the middle ear, brain, hypophysis (pituitary gland), eye, and choroid plexus.

The external carotid artery supplies blood to the structures of the neck, face, and skull through eight major branches. They include the superior thyroid, lingual, facial, occipital, posterior auricular, pharyngeal, temporal, and internal maxillary arteries. Many of these branches play an important role in providing collateral circulation to the brain.

The vertebral artery is the first branch to arise from each subclavian artery. Vertebral arteries travel superiorly, passing through the transverse foramen of each cervical vertebra, and enter the skull through the foramen magnum. They then meet and unite to form the basilar artery, which supplies blood to the brain stem, internal ear, cerebellum, and posterior cerebrum.

Communication between the various intracranial and extracranial channels is made possible by an anastomotic loop of vessels near the base of the brain called the circle of Willis (Figure 2). Essentially, the circle of Willis is formed by the union of the anterior cerebral arteries (branches off the internal carotid artery) and posterior cerebral arteries (branches off the basilar artery), which theoretically provide collateral circulation to the various parts of the brain should arteries become damaged or occluded.

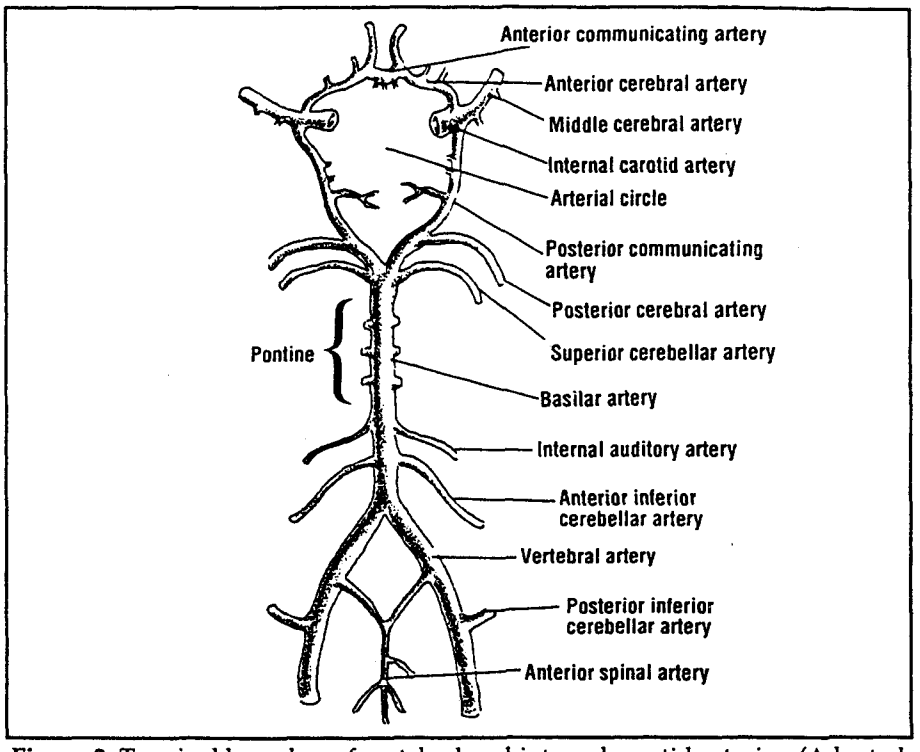

Figure 2. Terminal branches of vertebral and internal carotid arteries. (Adapted with permission from Wylie EJ, and Ehrenfeld WK. *Extracranial Occlusive Cerebrovascular Disease*. Philadelphia, PA: W. B. Saunders Co.; 1970.)

Pathophysiology

The significance of cerebrovascular disease is evidenced by the fact that carotid endarterectomy is the most common vascular operation performed today. According to the American Heart Association, approximately 144,000 deaths each year are attributed to cerebrovascular accidents, making it the third most common cause of death in the United States. In addition, an estimated 500,000 new cases of stroke occur in the United States each year.

Arteriosclerosis is a general term used to describe a group of diseases in which the arterial wall becomes thickened and loses elasticity. Atherosclerosis is a form of arteriosclerosis in which atheromas (a mass or plaque) containing cholesterol and lipoid material are formed within the intima and inner media of large-sized (aortic) and medium-sized (carotid) arteries.

Because atherosclerosis is practically universal, it is considered a process of aging. In general, it affects men over the age of 45 and women over the age of 60. Major risk factors that increase the chances of suffering from atherosclerosis and its complications include high blood pressure, smoking, diabetes, high fat and high cholesterol diet, obesity, and a family history of heart disease and peripheral vascular disease. Being male is also a "risk factor."

Atherosclerosis is the major cause of extracranial cerebrovascular disease in more than 95% of patients. Accumulation of atherosclerotic plaque is usually localized to the common carotid artery near its bifurcation and extends up into the external and internal carotid arteries for a short distance (approximately 1 cm to 2 cm).

Cerebral emboli derived from the atherosclerotic plaque can lodge temporarily or permanently anywhere in the cerebral arterial tree, producing brain ischemia and resulting neurologic symptoms. Whether ischemia and infarction occur depends on the efficiency of collateral circulation. If the blood supply is promptly restored, brain tissues recover and symptoms disappear; however, if ischemia lasts for more than a few minutes, infarction results and neurologic damage is permanent.[3] Cerebral embolization from the atherosclerotic plaque is the single most common cause of cerebral ischemic events.[4]

Clinical Manifestations: Transient Ischemic Attacks

By definition, transient ischemic

attacks (TIAs) are temporary neurologic deficits lasting less than 24 hours and followed by complete recovery. In the areas supplied by the carotid arteries, TIAs are usually discrete motor or sensory dysfunctions. Contralateral facial, arm, or leg motor weakness and sensory loss are the classic presentations.[4] A type of transient attack whereby the patient experiences a temporary monocular loss of vision is called amaurosis fugax. Patients usually describe it as a curtain being drawn down over the eye. Amaurosis fugax results when a microscopic fragment of atheromatous plaque embolizes to the ophthalmic artery, interfering with blood flow in the retinal artery and its branches. The most common source of microemboli is an ulcerative lesion in the internal carotid artery. These emboli are called Hollenhorst plaques after the ophthalmologist who first described them. If the period of ischemia is extensive enough to produce a severe degree of cerebral tissue death and the neurologic deficit is permanent, the episode is classified as a stroke. Depending on the duration of ischemia and the area of the cerebral cortex affected, the resulting deficit may range from minimal, with ultimate recovery of the lost function, to massive, leading to death.[4]

Without treatment, one-third of patients with TIAs will eventually develop permanent neurologic impairment either from the dislodging of a microembolus or thrombotic occlusion of the internal carotid artery, while 20% of patients with amaurosis fugax will suffer a stroke.[5]

Patient Evaluation

Evaluation of patients with symptoms of cerebrovascular disease (TIAs or amaurosis) should include a thorough history-taking and physical examination. Patients should be questioned for symptoms of both carotid artery disease and coronary artery disease since myocardial infarction and stroke during the perioperative period are the greatest risks.

Noninvasive testing of the extracranial portion of the carotid artery is designed to identify a hemodynamically significant lesion of the carotid artery bifurcation. Oculoplethysmography (OPG-Gee) measures ophthalmic artery pressure; OPG Kartchner compares and measures the arrival time of the arterial pulse of one eye with that of the other eye.[6] B-mode ultrasound imaging and duplex scanning provide visualization of the carotid bifurcation for detecting significant carotid artery stenosis.

The "gold standard" for evaluation of suspected extracranial cerebrovascular disease is the conventional four-vessel arteriogram, including views of the aortic arch and intracranial vessels. Cranial computed tomography (CT) plays an increasing role in the diagnosis and management of patients considered for carotid endarterectomy. The patient who presents with a TIA may have actually suffered a small cerebral infarction. CT scanning identifies an unsuspected cerebral infarction and establishes a baseline status before operative intervention.[5] More recently, magnetic resonance angiography (MRA) is being used to study the carotid vessels. Unlike standard angiography, MRA is a noninvasive procedure and does not carry the potential risks associated with standard angiography.

Preoperative Preparation

The objective of carotid endarterectomy for cerebrovascular disease is the removal of atherosclerotic plaque at the carotid bifurcation to prevent stroke and TIAs. This is accomplished by improving blood flow or removing a source of microemboli.[5]

The operating team for carotid endarterectomy at the David Grant Medical Center normally includes a primary surgeon (senior resident); first assistant (staff surgeon); second assistant (junior resident or intern); surgical technologist; circulator; and an anesthesia team consisting of an anesthesiologist and a nurse anesthetist (Figure 3).

The surgeon and first assistant stand opposite one another, with the second assistant positioned at the head of the operating room

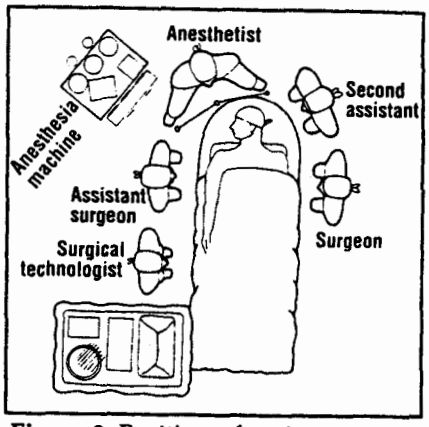

Figure 3. Position of patient, operating room team, and equipment.

table on the primary surgeon's side. This arrangement prevents the additional assistant from coming between the operating surgeons and the surgical technologist and instrument stand.

The patient is positioned on the table in a modified sitting ("beach chair") position with a donut placed under the head. The patient's neck can be hyperextended by placing a rolled sheet transversely at the level of the shoulder blades. The patient's head is turned to the side away from the operative field and secured in position with a piece of tape placed loosely across the forehead and secured to the sides of the operating room table. The operating room table is tilted away from the primary surgeon so the side of the neck being operated on is brought into a more horizontal plane. The neck is prepped with povidone-iodine solution and draped from the lobe of the ear down to the clavicle and across the neck from midline to the posterior aspect of the neck. Electrocardiogram and arterial line are used to monitor and assess the patient throughout the procedure.

Instruments

The basic instruments used for carotid endarterectomy are similar to the standard instruments used in any surgical procedure. The only difference is the addition of vascular forceps, a fine-tipped needle driver, a right-angle clamp, and special scissors for dissecting and opening vessels. Vascular forceps are used to grasp and hold delicate arterial tis-

sues. A right-angle clamp with a fine tip is used to dissect, mobilize, and encircle vessels. Blunt-tipped Metzenbaum and fine-tipped Potts-Smith tenotomy scissors are used to dissect around the vessels. A No. 11 scalpel blade is used to start the arteriotomy and angled Potts-Smith scissors are used to extend the incision in the vessel wall. An assortment of atraumatic vascular clamps is also necessary. The two basic types of vascular clamps include the cross clamp, which is used for total occlusion and control of a vessel, and the partial occlusion clamp, which is used for the occlusion of a portion of a vessel, permitting continuous flow of blood. Vascular clamps come in a variety of shapes and sizes. The jaws may be straight, curved, obtuse, or right-angle in order to accommodate differences in vessel size and angle of application. Vascular clamps have fine teeth or serrations that are offset and interdigitating, allowing them to grip and occlude without slipping or crushing the vessel wall. This minimizes intimal damage and fragmentation of atherosclerotic material.

An assortment of bypass shunts should be available in the room, ready to be put in use if necessary. Normally, the surgeon's preference card will indicate the specific type and sizes to have on hand if a bypass shunt is required to maintain adequate cerebral perfusion during the endarterectomy phase of the operation.

Operative Procedure

The skin incision is made along the anterior border of the sternocleidomastoid muscle (Figure 4). The bovie pencil is used to carry the incision through the subcutaneous layer and the platysma muscle until the sternomastoid muscle is identified. Blunt-edged, self-retaining retractors are placed in the superior and inferior margins of the wound to retract the sternocleidomastoid laterally and the subcutaneous tissue medially.[7] Care is taken to avoid division of sensory and motor nerves transversing the area of the incision.[2] Cranial nerves encountered during dissection include the following: ansa hypoglossi, vagus nerve, hypoglossal nerve, superior laryngeal nerve, glossopharyngeal nerve, and spinal accessory nerve (Figure 5).

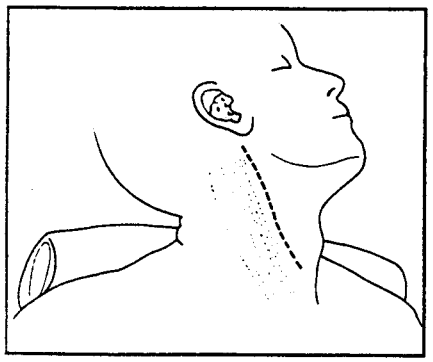

Figure 4. Incision site for carotid endarterectomy.

The carotid sheath is opened and the internal jugular vein and the ansa hypoglossi nerve are identified. The facial vein entering the internal jugular is divided and ligated with 3-0 silk ties, exposing the bifurcation of the common carotid artery and the vagus nerve. The common carotid artery is dissected proximally and encircled with a vessel loop. Manipulation of the carotid vessels during dissection is kept to a minimum to prevent the possibility of embolization. To prevent bradycardia during dissection of the distal carotid vessels, 1 ml of 1% lidocaine is injected in the area of the carotid bulb. The internal carotid, external carotid, and superior thyroid arteries are all dissected, mobilized, and encircled with vessel loops. The hypoglossal and superior laryngeal nerves are also identified.

Once adequate exposure of the proximal and distal carotid vessels is accomplished, the surgeon will ask the anesthesiologist to systemically heparinize the patient. One hundred units of the anticoagulant heparin sodium per kilogram of body weight is administered intravenously and allowed to circulate.

The surgical technologist can use these few minutes to assemble the instruments needed to perform the endarterectomy and place them neatly on the instrument stand.

Arterial control is achieved by placing a medium-sized vascular clamp on the common carotid artery and two small vascular clamps on the internal and external carotid arteries. The superior thyroid artery is also occluded with the application of a small vascular clamp. Some surgeons prefer to double-loop "Potts" the polymeric silicone loop that was previously placed around the artery to occlude it. The double loop eliminates the need to apply a clamp. The two ends of the doubled loop are pulled together and secured to the drape with a clamp.

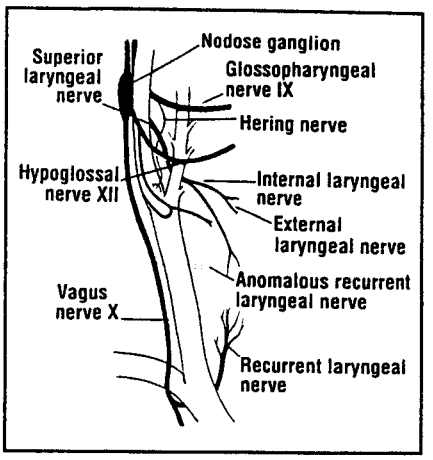

Figure 5. Peripheral nerves around carotid artery.

Endarterectomy

An arteriotomy is initiated in the anterolateral portion of the common carotid artery using a No. 11 scalpel blade (Figure 6). The arteriotomy is extended up into the internal carotid artery beyond the level of the disease and proximally down the common carotid artery using the Potts-Smith scissors (Figure 7).[7] The endarterectomy is started using a Penfield or Freer elevator in the common carotid artery. The proper plane of dissection is established by taking advantage of a natural cleavage plane that develops in the outer tunica media. Atherosclerotic plaque formation will usually only involve the intima and some of the media, leaving the outer layers of the tunica media and the adventitia intact. The endarterectomy plane is continued distally and circumferentially.[7] The plaque is dissected from the internal carotid artery. Care is taken to taper the plane of the endarterectomy to the level of the normal intima in order to leave a

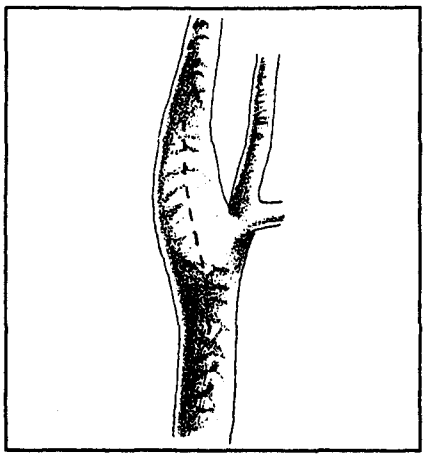

Figure 6. Placement of arteriotomy.

"feathered" distal edge. A No. 15 or Beaver blade can be used to sharply taper the distal edge. Next, the atherosclerotic plaque extending into the external carotid is excised in a similar manner. The proximal portion of the plaque is dissected from the common carotid. Once the plaque has been adequately mobilized from the artery, it is sharply transsected proximally. Following endarterectomy, the arterial lumen is irrigated with heparinized saline and meticulously inspected for residual fragments of plaque or debris. The distal end of the endarterectomy is inspected for any evidence of a distal intimal flap. If present, such a flap is secured in place with a 7-0 vascular suture to prevent further dissection of the flap once blood flow is restored.

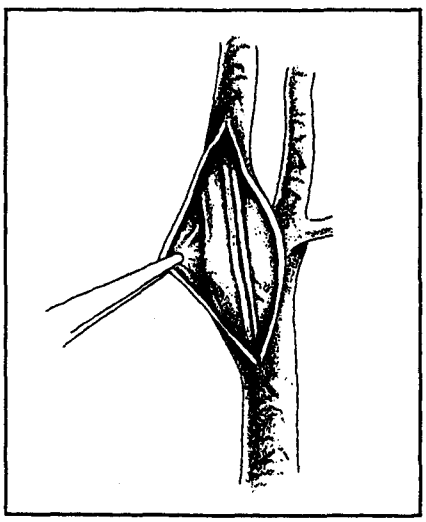

Figure 7. Carotid plaque exposed.

Arteriotomy closure can be accomplished with or without a patch graft. Closure without a patch is accomplished using a continuous running stitch of 6-0 nonabsorbable vascular suture (Figure 8). Frequently, a patch graft composed of polytetrafluoroethylene (PTFE), saphenous vein, or polyester fiber (knitted or woven) is used to close the arteriotomy (Figure 9). Two continuous running stitches of 6-0 nonabsorbable, double-armed vascular suture are used to encircle the patch graft and secure it in place (Figure 10). Prior to final closure, the clamp on the internal carotid is briefly released to back-bleed and flush the vessel (see Figure 10). The clamp is then reapplied. The clamps on the external and common carotid are released separately to flush the arteries in a similar manner after which the clamps are reapplied. The arteriotomy closure is then completed (see Figure 10). Initial blood flow is established by releasing the clamps on the external and common carotid arteries first. The clamp on the internal carotid is removed last. Prior to initial closure, the wound is irrigated with antibiotic solution and carefully inspected to be certain hemostasis is secured. The surgical technologist should have a suitable hemostatic matrix soaked in thrombin and radiopaque sponges available at this time to control oozing through the suture line holes. Active oozing and bleeding may necessitate the use of a closed drainage system. Heparin sodium can be reversed with protamine sulfate. If indicated, a 7-mm flat drain is inserted through a separate stab incision and placed in the wound. The underlying fascia and platysma muscle are closed in layers using a continuous running stitch of 3-0 absorbable suture. The skin is closed with a subcuticular stitch or staples and covered with a sterile dressing.

Complications

Carotid endarterectomy has a low complication rate of 2% to 5%; however, when complications do occur, they can be devastating.[8]

The complications of carotid endarterectomy include cranial

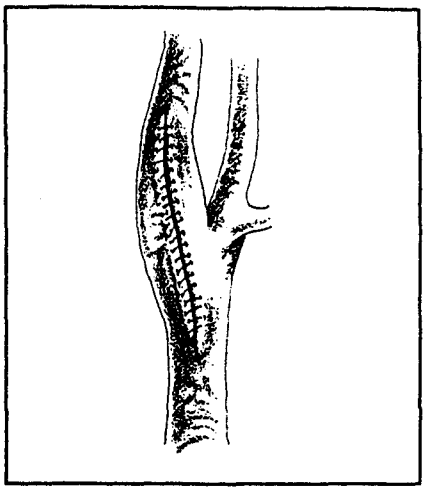

Figure 8. Completed primary closure.

nerve damage resulting from nerve division, excessive traction, or perineural dissection. The most frequently injured nerves are the vagus, the hypoglossal, the recurrent laryngeal, the glossopharyngeal, and the marginal mandibular branch of the facial nerve. Revascularization of a severely stenotic carotid artery may result in the "hyperfusion syndrome," characterized by headache, seizures, and occasionally intracranial bleeding. The most dreaded complication of carotid endarterectomy is perioperative stroke. Perioperative stroke may occur as a result of inadequate cerebral perfusion during the clamp period, embolization of debris from the plaque at the time of operation, or early postoperative thrombosis.[9] The majority of postoperative deaths are due to myocardial infarction.[7] A neck hematoma can devel-

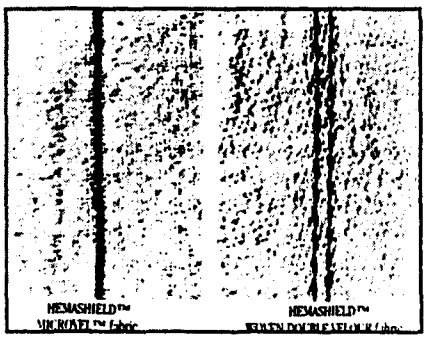

Figure 9. Carotid patch. (Courtesy of Meadox Medical, Inc.)

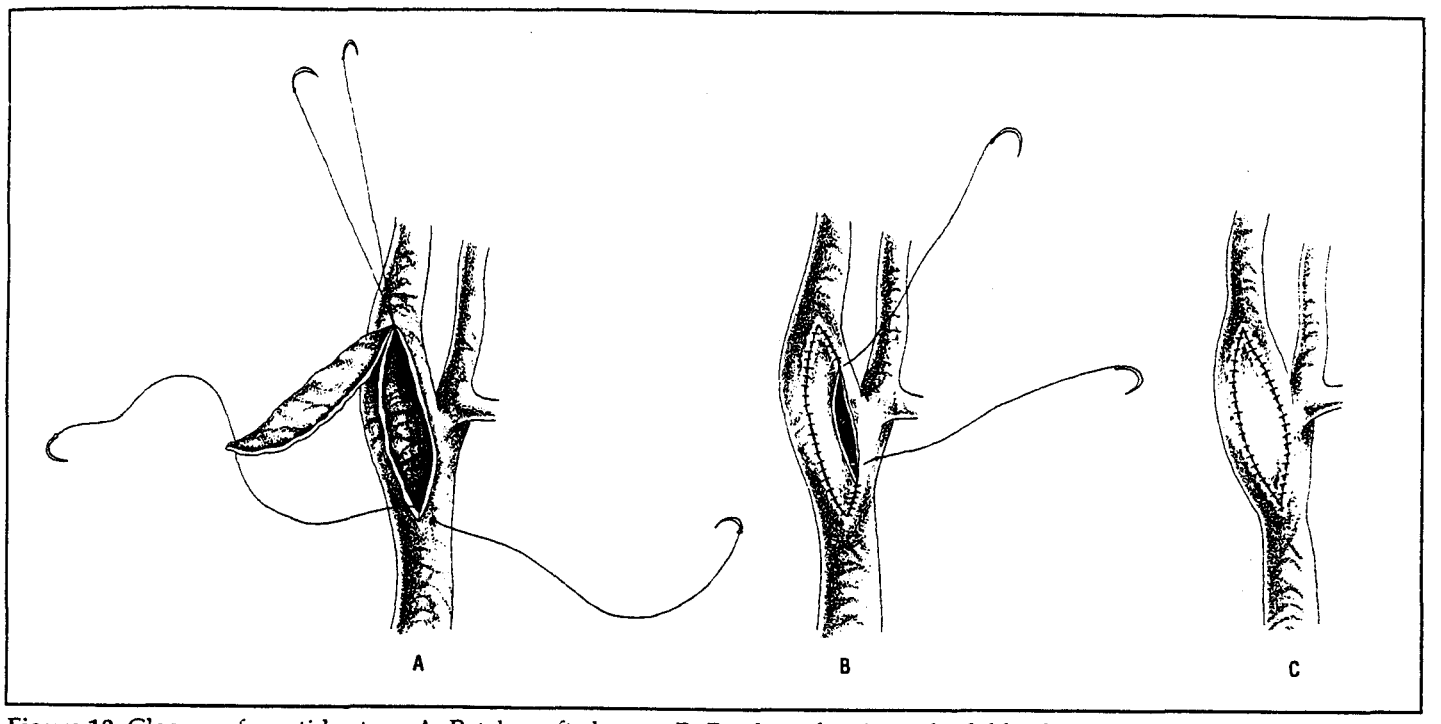

Figure 10. Closure of carotid artery. **A,** Patch graft closure; **B,** Patch graft prior to back bleeding and final closure; **C,** Completed patch graft.

op, resulting in airway obstruction. Other postoperative complications include recurrent carotid artery stenosis and false aneurysm formation.[7]

Postoperative Care

Upon completion of the carotid endarterectomy, the patient is transferred to the surgical intensive care unit and observed closely until the following morning. In the early postoperative period, the patient is monitored for blood pressure-systolic (160 or less) and mean blood pressure (70-80). Ideally, blood pressure should be obtained from an arterial line. Heart rate is watched for the presence of tachycardia. The gauze dressing over the wound is inspected closely for the first 24 hours since excessive bleeding can cause respiratory problems. In addition, the patient is prescribed a daily dose of aspirin (anti-platelet) to minimize the risk of postoperative thrombosis. The patient is started on a clear liquid diet.

Once a stable and satisfactory postoperative status is achieved, the patient is transferred to a regular hospital bed, normally on the second postoperative day. The patient is started on a regular diet. Floor staff continue to monitor the patient's vital signs. If the postoperative phase remains uneventful, the patient is discharged from the hospital on the third postoperative day.

Summary

Carotid endarterectomy is the most common vascular operation performed today. It is a well-established procedure for relief of cerebrovascular insufficiency. Although the procedure is conceptually simple, carotid endarterectomy is a technically unforgiving operation. Even minor deviations in technique can result in irreversible neurologic damage. A well-trained, highly experienced team is essential for a successful outcome. Δ

Acknowledgements

The author would like to sincerely thank Capt Jeff Jenkins, MD, and Capt Dave Harker, MD, for their assistance in preparing this article.

References

1. DeBakey M. *JAMA*. 1955;233:1083-1085.
2. Callow AD. Technical considerations in the conduct of carotid endarterectomy. *The Surgical Technologist*. Mar 1988:8.
3. Berkow R, ed. *The Merck Manual of Diagnosis and Therapy*. 15th ed. Rathway, NJ: Merck Sharp and Dohme Research Labs; 1987:1381.
4. Dean RH. Carotid artery occlusive disease. In: Sabiston DC, ed. *Textbook of Surgery*. 13th ed. Philadelphia, Pa: W. B. Saunders Co; 1986:1581.
5. Krupski WC, Efferney DJ. *Current Surgical Diagnosis and Treatment*. 10th ed. Norwalk, Conn: Appleton and Lange; 1994:748,751.
6. Lore JM. *An Atlas of Head and Neck Surgery*. 3rd ed. Philadelphia, Pa: W. B. Saunders Co; 1988:1037.
7. Jorgensen-Jens E, O'Donnell TF. *Operative Surgery: Principles and Techniques*. 3rd ed. Philadelphia, Pa: W. B. Saunders Co; 1990:960,962,963, 968.
8. Ginzburg E, Houston D, Nunez A, Tabarra M, Evans WE. Aneurysm after carotid endarterectomy: A review of the literature. *Contemp Surg*. June 1994;44: 345.
9. Green RM, Ouriel K. Peripheral arterial disease. In: Schwartz SI, ed. *Principles of Surgery*. 6th ed. New York, NY: McGraw-Hill, Inc; 1994:968,969.

Technical Sergeant Eric J. Zelinskas, BA, *works as a surgical technologist and is the noncommissioned officer in charge of the surgery suite at the David Grant U. S. Air Force Medical Center, Travis Air Force Base, California. He earned associate degrees in surgical technology and education technology at the community college of the Air Force and a bachelor's degree in business administration at Columbia College.*

Earn CE Credit at Home

You will be awarded one continuing education credit for recertification after reading the designated article and completing the exam with a score of 70% or better.

The Education Department will process your exam and send you a postcard notifying you of the credit earned. If you are a current AST member, credit for the exam is automatically recorded in your file; you do not have to submit a CE report form.

Detach or photocopy the answer block, include your check or money order for $6.00 for members or $10.00 for nonmembers payable to the Association of Surgical Technologists, Inc., and send to the Accounting Department, AST, 7108-C S Alton Way, Englewood, CO 80112-2106.

Continuing Education Examination (September 1995)
Carotid Endarterectomy

#109
3-G

Date _____ Cert. No. _____

Name _____

Address _____

City _____ State _____ Zip _____

Chapter or At-Large Region _____ Telephone _____

Mark one box next to each number. There is only one correct or best answer to each question.

	A	B	C	D		A	B	C	D
1.	❑	❑	❑	❑	7.	❑	❑	❑	❑
2.	❑	❑	❑	❑	8.	❑	❑	❑	❑
3.	❑	❑	❑	❑	9.	❑	❑	❑	❑
4.	❑	❑	❑	❑	10.	❑	❑	❑	❑
5.	❑	❑	❑	❑	11.	❑	❑	❑	❑
6.	❑	❑	❑	❑	12.	❑	❑	❑	❑

CUT ALONG DASHED LINE

CE Exam

1. Which of the following vessels is the first branch off of the aortic arch to have oxygenated blood pumped through it?
   A. Internal jugular vein
   B. Innominate artery
   C. Left common carotid artery
   D. Right vertebral artery

2. The external carotid artery supplies blood to the structures of the neck, face, and skull through ___ major branches.
   A. six
   B. seven
   C. eight
   D. nine

3. According to the American Heart Association, cerebrovascular accidents account for approximately ___ deaths each year.
   A. 120,000
   B. 125,000
   C. 136,000
   D. 144,000

4. A type of transient ischemic attack (TIA) whereby the patient experiences a temporary monocular loss of vision is called
   A. Bell's palsy.
   B. LeRiche syndrome.
   C. amaurosis fugax.
   D. Skidmore disease.

5. Which of the following diagnostic methods is considered the standard for evaluation of extracranial cerebrovascular disease?
   A. B-mode ultrasound imaging
   B. Magnetic resonance angiography (MRA)
   C. Duplex scanning
   D. Conventional arteriogram

6. The patient is placed on the operating room table in which of the following positions for carotid endarterectomy?
   A. Lateral
   B. Modified sitting "beach chair"
   C. Fowler's
   D. Ginzburg

7. A No. ___ blade is used to start the arteriotomy, and angled ___ scissors are used to extend the incision in the vessel wall.
   A. 10, Mayo
   B. 11, Potts-Smith
   C. 12, Metzenbaum
   D. 15, Jorgenson

8. Cranial nerves encountered during dissection include all of the following except the
   A. peroneal nerve.
   B. vagus nerve.
   C. ansa hypoglossi nerve.
   D. superior laryngeal nerve.

9. Normally, the underlying fascia and platysma muscle are closed using a continuous running stitch of ___ absorbable suture.
   A. 2-0
   B. 3-0
   C. 4-0
   D. 5-0

10. Which of the following postoperative complications could result in an airway obstruction?
    A. Stroke
    B. Myocardial infarction (MI)
    C. Neck hematoma
    D. All of the above

11. A ___ clamp is used to dissect, mobilize, and encircle vessels.
    A. Crile
    B. tonsil
    C. Kelly
    D. right-angle

12. The skin incision is normally made along the anterior border of the ___ muscle.
    A. masseter
    B. temporal
    C. sternohyoid
    D. sternocleidomastoid