CE Examination
Category 1

Surgical Treatments of Peripheral Vascular Disease

Terry Sweno, CST, and Mickie Stelck, CST

Varicose veins are the world's most common disease of the lower limbs. An estimated 40 percent of the US population is affected to some degree, accounting for 4.6 million days of work missed each year. A varicose vein is defined as any size vein that has elongated, dilated and become tortuous. Spider veins (telangiectasis) are intradermal varicosities that are small and usually asymptomatic. Risk factors for varicose veins include obesity; pregnancy; standing or sitting for long periods; a low fiber diet, which causes constipation (more in Western countries); heavy lifting; or hematologic factors. Women are more prone to varicosities than men.

Treatments for peripheral vascular disease, either medical or surgical, must be implemented if prevention fails. Consequences for non-treatment may lead to serious complications or even death for those at risk. New techniques can lead to better end results.

Varicose veins can result in valve damage, thus a higher risk of thrombosis. Phlebitis, usually occurring in the lower leg, presents with symptoms of pain, redness and swelling. Venous insufficiency caused by a thrombus can lead to a potential risk of a pulmonary embolus (PE). Without treatment it causes an estimated 150,000-200,000 deaths annually in the United States. Twenty percent of PEs develop in the proximal venous system in the calf. The risk of not treating a proximal venous thrombus can lead to a 10 percent risk of a fatal PE and a 50 percent risk of a non-fatal PE.

VEINS IN THE LEGS

The venous return system for the legs is divided into two sets, superficial and deep. The superficial system includes the internal, external saphenous veins and their branches. The internal or greater saphenous vein begins on the dorsum of the foot, medially on the arch side, and ascends on the inner aspect of the lower leg to the knee. At this point the greater saphenous goes behind the femoral condyle and continues up the medial aspect of the thigh, terminating at the femoral vein about 4 centimeters below Poupart's ligament. Branches include the internal plantar, anterior tibial, articular (at the knee) and one or more veins into the femoral. (See Figure 1.)

The external or lesser saphenous vein begins on the lateral aspect of the arch on the dorsum of the foot and ascends the posterior aspect of the leg directly in the midline, terminating at the popliteal vein between the two sections of the gastrocnemius muscle. The valves in this vein number three through nine, versus two through six in the greater saphenous, with one valve in the short vein always found near the junction with the popliteal. The lesser saphenous does give off a connecting branch with the greater saphenous before penetrating deep into the leg.

The deep venous system includes external and internal plantar veins, anterior tibial, popliteal, femoral, external iliac, and internal iliac. This system, because of its location in softer tissue, tends to be the location for more peripheral vascular diseases including varicose veins and deep venous thrombus (DVT).

EVALUATING PERIPHERAL VASCULAR DISEASES (PVD)

Evaluation of PVD is performed by either Duplex scanning or venography. Duplex scanning uses a Doppler probe to trace the vessels and determine valvular function. The patient, while in a nearly upright position during the examination, has

a pneumatic cuff around the calf. If the duplex scan shows a deep venous occlusion, the next step is venography.

Venography is accomplished by injecting IV contrast dye into a superficial vein on the dorsum of the foot, while the patient is in a 30 to 40 degree upright position. A tourniquet inflated around the ankle allows the deeper veins to fill with contrast dye. Radiographic images are taken while the affected leg is elevated 6 inches to continue an ascending venous flow.

Descending venography is performed to determine valve reflux. The patient position is also 30 to 40 degrees upright; however, venous access is achieved through the common femoral vein via a 4 or 5 fr short straight catheter. Valve reflux is graded as follows:

Grade 1: Limited to upper thigh
Grade 2: Limited to lower thigh
Grade 3: Involves the popliteal vein
Grade 4: Severe infrapopliteal involvement

A grade 3 or 4 valve reflux with recurrent symptoms may require deep valve repair or valve transplant.

Venous and valvular insufficiency can then cause venous pooling, which in turn can lead to ulcers. Ulcers are preceded by dark brown pigmented skin and, 95 percent of the time, develop in the ankle area or "gait" zone. Venous ulcers can require more than a year to heal, and, if there is deep venous involvement, their recurrence rate is 72 percent. (See Figure 2.)

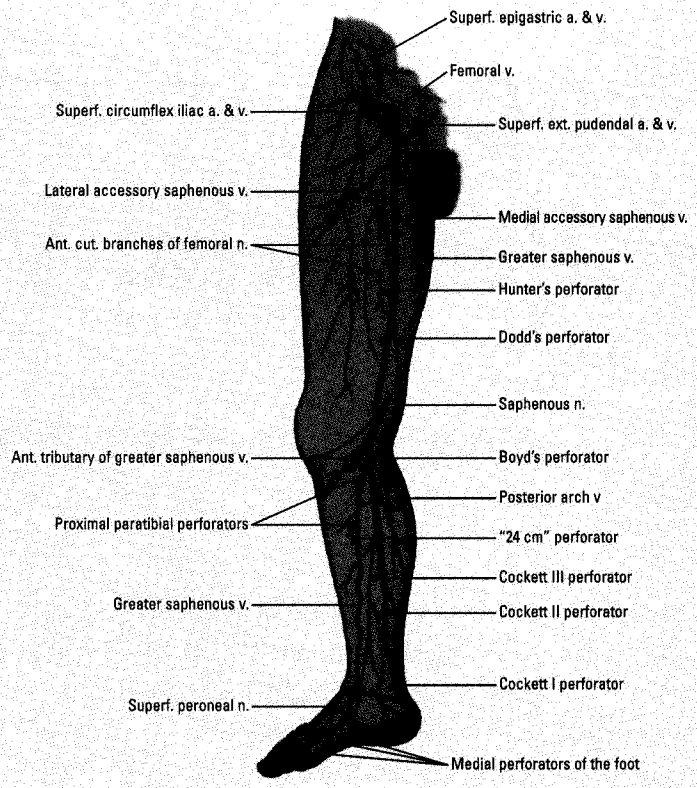

FIGURE 1 shows the superficial and deep venous return systems in the leg.

NON-SURGICAL TREATMENTS OF PVD

For those at risk, prevention of PVD is, of course, the goal. If prevention should not prevail, some cases can be treated non-surgically. Prevention steps include exercise—especially after sitting or standing for long periods—if only to flex the lower legs and ankles. Wearing support stockings will apply pressure on the legs to prevent pooling. Elevation of the legs helps reduce swelling and facilitates venous return. Mechanical compression devices, applied preoperatively and used during the surgical procedure, will aid with venous return.

Superficial disease treatments include elevation, heat and anti-inflammatory drugs. Deeper venous involvement incorporates anticoagulants, first intravenously then orally, to prevent clot growth.

SURGICAL TREATMENTS OF PVD

Several conventional procedures are used for venous incompetence or obstruction. For incompetence, saphenous vein stripping, avulsion of incompetent varicosities, valve repair, autotransplant of valves or perforator ligation may be used.

Procedures for obstruction include bypass procedures and venous angioplasty, either with or without stenting. These are all performed with standard soft tissue and vascular instruments. A newly developed procedure is endoscopic perforator vein stripping. The procedure mimics current techniques; however, the instruments and ancillary equipment used compares with an abdominal laparoscopic procedure.

Skin pigmentation is the most frequent initial sign of chronic venous disease; pain is the most frequent symptom. Varicose veins are noted in half of the patients. Seventy percent have at least one active ulcer at the time of surgery. Most ulcers were larger than 2 centimeters and had recurred more than once.

Preoperative evaluation studies include the duplex scanning of the leg veins in 110 patients, ascending or descending venographies in 74 patients, and evaluation by impedance, strain gauge, air or photo-plethysmography in 50 patients.

Prior to surgery, all patients received non-operative treatment for venous disease that included compression stockings, elastic wrap or unna boots. Preoperative patient compliance with non-operative management was estimated at 75 percent.

FIGURE 2—Venous and valvular insufficiency can lead to venous pooling, which can lead to ulcers.



FIGURE 3 shows the endoscopic view of the vein, endo clips and scissors.

(See Table 1.) Several patients had undergone surgical treatments for their disease before subfascial endoscopic perforator surgery (SEPS).

A family history is taken to verify symptoms originate from a deep venous problem and not a traumatic injury. SEPS surgery begins with the patient, in the supine position, receiving general anesthesia. Prepping is performed circumferentially from umbilicus to toes. A sterile 6-inch stockinette is placed on the operative leg(s), and sterile drapes are used underneath to elevate the leg 10 inches. Using a ruler, the legs are marked for the port insertions. A sterile tourniquet is placed above the knee, and the stockinette is rolled over the leg. A 6-inch Esmarch bandage is applied over the stockinette from the toes to the tourniquet. The tourniquet is inflated to 300 atmospheres, and the Esmarch is removed.

One small incision is made in the leg with a #10 knife blade, followed by dissection using Metzenbaum scissors and small tissue forceps (Adson or Debakey). Upon reaching fascia, a #11 blade and right-angled forceps create an opening for a 12-millimeter Endopath port. A blunt end glass rod replaces the trocar. When the port is inserted and tubing for the CO_2 is attached to the stopcock and inflated, the glass rod is removed; and a 10-millimeter 0-degree lens is placed in the port for viewing. A second incision is made in the same manner creating another 12-millimeter port, and 10-millimeter endo metz scissors are placed inside.

Dissection with the scissors under vision proceeds down the leg until a venous perforator is located. An endo clip applier is inserted to place two ligating clips on the perforator then the tissue is cut in between. (See Figure 3.) A harmonic scalpel may also be used. Ligating clips are not desirable in that area. If an avulsion, a small stab wound, is made in the vein, a #5 crochet hook is inserted to elevate the vein, and the vein(s) are removed with small curved clamps.

When performing a saphenous vein stripping, incisions are made at the groin and ankle. Using silk ties at the groin and Vicryl ties at the ankle, side branches are ligated. A #11 blade opens the saphenous vein distally, and a Codman stripper with the appropriate-sized bullet head on the end is inserted up the vein. The vein is then removed, and the large incisions are closed with layered Vicryl sutures. The small incisions are approximated with adhesive strips. Next, the leg is washed and dried then dressed with gauze and ace wraps.

Equipment and instruments needed for an endoscopic procedure include: CO_2 tanks and insufflator, light source, two TV monitors, electrocautery, pneumatic tourniquet machine, harmonic scalpel, soft tissue and vascular instrumentation, and the endoscopic instrumentation. Arrange the

TABLE 1 Non-operative management of 148 patients

Type of treatment	Patients (no.)	%
Compression stockings	114	77
Elastic wrap	39	26
Unna boot	77	52
Leg elevation	77	52

FIGURE 4—Equipment and instruments for peripheral vascular surgery must be arranged around the patient so that everything is accessible.

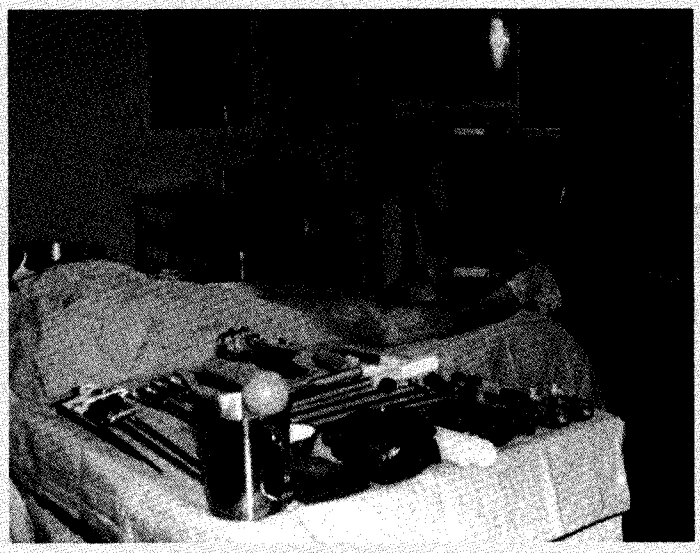

FIGURE 5 shows the equipment and arrangement for an operating room set up for surgical treatments of PVD.

equipment around the patient to have everything accessible for those working. (See Figures 4 and 5.)

POSTOPERATIVE CARE

Postoperative care is not complicated. The leg(s) is kept elevated, and prescription pain medication is given to the patient, who may go home either the same or the following day. One week later the patient is seen for a dressing change and fitted for compression stockings. The patient may return to work in two weeks if progress continues.

Complications are few, but wound infection is still the main problem. Infection appears to occur less frequently than following open procedures. Clinical follow-up to determine ulcer healing was available on 85 of 104 patients with active ulcers. During early follow up, healing occurred in 88 percent of the patients. (See Figure 6.)

The average length of follow up was 5.4 months for those whose ulcers healed and 7.1 months for patients whose ulcers did not heal. Postoperative results have shown that the probability of ulcer healing was 67 percent at 90 days and 79 percent at 180 days. Ulcer duration, history, recurrence or multiplicity did not significantly influence healing, but small ulcers healed much faster than larger ones.

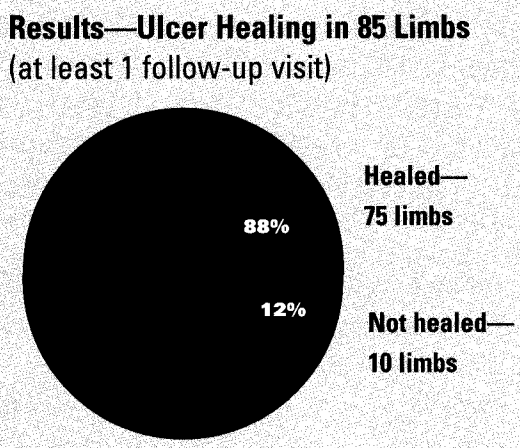

FIGURE 6—Results from North American Subfascial Endoscopic Perforator Surgery are overwhelmingly positive.

CONCLUSION

Endoscopic perforator vein surgery is safe with no deaths and no clinically evident thrombosis complications noted within 30 days postoperative. Careful patient selection, avoiding operations in patients with other significant, underlying, deep venous occlusions, and, most importantly, perioperative thrombosis prophylaxis is recommended for patients prone to develop thrombotic complications.

AUTHOR BIOGRAPHY

Terry Sweno is a 20-year CST at the Mayo Clinic, Rochester, Minn, specializing in vascular surgery. Mickie Stelck, CST, has 16 years' experience working for the Mayo Clinic at St Mary's Hospital. She specializes in bronchoscopy and urology.

The authors would like to thank Dr Peter Gloviczki for his assistance with this manuscript.

REFERENCES:

Gloviczki, Peter, and Bergan, John, eds. *Atlas of Endoscopic Perforator Vein Surgery*. Springer-Verlag London Limited:1998.