CE Examination Category 1

Endoscopic Saphenous Vein Harvesting

Kenneth J Elder Jr, CST

Since the inception of coronary artery bypass grafting surgery, surgeons have been trying to minimize the trauma associated with saphenous vein harvesting in order to maximize long-term graft patency.

Until recently, an extended incision along the medial aspect of the leg has been the traditional way to access the saphenous vein. This procedure, though effective, is replete with associated morbidity and complications. Some of the primary complications associated with this procedure are infection, pain, and tissue trauma resulting in prolonged convalescence.[3,6,12]

As technology in the area of minimally invasive surgery has been developed, one method has achieved some impressive results in the area of endoscopic vein harvesting. The VasoView Uniport™ Endoscopic Vessel Harvesting System, which uses CO_2 insufflation, permits the complete harvest of the saphenous vein through a 2 cm incision. (Figures 1 and 2.)

The VasoView System uses a 5 mm extended length endoscope, a 12 mm blunt tip trocar, a conical tip dissection cannula, bipolar scissors, and an extended cannula with a vein cradle for skeletonization of the vein.

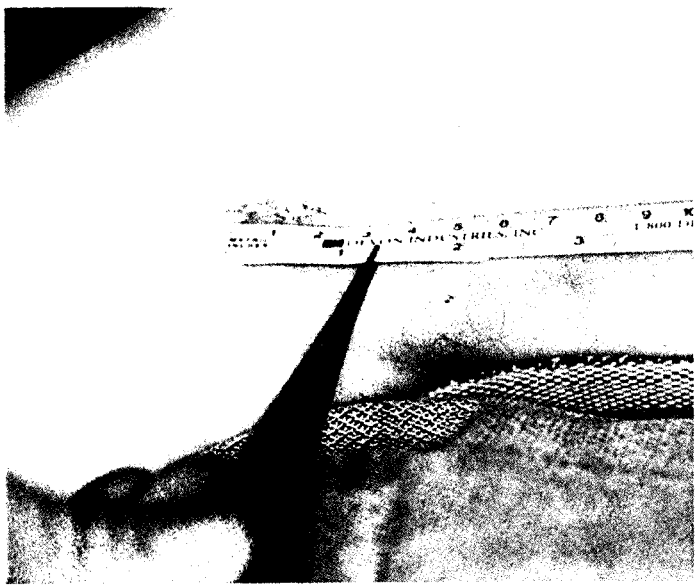

FIGURES 1 AND 2—The endoscopic method permits the complete harvest of the saphenous vein through a 2 cm incision. The traditional method left the patient with a long scar and possible complications including infection, pain, and tissue trauma.



FIGURE 3—After locating the saphenous vein, a vessel loop should be placed around the isolated vein.

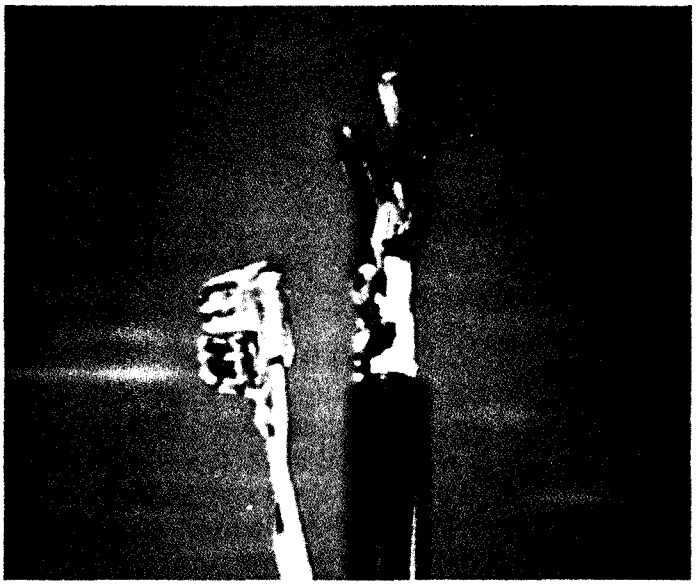

FIGURE 4—The VasoView Uniport™ Dissection Cannula is used for tributary cauterization and division.

SET UP

The set up for endoscopic vein harvesting requires a video monitor, a video camera, a CO_2 insufflator and delivery system, and a fiberoptic light source and cable.

Other items needed for the case include:

Sterile items:

- VasoView System (components listed above)
- Bipolar cord
- Anti-fog solution
- Water-soluble lubricant
- Vessel loop
- Scalpel handle
- #11 blade
- Senn or other comparable retractor
- Army/Navy retractor
- 6-inch or 7-inch right-angle hemostat
- 6-inch or 7-inch Crile or Kelly
- Ligature (manual clips, small and medium, with appliers or suture, absorbable and non absorbable)
- Minor instrument set (available but not open)
- Back-up sterile endoscope (available but not open)

Non-sterile items:

- Endoscopic video cart (components listed above)
- CO_2 tank
- Bipolar generator and foot pedal
- Cosgrove pillow or alternate leg support for positioning the legs

The patient is prepped and draped in a sterile fashion so that both legs are fully accessible. A linen-constructed prop is placed under the leg near the popliteal fossa, with a slight frogging to promote access.

The lines for the video camera, light source, and insufflation are passed off to the circulating nurse for connection.

OPERATIVE PROCEDURE

A 2 cm incision is made on the medial aspect of the knee adjacent to the patella, 2 cm above the popliteal crease. The saphenous vein is located via sharp dissection so the adventitial layer of the vein is clearly exposed and is isolated with a vessel loop. (Figure 3.)

Next blunt dissection is used to create access for the 12 mm blunt tip trocar. Following insertion of the trocar, the VasoView dissection cannula is advanced through the blunt tip trocar. (Figure 4.) Once inserted, the cannula is advanced approximately 4 cm keeping the conical tip on the anterior surface of the vein. The balloon on the blunt trocar is inflated with 25 cc of air, the insufflation line is connected, and a minimum flow of 3-5 L at 10-12 mm Hg is initiated.

This creates a webbing effect of the surrounding tissues, separating them from the saphenous vein. (Figure 5.) The

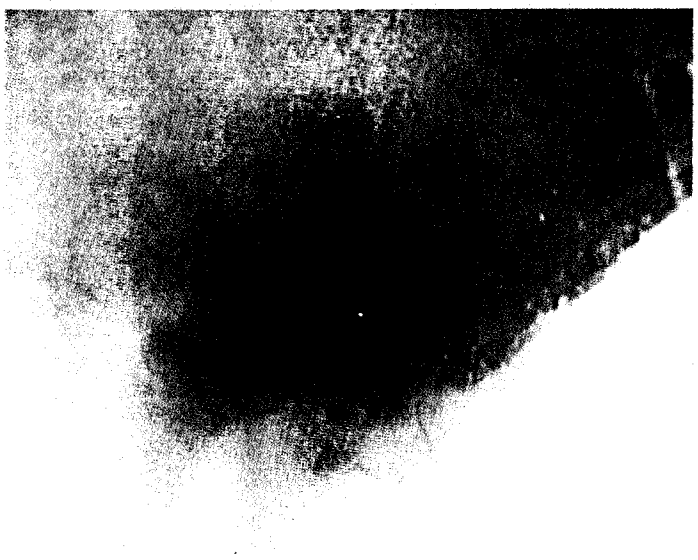

FIGURE 5—When inflated, the balloon on the blunt trocar creates a webbing effect of the surrounding tissues, separating them from the saphenous vein.

FIGURE 6—Rotating the uniport and retracting the main trunk of the saphenous vein exposes the tributary for transection.

conical tip of the cannula is then advanced along the vein to the desired length of the graft. The dissection is done along superior, inferior, medial and lateral aspects of the vein. Tributary branches are gently exposed during this part of the procedure. Once the dissection is completed, a skeletonized vein should remain in the center of the canal (Figure 6.)

Next the bipolar scissors are inserted into the extended cannula. After inserting the uniport into the tunnel, the vein cradle is advanced along the vein to clear tissue and facilitate exposure to tributary branches, which are then cauterized with the bipolar scissors. As soon as all of the tributary branches are cauterized proximally and distally as required for the specific length of vein, an incision is made with a #11 blade at the proximal end of the leg near the groin. A hemostat is inserted into the incision, and the vein is lifted up through the incision to ligate the distal end with non absorbable suture and resect it.

The uniport dissection cannula is then withdrawn. The blunt tip trocar is deflated and removed. The proximal end of the vein is ligated and resected before the vein is removed for final preparation. A standard vein distention kit using a heparinized saline solution is used to distend the vein graft. Branches of the graft are then ligated with 4-0 silk suture tie, before placing the graft in a heparinized saline solution.

The graft is then irrigated with 300 to 500 cc of heparinized saline and placed in a heparinized saline solution. To alleviate any spasms that may have occurred during harvesting, absolution of 2 mg of Papaverine to 100 cc of normal saline may be injected through the lumen. If this solution is used, then the graft must be irrigated again with the heparinized saline solution.

Residual blood is then expressed from the leg by rolling a lap sponge along the medial aspect of the leg from proximal to distal (groin to popliteal fossa). An optional drain can be inserted to collect any residual blood. A flat Jackson Pratt drain is inserted through a separate incision made by a #11 blade and sutured into placé by a 3-0 silk suture ligature. The incisions are then closed with absorbable suture and the wound is dressed with steri strips. (Figure 7.)

CONCLUSION

The reduction of trauma associated with endoscopic vein harvesting will bring about a significant number of benefits, which include minimization of patient pain and potentially accelerated ambulation. Early data from a clinical study comparing minimally invasive saphenous vein harvesting to traditional vein harvesting found that endoscopic procedures significantly reduced pain and led to earlier and improved ambulation.

As impaired wound healing occurs in up to 44 percent of traditional saphenous vein harvesting incisions,[1] smaller incisions associated with endoscopic vein harvesting should help improve postoperative healing.[2,3,4,5] (Table 1.)

TABLE 1—POSTOPERATIVE COMPLICATIONS FROM TRADITIONAL VEIN HARVESTING METHODS

	COMPLICATION RATE	NATURE OF WOUND COMPLICATION	STUDY DESIGN	REFERENCE
Wipke-Tevis DD et al	43.8%	Prolonged erythema and/or drainage; separation of superficial wound edges*	Prospective descriptive	Heart Lung 1996;25(2):108-116
Utley JR et al	24.3%	Inflammation; separation; cellulitis; lymphangitis; drainage; necrosis or abscess requiring dressings, antibiotics or debridement	Prospective descriptive	J Thorac Cardiovasc Surg 1989;98:147-149
Wong SW et al	10%	Wound infection defined as purulent drainage and erythema of wound edges	Prospective descriptive	Aust NZ J Surg 1997;67:689-691
Farrington M	12.9%	Infections in which purulent drainage or erythema was observed	Retrospective	Br J Surg 1985;72:758-762

* *Other eligible complications not seen in this series included purulent exudate, deep tissue separation, additional treatment (antibiotics, pus drainage, or debridement), isolation of bacteria, and inpatient stay >14 days.*

With the reduction of postoperative complications, there may be a reduction in length of stay for some coronary artery bypass grafting patients. One study found hospital length of stay to nearly double for patients who develop wound complications from traditional saphenous vein harvesting techniques.[9,10]

Endoscopic technology has been in use for many years and in many specialties. As the technology of endoscopic surgery evolves, quality of patient care should continue to improve. With the advent of endoscopic saphenous vein harvesting, the coronary artery bypass patient now has a less painful, less complicated and less traumatic modality of treatment.

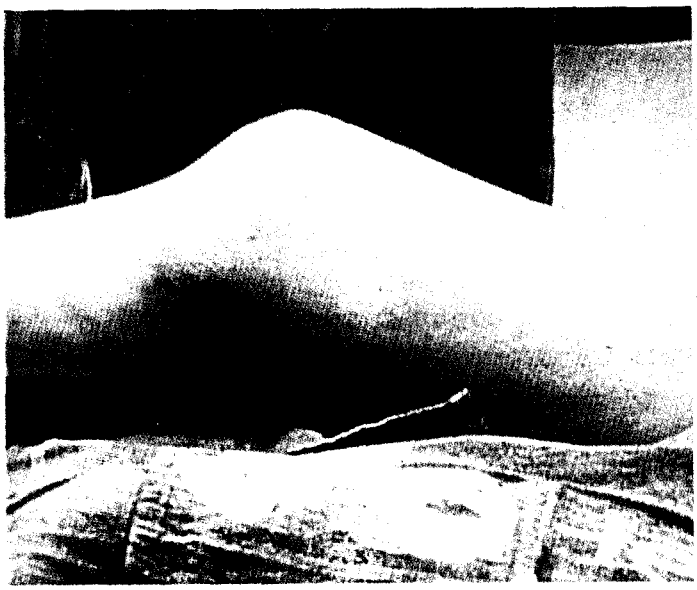

FIGURE 7—Absorbable suture is used to close the incision.

ABOUT THE AUTHOR

Kenneth Elder, CST, is a staff surgical technologist working with the open heart team at Peninsula Heart Center in Salisbury, Md. He graduated from the Harris County Hospital District School for Surgical Technicians at Ben Taub Hospital Houston, Texas, in 1983.

REFERENCES

1. Crouch J, et al. Endoscopic vein harvesting for coronary artery bypass grafting. 6th *World Congress of Endoscopic Surgery, Oral communications, Posters, and Videos*. June 1998;881-885.
2. Wipke- Tevis DD, et al. Frequency, manifests, and correlates of impaired healing of saphenous vein harvest incision. *Heart Lung*. 1996;25(2):108-116.
3. Utley JR, et al. Preoperative correlates of impaired wound healing after saphenous vein excision. *J Thorac Cardiovasc Surg*. 1989;98: 147-149.
4. Wong SW, et al. Leg wound infections associated with coronary revascularization. *Aust NZ J Surg*. 1997;67:689-691.
5. Farrington M. Study of cardiothoracic wound infection at St. Thomas' Hospital. *Br J Surg*. 1985;72:759-762.
6. Morris R. Facts and myths of minimally invasive cardiac surgery. *Present. at Current Trends In Thoracic Surgery IV*. January 1998.
7. Lee J. Minimally invasive vein harvesting: the second generation. *Surgic. PA*. 1998;4(6):23-36.
8. Kaiser AB, et al. Efficacy of cefazolin, cefamandole, and gentamicin as prophylactic agents in cardiac surgery: results of a prospective, randomized, double-blind trail in 1030 patients. *Ann Surg*. 1987;206(6):791-797
9. DeLaria GA, et al. Leg wound complications associated with coronary revascularization. *J Thorac Cardiovasc Surg*. 1981;81:403-407.
10. DeSisto MG, et al. Risk factors for impaired wound healing at the saphenous venectomy site after coronary artery bypass graft surgery. *Cardiovasc Nurs*. 1996;32(6):37-41.
11. Kshettry V, et al. Results of minimally invasive saphenectomy. *ISMICS Annual Meeting Abstract*. 1998.
12. Chin A, et al. Endoscopic cardiovascular vessel harvesting. 6th *World Congress of Endoscopic Surgery, Oral Communications, Posters, and Videos* June 1998;875-879.