Femoropopliteal Bypass Graft

Eric J Zelinskas, CST, BA

Human arteries carry oxygenated blood ejected from the left ventricle of the heart to all areas of the body (except the lungs). Normally, arteries have a smooth inner lining, (endothelium) called the tunica interna (intima), that prohibits blood from clotting and facilitates optimal blood flow. However, hyperlipidemia, cigarette smoking, hypertension, diabetes, trauma and age contribute to vessel narrowing and loss of intimal continuity, resulting in thrombus and clot formation.[1]

Peripheral arterial disease (PAD) belongs to a group of diseases in which the arterial wall becomes thickened and loses elasticity. The general term that defines this group is arteriosclerosis.[2] Other names for peripheral arterial disease include hardening of the arteries and, the more recognized term, atherosclerosis. In atherosclerosis, a form of arteriosclerosis, atheromas (masses of plaque) containing cholesterol, lipid material and lipophages are formed in the large and medium-sized arteries.[2] It is the major degenerative disease of human arteries and plays a significant role in vessel obstruction. (Figure 1)

Atheromas usually develop adjacent to arterial bifurcations and the origins of major arterial branches. This includes the aorta, aortoiliac, common femoral bifurcation, common carotid bifurcation, superficial femoral, and popliteal.

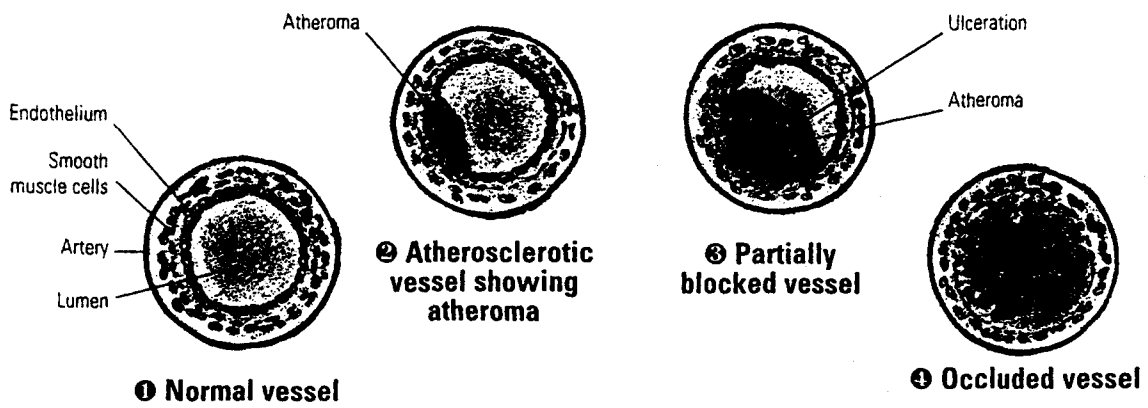

FIGURE 1—STAGES OF ATHEROSCLEROSIS

Gradually, plaque deposits accumulate, narrowing the lumen of the artery. Cellular components, consisting of platelets and fibrin, aggregate on the rough intimal surface, leading to the development of a thrombus within the lumen of the artery. Such a thrombus may progress to occlusive thrombosis or may fragment to produce thrombotic embolization.[3] Subsequently, the affected arteries become constricted, impeding or even blocking arterial blood flow to organs such as the brain, heart, kidneys, lungs and lower extremities. This condition, called ischemia, will result in tissue damage and, if left untreated, can lead to tissue death (necrosis).

The lower extremities are the most common part of the body affected by peripheral arterial disease, which afflicts between 8 to 15 million people nationally. The ravages of peripheral arterial disease on the lower extremities is evidenced by the fact that approximately 100,000 amputations are performed annually in vascular surgery for either gangrene or irreversible, painful ischemia not amenable to vascular reconstruction.[1]

PERIPHERAL ARTERIAL INSUFFICIENCY

Peripheral arterial insufficiency is predominately a disease of the lower extremities.[6] The obstructive lesions are distributed widely (aortoiliac, femoropopliteal and tibioperoneal), and symptoms are related to the location and number of focal lesions. A certain percentage of patients with peripheral vascular disease will have disease involvement in more than one area and have concomitant coronary artery disease. No matter where the obstruction is located, the physiological deficit is decreased blood flow to the lower extremities with symptoms ranging from intermittent claudication to gangrene.

BLOOD FLOW

Hemodynamics refers to the physical characteristics of blood and the physical principles of blood flow through the vessels of the circulatory system, including the interrelationships among pressure, flow and resistance.[4]

Blood is a viscous fluid composed of cells and plasma.[4] The percentage of whole blood that is erythrocytes or RBCs is called the hematocrit. Plasma is the fluid portion of the blood, in which the cells (erythrocytes, leukocytes and platelets) are suspended.

Blood pressure (BP) is the pressure of the blood on the walls of the arteries. Blood pressure is dependent on the energy of the heart action, elasticity of the arterial walls, and volume and viscosity of the blood. Blood flow is directly proportional to pressure in the circulatory system.

Blood flow means simply the quantity of blood that passes a given point in the circulation during a given period of time. Ordinarily, blood flow is expressed in milliliters or liters per minute.[4]

The overall blood flow in the circulation of an adult person at rest is about five liters per minute. This is called the cardiac output because it is the amount of blood pumped by the heart in a unit period of time.[4]

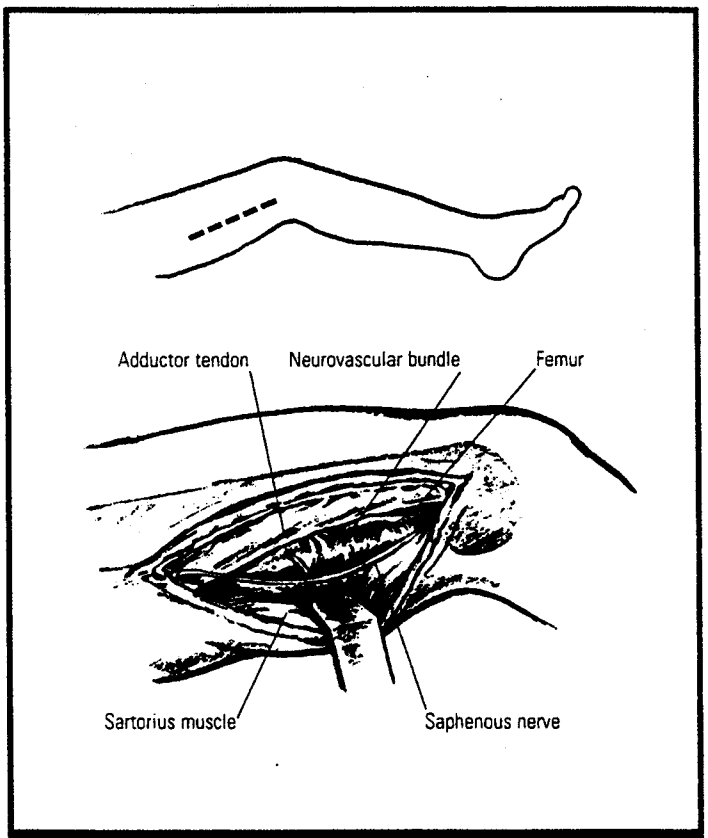

FIGURE 2—EXPOSURE, PROXIMAL POPLITEAL ARTERY

Blood flow is opposed by the force of resistance. This means that the relationship between flow and resistance is an inverse one. As resistance increases, flow decreases, and as resistance decreases, flow increases.[5]

Several factors contribute to resistance, such as blood viscosity, velocity, type of blood flow, the arrangement and length of blood vessels, and radius of the vessel.[5] (The radius of the vessel imparts the single most significant effect on resistance, ie decreasing the radius by half increases the resistance by a factor of 16). When the radius decreases, the friction of the blood

flow against the wall of the artery increases. The flow of blood decreases, and the cells in affected organs may not receive the necessary oxygen and/or excrete toxic metabolic wastes.

In addition, the accumulation of plaque can change the structure of the inner lining of the arterial wall, thereby increasing turbulent flow and resistance.

TYPES OF BLOOD FLOW

Laminar flow. This flow is smooth or streamlined. It is called laminar because the blood flows in layers or laminae in smooth-walled vessels. These layers slide over each other, creating a parabolic (side-by-side) profile of laminar flow. This profile indicates parallel movement of molecules. The velocity of flow of the layers differs. Layers toward the center flow faster, those closer to the wall flow more slowly, and those against the wall do not move at all.[5]

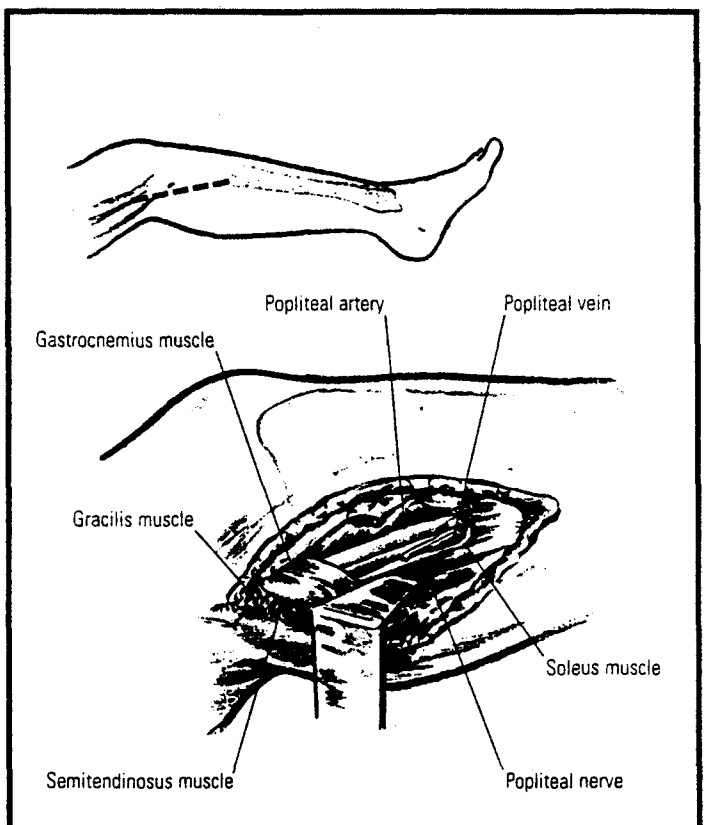

FIGURE 3—EXPOSURE, DISTAL POPLITEAL ARTERY

Turbulent flow. This flow is not streamlined, but moves crosswise, generating whorls, eddies, or swirls. These patterns occur as a result of obstruction or uneven edges in the vessel walls, in conditions such as atherosclerosis or in areas of shear stress (ie the tendency for the vessel epithelium to be pulled along by the flowing blood, which causes it to deform). Injury occurs especially at points where arteries branch. Turbulent flow alters the parabolic profile. It slows velocity around obstructions, increases resistance to flow, and results in a decreased flow. Atherosclerosis develops with subsequent injury to the intima, particularly at arterial bifurcations where shearing forces and turbulent flow are highest. Cellular components (ie platelets and fibrin) can then adhere to each other and to the intima, resulting in thrombus or clot formation.[5]

RISK FACTORS

Estimates of the number of men and women who have peripheral arterial disease begin at eight million. Several risk factors are commonly present: age of 50 or older; diabetes; history of heart disease; smoking; high blood pressure; high cholesterol; and high levels of the amino acid homocysteine.

CLINICAL MANIFESTATIONS OF PERIPHERAL ARTERIAL INSUFFICIENCY

Peripheral arterial disease can be challenging to diagnose, because individuals may have the condition and not show any of the previously mentioned symptoms and risk factors. To confuse things further, patients have demonstrated both symptoms and risk factors and not had the disease.

DIAGNOSIS

A detailed history and physical examination are often sufficient to establish diagnosis of lower extremity ischemia.[7]

Intermittent claudication is ischemic muscle pain caused by inadequate blood flow resulting from lower extremity arterial occlusion (superficial femoral and proximal popliteal arteries). The condition is typically described as a "cramping" pain in the calf muscles that occurs during exertion (ie walking) and is relieved upon cessation of activity.

Rest pain is more severe than claudication and indicates far-advanced arterial insufficiency. It is a severe burning pain usually confined to the forefoot and is aggravated by elevation of the extremity. The patient with continuous rest pain hangs the leg over the side of the bed to obtain relief or sleeps sitting in a chair.[6]

Often, symptoms of peripheral arterial disease will not be demonstrated until 60 percent of the artery has narrowed. Progression of the disease is determined by the individual's

history and specific area of circulation. When central arteries become constricted, smaller peripheral arteries permit some blood to flow around the restricted areas. This development, called collateral circulation, may cause the apparent lack of symptoms in some individuals.

PHYSICAL EXAMINATION

Palpation of peripheral pulses is an important feature of the examination. In the lower extremity, the femoral, popliteal, posterior tibial, and dorsalis pedis pulses should be noted.[7] Blood pressure and presence of bruit—the sound of blood passing through a stenotic arterial segment—should be checked.

With chronic ischemia, the lower extremities are inspected for hair loss, shiny skin, thickened toenails; and color changes consisting of a purplish rubor (redness) in dependency, which changes to pallor when the extremity is elevated. Also characteristic are ulcers, gangrene, atrophy, and cold temperature.

DIAGNOSTIC TESTS

Procedures for assessing peripheral arterial disease are simple, noninvasive and fairly inexpensive. Vascular laboratories are equipped with dopplers, duplex scanning and other radiologic instrumentation.

Essentially an ultrasound stethoscope, the Doppler is used to assess blood flow (velocity) through the arteries of the lower extremity. The ankle-brachial index (ABI) is a measurement test that divides systolic blood pressure at the level of the ankle by the brachial arterial pressure. The technique correlates roughly with the degree of lower extremity ischemia. The ankle-brachial index is the most common test for peripheral arterial disease. ABI values and their associated meanings are shown in Table 1.

Arteriography supplements the physical findings by defining precisely (1) the site and degree of arterial obstruction, (2) the status of the proximal and distal arterial tree, and (3) the status of the collateral circulation.[6] Evaluation of the cardiac and respiratory system is also required due to the fact that most patients with peripheral vascular disease also have ischemic heart disease and/or chronic obstructive pulmonary disease due to prolonged tobacco use.

TREATMENTS

Methods for treating peripheral artery disease vary, and most physicians will consider many options based on the history and health of the patient. The majority of atherosclerosis cases can be treated without surgery. Nonsurgical plans will emphasize a change in lifestyle, including smoking cessation, dietary changes and exercise recommendations. Drugs, including clopidogrel and cilostazol, are now available to help with the condition.

When surgery is considered an option, an arteriogram is performed to help the surgeon locate the blockage in the arteries. Contrast is injected into an artery using a needle or small catheter, and X-ray images of the arteries and blockage locations are generated.

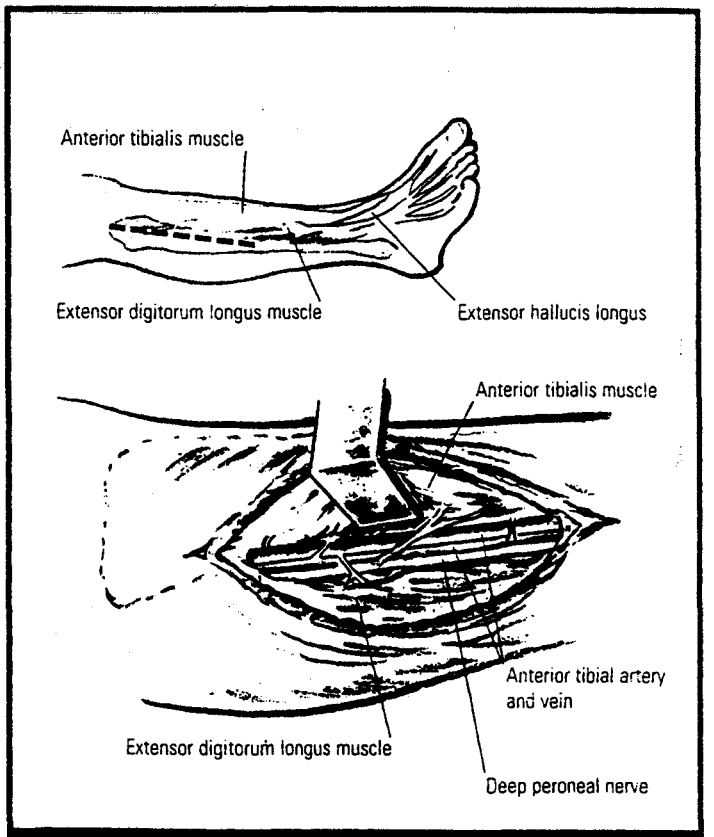

FIGURE 4—EXPOSURE, ANTERIOR TIBIAL ARTERY

The goal of vascular surgery is to remove the obstructing plaque or to bypass the blocked areas with a graft. Such procedures can include endarterectomy or thrombectomy/embolectomy. The bypass is discussed below.

BYPASS GRAFTING

A femoropopliteal bypass graft is performed to provide pulsatile blood flow to the popliteal artery.[6] The patient's own saphenous vein (autogenous tissue) can be used for above-the-knee, femoropopliteal bypass, and is generally consid-

ered the graft of choice for bypass below the popliteal artery.

Several techniques are available, and the choice depends on whether the graft extends beyond the joint. Four of the more common methods are insitu, reverse saphenous, endoscopic saphenous and expanded polytetrafluoroethylene vascular grafts.

In the insitu technique, the proximal and distal ends of the saphenous vein are mobilized, leaving the majority of the vein undisturbed in its native supporting tissue. Venous tributaries are ligated with fine silk sutures, and the valves are made incompetent with a valvutome. The proximal end of the vein is sewn to the common femoral artery, and the distal end of the vein is sewn to the distal anastomotic site.

Reverse saphenous (free graft) technique: The saphenous vein is harvested and tributaries are ligated with small hemoclips or fine vascular sutures. The vein is cannulated with a "flushing" needle attached to a 20 cc syringe filled with heparinized saline, which is used to distend the vein graft and check for leaks. Any leaks are repaired with 6-0 or 7-0 vascular suture. The ends of the vein are reversed anatomically (due to the valves, which only allow blood flow in one direction) and sewn to their respective arterial anastomotic sites.

With the development of minimally invasive endoscopic surgical techniques, a new endoscopic procedure has been developed for saphenous vein harvesting. (Please see "Endoscopic Saphenous Vein Harvesting" in *The Surgical Technologist*, July 1999.)

Expanded polytetrafluoroethylene (ePTFE) vascular grafts can also be used for peripheral bypass procedures. Operative death rates are low (2 percent), and five-year patency rates range from 60 percent to 80 percent.[1,3]



FIGURE 5—PARACHUTE TECHNIQUE-START



FIGURE 6—PARACHUTE TECHNIQUE-FINISH

OPERATIVE TECHNIQUE

Definition

The positioning and anastomosis of a graft (saphenous vein or ePTFE) is usually from the common femoral artery in the groin to the proximal or distal popliteal artery to relieve lower limb vascular insufficiency. The location of the occlusion in reference to the knee will determine whether an above-knee

TABLE 1

ABI VALUES

1.3 or greater	Arteries calcified (diabetes); results not applicable
1.3 to .9	Normal
0.9 to 0.5	Modest PAD may interfere with walking
0.5 or less	Substantial PAD; possible rest pain or ulcers

femoral popliteal bypass or below-the-knee distal bypass is indicated.

Objective

The goal of the procedure is to restore unobstructed blood flow distally all the way to the foot, with subsequent relief of claudication (pain) and prevention of limb loss.

Preparation

The patient undergoes a preoperative arteriogram to confirm adequate inflow at the femoral level, to locate the lesion, and to select the sites for proximal and distal anastomosis. The bypass procedure can be performed under general or regional (continuous epidural) anesthesia. The patient is positioned on the operating room table in the supine position with the arms extended on arm boards. The entire lower extremity, including the groin area, is prepped and draped into the field. (This can include both legs if the surgeon decides to harvest the contra-lateral saphenous vein.) The operative leg is externally rotated and flexed at the knee. A small padded basin or a stack of towels is used to bolster the knee.

Procedure

A standard vertical incision is made two fingerbreadths (FB) lateral to the pubic tubercle in the groin area. The electrocautery pencil and dissecting scissors are used to carry the incision through the subcutaneous tissue layers down to the adventitia. A self-retaining retractor is placed in the wound to aid exposure. The common femoral artery is carefully dissected. A right-angle clamp is used to pass and encircle the artery with an elastic vessel loop or moistened umbilical tape. This maneuver helps control the vessel and facilitates further dissection. In a similar fashion, the superficial femoral artery and profunda femoris are mobilized and encircled with elastic vessel loops or moistened umbilical tapes.

A moistened Raytex or lap sponge is placed in the wound to keep the tissues from drying out. Then the proximal popliteal artery is exposed through a longitudinal incision along the medial aspect of the lower thigh (above-the-knee) with retraction of the sartorius muscle posteriorly.[8] (Figure 2)

The proximal popliteal space is entered and the artery is exposed using blunt and sharp dissection. A self-retaining retractor with medium to long blades can be used to expose the vessel structures of the popliteal space. Care is taken to avoid injury to the accompanying nerve and vein.

If the popliteal artery is diseased, the distal popliteal space i entered through an incision that begins just distal to the joint line and parallels the posterior border of the tibia.[8] (Figure 3)

Extending the incision distally exposes the tibial-peroneal trunk for placement of a graft to this region. If necessary, a longitudinal incision can be made over the anterior compartment (lateral aspect of the lower leg) and the anterior tibialis and extensor digitorum longus muscle bellies are separated to expose the anterior tibial vessel for distal graft anastomosis.[8] (Figure 4).

The muscle is retracted inferiorly and may be divided to gain additional exposure. The popliteal artery is mobilized. A right-angle clamp is used to pass and encircle the artery with an elastic vessel loop or moistened umbilical tape. A tunneler is passed in the plane of the artery from the popliteal space to the groin. The graft is pulled through the tunnel and positioned to prevent kinks or twists.

The patient is administered heparin sodium intravenously to prevent thrombosis during the cross-clamping phase of the procedure. Wait 5 minutes. Angled vascular clamps are applied to the common femoral, superficial femoral and profunda femoris arteries to occlude them. Some surgeons prefer to double-loop or "Potts" the elastic vessel loops placed around the arteries to occlude them, thereby eliminating the need to apply vascular clamps.

An arteriotomy is initiated in the femoral artery using a #11 scalpel blade and extended using angled Potts-Smith scissors. The proximal end of the graft is positioned and anastomosed to the artery using two continuous running stitches of 6-0 double-armed vascular suture.

An arteriotomy is initiated in the popliteal artery using a #11 scalpel blade and extended using angled Potts-Smith scissors. The distal end of the graft is positioned and anastomosed to the popliteal artery using two continuous-running stitches of 6-0 double-armed vascular suture.

If the popliteal space is tight or vessel exposure is limited, the surgeon can elect to "parachute" several throws of suture and then sequentially pull each loop tight, bringing the graft and vessel together with just the right amount of tension. This technique also helps ensure accurate suture placement. (Figures 5 and 6)

A blunt nerve hook should be available to help control and adjust the loops of suture. Prior to tying the suture, the vascular clamps are briefly released in a sequential fashion to back bleed and flush the vessels of possible clots, air, and debris. Intraoperative X-ray studies (arteriography) can be performed to determine if the bypass procedure has successfully restored distal circulation. A suitable hemostatic matrix, soaked in thrombin and radiopaque sponges, should be available to control oozing through suture line holes.

With hemostasis achieved, the wounds are irrigated with warm saline and closed in layers using 3-0 absorbable suture. The skin is closed with subcuticular stitches or staples and covered with a sterile dressing. A staple removal device should be available to remove the staple that secure the towel over the genital area.

SUMMARY

Atherosclerosis is the major degenerative disease of human arteries and plays a significant role in vessel obstruction. Peripheral arterial insufficiency is predominately a disease of the lower extremities. The obstructive lesions (atheromas) alter normal blood flow to the lower extremities resulting in symptoms that range from intermittent claudication to gangrene. A femoropopliteal bypass graft is placed to restore unobstructed blood flow all the way to the foot, with subsequent relief of claudication and prevention of limb loss. The location of the focal lesion in reference to the knee will determine whether an above-knee femoropopliteal bypass or below-the-knee bypass is indicated. Autogenous saphenous vein or ePTFE can be used for an above-knee bypass. However, the saphenous vein is generally considered the graft of choice for a below-knee bypass. Operative death rates are low (2%), and five-year patency rates range from 60 percent to 80 percent.

Peripheral arterial disease carries serious consequences because of its relationship to other terminal conditions, including heart disease, stroke and diabetes. Some research indicates that heart disease is found in 28 percent of the patients diagnosed with peripheral arterial disease, and their life expectancy is consequently reduced.[1] Blocked arteries increase the chance of stroke, and diabetics are susceptible to peripheral arterial disease because of the way glucose accumulates in the arteries. Statistically, 80 percent of diabetics die from heart or blood vessel disease.[1]

The opinions or assertions contained in this article are those of the author and are not construed as official or reflecting the view of the United States Air Force.

ABOUT THE AUTHOR

Eric Zelinskas, CST, currently manages a minor surgery/endoscopy suite and central sterile supply and supervises four surgical technologists for the United States Air Force in Dover, Delaware. He has a special experience identifier (SEI) in vascular surgery. He received a bachelor's degree in business administration from Columbia College and associate degrees in surgical services technology and educational technology from the Community College of the Air Force.

REFERENCES

1. Vascular Disease Foundation Web site, www.vdf.org. Accessed 10/9/99
2. Dorland's Pocket Medical Dictionary, 24th ed. Anderson DM ed. Philadelphia, PA: WB Saunders;1989
3. Fields WS. Clinical Symposia "Aortocranial Occlusive Vascular Disease" Vol 26, No 4, 1974; Summit, NJ: CIBA Pharmaceutical Company; 6.
4. Physics of Blood Flow and Pressure: Hemodynamics. In: Guyton, Author, C. *Human Physiology and Mechanisms of Disease*. 3rd ed. Philadelphia, PA: WB Saunders Co; 140, 142.
5. Gavaghan, Mary: Vascular Hemodynamics. AORN . 1998; 68(2): 221,222.
6. Krupski WC, Effeney DJ, Way LW. *Current Surgical Diagnosis and Treatment*. 19th ed. Norwalk, Conn: Appleton & Lange; 1991: 740, 741, 743, 745.
7. Peripheral Arterial Disease In: Schwartz, SI. *Principles of Surgery*. 4th ed. New York, NY: McGraw Hill Companies; 1984: 898.
8. Disorders of the Arterial System In: Sabiston DC Jr. (ed). *Textbook of Surgery*. 13th ed. Philadelphia, PA: WB Saunders Co; 1986: 1865-1867.