Laser Removal of Warts in the Throat

ARTICLE BY FRED CARLILE, CST

Although lasers have been used in head and neck surgery for more than 30 years, their use has not been a prominent form of treatment until the 1990s. With new instruments and improved techniques, lasers are now used more than ever before. Above all other types of lasers, the CO_2 laser has proven to be the most effective for use in the larynx. Laser treatments are not only used for warts in the throat, or laryngeal papillomas, but are very widespread in many other areas of head and neck surgery as well. They have proven themselves in the operating rooms of the 1990s and are sure to be around for many years to come.

Historical Perspective

As early as the 17th century, physicians were using the term, "warts in the throat," to describe benign tumors most often found in the larynx of children.[1] Since that time, many different treatments have been tried, several of which are still used today. Of these treatments, the CO_2 laser seems to be one of the best ways to control the spread of these warts, or papillomas, as they are known today.

Juvenile laryngeal papillomatosis was the term used for many years, and as recently as the 1960s, to describe benign tumors most often found in patients 15 years of age and under. These tumors are caused by the human papilloma virus (HPV). Two thirds of all patients affected are under the age of five. However, patients should be treated regardless of age, since no relationship has been shown between puberty and a regression of the disease. Although these papillomas are most common in the larynx, they may also be found in the nasal mucosa and in the lung parenchyma and have been reported in the esophagus; however, they seldom invade submucosal tissue. The papillomas usually occur in multiple clusters spread over a wide area and may be localized as well.[1]

Over time, many different treatments have been used for laryngeal papillomas. Some of the more common treatments have included injections of hormones and steroids, the use of ultrasound and radiotherapy, a vaccine made from the papillomas themselves, and tracheotomy. Radiotherapy is contraindicated since it may encourage malignancy, and tracheotomy should be avoided, as papillomas may grow at the tracheostoma. Some treatments still used today are removal by microsurgery, cryosurgery, electrosurgery, ultrasound, direct removal by laryngofissure, and naked-eye endoscopic removal.[1] Though these treatments are still in use today, removal of the papillomas by laser causes less trauma to the larynx and airway.

Anatomy of the Larynx

An examination of the anatomy of the larynx, sometimes called the voice box, shows it to be composed mostly of cartilage connected by ligaments. Its movement is controlled by numerous muscles. The larynx is located between the base or root of the tongue and the top of the trachea, with the thyroid gland located on either side. The lining consists of a mucous membrane continuous with that of the trachea and pharynx. In adult males, the larynx is considerably larger than that of the female and may be seen moving when talking or swallowing; it is sometimes referred to as the "Adam's apple." The larynx of an adult male is approximately 45 mm in length compared with the larynx of a female, which is approximately 35 mm. In children, the size varies very little between the male and female until puberty.

The upper portion or vestibule of the larynx is triangular and slopes downward and backward. The epiglottis, ventricular fold (*false vocal cords*), and vocal fold (*true vocal cords*) are just part of its contents (Figure 1). The upper and lower portions are divided by the vocal folds. The lower portion is at first an elliptical form that widens and assumes a circular form at the bottom. This circular form connects with and is continuous with the trachea (Figure 2).[2]

Lasers in Treatment

The use of the laser in otolaryngology had its beginning in the 1960s with the use of argon laser therapy. Since then, the Nd:YAG, copper vapor, gold vapor, and other types have been tried, but the CO_2 laser has achieved the best results. Today it is the most common type of laser used for various otolaryngologic applications. After the laser's introduction, its use rapidly increased until it plateaued in the mid 1980s. By the late 1980s there was a sharp decrease in laser use, but since 1990 lasers have once again become popular. This is largely due to the many advances in the field of laser technology. For example, the first CO_2 laser

for the operating room was approximately the size of a telephone booth. While this laser did have an articulating arm, there was no way to direct the laser energy precisely through a laryngoscope. Advances in modern-day lasers include the development of the micromanipulator that attaches the articulating arm to the operating microscope, a drastic reduction in the size of lasers, and the availability of hand-held fibers and instruments. The existence of organizations that publish user guidelines and safety standards for laser use have also helped to increase the popularity of lasers.

Preoperative Considerations
Several things must be considered before beginning a laser laryngoscopy. Not only must the surgeon be familiar with the use of the laser and the procedure itself, but the anesthetist must be aware of the adverse effects that may appear unexpectedly and be prepared to deal with them if necessary.

Intraoperative Concerns and Safety Precautions
Many of the intraoperative concerns present with a traditional laryngoscopic procedure still exist in laryngoscopy with lasers. In addition to these concerns, the safe use of the laser is essential. Nitrous oxide should not be used for several reasons.[3] First, it causes decreased cardiac output in patients with heart damage.[1] Second, and most important in laser use, nitrous oxide is as combustible as oxygen.

Another concern is the possibility of cardiac arrhythmias during laryngoscopy. These may occur from the pressure of the laryngoscope blade on the supraglottis thus stimulating deep laryngeal receptors. Arrhythmias must not be ignored, since they increase both intraoperative and postoperative myocardial infarction risks. Cardiac arrhythmias usually clear once the laryngoscope is removed. If the arrhythmias reappear upon reinsertion of the laryngoscope, the procedure should be terminated and rescheduled. When it is necessary to return a second time, 50 to 100 mg of lidocaine should be given intravenously after induction, or the superior laryngeal nerve should be blocked prior to the start of general anesthesia.

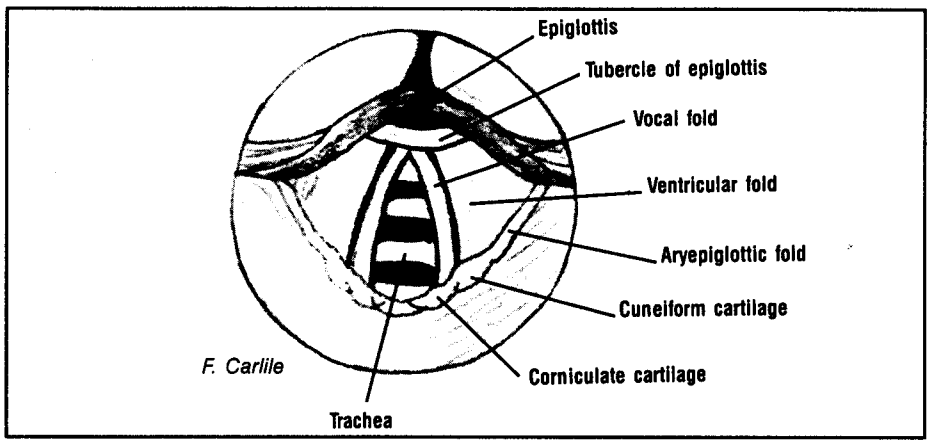

Figure 1. Laryngoscopic view of larynx.

Laryngeal spasms are quite common upon removal of the laryngoscope and with the reversal of any muscle relaxant that has been used. The use of lidocaine on the vocal cords helps to prevent laryngospasms. Postoperative edema may also compromise the airway. Intravenous steroids may reduce edema but should be used only if excessive mucosa trauma has occurred.[1]

The most dangerous risk is the possibility of an endotracheal tube fire or explosion. To reduce this risk, a laser-safe tube must be used.[1,4] There are currently many different tubes available that are approved for laser use. Some of these are manufactured with methylene blue in the cuff, while others are not. The cuff of a laser tube should be filled with normal saline, as opposed to air as are other tubes. If the tube does not have methylene blue in the cuff, the anesthesia personnel should plan to fill it with normal saline containing a dye. The dye will alert the surgeon

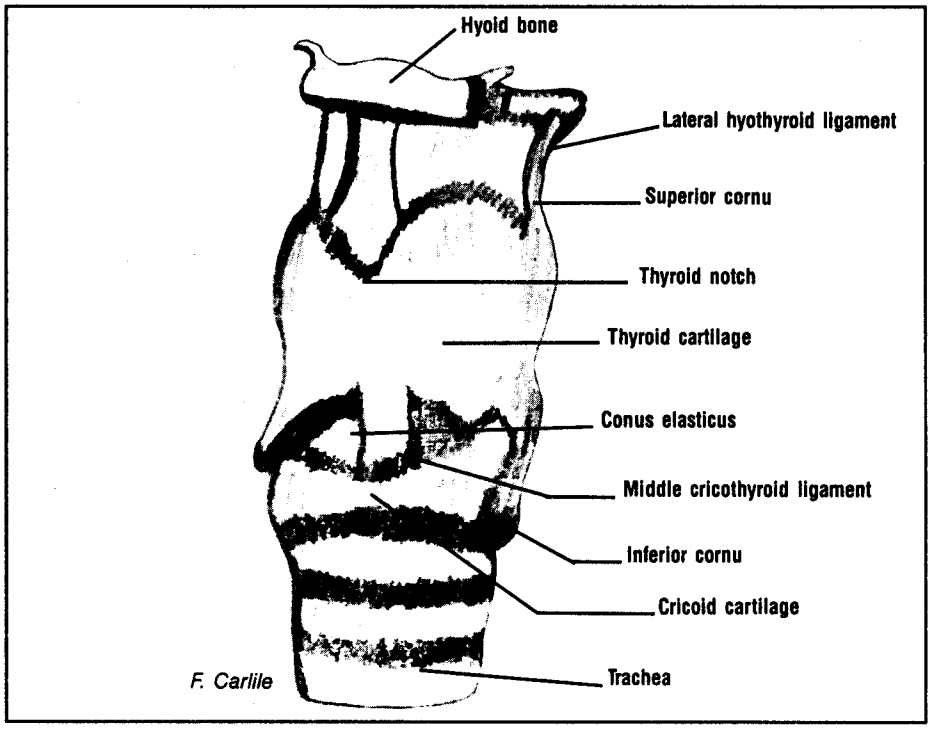

Figure 2. Ligaments of the larynx.

to a leak in the cuff should it be hit by the laser beam while the saline will absorb the laser energy and heat to help prevent injury. Anesthesia personnel may choose to use a jet technique or an apneic technique, which do not require a tube for patients who have a compromised airway; however, these techniques are not preferred in laser cases. Regardless of the technique chosen, combustible anesthetic gases must not be used for laser procedures. Again the use of nitrous oxide is discouraged since a mixture of nitrous oxide and oxygen can be ignited by CO_2 laser as readily as 100% oxygen. The preferred inhalation agents are halothane and forane.[1] When possible, a 24% solution O_2 mixture is preferred for delivery of these agents. This mixture can be achieved by using both O_2 and compressed air.

Laser safety is not only of concern to anesthesia personnel and the surgeon but is the responsibility of the entire operating room team as well. Each team member should be familiar with the laser equipment as well as knowledgeable of laser precautions. This is usually accomplished by attending a laser seminar or laser training course. The surgical technologist should visually check all ebonized finishes on instruments as well as the operation prior to the start of the procedure. Operating room staff must take all available precautions to prevent an accident or injury.

The first precaution that must be taken by operating room personnel is to place a "laser in use" sign on the outside of all doors leading into the operating room suite.[3] This sign should be clearly visible and should also state what type of laser is in use. The laser itself must be test fired before the patient enters the room, but only after each person in the room has donned protective eyewear and a mask designed specifically for laser use.[3] To prevent burns to the patient and to the operating room personnel by reflected beams, all instruments selected must have either a nonglare or ebonized finish.[3] The laryngoscope (a large-bore one is best) must also have a port for connection to the smoke evacuator and be approved for laser use. Only after all of the equipment is checked and found to be working properly is the patient taken into the operating room suite to begin the laser treatment.

Patient Preparation

Once in the operating room, the patient is placed on the operating table in the supine position and prepared for the surgical procedure. Following induction and establishment of the airway by the anesthetist, the patient is paralyzed to ensure complete immobility of the vocal cords. Paralysis is not always necessary in a standard laryngoscopy, but in a laser treatment, severe damage may be done to the cords if they move unexpectedly. The surgeon may place a mouth guard or tooth protector on the patient. This helps prevent damage to the patient's teeth and gums that may otherwise be caused by the laryngoscope. The surgeon inserts a laser-safe laryngoscope and secures it in place with a suspension device. Moist cottonoid pledgets are placed around the cuff of the endotracheal tube for added protection from the laser beam. This is done using the microlaryngeal grasping forceps.

Once everything is in place, the laser arm is attached to the micromanipulator, which was previously placed on the microscope along with a 400-mm objective. At this time, wet eye pads are taped to the eyes and wet towels or drapes are used to cover the face and all exposed metal surfaces of the laryngoscope and suspension device to prevent burns to the patient.[3] The laser is now ready to be turned on. The surgeon tells the laser operator the power settings he or she wishes to use and the laser operator keys the settings into the laser control panel. These settings are obtained based on certain laser principles involving the relationship of the watts of energy used and the area over which the energy is delivered. The pulse mode is usually preferred over the continuous mode to prevent heat damage within the larynx. A typical setting might be a spot size of 0.8 mm with 4 to 6 watts of power at 0.1 second.[1] With the settings entered, the laser is once again test fired on a wet tongue blade to ensure that the aiming beam and the laser beam are aligned and that the laser is working properly. It is important to note that, even at this point, if the laser misfires or gives the operator an error code, it must

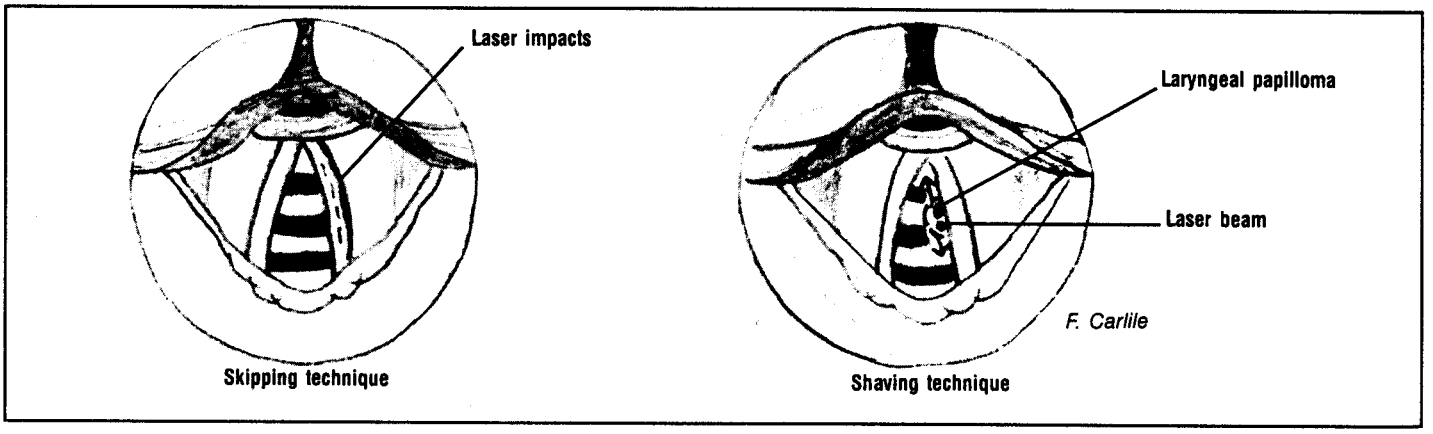

Figure 3. Techniques used in CO_2 laser laryngoscopy.

not be used in order to provide the patient with the safest possible treatment. As soon as all safety measures have been met, the surgeon proceeds with the laser treatment.

Operative Procedure

There are two methods that may be used in the larynx. The first is a skipping technique used to incise the squamous epithelium of the vocal cord. This technique produces a serrated cut and therefore lessens the chance of an uneven cutting depth by the laser beam. The second technique used in the larynx is shaving. Shaving is done with an operating platform, placed behind the lesion to protect the underlying tissue. By allowing half of the beam to impact the lesion and half of the beam to hit the platform, the lesion is shaved or vaporized a small amount with each firing of the laser beam (Figure 3).[1] Both techniques may require the use of some or all of the following: metal laser mirrors, forceps, operating platforms, suction tips, probes, and other instruments approved for laser use (Figure 4). Laser safety must remain in the forefront of everyone's mind throughout the procedure. With the proper use of all laser-associated equipment, the results will be both safe and effective.

Upon completion of the laryngoscopy, the wet towels or drapes are removed, and the articulating arm is removed from the microscope. Before removal of the laryngoscope, cottonoid pledgets are removed and counted as a sponge count.

Postoperative Care

After removal of the laryngoscope, the patient is awakened according to standard procedure and taken to the postanesthesia care unit. As in other procedures, the patient remains in postanesthesia care until he or she is stable and able to return to the floor. Most laryngoscopic procedures are done as a same-day surgery outpatient basis. However, patients must be observed for bleeding or edema, which could block the airway. This is the most common postoperative concern in any surgical procedure involving the airway.

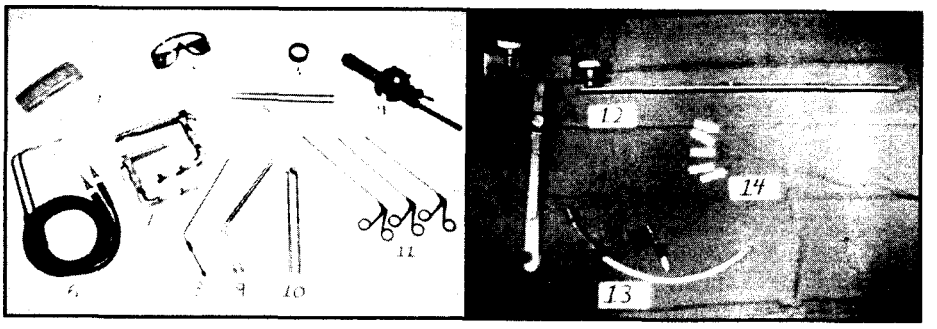

Figure 4. Items needed to perform laser laryngoscopy. **1,** Laser mask; **2,** Protective eyewear; **3,** 400-mm objective; **4,** Micromanipulator; **5,** Straight and 90° angled probe; **6,** Fiber optic light cables; **7,** Non-glare laryngoscope (pediatric and adult); **8,** Suction tip; **9,** Operating platform (4 & 6 mm); **10,** Metal mirrors; **11,** Straight, left, and right grasping forceps; **12,** Suspension device; **13,** Endotracheal tube; **14,** Cottonoid pledgets.

Promising Results

The knowledge and safe use of the CO_2 laser have given many patients better results than any other procedure currently used. Although a prolonged remission (many years for some patients) has been reported, the disease may not be permanently eradicated. A reported 65% control rate for pediatric-onset patients and a 45% control rate for adult-onset patients may be achieved. However, the pediatric patient may require treatments much more frequently, possibly as often as every 3 to 6 months.[1] The treatment rate varies greatly from patient to patient.

Not only may papillomas be treated with better results, but accessory instruments for the laser have made it possible to treat lesions previously considered inoperable and still achieve a good result. These benefits, along with improved intraoperative bleeding control, less postoperative pain and edema, less chance of scarring and web formation postoperatively, and a greatly reduced chance of seeding, all work together to make the CO_2 laser beneficial as a means of treatment.[1]

Otolaryngologists have reported positive results in the laser treatment of many other laryngeal diseases as well. These include capillary hemangiomas, the reduction of scar tissue, webs, other lesions involving the vocal cords and epiglottis, and the debulking of large malignant lesions to improve the patient's airway.[4] Combining these with the hundreds of other possible uses in head and neck surgery, the CO_2 laser, along with other laser types, is sure to remain one of the most promising treatments available to the otolaryngologists of today and tomorrow. Δ

Acknowledgements

The author would like to thank T. Lawrence, MD; C. Jordan, MD; B. Rayne, MD; HK Bralley, CRNA; and J. Wall for their assistance with this manuscript.

References

1. Dixon JA, Hunter JG, Parsons DS, Duncavage JA, Ossof RH, Benjamin B. *Lasers in Otolaryngology - Head and Neck Surgery.* 1st ed. Philadelphia, Pa: WB Saunders Co. 1990; 1-43.
2. Goss CM. *Gray's Anatomy 100th Year.* 26th ed. Philadelphia, Pa: Lea & Febiger. 1963; 1176-1187.
3. Atkinson LJ. *Berry & Kohn's Operating Room Technique.* 7th ed. St Louis, Mo: Mosby-Year Book. 1992; 176-178.
4. Lore' JM. *An Atlas of Head and Neck Surgery.* 3rd ed. Philadelphia, Pa: WB Saunders Co. 1988; 874-875.

Fred Carlile, CST, *is employed at Cookeville General Hospital in Cookeville, Tennessee. He worked at CGH for 5 years before leaving to work for a private otolaryngologic practice for 2½ years. He returned to work at CGH 3 years ago. His article won second place in this year's Writer's Award.*