Rhinoplasty

ARTICLE BY PHILIP WILKES, CST/CFA

Rhinoplasty is plastic surgery of the nose for reconstructive, restorative, or cosmetic purposes. The procedure of rhinoplasty had its beginnings in India around 800 B.C., as an ancient art performed by Koomas Potters.[1] Crimes were often punished by the amputation of the offender's nose, creating a market for prosthetic substitutes. The skill of the Koomas enabled them to supply this need. In modern times, rhinoplasty has developed into a high-technology procedure that combines art with the latest scientific advancements.[1]

During rhinoplastic procedures, surgeons can change the shape and size of the nose to improve physical appearance or breathing. From the central position it occupies in the face, the nose has important aesthetic implications. Regardless of how pleasing or acceptable the other features may be, if the size and shape of the nose are not in harmony with the rest of the face, it has a dominating effect. Individuals who have suffered trauma or who have congenital deformities that affect the valve functions of the nose have benefitted from rhinoplasty. A change in the direction of air flow through the nasal passages due to trauma may cause metaplasia resulting in symptoms such as difficult breathing, sinus pain, headache, foul odors, stuffiness, dry throat, infection, and recurrent epistaxis.[2] The most common types of nasal obstructions are the irregular septum, hypertrophied turbinates, and nasal polyps. Many obstructions are also caused by foreign objects that become lodged in children's noses.[3] Fortunately, the art and science of rhinoplasty in the hands of a skilled surgical team offers positive alternatives.

Three general types of rhinoplasty will be discussed in this article. They include partial, complete, and finesse rhinoplasties.

Anatomy and Physiology of the Nose

The nose is the olfactory organ that projects from the center of the face and warms, filters, and moistens air on the way to the respiratory tract. Someone breathing only through the mouth delivers a bolus of air with each breath. The components of the nose allow a thin flow of air to reach the lungs, which is a more efficient distribution of air to the lungs.[4] The nose consists of external and internal components (Figures 1, 2, and 3). The external nose is that portion of the nose that projects from the face and includes the nasal bones, nasal cartilages, and connective tissue covered with skin, nostrils and tip, major alar cartilages, columella, septum, and ethmoid (Figures 2, 3, 4, and 5). The internal nose, also known as the nasal cavity, is divided by the septum (see Figure 5). It communicates with the nostrils and continues on to the nasopharynx. The inferior border of the nose is the hard palate. The superior border is the ethmoid (see Figure 1). The turbinates lie between these borders (see Figure 2).

The nasal bones are two small bones that create the bridge of the nose (see Figures 3, 4, and 5). These bones articulate superiorly with the glabella, laterally with the maxilla, inferiorly with the upper lateral cartilages, and posteriorly with the ethmoid bone.[5]

The nasal septum is formed by the ethmoid (perpendicular plate) and vomer bones (see Figure 5). The cartilaginous part is formed by septal and vomeronasal cartilages. The anterior portion consists of the medial crus of the greater alar cartilages, called the columella nasi.[3]

The vestibule is the cave-like area inside the nostrils that is lined with skin containing sebaceous glands and stiff hair known as vibrissae (see Figure 1).[3]

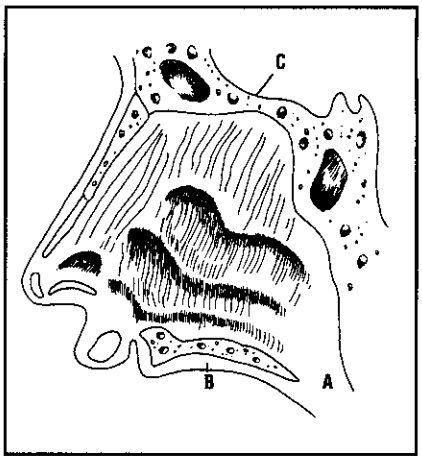

Figure 1. Nasal cavity. **A**, Nasopharnyx; **B**, Hard palate; and **C**, Ethmoid.

The nose contains an internal and external valve. The internal valve is the caudal reflection of the upper lateral cartilages and the external valve is the lower third of the nose to the nostrils' flare.[2] External valve airway impairment creates a condition

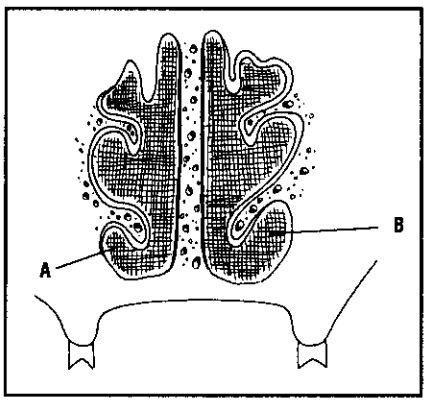

Figure 2. Vertical section through the nose. **A**, Inferior meatus; and **B**, Inferior turbinate.

known as flutter valve where a weak or poorly supported nostril closes or flutters on inspiration, instead of flaring the nostrils from the external valves. The internal valve is created by the nasal floor, the septum, and the caudal reflection of the upper lateral cartilage. It acts paradoxically by widening on expiration and narrowing on inspiration.[2]

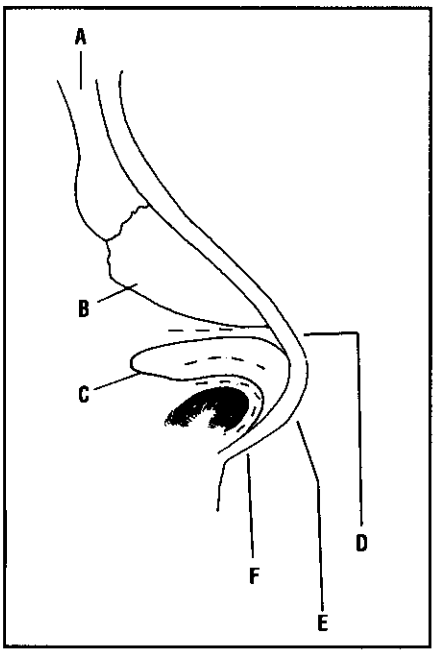

Figure 3. Side view of the nasal bones, upper lateral and alar crus. **A**, Nasal bones; **B**, Upper lateral cartilage; **C**, Major alar cartilage; **D**, Intercartilaginous incision; **E**, Intracartilaginous incision; and **F**, Infracartiginous incision.

The nasal cavity is lined with mucous membrane overlying periosteum and perichondrium that continues from nasopharynx through the choanae to the skin at the vestibule.[5]

The nasal fossae are the two halves of the nasal cavity, connecting the external nares with the nasopharynx by way of the funnel-like choanae.[5]

The ala nasi are the wings of the nose that form the lateral walls of the nostrils. Alaplasty is performed to reduce nostril size in this instance (Figures 6 and 7).[5]

The turbinate bones consist of the superior middle and inferior conchae. Grooves called nasal meatuses separate the turbinate bones and drain the accessory sinuses (see Figure 2). Communicating arteries are located beneath the epithelial layer of turbinated bone.[4] Dilation of the superficial veins causes the turbinates to swell, becoming hypertrophic and creating an airway obstruction. Airway obstruction is relieved when the surgeon performs an inferior turbinectomy using Takahashi or Gruenwald forceps.[6]

The dorsum extends from the radix, which is the root of the nose, to the distal projections of the lateral crus and the dome. The dome is the most prominent part of the alar cartilage.[2] The area of crucial refinement in cosmetic surgery is the tip, defined as the left and right lateral projections of the dome and the point from which the dorsum ends to the columellar-lobular junctions.[2]

Blood is supplied to the nose by branches of the internal maxillary artery. The maxillary branch of the trigeminal nerve provides innervation to the nose.[5]

Preoperative Considerations and Patient Selection

The patient has an initial consultation with the surgeon to assess the patient's suitability for aesthetic rhinoplasty. Among the factors the surgeon will use to determine whether an individual is a good candidate for rhinoplasty are the patient's age, general health, and emotional well-being.[7] Because the nose has not yet completed growing in children and adolescents, aesthetic surgery is not recommended until individuals have reached their middle teen years. The patient's general health must also be reviewed in older adults considering this procedure. Finally, the patient's mental stability and expectations must be closely examined and discussed prior to undergoing surgery to ensure that the patient does not have unrealistic expectations of the end results; the attainment of physical perfection and life happiness should not be among the patient's goals for plastic surgery.[7] In some cases, nose shapes represent specific ethnic heritages. At times, the patient's aims may clash with surgical realities. When a

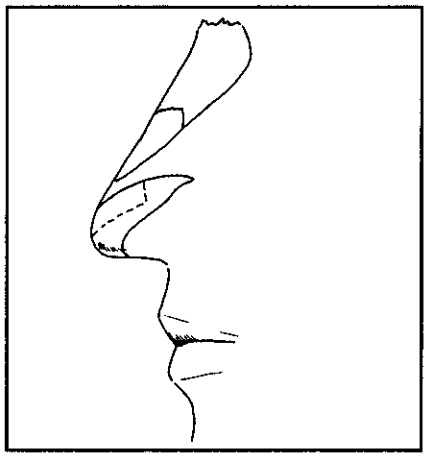

Figure 4. Retruded columellar-labial angle.

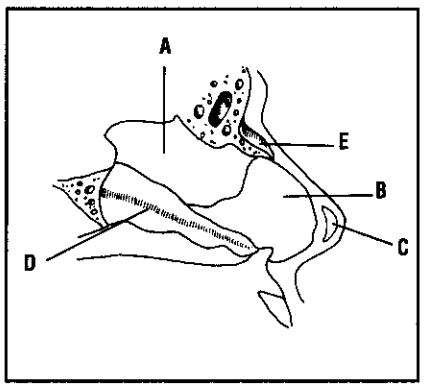

Figure 5. Side view nasal septum. **A**, Ethmoid (perpendicular plate); **B**, Septal cartilage; **C**, Alar cartilage; **D**, Vomer; **E**, Nasal bone.

patient seeks a nose shape that is an unrealistic conversion, the surgeon will suggest a surgical plan during consultation that will minimize any undesirable attributes while maximizing balance and harmony.

Preoperative Medication and Anesthesia

Preoperative medication may range from transdermal scopolamine (Transderm Scop disc) the night before surgery to preoperative intravenous medication. Titration is more reliable than intramuscular injection. The patient may receive 10 mg of diazepam 1 hour preoperatively or lorazepam under the tongue a few minutes before surgery.[6]

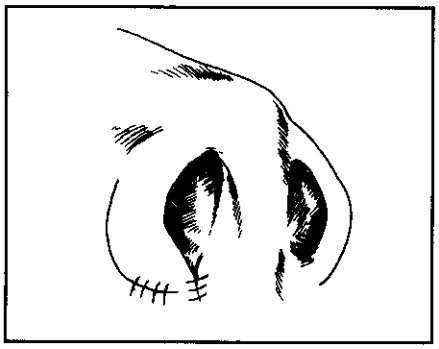

Figure 6. Alaplasty (after closure).

Local anesthesia with intravenous sedation and monitoring by the surgeon is an accepted standard of care (many surgeons prefer general anesthesia). A surgeon using intravenous sedation may prefer the patient be at his or her deepest level of sedation during the initial preparatory injection and packing of the nose, and during fracture and osteotomy. Intravenous sedatives of choice are typically a combination of thiopental sodium, fentanyl citrate, diazepam, and midazolam. A 0.2 saturation is maintained by oral catheter.[6]

The surgeon may opt for general anesthesia when performing more substantial cases, which require the services of an anesthesiologist or anesthetist. The anesthesiologist may choose to use isoflurane. Enflurane is preferred by some surgeons since it reduces cardiac irritability by lowering blood pressure allowing a greater use of epinephrine.[8]

Preoperative Local Infiltration

Most commonly, a sterile medicine cup, 10-ml syringe, 27-gauge 11/4-inch needle, 1% lidocaine with epinephrine 1:100,000, 3 x 3 inch gauze strip, and small speculum are required.[4]

Injection begins at radix into soft tissue, then the needle is placed in vestibule injecting over dorsum and along future osteotomy sites, including the caudal reflections of the lateral crus, and the membranous septum to the nasal spine. The alar lobules are infiltrated when alar wedge resections are planned and the final injection is near the infraorbital foramen. Any distortion of the tip and dorsum caused by injection will diminish after skeletization. Injection helps reduce bleeding during resection.[2]

Preoperative Packing

The supplies and instruments generally used include a sterile medicine cup, bayonet forceps, small nasal speculum, and 1/2-inch plain packing.[6]

Packing is dipped in a mixture of tetracaine hydrochloride or cocaine hydrochloride and epinephrine. The first pack is placed between the septum, inferior turbinate, and nasal floor. The second pack is placed on the mucosa over the lateral osteotomy site's dorsal area and the roof of the nasal cavity, then removed just before incision (Figures 8 and 9).[2]

Patient Preparation

The surgeon may prep the vestibule to the internal valve by shaving the vibrissae and swabbing the area with povidone iodine. Some surgeons consider the vestibule of the nose to be a "dirty" area, and believe that extensive preparation has no effect on the surgical outcome.[6] A normal external skin prep is required in all situations. Typically, the face and submental area below the chin is washed with hexachlorophene and sterile water and blotted dry with sterile gauze. A head-drape, towels, and split-sheet are used in rhinoplastic procedures.

Types of Incisions

Most surgeons who perform rhinoplasty use one of three transcartilaginous-vestibular incisions. An infracartilaginous incision is made along the caudal reflection of the alar cartilages, whereas an intracartilaginous incision is made through the alar cartilage (see Figure 3). An intercartilaginous incision is made between the alar cartilages and the upper lateral cartilages and entered through the vestibule of the nose (Figures 3 and 10). These are classified as closed incisions.[2]

Open rhinoplasty may involve a transcolumellar approach using a

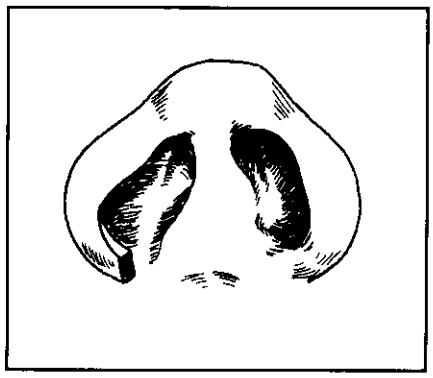

Figure 7. Alaplasty (alar wedge resection).

chevron-like incision or stepped incision (Figure 11). The surgeon undermines the skin using a cephalad and lateral skeletization, enabling the underlying anatomy of the nose (including the alar cartilages, upper laterals, and nasal bones) to be undraped and fully exposed.[2]

Surgeons disagree on whether the use of closed or open rhinoplasty is preferable. Jack H. Sheen, MD, states, "Never make an external incision when an internal one will do." A transcolumellar incision scar is unacceptable, according to Sheen.[2] However, rhinoplasty specialist Lawrence Birnbaum, MD, believes that, "The optimum exposure offered by the open approach reduces the likelihood of touch-up revisions and the scarring is minimal."[9] For the purposes of this article, the open approach will be assumed.

Septoplasty and Submucous Resection

Septoplasty is the surgical

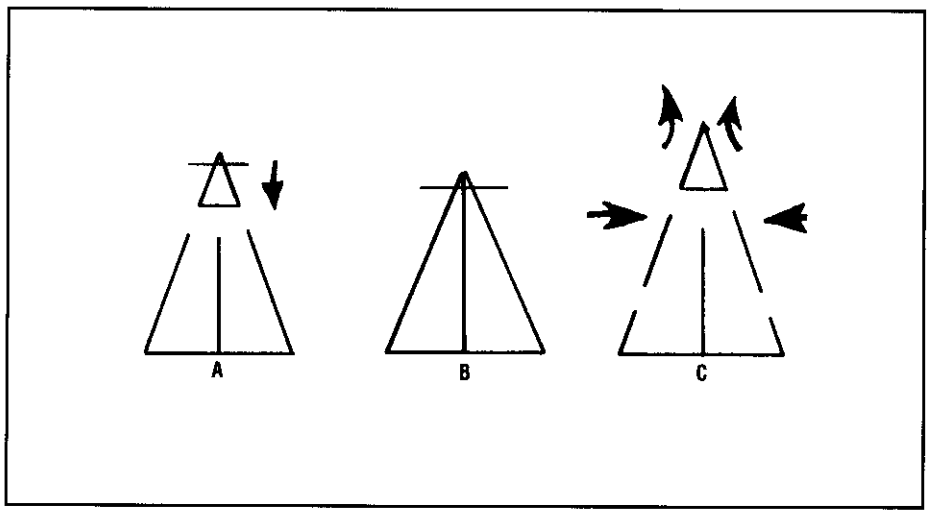

Figure 8. Nasal vault. **A**, Roof off nasal vault (trim and replace); **B**, Nasal vault, hump rasped or shaved (roof intact); **C**, Nasal vault, roof removed lateral osteotomies performed, and roof reformed.

reconstruction of the nasal septum. Submucous resection involves the excision of part of the deviated septum. A flap of mucous membrane is first layed back and replaced or repositioned following the operation.[10] A fractured or deviated nasal septum results in reduced drainage and respiratory functions. Deviations of cartilage and bone compress the turbinates, causing blockage of the sinus openings. The surgeon will remove the offending obstructions and re-establish a partition between the right and left nasal cavities by performing a septoplasty or a submucous resection.[2]

Partial Rhinoplasty

A partial rhinoplasty includes procedures such as when a surgeon rasps the dorsum, reduces the cephalic portions of the alar crus, and undermines the skin over the dome (see Figure 8).[2] Using the eversion or retrograde technique, an intercartilaginous incision is made with scissors placed retrograde and the lateral crus is exposed and trimmed (Figure 12). The cartilage is exposed by eversion and excised, allowing the tip to rotate upward. A transfixion incision is normally not made for a partial rhinoplasty. Another example of a partial rhinoplasty involves the weakening of the dome cartilage by interdigitating partial-depth cuts (Figure 13). A narrower tip with more projection is produced, converting a box shape into a triangular one. Morselization of the dome, a procedure in which an instrument called the morselizer with opposing interlocking teeth is used to take the stiffness out of cartilage, is not recommended.

Alaplasty may also be part of the surgical plan for partial rhinoplasty. In addition, a retrolabial-columellar graft may be inserted using alar cartilage sutured together in a layered fashion to reduce a sharp retrolabial angle (Figures 4 and 9). The alar grafts are stacked with convex sides facing outward.

Complete Rhinoplasty

A complete rhinoplasty is an extension of the partial rhinoplasty except when the dorsum or hump is reduced. The dorsum includes the anterior portion of the bony vault and the anterior septum. A complete rhinoplasty is equivalent to removing the roof of a rectangular pyramid (see Figure 8). If the base of the pyramid is too wide, it can be narrowed by performing osteotomies on its lower lateral surfaces. The anterior portions of these now detached walls are then joined to reform the roof of the pyramid. If osteotomies to narrow the base are not necessary, yet the dorsum roof has been removed, the surgeon may reduce the dorsum with a rasp and scalpel, then replace the original portion of dorsum that may also have been reduced to recreate the roof (see Figure 8).

Lateral osteotomies are accomplished through stab wounds in the posterior area of the left and right vestibules. Incisions are made near the pyriform aperture to the bone. A Joseph periosteal elevator is then used to raise the periosteum prior to posting osteotomes or saws. Saws or osteotomes are inserted in a cephalad direction.[2]

If osteotomes are used, the surgeon will hold and direct the osteotome with one hand while positioning the fingers of the other hand to determine when the osteotomy is complete. Since the surgeon is using both hands at this time, the assistant is responsible for the appropriate blows with the mallet to the head of the osteotome, under complete supervision of the surgeon. The surgeon will direct the first assistant with phrases such as, "tap-tap," or "tap," or "too hard," or "a little harder." The assistant must be sensitive to the tone and inflection of the surgeon's verbal commands and strive to echo these commands with physical action. The blow struck must be a clean one, not a push or a glancing blow. There is a sound and feel that the mallet operator should develop. Earlier blows

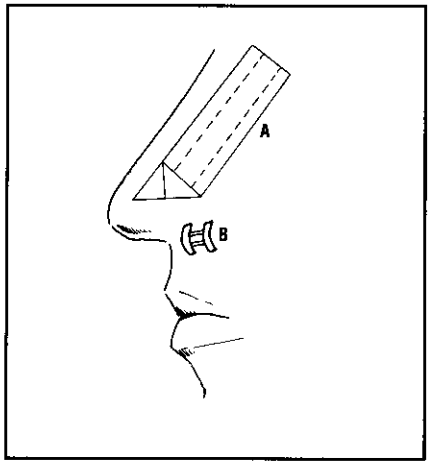

Figure 9. Columellar-labial angle repaired. **A**, Symbol for bony cartilaginous vault; **B**, Alar grafts in pocket behind columellar-labial angle.

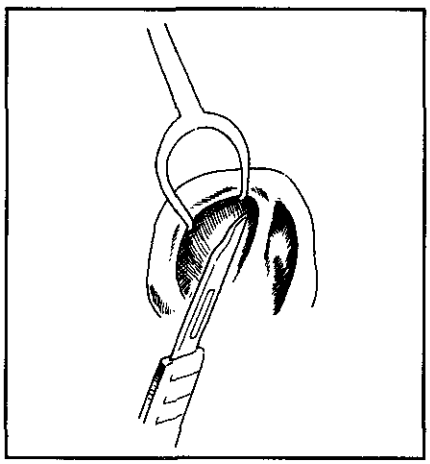

Figure 10. Vestibular incision.

are resonant and penetrating, while the final blow tends to be solid, resistant, and nonresonant.

Finesse Rhinoplasty
The term "finesse rhinoplasty" was coined by Sheen in his book, *Aesthetic Rhinoplasty*.[2] Finesse rhinoplasty has been performed by many surgeons in the past and continues to grow in popularity among surgeons. Finesse rhinoplasty is described by Sheen as "making something subtle out of something complex." Patients who want a finesse rhinoplasty are looking for super-refinement. This could involve reduction in size of an otherwise perfect nose or subtle tip refinement.

The attitude toward finesse rhinoplasty as described by Sheen is one of restraint because the surgeon is frequently dealing with a well-balanced nose that requires reduction in all of its dimensions while maintaining the original character.[2] Finesse rhinoplasty requires the application of any or all of the regular surgical steps associated with rhinoplasty in minimal degrees.

Specimen and Tissue Handling
Tissue taken from the nose must be handled carefully and kept moistened with saline solution.[11] Septal cartilage should be kept separately in a medicine cup or on a wet sponge, sheen grid, or tongue blade. Septal cartilage may be the first tissue removed and is returned just prior to closure. Turbinate and septal tissue must be saved in case it is necessary to prove that the nasal surgery was performed for more than cosmetic purposes.

Grafts
The most common sources of graft material for reconstructive purposes are the alar crura, septal cartilage, and the ear concha. Alternative sources include the ethmoid/vomer, cranial bone, and rib. The ninth rib could be called the nose rib because crushed portions of it can be contoured for use in the columella, tip, maxilla, and dorsum. The seventh, eighth, and tenth ribs are also usable as grafts.[2]

Postoperative Care
Generally, if no septal or turbinate surgery has been done, little or no packing is used. If a septoplasty or a turbinectomy has been performed, applied dressings should absorb secretions, stop bleeding, discourage adhesions, and assist nasal hygiene.[12] The surgeon may use a petrolatum gauze pack for 5 to 7 days. A vestibular area pack is used to aid in tissue approximation (24 hours). For septal surgery a surgeon may also use plastic splints sutured on each side of the septum using a through-and-through stitch, or magnets can be used to help in septal approximation and to reduce hematomas. These internal splints will be removed later with packs.[2,9]

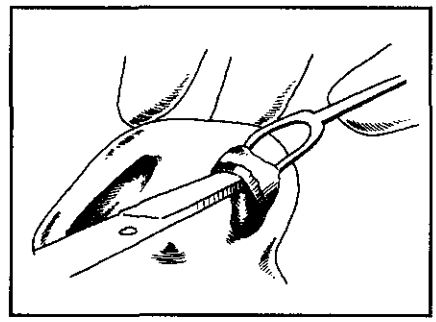

Figure 12. Eversion/retrograde technique.

Tincture of benzoin may be used externally over the bridge of the nose and on the malar area. Paper tape in layers is applied to prepare the area for either a plaster or plastic splint or a second layer of tape splint. A V-notched piece of tape will be used across the columella to help sling and form the tip. This is followed by a drip sponge dressing. A partial rhinoplasty may require only tape, while a complete rhinoplasty requires tape, splint, packs, and drip sponge. A finesse rhinoplasty may require either tape only or tape, splint, packs, and a drip sponge.[2]

The patient's head must be kept elevated and ice compresses should be applied on and off for 48 hours. Expect oozing for 24 to 48 hours, bruising for 1 to 2 weeks, and swelling for at least 6 weeks following the procedure. A degree of swelling may be evident for 1 year. Vestibular packs are removed 24 hours after surgery. Septal packs and splints are removed in 5 to 7 days. The patient should not blow his or her nose for 1 month.[2]

Postoperative Complications
Over-resection can result in postoperative valve complications. Vestibular stenosis in another postoperative consideration. An

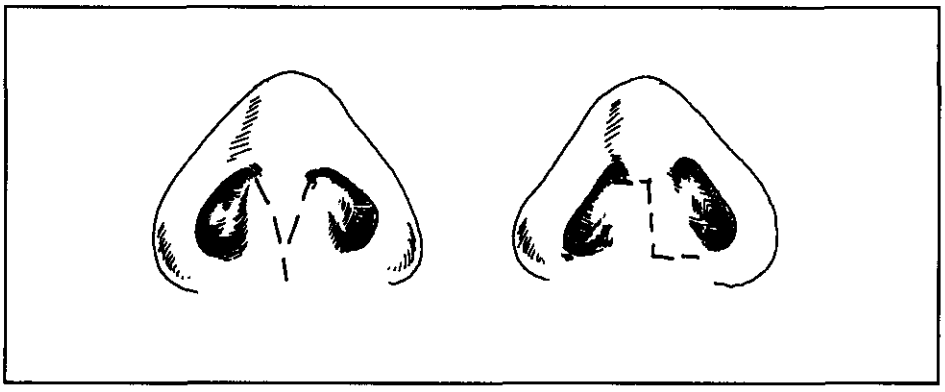

Figure 11. Open incisions. **A**, Chevron-like; and **B**, Stepped.

estimated 30% of rhinoplasty patients have some vestibular reduction due to synechiae following surgery.[2]

Postoperative infection is uncommon in aesthetic rhinoplasty; however, patients with poor healing may require a second procedure. The risk of complication is greatly reduced when patients follow the surgeon's instructions for postoperative care during the recovery period.[7]

First Assistant's Role

Surgical technologists who assist in a rhinoplasty procedure should be concerned with basic scrub considerations and also mindful of the pulse oximeter, blood pressure monitor, and ECG during the case. The assistant should also read the chart for information regarding the surgeon's intentions. Check the surgical history and look at computer images, photos, and x-ray film. Surgical technologists who are involved in admitting the patient must check that all the necessary paperwork is in order including the surgical, anesthesia, and specialized consent forms, patient history and physical reports, preoperative questionnaires, lab results, lab and recovery room records, and postoperative instructions. All of these items provide crucial information. The patient must also be scheduled for a follow-up appointment.

An increasing reality in surgery today is that there are often three job roles that need to be filled (the surgeon, scrub, and the assistant) and only two individuals to carry them out: the surgeon and the surgical technologist who functions as the scrub and first assistant. In plastic surgery offices and surgicenters, the added demand is the ability to work from both sides of the table. On many occasions surgical technologists must assist with one hand and control the instrumentation with the other. For those who are not ambidextrous, it is helpful to become comfortable with using the less-favored hand outside of surgery, such as when eating or drinking. Rhinoplasty does not normally require a surgical technologist to work from both sides of the table, but he or she may be called upon to retract with one hand while stabilizing a tip graft or suction with the other hand.

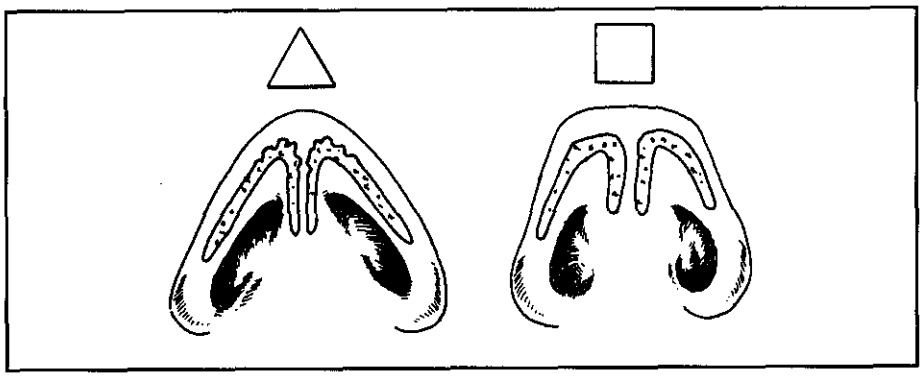

Figure 13. Partial rhinoplasty. **A**, Weakening of dome to produce higher angle; and **B**, Dome before partial-depth incisions.

Surgical technologists must anticipate as many of the surgeon's needs as possible in the set-up but should limit the mayo tray to the essentials. When the surgical technologist is holding retractors and the surgeon is getting his or her own instruments, the instruments may not be replaced in an orderly fashion, yet the surgical technologist must be able to find the instruments that the surgeon requests immediately. A magnetic instrument pad helps to organize in these circumstances and serves as a second or immediate needs mayo. Once the case begins, the priority shifts to assisting. The surgical technologist must carefully choose opportunities to regroup the scrub needs such as tray organization, specimen handling, and suture preparation.

Surgical technologists should always check the suction prior to each case. Nasal surgeries are very suction dependent. It is advisable to have two Frazier suction tips and one stylet on the field at all times. If a tip gets clogged with bone, the flow of the case can be maintained with a quick tip change. It is essential that there be a working suction at all times. The suction will alternately be used by the surgical technologist and the surgeon throughout the case during septoplasty, turbinectomy, osteotomy, skeletization, and closure and dressing applications. The surgical technologist must learn to sweep with the suction tip to get it in and out quickly.

One of the most important tools that a surgical technologist must have to function effectively as a first assistant is excellent observation. While the CST/CFA does not have the benefit of medical school, a second set of eyes alert for irregularities or red flags is a great asset to the surgeon and the patient. For example, during the skeletization of an area the surgical technologist's view enables him or her to see if the dissection is getting very thin. In such a situation, it is the surgical technologist's responsibility to make a cautionary remark; it could prevent an unwanted "button-hole" or iatrogenic cut or tear from the undersurface through the skin. The surgical technologist may see bleeding points in the gutter of a wound that are difficult for the surgeon to see. It is better to make an intervening statement that may prove unnecessary than to remain silent and find that you have made a costly omission.

In considering the synchronization of the scrub and assistant roles, the author can best express it as follows: When you sing, sing like Pavarotti; when you play piano, play like Horowitz. But on days when you must play and sing, think of Billy Joel or Ray Charles; they get along nicely blending two jobs.

Summary

Rhinoplasty is a vast surgical specialty that includes many procedures in addition to those discussed in this article. Although each

(Continued on page 33)