Reconstruction of a Mandible

ARTICLE BY LINDA O'CONNOR, CST

A serious defect of the mandible that necessitates reconstruction may occur from a congenital abnormality, osteomyelitis, osteoradionecrosis, trauma, or resection of a tumor. In such instances, reconstruction of the mandible is necessary because without a continuous mandible, the soft tissue of the lower face loses its supportive framework, resulting in nutritional and speech difficulties, oral incontinence, and cosmetic distortion.

Mastication of food—necessary to maintain a normal diet—depends on an intact mandible to provide a firm foundation for teeth (whether natural, dental implants, or dentures) to withstand the pressure involved in chewing. Since speech occurs through the coordination of the larynx, mouth, lips, chest, and abdominal muscles, dysfunction of the mouth and lips impacts communication. Additionally, oral incontinence presents the difficulty of maintaining tissue integrity and therefore necessitates constant attention to the mouth. Finally, cosmetic distortion may have a negative impact on a person's self-image that will impair social interaction and result in extreme emotional stress.[1] The case study presented in this feature follows one patient's perioperative experience with a recurring tumor of the mandible and the impressive reconstruction that returned both form and function, thereby allowing the patient to resume a normal life.

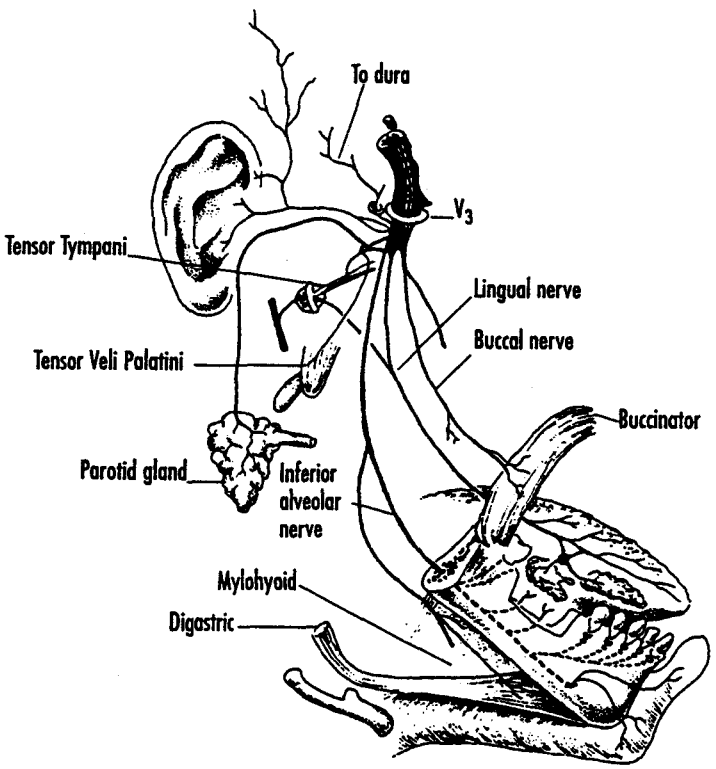

Figure 1. Trigeminal Nerve

Anatomy and Physiology

Embryologically, the mandible is the first part of the face to form: It develops in two halves that fuse along a midline *symphysis*, the fusion usually not being completed until the second year of life. The mandible is composed of a horseshoe-shaped horizontal body with two upward-angled projections (*rami*) at its ends. Each ramus has a *condyle*, which constitutes part of the *temporomandibular joint (TMJ)*, and a *coronoid process*, where the *temporalis* muscle inserts. The *masseter* and *medial pterygoid* muscles insert on the ramus and angle of the mandible. The *mylohyoid* muscle that forms the floor of the mouth arises along a line on the internal aspect of the mandible. The *anterior digastric, geniohyoid,* and *genioglossus* muscles attach to the internal aspect of the mandible near the symphysis. The *superior constrictor* muscle of the pharynx attaches near the mandibular angle. A *mandibular foramen* is located on the internal aspect of each ramus, near its center; a *mental foramen* is located on the external aspect of the body, on either side of the symphysis.

Chewing involves mandibular movements in vertical, anteroposterior, and horizontal planes and requires coordination of the four muscles of mastication (*temporalis, masseter, medial pterygoid,* and *lateral pterygoid*). The suprahyoid muscles (*digastric, mylohyoid, geniohyoid,* and, indirectly, *stylohyoid*) also act on the mandible while the infrahyoid or "strap" muscles (*sternothyroid, thyrohyoid, sternohyoid,* and *omohyoid*) stabilize

the hyoid bone. The *buccinator* and *orbicularis oris* muscles help keep food between the occlusive surfaces of the teeth. Swallowing requires coordinated movements of the tongue, palate, hyoid bone, and muscles of the pharyngeal wall.

Most of the innervation of the mandibular area is provided by cranial nerve V, the *trigeminal nerve*, via its third division, the *mandibular nerve* (V_3). The sensory component of the mandibular nerve has three branches in the area of the oral cavity: (1) the *buccal nerve* supplying sensation from the skin of the cheek, the buccal mucosa, and part of the gingiva; (2) the *lingual nerve* supplying general sensation from the mucous membrane of the anterior two-thirds of the tongue, part of the gingiva, and the mucosa of the floor of the mouth; and (3) the *inferior alveolar nerve* that enters the mandibular foramen to pass in a canal deep within the bone, giving off *dental branches* to the lower teeth and supplying the *mental nerve* that emerges from the mental foramen to supply sensation from the skin of the chin and, as the *inferior labial nerve*, the skin and mucosa of the lower lip (Figure 1).

The motor component of the mandibular nerve innervates the four muscles of mastication: the *temporalis, masseter, medial pterygoid,* and *lateral pterygoid* muscles. Motor branches of V_3 also innervate the *tensor tympani* and *tensor veli palatini* muscles, as well as two muscles of the floor of the mouth, the *mylohoid* and the *anterior belly of digastric* (Figures 1 and 2). Most of the muscles of the palate, pharynx, and larynx are innervated by branches of the ninth and tenth cranial nerves (*glossopharyngeal* and *vagus*). The extrinsic and intrinsic tongue muscles are innervated by cranial nerve XII (*hypoglossal*). The suprahyoid muscles are innervated by branches of cranial nerves VII (*facial*) or V_3 (mandibular division of trigeminal), while the infrahyoid muscles are innervated by the *ansa cervicalis* of the cervical plexus.

The *external carotid artery* gives rise to the *facial artery*, which along its course gives off the *submental, inferior labial,* and *superior labial* arteries, nourishing the submental and lip regions, respectively. The *lingual artery*, also coming off the external carotid, supplies arterial branches to the floor of the mouth, tongue, soft palate, tonsillar region, and epiglottis. One of the terminal branches of the external carotid, the *maxillary artery*, provides branches to the muscles of mastication and gives off the *buccal artery* and the *inferior alveolar artery*. The inferior alveolar artery and its three branches (*lingual, mylohyoid,* and *mental*) follow paths similar to those of the corresponding nerves.[2] From veins that accompany these arteries, venous drainage flows into the *subclavian vein* via the *anterior jugular* and *external jugular veins* and into the *internal jugular vein*.

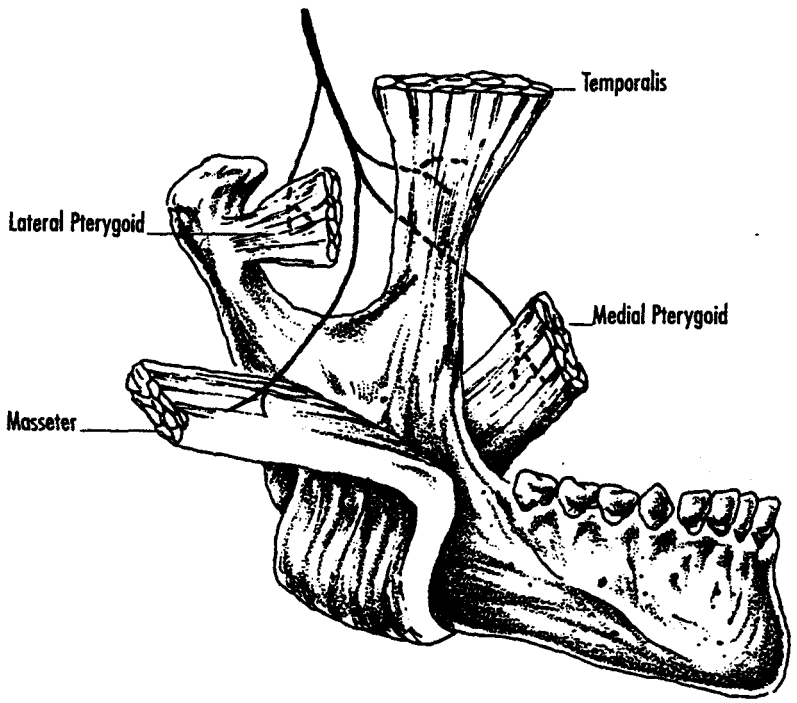

Figure 2. Motor innervation to the four muscles of mastication.

Types of Mandibular Reconstruction

Several methods of mandibular reconstruction exist, and each is applicable to specific situations. Using an external approach to avoid contamination from the oral cavity—subsequent to any excision and/or debridement of the mandible—synthetic materials have been used as a mandibular substitute for many years. These materials include single or double Kirchner wires, acrylic or silicone prostheses, and stainless steel bars, which have not proven satisfactory because of their poor response to the pressure and constant chewing motion of the reconstructed jaw. The thinness of the oral cavity's mucosal lining was a factor in the high extrusion rates and increased incidence of infection associated with the use of these alternative materials.[1] Titanium and stainless steel reconstruction plates have proven more adaptable; however, they present long-term problems, such as metal fatigue and screws that eventually loosen. In addition, when dentures are placed over a bridge consisting of a plate, chewing may cause extrusion and accompanying infection. Vascularized bone grafts may be necessary when a significant deficit of soft tissue exists. Autologous or allogeneic grafts, consisting of cancellous bone from the illac crest, calvaria, or rib, can be considered as options that work well when the soft-tissue bed is well vascularized.

Material consisting of a combination of autologous and allogeneic bone can be used as an alternative graft. In March of 1996, Dr Melugin, Assistant Professor of Oral and Maxillofacial Surgery at the Medical College of Wisconsin, explained that this combination of bone is used in

the "matrix band technique"— a procedure attributed to Robert E. Marx, DDS. This procedure, which has been performed for several years, uses allogeneic rib to provide a scaffolding for autologous bone from the posterior iliac crest. However, it must be processed through a bone mill before it is used. The rib also contributes bone morphogeneic protein (BMP), which induces the osteoplastic cells of the periosteum to produce bone. The cancellous bone from the posterior iliac crest contains the highest concentration of osteoplastic (bone forming) cells of all the possible graft donor sites. Eventually, the rib scaffold is replaced by the patient's own bone. By combining autologous and allogeneic bone, minimal bone resorption occurs; thus, sufficient bony height is achieved. The newer dental implants, osseointegrated artificial teeth, can provide patients with a more normal oral cavity. They can be implanted once the natural process of bone remodeling in the reconstructed mandible occurs.

Mandible reconstruction requires oral surgeons to call upon both their knowledge and artistry. It also provides an opportunity for surgical technologists to display specialized skills as part of the surgical team. The following case study examines one patient's perioperative experience resulting from the treatment of a recurring tumor of the mandible. The reconstruction performed by the surgical team and perioperative support staff restored normal form and function to the oral cavity, thus significantly improving the patient's quality of life.

Patient History

A 39-year-old female presented with pain at the site of a previous surgery. The pain occurred when her partial denture was inserted and when the area was touched. A Panorex™ film showed radiolucent areas at the symphysis, and the occlusion showed border irregularity. Because the patient was in good health otherwise, this appeared to be a recurrence of a tumor that previously had received nonresection treatment, rather than a newly occurring (primary) neoplasm. A treatment plan was based on an incisional biopsy and a computed tomography (CT) scan. A mandibular odontogenic myxoma was diagnosed.

Odontogenic myxoma is a tumor that originates from the tooth germ in the jaw, usually during a person's twenties or thirties. It appears to occur mostly in the mandible and may be associated with missing or buried teeth. The lesion, which expands the bone, may destroy the cortex and/or teeth. Because the tumor grows slowly, the patient may or may not experience pain. On Panorex film, the lesion may appear mottled or honeycombed. Treatment requires surgical excision or resection of the tumor which, although benign, can be difficult to remove because of the gelatinous nature of the bone affected by the tumor. Prognosis is good; however, recurrence is unpredictable.[3]

Tumor Resection

Approximately 6 weeks after the initial visit, following which the diagnosis was made, the patient was brought to the surgical suite for tumor resection. Under general anesthesia, the patient was prepped and draped following the specifics outlined on the surgeon's preference card.

A throat pack was placed in the patient's oropharynx, and an Erich arch bar was shaped and applied to the maxilla. For the mandible, a combination of Dingman wires and Ivy loops, fashioned from stainless steel wire, were placed for later intermaxillary fixation. Lidocaine with epinephrine was injected for local hemostasis near the inferior border of the mandible and a transcutaneous incision was marked with a surgical marking pen. The incision was made once the effects of the lidocaine were observed. Both sharp and blunt dissection techniques were performed, and a nerve stimulator and electrocautery were used when necessary. When the dissection was completed, the area was packed with saline-moistened sponges.

Before intraoral incision and dissection, lidocaine with epinephrine was injected again for local hemostasis. An incision was made around the teeth and extended in the labial aspect of the symphysis region to allow for excision of a cuff of tissue surrounding the lesion. The incision continued around the teeth in the lower left quadrant. Dissection was performed using sharp and blunt techniques (when possible intraorally), and then was completed via the transcutaneous incision after removal of the sponges.

Tooth No. 29 was extracted, a portion of the inferior alveolar nerve on the right side was decorticated, and the mental and inferior alveolar nerves w dissected and protected. A Synthes™ 2.7-mm reconstruction plate was adap ed in the following manner: three hol on the right and left sides of the mandible were placed using a Zimmer™ wire driver with a .062 K-wire while the plate was held in place. The plate was then set aside. Tl bony cuts were marked using a bur, a the resection was completed with a Zimmer reciprocating saw. The osteot my extended from the extraction site (tooth No. 29 to the anterior border of the mental foramen and through the inferior border of the mandible. Using flexible ruler on the left side of the mandible, the osteotomy was measure 12 mm medial to tooth No. 30 and directed anterior and inferior to the mental foramen through the inferior border of the mandible. The resected portion was removed and placed on a separate table to be radiographed. The intraoperative radiographs indicated t neoplasm had been removed entirely. a precaution, an additional 2 mm to 3 mm of bony margin was excised. The patient was placed in intermaxillary fi ation. After thorough irrigation, the pr formed reconstruction plate was secur tightly to the mandible using 2.4-mm bone screws of appropriate lengths.

Intermaxillary fixation was released and intraoral closure of the mucosa wa accomplished using 2-0 polyester (Ethibond™) suture to secure the musculature of the tongue base to the recor struction plate. Following this, the men talis muscle was reapproximated and 3-0 polyglactin 910 (Vicryl™) suture wa used for the final closure of the mucosa Extraorally, closure was achieved by attaching the digastric muscles to the plate using 2-0 and 3-0 polyester (Ethibond) sutures. This was followed by a multiple-layer closure using 3-0 and 4-0 polyglactin 910 (Vicryl) and 5-0 nylon (Ethilon™) sutures and the placement of a 2-0 silk (Perma-hand™) suture that secured a Jackson-Pratt drain. The oropharynx was then suctioned dry, the throat pack removed, and intermaxillary fixation was reestablished.

Postoperative Period

On the sixth postoperative day, the patient returned to the clinic because she experienced drainage from the incision site. The wound was incised and

drained, and the patient was placed on antibiotics and admitted to the hospital. After 3 days, the patient was stable and thus, discharged.

Surgical Preparation for Mandibular Reconstruction

Three factors—multiple patient positions, several instrument trays, and specialty equipment used for this type of mandible reconstruction—necessitated appropriate room preparation in the surgical suite. The senior resident informed the circulator and the surgical technologist that the patient would be induced in the supine position, turned prone to harvest the posterior iliac crest graft, and returned to the supine position for the remainder of the procedure. It was decided to induce the patient while supine on the ambulatory surgery cart. The operating room table and one arm board were padded with egg-crate type material (2 inches thick) and covered with linen sheets. Chest rolls of appropriate size were obtained and positioned on the OR table, and a draw sheet was draped over them. Other necessary furniture and supplies included a 6-foot-long back table, bipolar cautery and wall adapter, and air cord for the air-powered equipment (Zimmer Power System™).

A case cart system obtained from central sterile supply was brought into the OR suite. It contained the sterile supplies and instrumentation outlined on the staff surgeon's computerized preference card. Specialty supplies included a plating system (Synthes Mandible Trauma System™), a bone bank rib (Musculoskeletal Transplant Foundation™), and various pharmaceuticals: 1% lidocaine with epinephrine (1:100,000) and a bone reconstitution solution that the OR pharmacy prepares specially. The solution, which is prepared in a pour bottle, consists of 50,000 μ bacitracin (Upjohn) and 500,000 μ polymixin (Pharmacia) in 100 ml of normal saline with a 7-day expiration. Based on the information received concerning patient positioning, extra draping materials and surgical gowns were obtained and held aside to open at the appropriate time.

Instrumentation was set up on the back table, and the instruments used most often were placed on the Mayo stand; other instruments would be brought to the Mayo stand as needed (Table 1). Since part one of the procedure involved harvesting bone from the posterior iliac crest, suitable instrumentation was arranged on the Mayo stand. Drapes, cautery, suction, and instrument mat were also arranged in order of use and placed on the Mayo stand to facilitate the process.

Part I - Bone Harvesting

Anesthesia Induction

The patient was brought into the operating suite on the gurney, which was positioned close to the anesthesia equipment (the OR table/bed having been previously moved closer to the sterile area to allow the necessary space). During the induction and preparation for patient positioning, both the circulator and surgical technologist maintained a vigil to ensure the sterile field was not breached. The general anesthetic was begun with sedatives and a numbing of the nasopharynx before dilatation and insertion of a nasal endotracheal (ET) tube. Placement of this tube was accomplished with the assistance of an anesthesia technician and staff anesthesiologist using a fiberoptic bronchoscope. Once the ET tube was in place, it was secured with tape, and the patient's eyes were protected. A towel was wrapped around the head turban-style to cover the patient's hair and was secured with adhesive tape.

Patient Positioning and Preparation

The OR bed was positioned next to the gurney, and both were locked in place. The patient was rolled onto her side and then lifted onto chest rolls (previously positioned on the OR bed) by available OR team members. The gurney was unlocked and removed from the room after all monitoring and IV lines were ascertained to be clear of its path. The patient's position was adjusted on the OR bed to ensure proper positioning of the chest rolls. The head and neck were supported by two stacked, doughnut-shaped pads, and the elbows and wrists were padded and the arms secured. The knees were already cushioned by the egg-crate pad on the OR bed, and two pillows were placed under the lower calves to suspend the feet.

The circulator placed the electrosurgical grounding pad on the lateral aspect of the thigh on the side opposite the graft site. The operative site was examined by the oral surgery residents. Tl circulator was directed to perform th surgical prep according to the surgeo preference card. This consisted of a ti ture of iodine scrub followed by a tin ture of iodine paint.

Harvesting the Bone

After completing the prep, the surgic site was draped by squaring off with four towels, which were secured with four towel clips. A disposable laparot my drape was placed and secured wi the adhesive strips built into the drap The electrocautery and suction tubing were secured to the drape, and the appropriate ends were passed to the c culator for connection to their respecti units. With the placement of the light handles and the instrument mat, drap ing was complete. Subsequent to chec ing with anesthesia personnel, the sur geon made a standard curvilinear inci sion over the posterior iliac crest. Shar dissection exposed the posterior iliac crest, and electrocautery was used jud ciously. When the lateral aspect of the crest was exposed and the periosteum elevated, a block consisting of both co tical and cancellous bone was removec using various osteotomes. An assortment of gouges and curettes was used to harvest approximately 65 ccs of resi ual cancellous bone and some other small fragments of cortical bone. All of this bone was placed in a specimen cor tainer and moved to the back table for safekeeping.

The wound was irrigated with copious amounts of antibiotic irrigating solution and packed with a hemostatic agent (Avitene™); when hemostasis wa achieved, a closed-wound drain (14 Fr Jackson-Pratt) was placed through a separate puncture made anterior to the incision and bony defect. The area was then closed in layers using polyglactin 910 (Vicryl) suture in appropriates sizes Staples were used to approximate the skin edges. The drain was secured with a silk (Perma-hand) suture. A small piece of nonadherent dressing and sterile 4x4 dressing sponges were applied t the incision site, and a drain sponge wa placed around the drain. The drapes were removed and the dressings were secured with tape.

Part II - Mandibular Reconstruction

Patient Repositioning and Preparation

The gurney was returned to the OR suite and locked into position alongside the OR bed. The patient was rolled off the chest roll on the gurney side, and the chest roll was removed. The patient was then rolled off the OR bed onto the gurney by the OR team. Anesthesia personnel checked the patency of patient-airway and IV tubing while the circulator removed the remaining chest roll from the OR bed. This time, the patient was lifted onto the OR bed in the supine position. The gurney was unlocked and removed from the room once all monitoring and IV lines were determined to be clear of its path. The patient was adjusted on the OR bed to ensure proper positioning: the head resting on a doughnut-shaped pad, the left arm extended on a padded arm board for anesthesia access, the right arm secured alongside the patient's body, and a pillow placed under the knees for lumbar support.

The grounding pad was inspected to ensure that proper contact was maintained. The ET tube was readjusted and secured to angle toward the forehead while avoiding placing tension on the nostrils. A sterile plastic drape (1010 Vi-Drape™) was placed over the lower lip below the vermilion border and opened cephalad in an aseptic fashion. The lower face, neck, and drape were washed with a soap (pHisoHex™) and saline mixture and rinsed with saline-saturated 4x4 sponges.

Instrument Preparation

After the bone harvesting, but before removing the drapes, the cautery, suction tubing, and instrument mat were removed from the drape and placed onto the Mayo stand. They were then secured and kept sterile for use in the reconstructive portion of the surgery. Care was taken to maintain the sterility of the field ends while the unsterile portion was suspended off the Mayo, and the ends balanced on the base of the Mayo. In an effort to prevent contamination, sterile items were grouped together and placed on the sterile side of the room. The Mayo was moved carefully, along with the back table and ring stand bearing a rinse basin. The lights were adjusted toward the ceiling to protect the sterility of the light handles. The scrub person remained sterile to prepare the Mayo stand for the reconstructive portion of the surgery and to guard the sterile field while the unsterile team members repositioned the patient. Instruments used for the bone harvest procedure, which were no longer needed, were rinsed in the basin and returned to their trays. Instruments needed for the reconstruction were arranged on the Mayo tray (Table 1).

Table 1. Instruments Required for the Surgical Procedure

Back table setup

Instrument Trays

- Oral general - soft tissue instruments and periosteal elevators
- Oral saggital - mandibular osteotomy instruments
- Zimmer Power System™
- Obwegeser™ retractors
- Synthes 2.4 Mandible Trauma Set™
- Tessier Bone Mill™
- Basic 1 - basic soft-tissue instruments
- Lambott™ osteotomes
- Tessier Bone Bender™

Mayo setup - Part 1

- #3 knife handles: 1 #10 and #15 blade on each
- 8-inch Debakey™ tissue forceps
- 6-inch Kocher™ clamps
- Freer elevator
- 7-inch Metzenbaum™ scissors
- 5-inch tissue forceps with teeth
- 6-inch curved Crile hemostats
- Bunion elevator

Placed on Mayo as needed:

- Rake retractors
- Selection of osteotomes
- Bone gouges
- Specimen cup to collect bone graft
- Sharps safe
- Various suture material:
  - 0, 2-0 polyglactin 910 (Vicryl™)
  - 3-0 silk (Perma-hand™)
- Gelpi retractors
- Mallet
- Bone curettes
- Needle holders
- Suture scissors
- Skin staples

Mayo setup - Part 2

- #3 knife handles: #15 blades on each
- Adson™ forceps with teeth
- Adson™ forceps without teeth
- Molt™ periosteal elevator
- Freer™ elevator with one end strongly curved
- 3-inch tenotomy scissors
- 5-inch Debakey™ forceps
- Mosquito hemostats: curved & straight
- Freer™ elevator, slightly curved
- Seldin™ periosteal elevator
- Obwegeser™ retractors - various sizes

Placed on Mayo as needed:

- Disposable nerve stimulator
- From Synthes 2.4 Mandible Trauma Set™:
  - Screw drivers
  - Depth gauge
  - Drill bit guide
  - Bone cutter
- Various suture material:
  - 2-0, 3-0 polyglactin 910 (Vicryl™)
  - 3-0 chromic surgical gut suture
  - 4-0 nylon (Ethilon™)
  - 3-0 silk (Perma-hand™)
- Power handpieces and cord (Zimmer Power System™)
- Needle holders
- Suture scissors
- Sharps safe

Mandible Reconstruction

At the completion of the prep, the surgical site (including the Vi-Drape-covered mouth) was draped by squaring off with four towels that were secured with

four towel clips. Then, a disposable split-sheet drape was placed and secured with the adhesive strips built into the drape. The top edges of a disposable half-sheet drape were secured to IV standards placed alongside the patient's left side to construct an anesthesia screen. The lower edges were secured to the split sheet by the scrub person with Kelly clamps. The electrocautery and suction tubing were secured to the drape, and the appropriate ends were passed to the circulator for connection to their respective units. The instrument mat was placed on the patient and the OR lights were adjusted.

The patient was injected with 1% lidocaine with epinephrine along the previous submental incision. A large keloid that had formed across the old incision line was excised. Sharp dissection continued through the skin and subcutaneous tissues, and proceeded along the scar line down to the anterior belly of digastric muscle, then up to the anterior border of the mandible. A disposable nerve-stimulator unit was applied to identify nerves, and electrocautery was used judiciously. The periosteum was sharply incised at the right and left segments of the mandible and carried across the inferior border of the mandibular reconstruction plate. With the plate exposed, the screw lengths were assessed. The length of three of the screws was determined to be excessive; they were therefore replaced with screws of appropriate length. The screws that had been removed were cleaned off in the rinse basin and saved on the back table by the scrub person. A pocket of tissue was developed in the anterior mandible, thus allowing for the maintenance of the alveolar height necessary to accommodate the bilateral segments. Bimanual palpation of the oral cavity (pressing the drape into the oral cavity) was performed through the Vi-Drape, which was serving as a barrier to prevent contamination from the oral cavity. This was conducted to verify that an adequate mucosal pocket had been created to prevent the formation of excessive scar tissue between the oral mucosa and bone graft.

While the residents injected the submental incision line and began the dissection, the staff surgeon (using space allotted at the back table) began to shape the freeze-dried rib, which was reconstituted and floating in an antibiotic bath. A Zimmer saw was set up, and the air hose was attached to the back table. It was connected to an unsterile nitrogen extension hose that ran to the wall supply and was set at 110 psi. The staff surgeon selected a saw blade that was attached to the saw and tested by the scrub, and the rib was split lengthwise. Following this, the saw handpiece was removed and replaced with a burr handpiece (Zimmer Surgairtome II™) armed with the appropriate burr guard in place and a burr selected by the surgeon. The two pieces of rib were hollowed out until thin, and the posterior portion of the rib crest was rendered more flexible by crimping with a Tessier™ bone bender. Both pieces were returned to the antibiotic bath on the back table for safekeeping until needed. Attention was turned to the pieces of cortical and cancellous bone previously harvested from the posterior iliac crest. Once the bone was thoroughly shred in a Tessier bone mill, it was returned to the specimen container for safekeeping on the back table until needed.

At this point, the posterior piece of rib was pressed against the medial aspects of the mandibular segments bilaterally. After being measured and cut to the appropriate length, it was secured with a mandibular reconstruction screw of appropriate length on each side. Copious amounts of irrigating solution were used while drilling the holes. Using a Zimmer saggital saw, the anterior portion of the rib crest was notched at each end to ensure a secure fit around the screws attaching the mandible reconstruction plate. Four small holes were drilled into the rib crest to pass two 25-gauge wires, which secured the bone graft to the anterior aspect of the plate. A small, round burr was used to create six small holes in the posterior portion of the rib graft to allow for reapproximation of the floor-of-mouth genioglossus and geniohyoid musculature to this rib strut using a polyglactin 910 (Vicryl) suture in a vertical mattress fashion. Once the musculature was reattached, the previously milled cortical/cancellous bone graft was packed tightly into syringes, which were used to deliver the graft material to the mandibular defect. This made it possible to achieve not only an excellent bony height level, but also a tightly packed placement with no dead space and good contact with the resected mandible ends bilaterally.

A bimanual palpation (conducted through the Vi-Drape to prevent contamination from the oral cavity by pressing the drape into the oral cavity and along the alveolar ridge) was executed to ensure that the oral mucosa remaine intact with no communication between the graft and the oral cavity. The new occlusion was purposely left slightly higher to permit bone resorption. The area was irrigated thoroughly and closure completed in several layers. The preexisting strap and platysma muscles were replaced over the anterior mandible and reconstruction plate, and sutured with polyglactin 910 (Vicryl) suture of appropriate size in an interrupted, horizontal mattress fashion. A closed-wound drain was placed just inferior to the anterior border of the mandible and secured with silk (Permahand) suture. Interrupted subcutaneous sutures of polyglactin 910 (Vicryl) sutur material were placed for good wound eversion, and skin was closed with a running stitch of nylon (Ethilon) suture.

The oral cavity was exposed by removing the Vi-Drape. The adhered edge was peeled from below the lower lip edge, a throat pack was placed, and the patient was placed in maxillomandibular fixation using Ivy loops on the left side of the mandible and a Dingman loop on the right. After removing the throat pack and suctioning the oral cavity dry, the loops from both sides were secured to the preexisting maxillary arch bar, which was tightened and had several wires replaced that had broken during previous weeks. A pressure dressing was applied to the neck wound.

The patient's emergence from the general anesthetic occurred in the OR suite. The ET tube was removed in the Postanesthesia Care Unit. Upon recovering sufficiently, the patient was transported to her room on the nursing floor.

Postoperative Period

The patient continued to do well. The neck sutures were removed and replaced with Steri-strips™ on the sixth postoperative day. On the twelfth postoperative day, periodic injections of the corticosteroid Kenalog™ (10mg/ml) were begun in the keloid that had formed in the left submandibular region at the drain site and incision. The sta-

ples at the iliac graft site were removed. Intramaxillary fixation remained stable throughout the postoperative course and was released 6 weeks postoperatively. The patient continued to improve and was checked regularly. Two and one-half months postoperatively, the graft, mucosa, and gingivae were found to be intact, and the submental incision keloid showed evidence of responding to the Kenalog injections.

Conclusion

A serious defect of the mandible may occur from a congenital abnormality, osteomyelitis, osteoradionecrosis, trauma, or resection of a tumor. Several methods of mandible reconstruction are possible; each is suitable for certain situations. The surgical technologist will find that the mandibular reconstruction procedure calls upon his/her knowledge of the indications for such surgery, the anatomy and physiology of the mandible, patient preparation techniques, the selection of appropriate surgical instrumentation and supplies, and the surgical procedure itself as well as the associated postoperative considerations. Mandible reconstruction is an operation that emphasizes an oral surgeon's scope of knowledge and artistry. In addition, this procedure allows surgical technologists to demonstrate their specialized skills.

The case study examined one patient's perioperative experience in which a recurring tumor of the mandible and the resulting defect were treated. The impressive reconstruction performed by the surgical team and perioperative support staff made a significant difference in the patient's quality of life. Δ

References

1. Anderson JE. *Grant's Atlas of Anatomy*. 7th ed. Baltimore, Md: Williams and Wilkins Company; 1978:8-15.
2. Ruberg RL, Smith DJ. *Plastic Surgery of the Head and Neck*. St Louis, Mo: Mosby-Year Book, Inc; 1994:400-401.
3. Shafer WG. *A Textbook of Oral Pathology*. Philadelphia, Pa: W. B. Saunders Company; 1983:295-297.

Linda O'Connor, CST, *has been employed at Froedtert Hospital in Milwaukee, Wisconsin, since 1986. She has been a surgical technologist for 14 years and a CST for 12 years. She has served as Chapter 17 president, Wisconsin representative, and treasurer for AST Region 5; she currently represents Region 5 on the Bylaws Committee. She also received the PEAK Aw for Advanced Generalist in 1994 and the 1995 AST Outstanding Achievement in Public Relations Awa*

Other Suggested Anatomy Referenc

Hole JW. *Human Anatomy and Physiology*. 4th Dubuque, Iowa: Wm. C. Brown Publishers; 1987.

Moore KL. *Clinically Oriented Anatomy*. 3rd ec Baltimore, Md: Williams and Wilkins Compa 1992.

Moore KL. *The Developing Human: Clinically Oriented Embryology*. 4th ed. Philadelphia, Pa: W. B. Saunders Company; 1988.

Tortora GJ, Grabowski SR. *Principles of Anato and Physiology*. 7th ed. New York, NY: Harper Collins College Publishers; 1993.