Resurfacing the Aging Face

Linda O'Connor, CST

Signs of facial aging—for some a symbol of maturity and wisdom—signal the end of youth to others. Man has searched for eternal youth, or the appearance of such, since ancient Egyptian times when cosmetics were used to enhance beauty, and oils and lotions protected the skin from the sun's drying effects.[1] During the 19th and 20th Centuries, physicians have incorporated such cosmetic recipes into the practices of dermatology and plastic surgery, developing a treatment known as "chemexfoliation" or "chemical peel." Dermabrasion techniques were developed in the mid-1950s; more recently, state-of-the-art carbon dioxide (CO_2) medical lasers, which are either superpulsed or equipped with a computer-controlled device that delivers laser energy, have been used to resurface aging skin.

As a prerequisite to developing an understanding of the treatment techniques available today—including chemexfoliation, dermabrasion, chemabrasion, and laser resurfacing, as well as therapeutic and prophylactic applications—one must have a basic knowledge of the structure and function of the skin and the causes of aging skin.

STRUCTURE AND FUNCTION OF THE SKIN

Squamous epithelial cells—which form the epidermis (the outer layer of the skin) as stratified squamous epithelium—differentiate as they move from the basal layer (stratum germinativum) to the outermost layer (stratum corneum). They function with lipids in a brick-and-mortar fashion, forming a physical barrier to the external environment. Melanocytes, also found in the epidermis, produce melanin (pigment): Hyperpigmentation is seen when melanocytes increase in numbers or activity. The dermis (the layer of skin directly under the epidermis) consists mostly of fibrous connective tissue, which is comprised of collagen, elastin, and glycosaminoglycans (GAGs) that are formed by the dermal fibroblasts. Collagen provides tensile strength; resiliency is provided by the elastin; and the GAGs provide the normal tension of the extracellular space (by their large volume when well-hydrated). Hair follicles, eccrine and sebaceous glands, peripheral-nerve endings, and blood vessels are also found in the dermis.[2] (See Figure 1)

CAUSES OF AGING SKIN

Two factors, in addition to genetics, cause the skin to age: Inherent aging—consisting of the clinical, histological, and physiological changes that occur with the passing of time—and actinic radiation, which causes photoaged skin. Inherent aging leads to a loss of elasticity, usually referred to as wrinkling; however, photoaged skin also displays a wrinkled appearance.[3] Chronological aging displays epidermal thinning, which is likely caused by reduced epidermal-cell proliferation and a relaxed (or flattened) dermal/epidermal junction, which results in an increased frailty of the skin. In both types of skin aging, the number of active melanocytes (and the amount of protection afforded by the skin's pigmentation) decreases; however, photoaged skin damage results from cumulative exposure to the sun. Decreases in collagen content, dermal thickness, vascularity, and the number and functionality of fibroblasts not only delay wound healing, but contribute to the appearance of aging as well.[2]

TREATMENT APPROACHES

Chemexfoliation

Chemexfoliation (or chemical peel) involves applying chemical solutions to the face, which lift away layers of wrinkled skin.

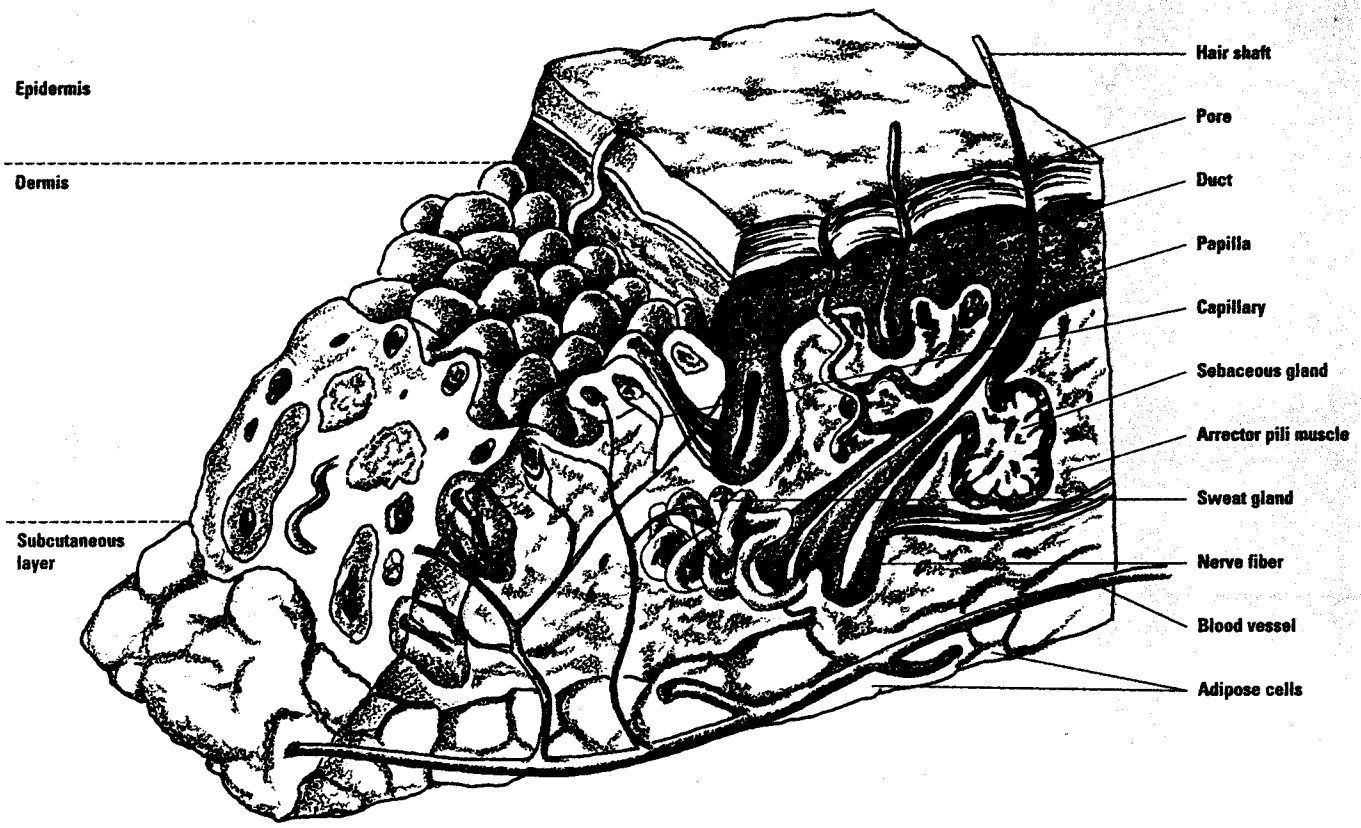

Figure 1—The structure of the skin.

Phenol was the chemical used as early as the 1880s by a young Scotch woman who was performing chemical peels.[1] *The Medical Journal and Record* of 1927 published possibly the earliest American article on cosmetic phenol peels, which described two kinds of peels: light (for removing/lightening freckles) and deep (to reduce wrinkles and lines). In 1961, the *Journal of the Florida Medical Association* published the Baker-Gordon Phenol Peel formula for chemical peel—3 ml phenol, 2 ml tap water, 8 drops of Septisol, and 3 drops of Croton oil—which has continued to be accepted.[1] Croton oil (a skin irritant) and Septisol (a liquid soap) allow the phenol to penetrate the skin layers. Candidates for this treatment must be in good health and have fair, thin skin. They should also have moderate to severe photo damage with deep wrinkling, hyperpigmentation, and melasma. Because phenol has a bleaching effect on the skin, it should not be applied to dark-pigmented skin; moreover, those patients who have kidney, liver, or heart problems should not be exposed to phenol because it can be toxic to these organs. (In all cases, the potential for systemic absorption of phenol must be limited by applying it sparingly over a period of time).

In the 1960s, trichloroacetic acid (TCA) peels use began to counteract the effects of moderate sun damage and wrinkling. TCA, used in concentrations of 25% to 50%, produces a medium peel (greater concentrations produce a deeper peel). Indications for TCA peels are moderate actinic damage, pigment changes or severe actinic damage—for whom phenol is contraindicated. To soften deep wrinkles, which can be difficult to obliterate, several applications may need to be applied over time.

In the late 1970s, Dr Scott discovered the efficacy of alpha hydroxy acids (AHAs) for softening fine wrinkles and treating the effects of light sun damage. AHAs, a group of naturally occurring fruit acids, can be used in low to high concentrations (25% to 70%) to produce superficial peels. Low-concentration treatments are used first, followed by higher-concentrated peels. The duration of treatment is increased before concentrations are increased. Theoretically, the most effective AHA is glocolic acid, which has the smallest molecular structure, allowing it to easily penetrate the skin. Indications for this peel are people with thin skin, fair complexions, and fine facial wrinkling. Patients with dark, oily skin tend to develop hyperpigmentation and therefore need to be treated with lower concentrations until skin response is established.[4]

Dermabrasion

Dermabrasion involves resurfacing the skin by removing the epidermis and middle dermis with sand paper (made of silica carbide); a wire brush; or a motorized, rapidly rotating hand-

piece equipped with a variety of abrasive attachments. Re-epithelialization and re-pigmentation then occur on the remaining skin surface, which contains the hair follicles, as well as the eccrine and sebaceous glands. When new collagen and epidermis replace the abraded skin, the skin's contour improves—even though the skin tightens only slightly. While deeper dermabrasion smooths deeper wrinkles, it also increases the risk of hypertrophic scarring, hypopigmentation, and keloid formation.[5]

Dermabrasion was standardized in the mid-20th Century. Wire brush surgery began modern dermabrasion techniques; however, it is technically more challenging than other methods. Sand paper is used to augment chemical peels by sanding fine lines.[6] When using motorized handpieces—especially dome- and pear-shaped handpieces with extra-coarse (90 to 100 grit) diamond surfaces—a significant amount of aerosolized particles are released into the air. The splatter shield should therefore always be used, and staff should wear surgical gowns, face shields/masks, and gloves.

A group of physicians documented the histopathologic effects attributable to dermabrasion. Preoperative and postoperative clinical and histopathologic changes were compared in 12 patients with significantly photoaged facial skin. Comparisons involved matching predermabrasion biopsies with postdermabrasion biopsies, which were taken at 6-month to 8-year intervals. The physicians concluded that dermabrasion improves the appearance of both naturally aged and photoaged skin, and additionally inhibits neoplasmic change.[7]

Figure 2—Perilabial region before laser resurfacing.

Figure 3—Perilabial region after laser resurfacing.

Chemabrasion

Chemabrasion (using both chemical peels and dermabrasion) increases skin turgor while blending the orbital pigmentation into the resurfaced cheek areas. Other studies led to the conclusion that chemical peels and dermabrasion reduce the recurrence of actinic keratoses and basal cell carcinomas. Additionally, chemabrasion

results in less recurrence of these conditions than either chemical peels or dermabrasion alone.[6]

LASER RESURFACING

Overview

In 1954, T.H. Maimon described the use of Light Amplification by Stimulated Emission of Radiation (LASER). Many applications were found for the first continuous laser—a gas laser developed in 1961.[8] Continuous lasers produce a wave of laser light with minimal power output variance over a given period of time. Surgeons can control the duration of the power output using a hand- or foot-switch, or a built-in electronic control to operate shutters or gates within the laser. Indications for laser resurfacing include rejuvenation of aged or photoaged skin, and treatment of pigmented and nonpigmented skin lesions, scars, and superficial or deep wrinkles.

The Joule (J) is used to measure laser energy; power (P) is measured in Joules per second (sec); and, 1 J/sec is called a watt (W). If laser power is set at 10 W, energy is being delivered at a rate of 10 J/sec. Therefore, during one second, tissue may potentially absorb 10 J of energy and conduct absorbed energy to surrounding tissues.[9] Continuous power delivery allows the tissue to desiccate (dehydrate) and carbonize (char).[8]

A pulsed laser produces multiple high-intensity bursts of laser light, which build to peak intensity and then drop off quickly. Pulsing also allows 10 J of laser energy to be stored and released at selected times and intervals. During superpulse, intervals are changed from 1 second to .001 second, and 10 J of energy are released in a power of 10,000 W. When 10 J of energy are delivered in .001 second, minimal energy can be conducted to surrounding tissues.[8] This circumstance results in protection against charring.

The CO_2 laser—an invisible light spectrum laser—has been applied in various surgical specialties during the past three decades. When the laser is delivered through continuous, pulse, or superpulse modes, the infrared light is absorbed by cellular or extracellular water in the stratum corneum and upper epidermis. Thermal conduction can be contained within less than 100 micrometers (μm) of tissue when a pulse of less than 1 millisecond (msec) is fired, allowing the energy to penetrate only 20 μm into the tissue.[10] During light-absorption, heat is produced, causing water in the tissue to boil, and any remaining tissue components are thus vaporized away in the laser plume. Superpulse, designed specifically for CO_2 lasers, produces bursts of high-intensity laser light that build to a peak intensity and drop off quickly. These "super" bursts of laser light (less than 1 millisecond in duration) provide a power density greater than the level needed for clean vaporization of tissue during a single laser pulse.[9]

With recent refinements, the CO_2 laser facilitates achieving accurate skin resurfacing results: Injury is restrained superficially; thermal conduction is limited; and adequate energy is available to ablate the tissue. Several FDA-approved CO_2 laser technologies use computers to control a series of mirrors that affect the laser light-beam pattern. The laser used today was created by combining computer technology with that of the superpulse laser, which enables surgeons to continually improve upon the skin resurfacing procedure.

Procedure

Local or general anesthesia (along with IV sedation) is administered before performing laser resurfacing, which involves a large portion of the face. Washing the face with an antibacterial cleanser is sufficient preoperative preparation. Appropriate laser precautions must be taken to protect the patient and staff. The laser is tested preoperatively by a qualified laser operator and adjusted to settings specified by the surgeon, who must be credentialed to use the laser. Preoperatively, the surgeon considers the following variables: the laser (spot diameter, energy-per-pulse, and power output) and, the patient (quality of the skin and general area to be resurfaced). The rate of delivery, which is controlled by the laser's power output, determines the speed at which the skin is resurfaced. Using a 3-millimeter handpiece, power settings between 250 and 500 milliJoules (mJ) per pulse are recommended, depending on thickness of skin and depth of ablation.[11,12] If a power setting of less than 200 mJ per pulse is used, the energy delivered to the tissue will prove insufficient to effect the evaporation process.[8]

The number of times the surgeon passes the laser over an area to be resurfaced is determined by the depth of ablation necessary to achieve the desired outcome. The first pass is usually performed with a slight overlapping of the adjacent pulses and removes the epithelial layer; after completion, the debris is wiped away with saline-moistened gauze or cotton applicators. During the second pass, skin tightening becomes noticeable as the dermal layers shrink, and the collagen tightens with the contraction.

Table 1—Comparison of Resurfacing Methods, Amount of Wrinkling and Complications

METHOD OF RESURFACING	AMOUNT OF WRINKLING	COMPLICATIONS
AHA Peel	fine wrinkling	Herpetic eruption, minimal hyperpigmentation, minimal hypopigmentation
TCA Peel	moderate wrinkling	Erythema, hyperpigmentation, chance for scarring after persistent erythema
Phenol Peel	deep wrinkling	Systemic absorption of the phenol, hypopigmentation, hyperpigmentation, increased prominence of pores, hypertrophic scarring
Dermabrasion	moderate wrinkling, deep wrinkling	Hypopigmentation, hypertrophic scarring, keloid formation, increased hypopigmentation, hypertrophic scarring, keloid formation
Laser resurfacing	fine–deep wrinkling	Minimal to moderate hyperpigmentation, prolonged erythema and scarring

Table 2—Comparison of Published Studies on Laser Resurfacing

STUDY	# OF PTS	FOLLOW UP PERIOD	IMPROVEMENT OF WRINKLES	COMPLICATIONS
Lowe et al	100	6 months	moderate to marked	Transient erythema and hyperpigmentation
Fitzpatrick et al	111	1-12 months	notable	Transient erythema and postinflammatory hyperpigmentation
Alster et al	259	24 week	90% improvement	Erythema and postinflammatory hyperpigmentation
Waldorf et al	47	9.7 weeks	65, 55, & 39%	Erythema and edema, hyperpigmentation

Complications include hyperpigmentation, prolonged erythema, and scarring. Hyperpigmentation may be prevented by using sun screen, and erythema may be prevented by using topical steroids. Scarring, while possible, is unlikely.[8] (See Table 1.)

Results of laser resurfacing in the perilabial region are shown in Figures 2 and 3. In February 1997, David Larson, MD, Professor and Chairman of the Department of Plastic and Reconstructive Surgery at the Medical College of Wisconsin, explained that Figures 2 and 3 illustrate results typically achieved with laser resurfacing. Dr Larson believes laser resurfacing produces better results than dermabrasion or chemical peels.

PUBLISHED STUDIES

Published clinical studies document improvements after laser treatment for rhytids (facial wrinkles), as well as precancerous and benign pigmented and nonpigmented skin lesions.[11] In a study by Lowe, Lask, and Griffin et al, 100 patients with varying degrees of photodamaged skin underwent treatment with the Ultrapulse Carbon Dioxide Laser. Selected patients were evaluated before and after treatment in order to determine the severity of photodamage: Skin surface replicas were reviewed using computer image analysis technology. One month following treatment, 68 patients demonstrated a moderate improvement from their baseline, 5 showed a marked improvement, and 27 a minimal improvement. All patients developed transient erythema, which lasted up to 6 weeks, and many developed transient hyperpigmentation, which lasted up to 4 months. Study results indicate that the Ultrapulse Carbon Dioxide Laser provides an effective method for resurfacing photodamaged skin.[12]

Fitzpatrick, Goldman, and Satur et al conducted a study of the degree of clinical improvement achieved through laser resurfacing procedures. Four reviewers independently scored preoperative and postoperative photographs using a nine-point clinical scoring system that was created to evaluate wrinkling and photodamage: They noted a 45% to 50% improvement in these areas, while documenting the minimal risks, which included erythema (lasting less than 90 days for the majority of patients) and hyperpigmentation in darker skinned patients (resolving in 8 to 16 weeks with treatment). Hypopigmentation did not occur; however, scarring—apparently related to the anatomic location and depth of treatment—occurred on the upper lip of one patient; another patient experienced an induration at the vermilion border.[10]

Alster and Garg noted the following in their study of 259 patients treated with laser resurfacing:

- A 90% improvement in perilabial, periorbital, glabellar, and forehead rhytids

- A 24-week follow-up illustrated minimal side effects
- When erythema developed, it averaged 10 weeks in duration
- Hyperpigmentation (following inflammation) occurred in 33% of the patients and lasted for an average of 12 weeks.[10]

Waldorf et al conducted a retrospective view of 47 patients within 9.7 weeks following the laser procedure. Results were broken down for three facial areas: Average degree of improvement were approximately 65% for the periorbital skin; 55% for perioral skin; and 39% for glabellar skin. Erythema and edema were reported in 100% of the cases, while 17% had hyperpigmentation, 8.5% developed excessive milia; 6.4% suffered impetigo; 4.3% developed eczema; and, 4% experienced contact dermatitis as a reaction to Bacitracin ointment. (See Table 2.)

A histological study documented skin changes in a small group of patients who were treated with a high-energy, short-pulse CO_2 laser. Changes were compared with those achieved through standard chemexfoliation procedures. Cotton et al concluded that the laser treatment produced morphologic changes similar to those produced by medium-depth chemical peels. Skin ablation was precise, blood loss did not occur, and the wound healing process was rapid. A subepidermal repair zone of fibrosis appeared to be responsible for improved clinical appearance following treatment.[13]

While the results of these studies are impressive, follow-up time (on average) was typically only 3 months or less, with the longest being 6 months. In many of the studies, it was noted that patients were continuing to improve, indicating that initial results would be enhanced with time—possibly because of collagen remodeling. Extensive research on corneal thermal injuries has shown that heat-induced collagen shrinkage occurs at 55° C to 60° C, and collagen fiber length may shrink by as much as two-thirds. During wound remodeling, new collagen formation occurs in the dermis of resurfaced skin and alters elastin fibers in the papillary dermis.[10]

ACKNOWLEDGMENTS

Deep gratitude to David Larson, MD, Professor and Chairman of the Department of Plastic and Reconstructive Surgery at the Medical College of Wisconsin, Chief of Staff at Froedtert Hospital in Milwaukee, WI for his guidance in the preparation of this article and continuous professional support . Special thanks to Margaret Hall, RN, CPRSN, Shirley Chartier, RN, and Kathryn Scroeter, RN, MS, CNOR of Surgery at Froedtert Hospital.

REFERENCES

1. Kotler R. *Chemical Rejuvenation of the Face*. 1st ed. St Louis, Mo: Mosby Year-Book; 1992:2-33.
2. Bolognia J. Dermatologic and cosmetic concerns of the older woman. *Clin Geriatric Med*. 1993;9:209-211.
3. Roenigk H. Treatment of the aging face. *Cosmetic Derm*. 1995;13:245-261.
4. Ryan F, La Fourcade C. Skin care, chemical face peeling, and skin rejuvenation. *Plastic Surg Nurs*. 1995;15:167-171
5. Orentreich N, Orentreich D. Dermabrasion. *Dermatol Clin*. 1995;13:313-327.
6. Fulton JE. Dermabrasion, chemabrasion, and laserbrasion. *Dermatol Surg*. 1996;22:619.
7. Benedetto A, Benedetto E, Griffin T, et al. Dermabrasion: Therapy and prophylaxis of the photoaged face. *J Am Acad Dermatol*. 1992;27:439-447.
8. Rosenberg G, Gregory R. Lasers in aesthetic surgery. *Clin Plastic Surg*. 1996;23:29-48.
9. Clark J. Presented at the Medical Laser Training Seminar for Health Care Workers. Pewaukee, Wis: Waukesha County Technical College; 1992.
10. Dover J. CO_2 laser resurfacing: Why all the fuss? *Plastic Reconstr Surg*. 1996;98:506-509.
11. Fitzpatrick R, Goldman M, Satur N, et al. Pulsed carbon dioxide laser resurfacing of photoaged facial skin. *Arch Dermatol*. 1996;132:1025-1029.
12. Lowe N, Lask G, Griffin M. Skin Resurfacing with the Ultrapulse Carbon Dioxide Laser. *Dermatol Surg*. 1995;21:1025-1029.
13. Cotton J, Hood A, Gonin R, et al. Histologic evaluation of preauricular and postauricular human skin after high-energy, short-pulse carbon dioxide laser. *Arch Dermatol*. 1996;132:425-428.

Linda O'Connor, CST, is employed at the Medical College of Wisconsin. She has been a surgical technologist since 1982 and a CST for 13 years. She has served as Chapter 17 president, Wisconsin representative, and treasurer for AST Region 5. Currently, she represents Region 5 on the Bylaws Committee and serves as chairperson of the Bylaws Committee; is a member of the Wisconsin state assembly board of directors, and president-elect of Chapter 17. She is a PEAK Award for Advanced Generalist recipient; has received the 1995 Outstanding Achievement in Public Relations Award, third place in the 1996 AST Writer's Award and first place in the 1997 AST Writer's Award for this article. ▲