CHOLECYSTECTOMY: A SURGICAL PERSPECTIVE

ARTICLE BY CRAIG W. MORRISON, MD; DEMETRIOS E. KEPAS, MD;
RICHARD E. WILLS, MD; AND PEGGY E. GRUSENDORF, MS, RNP

An estimated 8% to 10% of the United States population harbors gallstones. The prevalence increases with age, making gallstones and their sequelae a significant health problem for persons over the age of 40. Gallstones may be asymptomatic even when present. On the other hand, they may cause episodes of pain due to temporary blockage of the gallbladder outlet or the cystic duct as well as from contraction of the gallbladder against the obstruction of the stone itself. When this happens, proper diagnosis and surgical treatment may be required for relief of symptoms.

A knowledge of surgical anatomy and physiology of the gallbladder and its functional units will help the surgical technologist in his/her understanding of the various types of surgical approaches to the treatment of gallbladder diseases.

Anatomy

The gallbladder is a pear-shaped, tubular organ 6 to 10 cm in length and 5 cm in diameter with a filling capacity of about 45 ml. It is located in the right upper quadrant at the angle between the costal margin and the rectus abdominis muscle. It also is located between the right and quadrate lobes of the liver and lies in a fossa on the ventral surface of the liver. While in this location, it may be embedded within the liver parenchyma or adhered to the liver by peritoneum. It also can be surrounded by peritoneum or have a short mesentery to the inferior surface of the liver. While rare, the gallbladder may have a complete peritoneal covering. If this covering is present, it can lead to tissue infarction with necrosis by the way of torsion. With the presence of less or no peritoneum attached to the gallbladder, surgical excision is made easier. The gallbladder is close to the superior duodenum and transverse colon and anteriorly may be adhered to either of these.

The gallbladder is divided into three parts: the fundus, the body, and the neck. The neck may contain a pendulous pouch, which is referred to as Hartmann's pouch. During surgery, the surgeon puts traction on Hartmann's pouch, causing the cystic duct to stand out. The arterial blood supply to the gallbladder arises off the cystic artery, which is a branch of the right hepatic artery (Figure 1). The cystic duct runs between the layers of the lesser omentum, usually parallel to the common hepatic duct, before joining it just below the porta hepatis. The mucous membrane of the cystic duct is thrown into a spiral fold (of Heister) with a core of smooth muscle. The fold is continuous with a similar one in the neck of the gallbladder and coils along the cystic duct, giving it the tortuous appearance of a spiral valve.

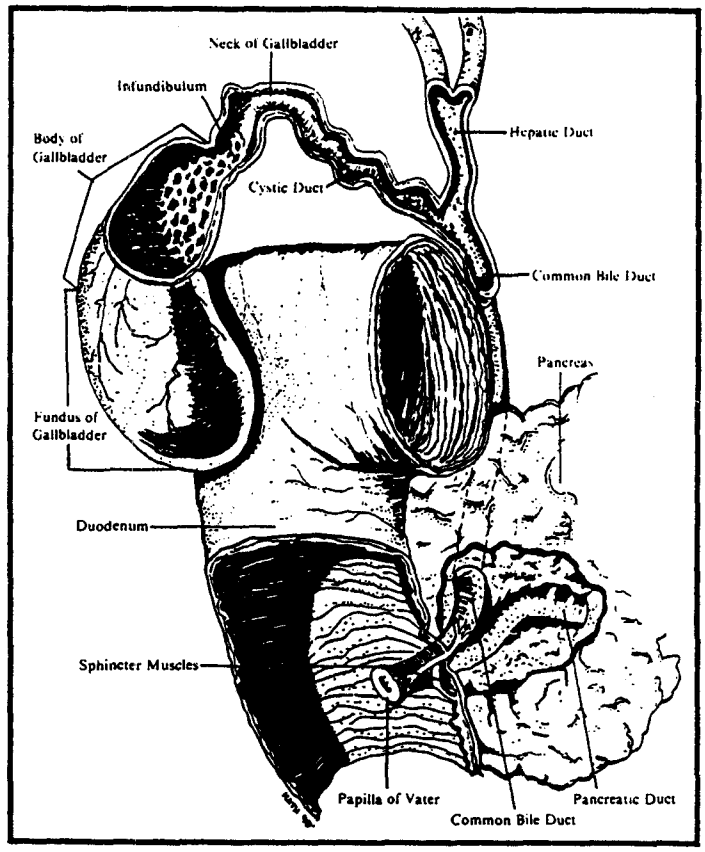

Figure 1. The anatomy of the gallbladder.

The spiral fold keeps the cystic duct constantly open so bile can pass into the gallbladder when the bile duct is closed by the choledochal sphincter or the hepatopancreatic sphincter. Also, bile can pass in the opposite direction into the duodenum when the gallbladder contracts by the hormone cholecystokinin (CCK) and vagal stimulation.

Physiology

The function of the gallbladder is to store and concentrate bile by mucosal absorption of electrolytes and water. Bile consists of electrolytes, bile salts, proteins, cholesterol, fats, and bile pigments. The color of bile secreted by the liver is related to the presence of the pigment bilirubin diglucuronide, which is a product of hemoglobin and is secreted into bile in high concentrations greater than those in plasma.

As a spurt of fat passes through the pylorus into the duodenum, it causes the release of CCK by the intestinal glands in the duodenum. CCK induces contraction of the

Craig W. Morrison, MD, general surgery, and **Demetrios E. Kepas, MD,** anatomic pathology, are with Utah Valley Regional Medical Center in Provo, Utah. **Richard E. Wills, MD,** medical director, and **Peggy E. Grusendorf, MS, RNP,** president, are with Intermountain Medical Research in Orem, Utah. Kathryn Muirhead, Provo, Utah, provided the medical illustrations.

gallbladder musculature, causing the fundus to rise and the body to narrow, thus resulting in increased pressure over the sphincters of the lower biliary tree. A normal adult with an intact hepatic circulation will secrete 500 to 1,200 ml of bile per day from the hepatic cells into the portal sinuses. The secretion of bile is responsive to neurogenic, hemoral, and chemical control. Vagal stimulation will increase secretion, whereas splanchnic nerve stimulation will result in decreased secretion.

The gallbladder's ability to concentrate bile forms the basis for radiographic visualization of the organ (cholangiography). When radiopaque compounds are administered, either orally or intravenously, they are sequestered and excreted by the liver. The radiopaque dye in the bile is concentrated in the gallbladder so that the entire organ becomes radiopaque.

Biliary Tract Disease

The diseases of the biliary system can be divided into (1) inflammatory disease (cholecystitis), (2) gallstones (cholelithiasis), and (3) neoplastic diseases. The first two categories will be discussed here.

Cholecystitis

Acute cholecystitis begins with colicky pain, localizing to the right upper quadrant and often radiating around to the right lower scapula. Nausea and vomiting are common. Within a few hours, involuntary guarding of the right side abdominal muscles occurs, without rebound tenderness at first. The gallbladder may become palpable in the right upper quadrant. Fever is low grade at first and neutrophilic leukocytosis is modest. The acute episode usually improves in 2 to 3 days and resolves within a week; failure for it to do so suggests serious complications. High fever, leukocytosis, and rigors along with findings of rebound tenderness or ileus suggest empyema, gangrene, or perforation. Each of these requires urgent surgical management. When jaundice or cholestasis is present, suspect a partial common duct obstruction by calculi or contiguous inflammation.

Acute pancreatitis may also complicate acute cholecystitis. The combination carries great risk.

Clinically suspected acute cholecystitis is most accurately confirmed by hepatobiliary scintigraphy and ultrasound. The usage of iminodiacetic acid compounds labeled with technetium 99m are rapidly taken up and excreted by the normal liver. Through use of isotope scanning techniques, the liver, extrahepatic bile ducts, gallbladder, and duodenum are sequentially visualized.

Real-time ultrasonography is valuable for confirming the presence of cholelithiasis through demonstration of gallbladder wall thickening when present.

Inflammation of the gallbladder may be acute chronic, acute superimposed, or chronic. Cholecystitis is one of the most common indications for abdominal surgery. Gallstones are present in 80% to 90% of all patients with cholecystitis (Figure 2).



Figure 2. Gross pathology of a gallbladder with gallstones.

With cholecystitis, bacteria can be cultured from about 80% of all acutely inflamed gallbladders. The most common offenders are *Escherichia coli*, enterococci, and salmonellae.

Acute cholecystitis usually presents as an enlarged, tense, edematous, fiery red gallbladder. The gallbladder is often covered with a fibrosuppurative exudate. Chronic cholecystitis presents as an enlarged gallbladder, but the wall is variably thickened, gray-white, and tough.

Cholelithiasis

Within the United States, gallstones occur in 8% of men and 20% of women over 40 years of age. The four "F's" —fat, female, fertile (multiparas), and forty — characterize the population with the highest incidence. Beside these factors, other instances of ethnic, and possibly genetic, predispositions to gallstones are being evaluated. Obesity also increases the cholesterol content of bile. The high incidence of gallstones in obese individuals is due to the increased calorie intake, which includes simple sugars, as well as the impaired gallbladder emptying secondary to physical pressure within the abdominal cavity. (This also occurs in pregnancy.) These situations favor lithogenesis, presumably allowing gallstone growth.

In descending order of common use, the following tests are used to diagnose gallstones:

1. Plain abdominal X-ray films (15% accuracy)
2. Ultrasonography (95% accuracy)
3. Oral cholecystography (largely replaced by ultrasound) (Figure 3)
4. Percutaneous transhepatic cholangiography
5. HIDA scans (radionuclide imaging of biliary tree)
6. Endoscopic retrograde cholangiopancreatogram (ERCP)

Cholecystectomy

Actual removal of the gallbladder is indicated in the treatment of diseases of the gallbladder, including acute or chronic inflammation with or without cholelithiasis as well as with the presence of polyps or carcinoma.

The setup and preparation of the patient is similar to setup and preparation for other abdominal surgeries.

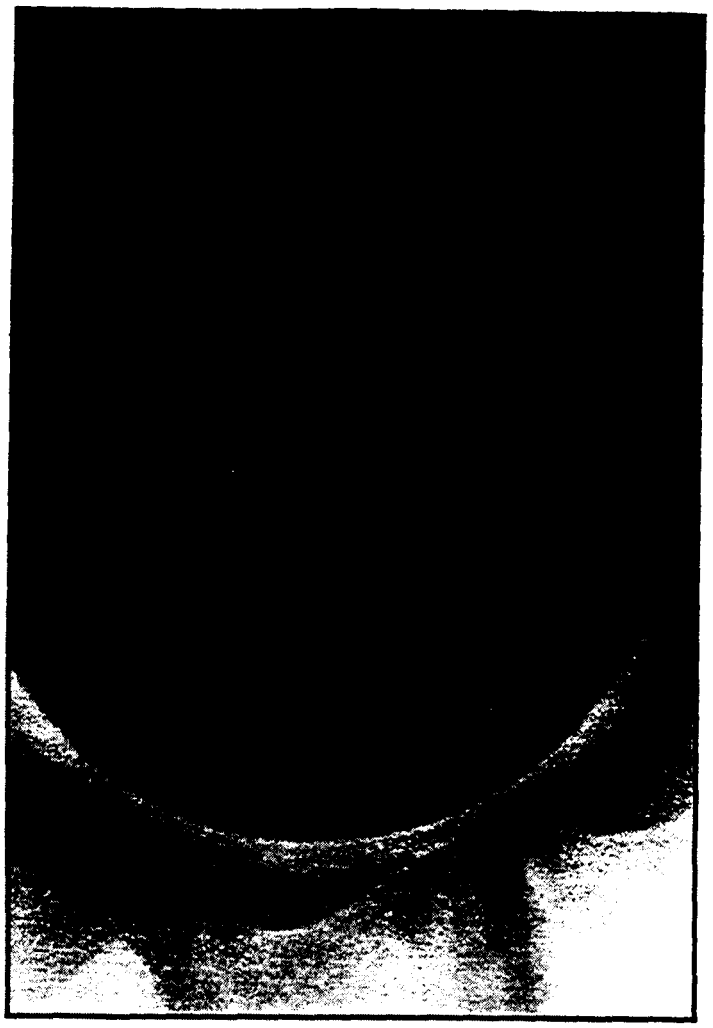

Figure 3. An oral cholecystography showing the gallbladder with no stones present. The gallbladder is normal.



Figure 4. X-ray film of an operative cholangiography showing no filling defects and a free flow of contrast medium into the duodenum and common bile duct.

Operative Procedure

The operative procedure begins with a right subcostal or right paramedian incision. The abdominal cavity is then opened layer by layer using the normal surgical approach. The use of Kelly retractors and laparotomy packs is necessary to complete a careful examination of the abdominal cavity.

Deaver retractors, moist or dry laparotomy packs, long tissue forceps, and suction are used in palpating the common duct for evidence of stones and determining the pathologic condition of the organ. Laparotomy packs and deep retractors are utilized to wall off surrounding organs from the gallbladder region. Rochester-Pean forceps are usually placed on the body of the gallbladder to facilitate gentle traction.

Using either a long no. 7 knife handle with a no. 15 blade or a no. 4 handle with a no. 20 blade, long Metzenbaum scissors, and forceps, the peritoneal fold overlying the junction of the cystic and common ducts is incised. Suction should always be available with bleeding points being clamped and ligated.

Small, round, dry dissector sponges, sponges on holders, and blunt right-angled forceps are utilized in separating the adhesions by blunt dissection. Dissection is continued until the neck of the gallbladder, the cystic duct, and the cystic artery as it enters the wall of the gallbladder are exposed. Upon complete exposure and visualization of the branches, the cystic artery is doubly ligated with silk or clamped with hemostatic clips and divided. On some occasions, a third ligature or clip may be used. If there is more than one branch of the cystic artery, each one is ligated and divided separately.

After the true junction of the cystic duct with the common bile duct is visualized, the cystic duct is identified and carefully dissected from the common bile duct to the gallbladder neck and doubly ligated and divided (Figure 4). Fine chromic gut may be used as a transfixion suture on the stump of the cystic duct near the common bile duct. Working upward to the fundus, the gallbladder is freed from the liver and then removed. In some cases, it may be necessary to work downward to the neck of the gallbladder.

Bleeding is controlled with reperitonealization of the liver bed by using interrupted or continuous fine chromic intestinal sutures. A Penrose drain is inserted near the cystic duct stump with the free end of the drain being exteriorized through a stab wound in the lateral abdominal wall.

The wound is then closed in layers using the surgeon's specific type of suture material. A safety pin is attached to the protruding drain and a dressing is applied to cover the incision area as well as the stab wound with drain.

Choledochostomy/Choledochotomy

Choledochostomy is the establishment of an opening into the common bile duct by means of a drainage T tube, while a choledochotomy is an incision into the common bile duct for removal of stones.

When relieving an obstruction in the common bile duct, a choledochotomy is performed. Before exploration is begun, open cholangiography may be performed as a means of locating all stones within the ductal system. X-ray films are repeated after placement of the T tube drain to confirm successful evacuation and patency of the ducts.

Operative Procedure

This procedure begins by opening the abdomen as for a cholecystectomy. If the gallbladder has not been removed previously, it is now exposed and removed or retracted with laparotomy packs and retractors.

The common duct may be identified by means of an aspirating syringe and fine-gauged needle to make certain the suspected duct is not a blood vessel. At this point a specimen or culture may be obtained.

Two fine traction sutures are placed in the wall of the duct below the entrance of the cystic duct.

Laparotomy packs and narrow blade retractors are used to wall off the common duct region. A discard basin is placed at the lower end of the operative field and is used for contaminated instruments. A suction apparatus is available for immediate use.

A long no. 3 handle with a no. 15 or no. 11 blade is utilized to make a longitudinal incision in the common duct between the traction sutures. A Yankauer suction tube is used to maintain constant suction to keep the field free of oozing bile as the incision is enlarged with a Potts angled and Metzenbaum scissors. Additional stay sutures may be applied to the ductal opening.

Visible stones are removed with gallstone forceps. Exploration of the duct is conducted with small malleable scoops proximally and then distally to the opening. As stones are being removed from both the common and hepatic ducts, probing continues. Isotonic saline solution in a bulb syringe and a small-lumen catheter or a Fogarty-type, balloon-tipped catheter is used to facilitate removal of small stones as well as debris. This practice also aids in demonstrating patency through the duodenum.

If the patency of the sphincter of Oddi and ampulla of Vater cannot be demonstrated, a duodenotomy may be performed. For this procedure, an area of the duodenum is walled off with laparotomy packs and an incision is made longitudinally with a scalpel, using a no. 15 blade or Metzenbaum scissors.

Any bleeding vessels are clamped with mosquito hemostats and ligated with fine silk or chromic sutures or electrocoagulated. Exploration is carried out after the placement of fine silk traction sutures.

The duodenal opening is usually closed in two layers transversely with fine chromic and silk intestinal sutures.

After taking care of the duodenum as necessary, the surgeon prepares the T tube by irrigating it to check for patency before it is introduced into the common duct with fine vascular forceps.

The common duct incision is closed with fine chromic intestinal sutures. All contaminated instruments are placed in the discard basin.

The patency of the T tube again is demonstrated through irrigation, and a cholangiogram is performed. At this point, the gallbladder may be removed as outlined in the procedure for a cholecystectomy.

A Penrose, Jackson-Pratt, or cigarette drain is inserted into the foramen of Winslow with both drain and tube being exteriorized through a stab wound. The wound is then closed in layers with the tube and drain being carefully anchored to the skin. Each wound is dressed individually to prevent undue tension that could result in displacement of tube or drain.

The T tube is then connected to a small drainage container with sterile tubing.

Postoperative Management

Analgesics. Papaveretum (Omnopon), 10 to 20 mg hourly, may be given as required. Morphine sulfate tends to produce spasm of the sphincter of Oddi. The addition of an antispasmodic drug such as atropine or Buscopan should be considered.

Antibiotics. Preoperatively, antibiotics may be prescribed if the bile is suspected of being infected. Postoperatively, treatment can be discontinued if the bile has been shown to be sterile.

Intravenous Fluids. Five percent dextrose and 0.9 percent saline are given as indicated by routine assessment of fluid and electrolyte balance.

Intragastric Drainage. Intragastric drainage is not required as a routine procedure unless indicated by signs of gastric hold up, nausea, vomiting, hiccups, distension, or shoulder-tip pain. This occurs in about 10% of patients. Exceptions are in patients who required duodenotomy or additional gastric surgery.

Physiotherapy. Physiotherapy is essential to encourage respiration and to keep the limbs mobile.

Prognosis

The overall death rate of acute cholecystitis is about 0.5%. Nearly all deaths occur in patients over age 60 and those with diabetes mellitus. With older patients, secondary complications from cardiovascular and pulmonary entities substantially contribute to the mortality rate. Uncontrolled sepsis with peritonitis and intrahepatic abscesses are notable causes of death within patients.

Acute pancreatitis may also complicate acute cholecystitis. The combination carries greater risk. Patients who develop the suppurative forms of gallbladder disease such as empyema or perforation are less likely to recover. Earlier admission to the hospital and prompt cholecystectomy reduce the chances of these complications. □

Bibliography

Anthony CP: *Textbook of Anatomy and Physiology,* ed 11. St Louis, 1983, CV Mosby Co.

Guyton AC: *Textbook of Medical Physiology,* ed 4. Philadelphia, 1981, WB Saunders Co.

Lehninger AL: *Biochemistry,* ed 6. New York, 1975, Worth Publishers.

Robbins SL: *Pathologic Basis of Disease,* ed 3. Philadelphia, 1984, WB Saunders Co.

Schwartz SI: *Principles of Surgery,* ed 4. New York, 1984, McGraw-Hill Book Co.

Sleisenger MH, Fordtran JS: *Gastrointestinal Disease,* ed 3. Philadelphia, 1983, WB Saunders Co.

Sodeman WA, Sodeman TM: *Pathologic Physiology Mechanisms of Disease,* ed 6. Philadelphia, 1979, WB Saunders Co.