Endoscopic Inguinal Herniorrhaphy

Transabdominal, Preperitoneal Approach

ARTICLE BY TERI JUNGE, CST/CFA

Recently, there has been an explosion in endoscopic surgery. This article will focus on inguinal herniorrhaphy. Of the two methods available, preperitoneal and intraperitoneal, the preperitoneal approach will be discussed here and may be used to repair either a direct or an indirect hernia. The examples and photographs provided in this article refer to right direct inguinal hernia.

Advantages and Indications

Approximately 500,000 American men undergo herniorrhaphy each year. It is estimated that 1 in 20 males will at some time develop an inguinal hernia.[1] When endoscopic herniorrhaphy was first described in 1990, it was an extremely difficult and technically challenging procedure.[2] As is true with all new procedures, surgeons are increasingly proficient at all types of endoscopic procedures as their experience increases, and the equipment has improved dramatically. Several techniques are being perfected, and the number of endoscopic hernia repairs is increasing.[2]

At this point in the development of endoscopic herniorrhaphy, it does not appear to offer a decrease in the length of the procedure as compared with the traditional anterior approach; however, the advantages of endoscopic herniorrhaphy are clear. Hospitalization is limited to an outpatient procedure, pain and suffering are diminished, risk of damage to the cord structures and ilioinguinal and genitofemoral nerves are reduced, and the patient returns to full activity very quickly. Endoscopic herniorrhaphy is usually performed on active, young adults.[1]

This type of surgery would be contraindicated if the hernia is incarcerated (not reducible), if the patient has had previous lower abdominal surgery, or if the patient would not be able to tolerate a general anesthetic or pneumoperitoneum due to other medical problems.

Instrumentation, Equipment, and Operating Room Setup

The instruments and supplies necessary for endoscopic herniorrhaphy are listed in Table 1, although some variations may occur depending on specific hospital procedures. Reuseable or disposable trocars and instru-

Table 1. Instruments and Supplies

Sterile Supplies
- Basic laparotomy pack with drapes
- #3 knife handle with #11 blade
- Curved criles (4)
- 4 nonpiercing drape clamps
- Curved and straight Mayo scissors
- 5" pickups with teeth
- Adson forceps with teeth (2)
- 6" needle holders (2)
- Army-Navy retractors (2)
- Mechanical camera holder (optional)
- Insufflation tubing
- Latex tubing (2)
- Transfer device
- Control syringe with 25-gauge 2" needle
- 0.5% bupivacaine with epinephrine (or surgeon's preference)
- Hand control cautery cord with holster and cleaner
- Unipolar cautery cord for endoscopic instruments
- Light handles (2)
- Telescopes: 0° (5 mm and 10 mm), 30 ° (10 mm), and 45° (10 mm)
- Warm water to soak lenses (helps prevent fogging)
- Camera
- Light cord
- 10-mm blunt tip (Hasson) infraumbilical cannula
- 12-mm trocar (with grips, if desired) (2)
- 5.5-mm reducers (2)
- Endoscopic needle holder
- Endoscopic irrigation/aspiration cannula
- Endoscopic grasper
- Endoscopic dissector with unipolar cautery
- Endoscopic scissors with unipolar cautery
- Endoscopic hernia stapler (reloadable, with refills)
- Fog reduction fluid
- Prep set
- Foley catheter with urimeter (optional)
- Polypropylene tissue patch (2½" x 4½")

Equipment
- Variable intensity light source
- High-flow insufflation unit
- Camera unit
- Video recorder with video tape
- High-resolution video monitors (2) (1 optional)
- 1,000-mL bag of lactated Ringer's solution (body temperature) with 5000 U of heparin (or surgeon's preference) added
- Pressure bag for lactated Ringer's
- Electrosurgery unit

Sutures
- 0 polypropylene control release (to secure infraumbilical cannula)
- 3-0 chromic gastrointestinal (to close peritoneum)
- 2-0 coated multifilament polyglactin 910 CT-1 (to close fascia)
- 3-0 coated multifilament polyglactin 910 PC-5 (2) or staples (for skin)

Dressings
- Tincture of benzoin (2 ampules)
- ½" steri-strips
- Extra-large plastic bandages (3)

ments may be used.

The operating room is set up for right endoscopic herniorrhaphy as in Figure 1. The surgeon stands on the patient's side, contralateral to the defect. While it is not necessary to have two video monitors, having two units is more comfortable for the surgeon and the first assistant. If only one monitor is used, it should be placed directly at the foot of the table.

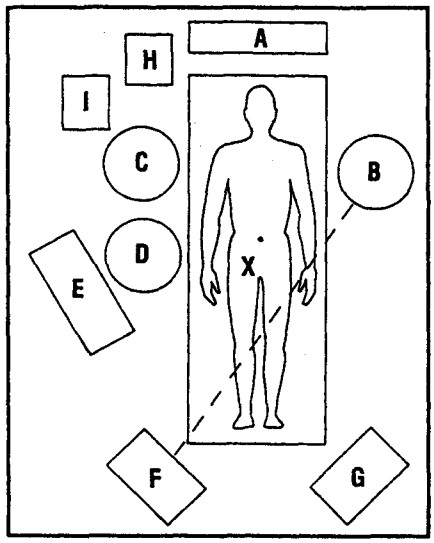

Figure 1. Operating room setup. **A,** Anesthesia; **B,** Surgeon (contralateral side); **C,** Surgical first assistant (camera holder); **D,** Surgical technologist in scrub role; **E,** Sterile instrument table; **F,** Primary video unit; **G,** Secondary video unit (optional); **H,** Electrosurgery unit; **I,** Insufflation unit; and **X,** Right inguinal hernia site.

Patient Preparation

The patient is placed on the operating table in the supine position with both arms positioned at the patient's sides. A general anesthetic is administered. Use of a nasogastric tube and Foley catheter are optional. If a Foley catheter is not used, the patient *must* void immediately prior to the start of the procedure. The skin prep includes the abdomen, genital region, and upper thighs, and the patient is draped to reveal the same. This allows for the application of external abdominal counterpressure during the procedure or the possibility of having to open the abdomen or to convert to an open herniorrhaphy. The patient is then placed in Trendelenburg's position at a 15°- to 30°-angle to displace the intestine from the pelvis for better visualization.[3]

Endoscopic Access

Prior to making the three small incisions (Figure 2) for endoscopic access, the surgeon may inject a long-acting local anesthetic containing epinephrine to facilitate postoperative pain control and to minimize bleeding at the trocar sites.

A 10-mm infraumbilical (vertical) incision is made sharply through the skin. The dissection is bluntly carried down through the subcutaneous tissue exposing the fascia. Retention/retraction sutures of 0 polypropylene are placed laterally in the fascia, which is then incised. The rectus muscle is separated bluntly, the peritoneum is opened under direct visualization, and a 10-mm blunt tip infraumbilical (Hasson) cannula is inserted.[3] The stay sutures are secured around the infraumbilical cannula to hold it in place. The insufflator is connected and carbon dioxide is introduced at 10 L/min to a maximum intraperitoneal pressure of 15 mm Hg. The lighted lens with camera attached is inserted inside the abdomen to inspect for any unusual findings and to ensure that the herniorrhaphy can be performed. The lens with camera will be the main port for visualization throughout the procedure.

Under direct visualization with the camera, two additional trocars are placed inside the right and left midabdomen, lateral to the rectus sheath, at or slightly below the level of the umbilicus. The trocar contralateral to the hernia *must* be 12 mm to accommodate the hernia stapling device. A 5-mm trocar may be used on the ipsilateral side, although a 12-mm trocar is much more versatile, especially if bilateral herniorrhaphy is to be performed. The two secondary trocars or ports are referred to as the working cannulas.

If available, the mechanical camera holder may now be attached. Care should be taken not to damage the camera, light cord, or lens. A piece of latex (cut from the irrigation/aspiration tubing) may be placed over the camera or lens, where the holder is attached, to help prevent damage from crimping and slippage. The camera holder is very useful in helping to provide a clear, still video picture.



Figure 2. Cannula placement. **A,** Infraumbilical cannula 10-mm blunt; **B,** Right (ipsilateral) cannula 12-mm trocar; **C,** Left (contralateral) cannula 12-mm trocar; and **D,** Mechanical camera holder.

Figure 3. Hernia defect peritoneum intact. **A,** Direct hernia site; **B,** Medial umbilical ligament; **C,** Inferior epigastric vein and artery; **D,** Spermatic vessels; **E,** Vas deferens; and **F,** External iliac vein and artery.

Abdominal Inguinal Anatomy

Viewing the inguinal anatomy from inside the abdomen is quite a contrast from the usual anterior approach (Figures 3 and 4). The key landmarks include the following: the medial umbilical ligament, the inferior epigastric vessels, the spermatic vessels, and the vas deferens. The external iliac vein and artery, Cooper's ligament, and the hernia are also visible.[4]

The right direct inguinal hernia will be located medial to the medial umbilical ligament while the right indirect inguinal hernia will be located lateral to the inferior epigastric vessels.[2]

It is important to note the close proximity of the large vessels and cord structures to the hernia. Great care must be taken to avoid injury to these vessels and structures when dissecting, stapling, or suturing.[1]

Surgical Procedure

The right inguinal hernia and surrounding structures are carefully identified. The use of a 30°- or 45°-lens may provide better visualization. The intestine is displaced from the pelvis with the use of Trendelenburg's position. Any adhesions that obstruct the view of the hernia site will be dissected and the intestine retracted. Gravity in combination with the pneumoperitoneum is all that is usually necessary to provide adequate exposure. A sharp incision is made in the peritoneum on the right side, using a grasper for countertraction and scissors with a cautery attached. The incision extends from the lateral edge of the internal ring to the posterior rectus muscle. The anterior and posterior flaps of this incision are developed and retracted to reveal the underlying anatomy.[2]

Figure 5. Hernia defect peritoneum dissected. **A,** Anterior peritoneal flap and **B,** Posterior peritoneal flap.

Using extreme caution, blunt dissection is used to identify the cord structures, the margins of the hernia, and the inguinal canal (Figure 5).

A prosthesis of polypropylene mesh is inserted to reinforce the wall of the inguinal canal and facilitate scar formation.[4] The surgeon determines the appropriate size mesh to be used and cuts the available piece to size. The mesh is rolled (cigarette fashion), inserted through one of the 12-mm ports, and pulled into the peritoneal cavity with a grasper. The mesh is unrolled and positioned under the peritoneal flaps, completely covering the direct and indirect space. The mesh is anchored to the underlying fascia (into the rectus muscle, next to the femoral vein, along the iliopubic tract, and adjacent to Cooper's ligament) on all sides with the titanium hernia staples (Figure 6). External counterpressure may be used to ensure the staples are well seated in the tissue. *Extreme* caution must be used to protect the vital structures situated nearby.[2]

Using 3-0 chromic sutures, the peritoneal flaps are closed.[2] The suture is shortened to approximately one-third its original length for easy handling inside the abdomen. A running stitch is used and is tied intracorporeally (Figure 7). The intra-

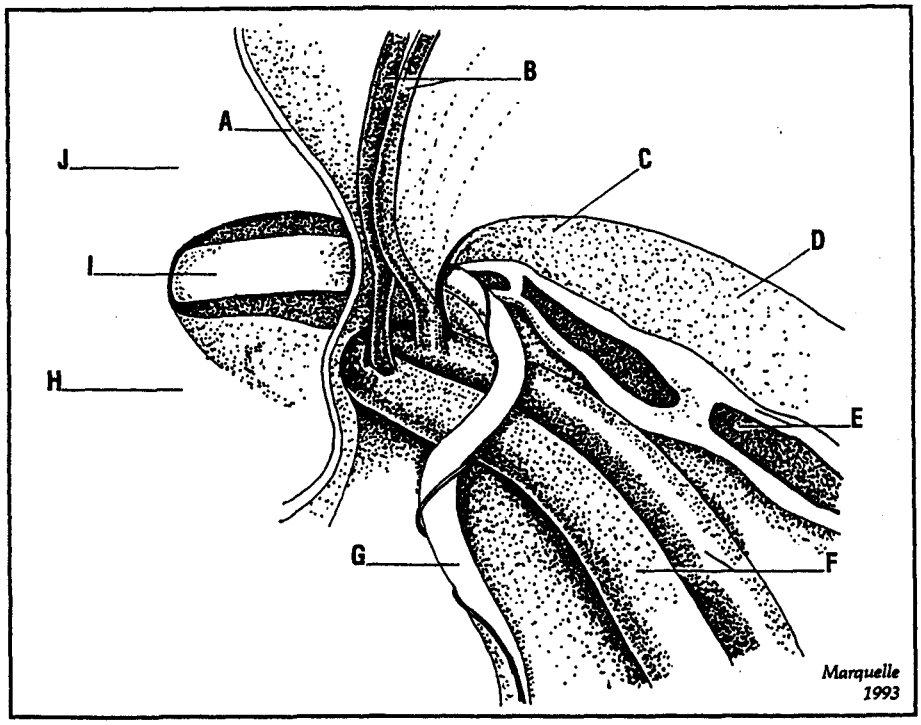

Figure 4. Pelvic anatomy; right inguinal region. **A,** Medial umbilical ligament; **B,** Inferior epigastric vein and artery; **C,** Internal inguinal ring; **D,** Indirect hernia; **E,** Spermatic vessels; **F,** External iliac vein and artery; **G,** Vas deferens; **H,** Cooper's ligament; **I,** Spermatic cord; and **J,** Direct hernia.

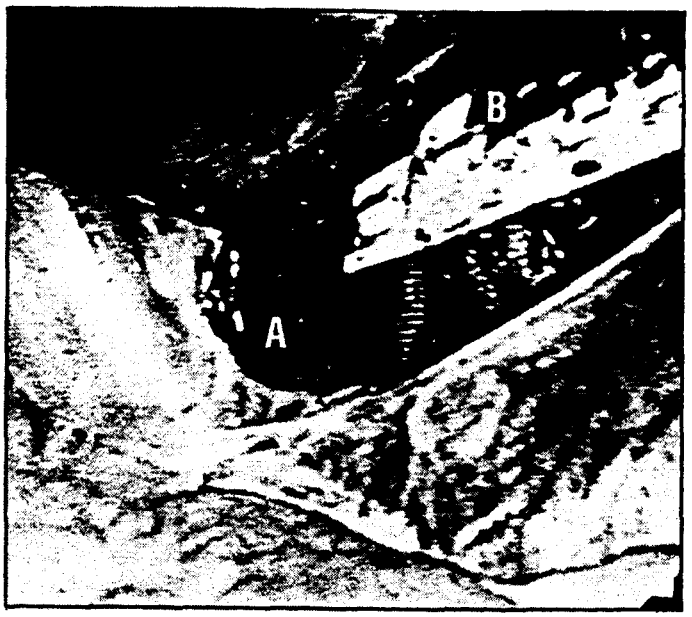

Figure 6. Prosthesis placement. **A,** Polypropylene mesh and **B,** Endoscopic hernia stapler.

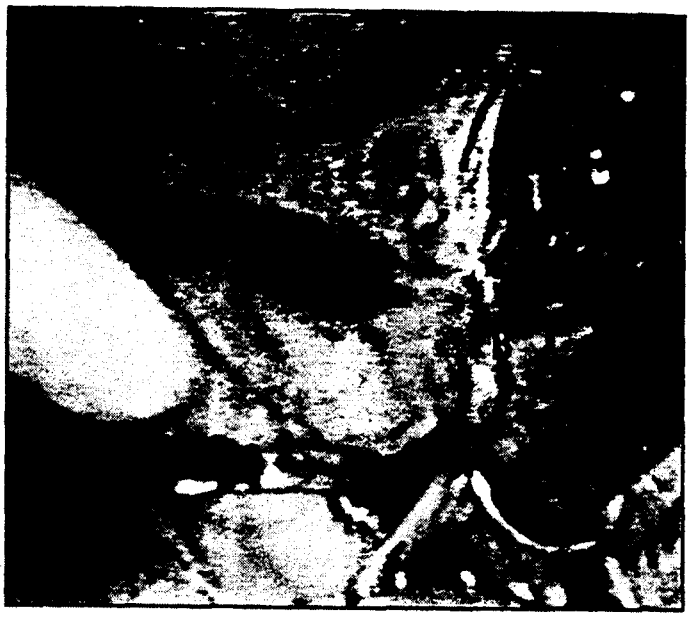

Figure 7. Closing of the peritoneal flap. **A,** 3-0 chromic suture and **B,** Running suture line.

abdominal pressure may be reduced slightly to allow the flap edges to come together. Covering the mesh helps reduce the possibility of adhesion formation.

If bilateral herniorrhaphy is to be performed, attention is now turned to the opposite side. The surgeon and first assistant move to the opposite sides of the table and repeat the procedure previously described.

A final inspection of the operative site is performed, the abdomen is decompressed by releasing the CO_2, and the ports are removed. The puncture wounds are closed with interrupted 2-0 uncoated monofilament polyglactin 910 sutures in the fascial tissue and 3-0 uncoated monofilament polyglactin 910 sutures in the subcutaneous and subcuticular tissue.

Tincture of benzoin, steri-strips, and sterile dressings are applied.

Postoperative Care

The patient is taken to the postanesthesia care unit and discharged to go home once fully awake , usually within 4 to 6 hours. An oral pain medication is prescribed for any mild discomfort at the puncture sites. The surgeon will see the patient 1 week postoperatively for a follow-up. The patient may return to normal activities as desired and is generally able to return to work in 1 week.[3]

Very few postoperative complications have been observed. The most common complication is abdominal distention, which diminishes very quickly.[1]

Researchers are currently conducting long-term studies the results of which are optimistically awaited. However, the results of preliminary studies have been positive and show very low recurrence rates. The endoscopic approach seems to be the most modern, least invasive way to manage inguinal hernias.[4] Δ

Acknowledgements

The author wishes to extend her appreciation to T. Velky, MD, and M. Savin, MD, for their assistance with this article. Thanks also to Dorothy Farrow for her encouragement, to Donna Dorlaque, CST, for her photographic skills, to Kriss Miller, CST, for her moral support and technical guidance, to Marquelle Hudson, CST, for her artistic ability, to Jerry Huber and Kevin Weisenstein for providing terrific resource material, and especially to my family for tolerating me during this effort.

References

1. Klein SR, Velez M, Davis IP. *Endoscopic Hernia Repair.* United States Surgical Corporation. 1992.
2. Fitzgibbons RJ, Jr, McKernan JB, Schultz LS, Spaw AT. *Techniques in Endosurgery: Laparoscopic Hernia Repair.* Ethicon, Inc. END086.
3. McKernan JB, Laws HL. Laparoscopic preperitoneal prosthetic repair of inguinal hernias. *Surgical Rounds.* July 1992.
4. Stoppa RE, Warlaumont CR. The preperitoneal approach and prosthetic repair of groin hernia. *Hernia.* 3rd ed. JB Lippincott Co. 199-225.

Teri Junge, CST/CFA, has worked in surgery since 1975 and has been a CST since 1985. Teri has worked at Palomar Medical Center in Escondido, California, for the past 8 years. Palomar, a major trauma center with an 11-bed operating suite, has a very progressive endoscopic surgery program.