Liver Resection

ARTICLE BY DENIS SCANNELL, CST

Although the concept of liver resection was known by the Greeks, the first surgical removal of a portion of the liver was recorded in 1716 by Berta, who amputated the protruding portion of the liver in a patient with a self-inflicted knife wound. In 1890, Tiffany was the first American surgeon to report a case of hepatic resection for a tumor. He excised a walnut-sized mass from the convex surface of the left lobe, using scissors and cauterization.

The modern era of anatomic hepatic lobectomy dates from the 1952 report of Lortat-Jacob and Robert, who used a thoracoabdominal approach and a technique designed to control hemorrhage by guillotine technique.

Until a decade ago, relatively few technical advances had been made. Hepatic resections therefore remained very difficult and challenging operations because of the massive amounts of blood loss that occurred during the transection of the liver.

This article will focus on the recent changes and new advances in surgical technique of hepatic resection that have made this operation less complex and almost bloodless and, therefore, tolerated even by high-risk patients. The more commonly performed major lobectomies and segmentectomies will be considered. Right hepatic lobectomy will be described in detail, and the description of left hepatic lobectomy will be omitted, since all of the principles detailed for right lobectomy apply.

Surgical Anatomy

The liver is the largest gland in the body and is situated in the right upper quadrant of the abdominal cavity, occupying almost the entire right hypochondrium, the greater part of the epigastrium, and extending into the left hypochondrium. The superior surface, which contains the hepatic veins as they enter the inferior vena cava, is in direct contact with the diaphragm, while the anterior surface is closely related to the deep surface of the abdominal wall. The posterior surface of the liver overlays other major intra-abdominal and retroperitoneal structures. They include the gallbladder and common bile duct, right kidney, duodenum, and stomach. The major hepatic veins divide the liver into three relatively bloodless surgical "corridors" (Figure 1). A right or left hepatic lobectomy is performed by following the right or left side of the middle hepatic veins respectively, again providing relatively bloodless segmental corridors. The right hepatic vein divides the right lobe into an anterior and posterior segment (Figure 2). The left lobe, however, is anatomically divided by the umbilical fissure into a medial and lateral segment (see Figure 2). The left hepatic vein divides the left lateral

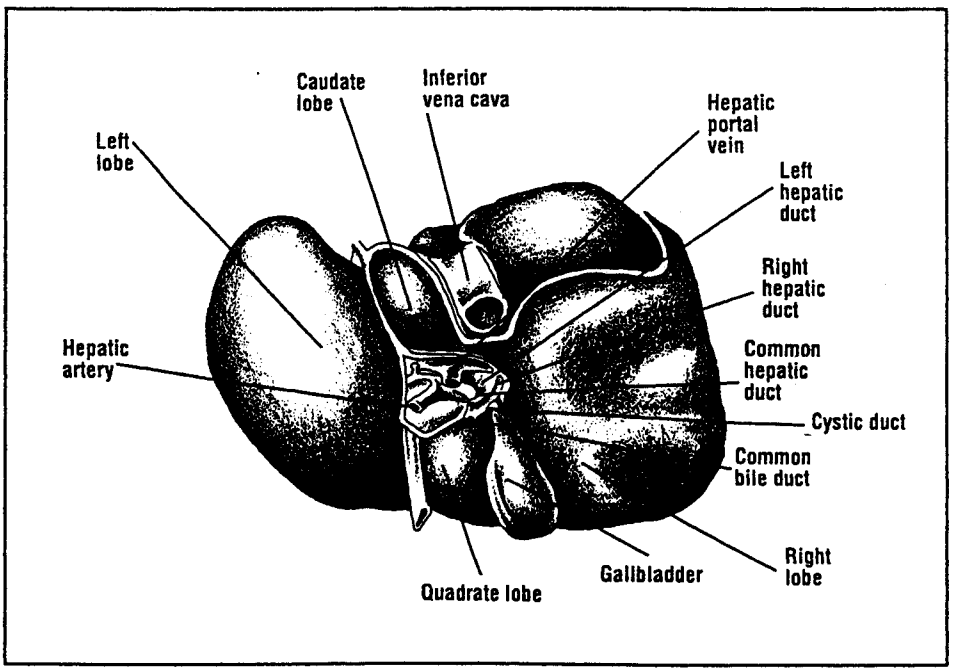

Figure 1. Inferior visceral surface of the liver. (Adapted from Tortora GJ, Grabowski SR. Principles of Anatomy and Physiology. 7th ed. New York, NY: HarperCollins College Publishers; 1993.)

segment into two subsegments, superior and inferior. Branches of the major hepatic veins further divide the parenchyma into eight subsegments, each of which can theoretically be removed while leaving the others intact. Each anatomic segment and subsegment is supplied by its own trinity structure (artery, portal vein, and bile duct). There is no collateral circulation between trinity structures.[1]

Patient Selection and Preoperative Preparation

The current indications for hepatic resection include the following: (1) trauma with resultant necrosis of hepatic tissue, (2) cysts, (3) granulomas, (4) primary neoplasms of the liver, and (5) secondary malignant tumors, which involve the liver either by direct extension or as metastatic lesions.[2] An essential feature of the preoperative protocol is angiography of both the celiac and the superior mesenteric arteries to define the extent of hepatic involvement and, thus, the resectability, and also to demonstrate the vascular anatomy and segmental supply. A venous phase to determine involvement of the portal vein should be included. Computerized axial tomography is the most accurate noninvasive diagnostic technique. Computed tomography performed while radiopaque medium is infused directly into the hepatic artery provides the best definition of intrahepatic pathology. Ultrasonography is useful in evaluating vena caval integrity.

Perioperative broad-spectrum antibiotics are administered. A central venous and two large-bore peripheral intravenous catheters are placed in the upper extremities. An arterial catheter may also be useful, particularly in the case of trisegmentectomy. A urinary catheter is left indwelling.

The most important preoperative serologic test is the clotting profile (partial thromboplastin time, prothrombin time, bleeding time).

The basic instruments and supplies required for biliary procedures should be available as well as supplies and equipment for hypothermia, electrosurgery, laser, ultrasonic dissection, measurement of portal pressure, thoracotomy drainage, and replacement of blood loss as well as special blunt needles for repair of liver tissue.[1] The following instruments are also needed:[1] manometer, 2 chest drainage catheters, 12-18 silk or chromic liver sutures, and hemostatic material (eg, Gelfoam).[1]

The surgical technologist in the scrub role should check the condition of all drainage materials and test them for patency before giving them to the surgeon.[1] During surgery, care must be taken to isolate contaminated instruments from the rest of the operative field.[1]

The patient is placed in the supine position. The surgeon may also prefer to have the right upper quadrant elevated to aid in exposure.[1] Proper alignment of the patient's body and extremities and padding for areas of pressure or bony prominence are important to prevent interruption to circulation and pressure injuries to tissue.[1]

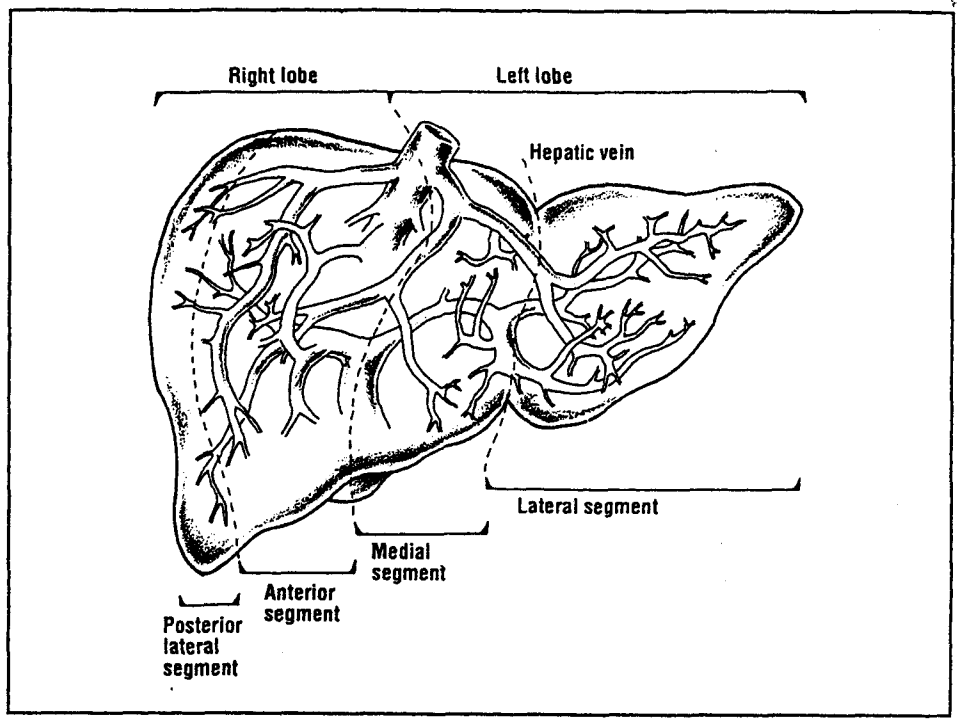

Figure 2. Anatomic division of liver showing intrahepatic distribution of hepatic and portal veins. (Adapted from Lilly JR, Stellin G.[3])

Intraoperative Management

In all major resections the xiphoid is excised. Extensions into the chest are optional but rarely necessary. Unless the thorax is open, deep anesthesia to avoid spontaneous respiratory efforts is mandatory during the cleavage phase of hepatic resection to prevent air embolism. During the operation, adequate blood flow to the part of the liver to be retained must be assured; otherwise, activation and release of fibrinolysin occurs, resulting in a hemorrhagic diathesis. Hemodynamic monitoring must be frequent; twisting of the inferior vena cava and impairment of blood return to the heart often occurs during hepatic mobilization. Blood loss should be replaced immediately and since banked blood does not contain several clotting factors (V and VII), fresh frozen plasma should be given periodically if blood loss is heavy.

Except for wedge resection, the first step of liver resection is division of the suspensory ligaments to the lobe or segment to be resected, and identification of the hepatic vein. The second step is the isolation and division of the portal hilar structures beginning with the hepatic artery, followed by the portal vein, and finally, the bile duct. An

ischemic (cyanotic) line of demarcation appears along the parenchyma, which is followed during the subsequent hepatic cleavage. The hepatic vein is isolated, clamped, and divided and the venous stumps are oversewn using vascular suture.[3]

The major intersegmental venous drainage is used as a guide during the hepatic cleavage and is spared. No devitalized tissue is left with the residual liver nor is the raw area covered with omentum or other tissue. Meticulous hemostasis of residual small vessels and ducts is accomplished with fine suture ligature. Adequate drainage of the residual dead space is essential. Recent developments in ultrasonic dissection and argon beam coagulation have allowed safer and more hemostatic technique of hepatic cleavage.[4,5]

Ultrasonic Dissection and Argon Beam Coagulation

Relatively new approaches to resection of multiple metastatic hepatic lesions of the liver include ultrasonic dissection and argon beam coagulation.

The ultrasonic surgical aspirator is a device used to resect the metastatic tumor.[1] It is a hollow titanium probe that oscillates longitudinally over a distance of 100 µm at a frequency of 23 kHz. The field is kept dry by virtue of the aspiration feature and additional surgical aspirators. The instrument is moved slowly. It causes small peripheral parenchymal vessels to be coagulated; the larger structures are isolated so that they can be divided with clips or sutures.

Like the ultrasonic surgical aspirator, the argon beam coagulator offers a technological advance in treating multiple metastatic lesions.[1] Coupling of the radiofrequency electrosurgical generator with coaxial argon gas allows electric current to arc by way of the gas to nearby tissue to achieve focal coagulation necrosis to a depth of approximately 2.4 mm.

Right Hepatic Lobectomy

Massive shattering injuries to the major hepatic veins at or near the junction with the vena cava may necessitate hepatic lobectomy in order to control bleeding.[2] A lobectomy may also be successfully used to remove a malignancy.[7]

The right triangular and coronary ligaments are taken down, the bare area is entered, and the right hepatic vein is identified.[6] The right lobe may be elevated into the wound and retracted toward the left to determine resectability. The falciform ligament is preserved. A cholecystectomy is performed. The right hepatic artery is sacrificed. The right branch of the portal vein is divided either from an anterior approach or, if tumor interferes, by retracting the right lobe of the liver and dividing the right portal vein posteriorly. After dividing the artery and the portal vein, a line of demarcation occurs between the true right and left lobes, extending from the gallbladder to the vena cava. The right hepatic duct is ligated and divided.

After division of the portal structures, the right hepatic vein is dissected. Exposure is improved by retracting the right lobe into the wound. The vein is clamped with vascular clamps and closed with a vascular suture. Several small hepatic veins entering the retrohepatic inferior vena cava are ligated.

The liver is divided along the line of color demarcation. Division can be accomplished by the finger-fracture method, or using the ultrasonic dissector and individually ligating major structures as they are encountered. Much of the middle hepatic vein can be preserved and bleeding can be controlled by compression of the hepatic lobes by the surgeon's hands.

After removal of the specimen, residual bleeding vessels and duct structures are identified and oversewn. Large intersegmental veins are preserved. The right subphrenic dead space is drained by leaving the midportion of the wound open. Five or six rubber drains are brought out through the wound.[6]

Right Trisegmentectomy

Larger lesions or multiple lesions of the liver may require trisegmentectomy.[7]

The early steps in right trisegmentectomy are identical to those of right lobectomy. After completing the hilar division of the right vascular and duct structures, dissection of the trinity structures to the medial segment of the left lobe begins. The left portal vein, left hepatic artery, and left hepatic duct are dissected from the medial segment by following their course along the segment's undersurface. Individual branches to the liver substance are ligated and divided. Usually one or two fair-sized posteriorly directed vessels enter the caudate lobe and are spared (unless the caudate lobe is also to be removed). The mobilization is stopped just short of the umbilical fissure.[8]

The majority of the vascular and duct structures to the medial segment originate in the umbilical fissure. Dissection is done just to the right of the fissure, however, in order to protect the residual trinity structures to the left lateral segment. Again, we prefer splitting the liver by finger fracture or by ultrasonic dissection and individually ligating the vascular and duct structures running into the medial segment. Quite early in this cleavage phase the medial segment becomes ischemic and provides an excellent guide to follow as the liver is split toward the diaphragm. Later, the middle hepatic vein is encountered and ligated. Hemorrhage is controlled during the resection by hepatic compression with the surgeon's and assistant's hands. The entire right lobe and left medial segment are removed in continuity and the massive dead space is completely drained.[8]

Division of the main right hilar and triad structures to the medial segment of the left lobe is completed. The right and middle hepatic veins have been divided and oversewn. The resection line followed the right side of the falciform ligament to the vena cava. In this case, the caudate segment was removed.[8]

Left Trisegmentectomy

The falciform ligament is divided and the suprahepatic bare area is entered to expose the main hepatic veins and suprahepatic inferior vena cava. The left triangular liga-

ment is incised, thus fully exposing the left hepatic vein. The left hepatic artery, left portal vein, and left hepatic duct are divided, but the first posteriorly directed branches are spared unless the caudate lobe is to be taken. The left hepatic vein is transected and closed with a vascular suture. If accessible, the middle hepatic vein is also divided. If the middle hepatic vein is not accessible, it is divided during hepatic cleavage.[8]

Cleavage of the hepatic parenchyma is started along a plane that runs roughly along a line beginning at the left hepatic vein and continuing to the obliterated ductus venosus, the liver hilus, the base of the gallbladder and the midpoint between the gallbladder and the right lateral extremity of the liver. In children, a natural groove in this area often identifies the separation of the anterior and posterior segments. Superiorly, the dissection begins at the coronary ligament, just in front of the right hepatic vein. These two planes of dissection are deepened and brought toward each other, ligating all anteriorly directed structures and preserving those running posteriorly. If properly developed, the plane separates the anterior and posterior segments of the right lobe. The entire left lobe and anterior segment of the right lobe are removed in continuity.[8]

Wedge Excision

This operation is reserved for lesions less than 3 cm in diameter that are located near the periphery of the organ. The liver is compressed on either side of the lesion by the surgeon's and assistant's hands and the lesion sharply excised. Hemorrhage is brisk afterward and is controlled by individual suture ligation of major arterial, venous, and ductal structures. Minor residual bleeding is dealt with by electrocoagulation. The margins of the defect are not reapproximated. Employment of the ultrasonic scalpel for wedge excision reduces blood loss significantly.

Postoperative Care

Parenteral antibiotics (begun immediately preoperatively) are discontinued after 5 days unless a specific infection exists. Drains are advanced after their effluence ceases. Further advancement is postponed if drainage resumes. In cases of trisegmentectomy, the residual dead space may be irrigated with topical antibiotic solutions after drain removal. Serum glucose levels are monitored frequently during the first 24 hours and 10% glucose intravenous are given if levels are low. Albumin and clotting factor synthesis may be started 2 to 3 days after operation. In the case of malignancy, chemotherapy is initiated as soon as recovery from operation is assured.

Continued bleeding in the immediate postoperative period is generally caused by ineffective mechanical hemostasis and not by a coagulopathy; thus, it usually requires early reexploration. Persistent leakage of bile or development of biliary fistula is extremely rare. The most common complication is a subphrenic abscess that usually becomes manifest on the fifth postoperative day. In the past, a subphrenic abscess required drainage through the lateral aspect of the major incision, but recently it has been managed successfully by ultrasonographically controlled placement of a pigtail catheter.

Postoperative Complications

Subphrenic abscess is not an unusual complication after major liver resection, and particularly after right hepatectomies, unless perfect drainage is provided. Fever is frequently the first indication of the complication. Treatment is best provided by reopening a portion of the wound.

Biliary fistula occurs in patients but is generally self-limited. Most fistulae close within 10 days, although in one case, after a trisegmentectomy, bile drained for 52 days before ceasing spontaneously.[3]

Most patients become mildly jaundiced for 5 to 10 days following trisegmentectomy. Serum hepatic enzyme levels may also be transiently elevated. These biochemical aberrations are a consequence of the massive resection and the small volume of remaining liver. Fortunately, the residual hepatic segment has commonly undergone hypertrophy due to the slow tumor growth and, taken in conjunction with its rapid growth after resection (complete liver regeneration occurs in 2 to 3 months), this hypertrophy accounts for the limited duration of these biochemical aberrations.

Delayed hemorrhage is an unusual complication after liver resection. Mechanical factors may be responsible, but often hemorrhage is a consequence of intraoperative ischemia of the residual liver.

Conclusion

Resections of the liver have been performed for some time, but they remain one of the most formidable surgical undertakings, both for the patient and for the surgical team. Mortality has improved in recent years because of new advances aimed at controlling blood loss. Liver resections can be complex and, as a result, the surgical team must depend on each other to benefit the patient. Knowledge and familiarity with the technical aspects of this operation helps surgical technologists to understand their contribution to the team. Δ

References

1. Petty LR. Surgery of the liver, biliary tract, pancreas, and spleen. In: Meeker MH, Rothrock JC, eds. *Alexander's Care of the Patient in Surgery*. 9th ed. St Louis, Mo: Mosby-Year Book; 1991:258.
2. Schwartz SI. *Principles of Surgery*. 6th ed. New York, NY: McGraw-Hill, Inc; 1994.
3. Lilly JR, Stellin G. Liver resections in children. In: Nixon HH, Spitz L, eds. *Rob & Smith's Operative Surgery*. 4th ed. London, England: Butterworth; 1988:466-471.

(Continued on page 25)

Denis Scannell, CST, is employed at Irvine Medical Center in Irvine, California, where he specializes in thoracic surgery. He received his certificate in surgical technology from California Paramedical and Technical College in Long Beach in 1993.