Endoscopic Laser Cholecystectomy

ARTICLE BY SUZANNA DE KATAY, CST

For the past few years, surgeons have been performing laser procedures with the use of an endoscope;, however, laser endoscopy had been primarily used to treat gynecologic problems. In February 1989, endoscopic laser cholecystectomy was introduced for the treatment of gallbladder disease, one of the most common adult disorders.[1]

An estimated 8% to 10% of the United States population harbor gallstones. The incidence is 2.5 times greater in women than in men. The four "Fs"—fat, female, fertile, and forty—are sometimes used to describe the population with the highest incidence.[2] The prevalence increases with age, making gallstones and other conditions associated with gallbladder disease a significant health problem for people over the age of 40.[2]

Anatomy of the Region

The gallbladder is a pear-shaped, tubular organ 6 cm to 10 cm in length and 5 cm in diameter with a filling capacity of 45 mm. Its location is in the upper right quadrant at the angle between the costal margin and the rectus abdominis muscle. It is found between the right and quadrate lobes of the liver and lies in a fossa on the ventral surface of the liver. The gallbladder may be embedded in the liver parenchyma or adhered to the liver by peritoneum. Surgical excision is easier when the gallbladder has little or no peritoneal attachments. The gallbladder is situated near the superior duodenum and transverse colon and may be attached to either of these structures. The organ is divided into three parts including the fundus, the body, and the neck. The neck may contain a pendulous pouch, which is referred to as Hartmann's pouch. The arterial blood supply to the gallbladder arises off the cystic artery, which is a branch of the right hepatic artery (Figure 1).

The function of the gallbladder is to store and concentrate bile by mucosal absorption of electrolytes and water. Bile consists of electrolytes, bile salts, protein, cholesterol, fats, and bile pigments. Bile gets its color from bilirubin diglucuronide, which is a product of hemoglobin.[2] Vagal stimulation increases the secretion of bile whereas stimulation of the splanchnic nerve results in decreased bile secretion.[2]

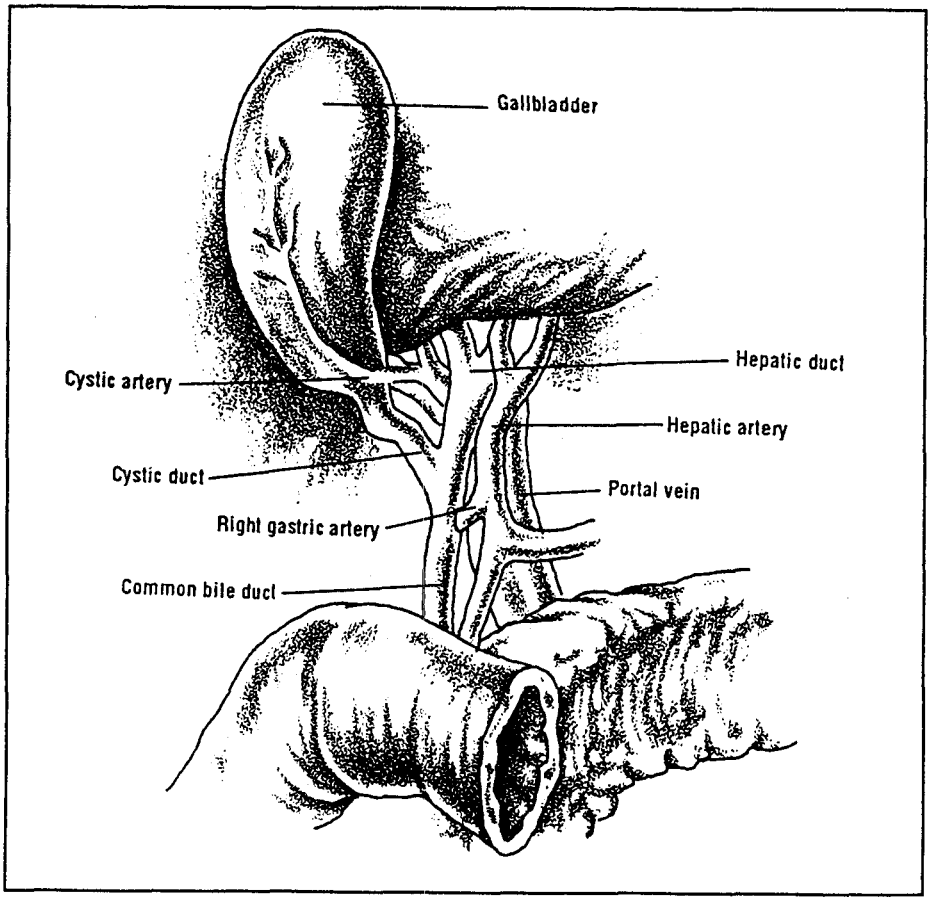

Figure 1. Anatomy of gallbladder and surrounding structures.

Patient Selection and Advantages
For more than a century, standard cholecystectomy had been the method of treatment for gallbladder disease.[3] As recently as 1993, acute cholelithiasis, jaundice, stones in the common bile duct, a need for common bile duct exploration, obesity, and previous abdominal surgery were considered contraindications for endoscopic laser cholecystectomy.[1] Today, surgeons have gained greater operative experience and those previous contraindications no longer make an individual ineligible for this procedure.[3] Traditional cholecystectomy requires the surgeon to make a large, right subcostal incision, which can be extremely painful postoperatively and leaves an unsightly scar. Endoscopic laser cholecystectomy is often performed with cholangiography. Cholangiography is the injection of radiopaque dye into the cystic duct to determine the presence of gallstones.[4] In endoscopic laser cholecystectomy, the surgeon makes four puncture wounds that measure 1 cm to 2 cm, causing the patient much less postoperative pain and minimal scarring.[1] What pain is present is due less to the incisions than to the phrenic nerve irritation caused by pressure on the diaphragm during carbon dioxide insufflation of the abdomen.

Instruments and Equipment
Basic equipment needed for endoscopic laser cholecystectomy includes a laser, a zero-degree 10-mm laparoscope, a video camera and video cassette recorder, a light source, a fiberoptic cable, high-resolution video monitors, video carts, an insufflator, an endocoagulator, and a suction/irrigation unit.[5] A great deal of care must be taken with the placement of all this equipment so that the many wires, cables, and cords do not become tangled or interfere with the movement of operating room personnel.

Instrumentation for an endoscopic laser cholecystectomy typically consists of a minor instrument set and specially designed instruments. For example, dissecting and grasping instruments should have atraumatic jaws and rounded tips to decrease the chances of perforating the gallbladder during retraction and consequently causing gross spillage of the organ's contents into the peritoneal cavity, resulting in peritonitis. Grasping forceps should have heavier jaws than those used to handle the ovaries and the uterus.[6] All grasping instruments should be insulated to permit cauterization of small blood vessels and lymphatics.[3] In addition, instruments used near the laser site should be dulled, ebonized, or have nonreflective anodized finishes.[7] This helps decrease the amount of direct laser beam reflection and beam scatter that can inadvertently cause "hot spots" on the monitors.[1] A few drops of an antifog solution (such as Ultra Stop) are applied to the distal end of the laparoscope. Fogging can also be prevented by dipping the same end of the laparoscope into warm saline.

Today, surgeons have gained greater operative experience and... previous contraindications no longer make an individual ineligible for this procedure.

Typical endoscopic laser cholecystectomy extras include a self-retaining forceps with alligator jaws, a smooth monopolar forceps, a microdissecting clamp (used extensively around the common bile duct for blunt dissection), a claw-type forceps (used to grab the gallbladder), and sharp microscissors (used to nick the cystic duct when cholangiography is performed). Hook scissors may be used to ligate the cystic duct, and a clip applier (Endoclip) is used to clip the cystic duct and the cystic artery. In addition, a Verres needle, a Foley catheter (which is connected to a closed urinary drainage system for measuring urinary output), two 5-mm trocars, and two 10-mm trocars are needed.[3]

The suction/irrigation unit is very important. Often, the surgeon will pass the laser fiber through the suction/irrigation unit, combining three functions into one instrument.

The endocoagulator permits the thermal coagulation of tissues before they are cut. Division of adhesions can be bloodless if the adhesions are first coagulated with this unit. Electrosurgery can be used for this purpose, but there is possible danger of burning the bowel when adhesions are coagulated electrically. Electrosurgery is best reserved for controlling bleeding on the liver bed, when control by the laser or clip appliers proves difficult.[3]

If complications should arise and the procedure can not be continued laparoscopically, a complete abdominal set, total gallbladder set, and the specific surgeon's gallbladder and abdominal extras must be kept sterile on hand.[5] Gallbladder instruments are much longer than standard instruments because of the area in which the surgeon must work, with the curve of these instruments parallel to the finger rings rather than perpendicular.

Patient Preparation
Initially, the patient is placed on the operating room table in the supine position. Anti-embolism stockings may be put on the patient to aid in prevention of venous pooling in the lower extremities if the patient needs to be put into the reverse Trendelenburg position.[6] The patient's bony prominences are padded, and the arm with the intravenous site is also padded and secured to the arm board so it is easily accessible to anesthesia personnel. The patient's other arm is tucked in at his or her side and a safety strap is placed across the mid-thigh region to help maintain positioning.[5]

General anesthesia is administered. This typically may consist of 3 mg of tubocurarine chloride (Curare), a non-depolarizing muscle relaxant, and 2 cc of fentanyl, a narcotic. An endotracheal tube is inserted and the patient is preoxygenated. Also, 100 mg of succinylcholine chloride (Anectine), a depolarizing muscle relaxant, is given. Thiopental sodium is then given,

after which anesthetic gases are administered. Nitrous oxide is not used because it may cause bowel distention.[5]

A nasogastric tube is inserted to decompress the stomach and avoid injury from instrumentation and to reduce its potential physical interference in the operative field.[5] The patient's eyes are covered with saline-moistened sponges. A Foley catheter is inserted to keep the patient's bladder drained and to reduce the chances of injury from instrumentation (ie, trocars) and is removed in the immediate postoperative period.[5]

The patient's skin is prepped with povidone-iodine solution. The prepped area starts around the umbilicus and goes up to the nipple line, down to the groin, and laterally down the sides of the patient to the bedline. The umbilicus is prepped last.

In order to move the organs out of the way and prevent injury to them when placing the trocars, the patient is put into the reverse Trendelenburg position and may remain in this position to allow better access to the operative area. The surgeon may also ask for the operating room table to be tilted to the left for the same reason.

Draping consists of four towels placed around the operative area secured by towel clips, followed by a self-adhering plastic sheet (Trengard) and a fenestrated abdominal drape. Another towel is placed at the bottom edge of the fenestration toward the patient's feet.

Operative Procedure

At the start of the procedure, a disposable Verres needle is inserted through the umbilicus through an incision the surgeon makes with a No. 15 knife blade on a No. 3 knife handle. Carbon dioxide is pumped through the Verres needle into the abdominal cavity with an insufflator to obtain a pneumoperitoneum.

The Verres needle is then removed and a 5-mm disposable trocar is inserted through the same site. A 5-mm laparoscope is inserted through the sheath and examination of the umbilical area is made to check for adhesions. Any adhesions are dissected away.[3]

Accurate placement of the trocars is extremely important for optimal retraction, visualization, and dissection angles. A 10-mm trocar is placed in the folds of the umbilicus for placement of the laparoscope and attached video camera. Another 10-mm trocar is placed 5 cm below the xiphoid process in the midline and is used for dissection and as an entry portal for the clip applicator (Figure 2). The 5-mm trocars are placed 2 cm below the right costal margin in the midclavicular line and at the level of the umbilicus in the anterior axillary line (see Figure 2). These are used to retract the gallbladder and the liver.

The dome of the gallbladder is pushed superiorly and laterally (toward the right shoulder) with a lateral grasping forceps causing stretch to be placed on the gallbladder and elevation of the liver, which simulates the same movements used in traditional open cholecystectomy. The midclavicular forceps controls Hartmann's pouch and places tension on the cystic duct and the cystic artery. Keeping the gallbladder on stretch, Hartmann's pouch is pulled away from the liver thereby exposing the triangle of Calot and making dissection possible without injury to the common bile duct.[3]

Dissection is performed through the upper midline sheath. Beginning at the gallbladder, dissection proceeds toward the common bile duct. The cystic duct is identified initially at the neck of the gallbladder and then dissected posteriorly and laterally from the surrounding tissues until the junction between the common bile duct and the cystic duct is visualized. At this point, the cystic artery can be safely dissected starting at the neck of the gallbladder and working toward the right hepatic artery. All dissection around the triangle of Calot is performed bluntly.[3]

If bleeding is encountered during the cystic artery dissection, the use of cautery or the clip applier may be used to obtain hemostasis since the other important structures have already been identified. If possible,

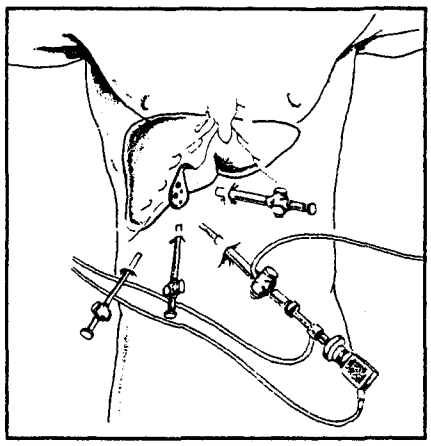

Figure 2. Cannulae placement for cholecystectomy.

the cystic artery should be clipped prior to cystic duct division. This prevents the proximal end of the vessel from retracting into the hepatoduodenal ligament if the artery becomes torn following the division and hemostasis of the bleeding artery becomes very difficult to achieve. If the cystic duct remains intact, the surrounding tissues will prevent the torn vessel from retracting out of the operative field. The cystic artery should be clipped and left intact during cholangiography. In case of accidental transection of the cystic duct, the cystic artery will keep the duct connected to the gallbladder and provide better control.[3]

Once the cystic duct is clipped, the laser fiber is introduced through the suction/irrigation unit through the upper midline cannula. Laser transection of the cystic duct and

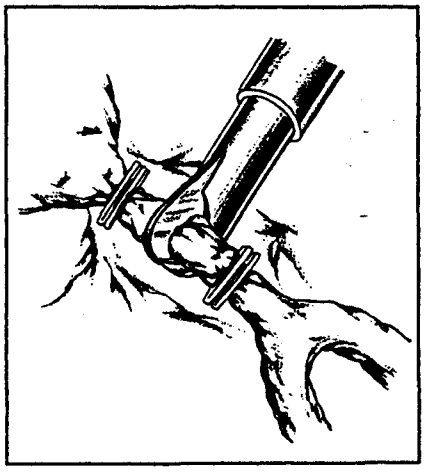

Figure 3. Division of the cystic duct.

the cystic artery is performed (Figure 3). When using the argon, carbon dioxide, or neodymium: YAG (Nd:YAG) laser with a sculptured fiber tip, the cystic duct and artery should be positioned in such a way that the liver will absorb any forward scatter of the laser beam, resulting in only superficial injury to the liver capsule.

The laser is used to transect all attachments of the gallbladder to the liver by pulling the gallbladder laterally. Most bleeding can be controlled by defocusing the laser beam, which is accomplished by retraction of the fiber 2 mm to 5 mm from the tissue, thereby decreasing the energy applied to the area and allowing coagulation. With the Nd:YAG laser and a cutting contact tip, minimal coagulation can be achieved. To ensure hemostasis, electrosurgery may have to be used more often with the Nd:YAG laser.[3]

The dissection continues and the peritoneal attachments of the gallbladder are exposed on either side by manipulation of the lateral and midclavicular grasping forceps, causing a twisting motion on the gallbladder. To expose the inferior peritoneal attachment, the midclavicular grasping forceps are pushed medially and superiorly, while the lateral grasping forceps, which hold the fundus of the gallbladder, are pushed inferiorly and laterally (left twist). The superior attachments of the peritoneum can be exposed using the exact opposite motions (right twist).

Should perforation of the gallbladder occur, dissection should continue until enough gallbladder wall is freed from the liver bed to allow grasping forceps to control the opening. A pre-tied suture is passed through the upper midline sheath and tied around the hole. Through a separate sheath, microscissors are passed to cut the suture.

It is very important to ensure hemostasis of the liver bed near the end of the dissection, because once the gallbladder is removed, it becomes difficult to expose the area to check for bleeding.[3] Intraabdominal pressure must be less than 15 mm Hg during this examination since high pressures can mask or slow bleeding significantly.[6]

Once hemostasis is attained, the gallbladder is dissected free and the abdomen is irrigated with a solution of normal saline solution with heparin (5000 U/L) and antibiotics (Figure 4). Heparin decreases clot formation, thereby allowing easier aspiration of spilled blood. After irrigation, the abdomen is suctioned dry.

The gallbladder is most easily removed through the umbilical puncture site since only one layer of fascia is present. The camera and laparoscope are removed from the umbilical sheath and placed through the upper midline sheath. The gallbladder is held near its neck over the liver with grasping forceps

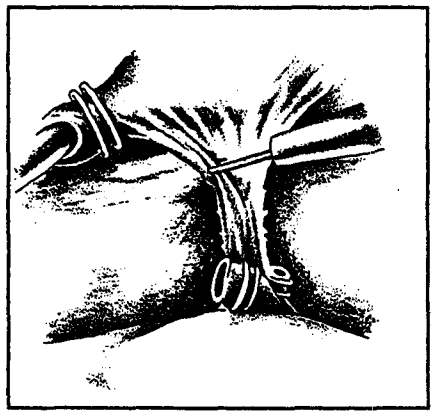

Figure 4. Gallbladder is dissected free from the liver bed.

placed through the lateral sheath. A forceps is passed through the umbilical portal to grasp the neck of the gallbladder. The neck of the gallbladder is pulled up into the umbilical sheath and the sheath is pulled out of the abdominal cavity.

The neck of the gallbladder is extracted out of the abdominal cavity and just outside the umbilicus. Gentle traction on the neck of the gallbladder will usually force bile through the fascial opening.[3] If the gallbladder will not come through the small opening in the fascia, a small suction device can be placed through the neck of the gallbladder to decompress it.

Stones that prevent the gallbladder from coming through the opening in the fascia may be crushed or removed with ring forceps placed through the neck of the gallbladder. If a stone is still too large to allow the gallbladder to be removed, the fascial opening may be enlarged 1 mm at a time, until it is large enough to accommodate removal of the gallbladder and stone, or the stone may be fractured with an ultrasonic device.[3]

The umbilical fascia is then closed with an absorbable suture such as 0 uncoated monofilament polyglactin 910. Skin incisions are closed with subcuticular stitches using absorbable 4-0 uncoated monofilament polyglactin 910 suture. A transparent film dressing (Tegaderm) may be applied over each wound.[1]

Special Safety Considerations

The two most common injuries involving the use of lasers are burns to the eyes and burns to the skin from a direct beam or its reflection. Burns to the cornea and retina can be prevented by the vigilant use of laser-specific protective eye wear by all operating room personnel who are involved in a laser procedure. The eye wear must assure absorption of dangerous radiation yet allow the transmission of the useable and safe light rays. Eye protection for the patient is extremely important as well. Laser-safe protective eye wear, saline-moistened eye pads, or special corneal protectors are available for this purpose. Special filters that will attach to the eyepiece of the endoscope to protect the surgeon's eyes are also available. Laser-specific warning signs along with a pair of the protective eye wear must be available at each entrance to the operating room where the laser is being used.

Whether the laser is used for cutting, coagulating, or vaporizing, all tissue that comes into contact with the beam is destroyed. Therefore, all healthy tissue must be protected. Saline-moistened towels around the operative site serve this purpose. Lasers should be kept in the standby mode when not in operation to protect personnel and patients from the laser beam.

Nonwoven drapes, muslin, and

clothing must be flame retardant to reduce the risk of combustion. The anesthesiologist will use nonflammable gases in the administration of anesthesia throughout the procedure. The anesthesiologist may also reduce the oxygen flow rate. No flammable agents such as alcohol are used during the case. A sterile basin of saline should be readily available on the back table in case of a fire. Additionally, water and a halon fire extinguisher, along with personnel versed in its use are necessary.

Laser use also causes the emission of toxic fumes. A smoke evacuator with a clean filter and laser masks, which have a tighter weave and a plastic liner than standard surgical masks, will prevent the inhalation of fumes, carbon particles, and viable cells.

During the procedure, the surgeon can use the laser in the intermittent mode to prevent intense heat buildup in the operative area. There is also a risk of electrical shock because of the higher voltage requirements of the laser. Therefore, leak-proof hose fittings and thorough inspection of the electrical cords is a must before every procedure.

Dulled or anodized instrumentation is used and must be carefully and thoroughly inspected by the surgical technologist before each laser procedure to ensure that the coating is not scratched or chipped. If instruments are scratched or chipped, they should be removed from the sterile field and sent out for repair. Using damaged instrumentation could cause reflection of the laser beam and possibly result in the destruction of healthy tissue.

Lasers should have a designated storage area to prevent damage to the equipment. It is also important to have a standardized laser policy and procedure book available to all personnel and only certified laser operators should have access to the laser key. There should be an appointed laser safety officer who inspects all new installations and assures regular, routine maintenance on the lasers. Lasers weigh hundreds of pounds and proper body mechanics should be practiced when moving the laser to prevent injuries to personnel.

Postoperative Care

Postoperative pain caused by phrenic nerve irritation can be relieved by heat application to the right shoulder. Early ambulation, which increases the rate of carbon dioxide absorption, also helps to rid the patient of this pain.[1] In traditional cholecystectomy, the patient must wait up to 6 weeks to resume unrestricted activities.[1] Endoscopic laser cholecystectomy requires a hospitalization stay of 1 to 2 days, and often can be performed on an outpatient basis. The patient can usually return to normal activities within 3 to 4 days, but is restricted from lifting heavy objects for 8 to 10 days.[1]

Conclusion

The use of lasers is becoming increasingly common as the need for more efficient use of time and resources gains importance in all specialties. As a result of the shortened hospital stay, the average hospital bill for an endoscopic laser cholecystectomy is approximately $800 less than the cost of a traditional cholecystectomy. When performed by a trained and professional operating room staff, the benefits to the patient greatly outweigh any potential risks associated with laser procedures. Δ

... Eye wear must assure absorption of dangerous radiation yet allow the transmission of the useable and safe light rays.

Acknowlegements

The author wishes to express her appreciation to Conrad Shull for providing her with access to the resources necessary to research this subject.

References

1. Jackson DC, Martin TE, Evans MM, Rubino PA. Endoscopic laser cholecystectomy. *AORN Journal*. June 1990: 1546.
2. Morrison CW, Kepas DE, Wills RE, Grusendorf PE. Cholecystectomy: A surgical perspective. *The Surgical Technologist*. Jan 1991:12.
3. Reddick EJ. Laparoscopic laser cholecystectomy In: Zucker KA, ed. *Surgical Laparoscopy*. St Louis, Mo: Quality Medical Publishing, Inc.; 1991:183.
4. Fuller JR. *Surgical Technology: Principles and Practice*. 3rd ed. Philadelphia, Pa: W. B. Saunders Company; 1994.
5. Guilbeau AM, et al. Laser laparoscopic cholecystectomy. *AORN Journal*. Oct 1990:780.
6. Goldman J, Kirshenbaum G. Laparoscopic laser cholecystectomy. *The Surgical Technologist*. Jan 1991:16.
7. Recommended practices: Laser safety in the practice setting. *AORN Journal*. Nov 1989:1018.

Bibliography

Goldman MA. *Pocket Guide to the Operating Room*. Philadelphia, Pa: F. A. Davis Company; 1989.

Meeker MH, Rothrock JC. *Alexander's Care of the Patient in Surgery*. 9th ed. St Louis, Mo: Mosby Year Book, Inc; 1991.

Thomas CL, ed. *Taber's Cyclopedic Medical Dictionary*. 16th ed. Philadelphia, Pa: F. A. Davis Company; 1989.

Suzanna de Katay, CST, is currently employed as a surgical technologist at the Robert Packer Hospital in Sayre, Pennsylvania. The subject of lasers interests her as is shown by this article, her second on the subject to be published in the journal. Her first article won third place in the 1993 Writer's Award.